



Title	Generalized spike-wave discharges involve a default mode network in patients with juvenile absence epilepsy : A MEG study
Author(s)	Sakurai, Kotaro; Takeda, Youji; Tanaka, Naoaki; Kurita, Tsugiko; Shiraishi, Hideaki; Takeuchi, Fumiya; Nakane, Shingo; Sueda, Keitaro; Koyama, Tsukasa
Citation	Epilepsy Research, 89(2-3), 176-184 <a href="https://doi.org/10.1016/j.epilepsyres.2009.12.004">https://doi.org/10.1016/j.epilepsyres.2009.12.004</a>
Issue Date	2010-05
Doc URL	<a href="http://hdl.handle.net/2115/43098">http://hdl.handle.net/2115/43098</a>
Type	article (author version)
File Information	ER89-2-3_176-184.pdf



[Instructions for use](#)

**Generalized spike-wave discharges involve a default mode network in patients with juvenile absence epilepsy: A MEG study**

Kotaro Sakurai <sup>a,\*</sup> Youji Takeda <sup>a</sup>, Naoaki Tanaka <sup>b</sup>, Tsugiko Kurita <sup>a</sup>, Hideaki Shiraishi <sup>c</sup>,  
Fumiya Takeuchi <sup>d</sup>, Shingo Nakane <sup>e</sup>, Keitaro Sueda <sup>c</sup>, Tsukasa Koyama <sup>a</sup>

<sup>a</sup> Department of Psychiatry and Neurology, Hokkaido University School of Medicine, Sapporo, Japan; <sup>b</sup> Athinoula A. Martinos Center for Biomedical Imaging, Massachusetts General Hospital, Charlestown, MA, USA; <sup>c</sup> Department of Pediatrics, Hokkaido University School of Medicine, Sapporo, Japan; <sup>d</sup> Department of Health Science, Hokkaido University School of Medicine, Sapporo, Japan; and <sup>e</sup> Division of Magnetoencephalography, Hokkaido University Hospital, Sapporo, Japan

Correspondence to: K. Sakurai, Department of Psychiatry and Neurology, Hokkaido University School of Medicine, North 15, West 7, Sapporo, 060-8638, Japan

Telephone: +81-11-716-1161 Fax: +81-11-706-5081

E-mail: kootaroo@ab.auone-net.jp

## **1 Introduction**

Absence epilepsy is an idiopathic generalized epilepsy characterized by typical absences and generalized tonic–clonic seizures. Usually, EEGs reveal bilateral, synchronous symmetrical spike-waves, at about 3 Hz, on a normal background activity (Commission, 1989). Although classified as a “generalized” form of epilepsy, evidence suggests that generalized spike-waves (GSWs) of absence epilepsy predominantly involve selective corticothalamic networks rather than causing global involvement.

Previous EEG and recent dense-array EEG studies have demonstrated that GSWs involve the medial prefrontal cortex (MPFC) predominantly during the repeating GSW cycles (Rodin, 1999; Holmes et al., 2004; Tucker et al., 2007). Results of those studies suggest that frontothalamic networks play an important role in the GSW process. Magnetoencephalographic studies also indicate frontal dominant cortical involvement (Stefan et al., 2009; Moeller et al., 2009).

Reports of functional magnetic resonance imaging (fMRI) studies describe that a negative blood oxygen level-dependent (BOLD) response occurs mainly in the bilateral frontal cortex, parietal cortex, and posterior cingulate during GSWs, with an accompanying positive BOLD response in the thalamus (Salek-Haddadi et al., 2003; Aghaknani et al., 2004;). The response is interpreted in the context of the “default mode network” (Gotman et al., 2005; Hamandi et al.,

2006; Laufs et al., 2006; Moeller et al., 2009). According to that hypothesis, the MPFC, precuneus, and posterior cingulate are active at rest and support the state of consciousness in a resting awake subject (Raichle et al., 2001).

Those reports suggest that GSWs involve the cortical areas that constitute the “default mode network”, and might explain the loss of consciousness during absence seizures (Gotman et al., 2005; Hamandi et al., 2006; Laufs et al., 2006; Moeller et al., 2009). However, fMRI studies are limited because the measured signals are related indirectly to neuronal activity, and its temporal resolution is significantly lower than that of either EEG or MEG. Therefore, it is uncertain whether the default mode network is truly involved in the GSW process.

To investigate the involvement of the cortical regions that constitute the default mode network during GSWs, we use magnetoencephalography (MEG) and analyses using dynamic statistical parametric mapping (dSPM; Dale et al., 2000). By imposing anatomical information about the cortical surface derived from magnetic resonance images (MRI) and noise normalization of the minimum norm estimate, dSPM provides spatiotemporal source distribution with millisecond temporal resolution. In fact, dSPM enables analysis epileptiform activity (Shiraishi et al., 2005).

In this study using dSPM, we investigated whether default mode networks are involved during GSWs in five patients with juvenile absence epilepsy (JAE).

## **2 PATIENTS AND METHODS**

### **2.1 Patients**

This study examined five patients with JAE (3 male, 2 female) aged 21–38 years (mean 27.2) treated at the Department of Psychiatry and Neurology at Hokkaido University Hospital during 2001–2006. Diagnoses were determined based on the detailed clinical history, standard scalp EEG, neurological examination, and MRI of the brain. Neurological examination results showed that all patients were normal. No structural lesions were observed on these patients' MRI. Typical absence was also recorded in four patients using long-term video-EEG monitoring. Four patients were under treatment with antiepileptic drugs at the time of MEG recording. Table 1 presents the patients' clinical profiles. All patients gave informed consent to MEG recording.

### **2.2 MEG, EEG, and MRI acquisition**

Using a 204-channel, whole-head gradiometer system (Vecterview; Elekta Neuromag Inc., Helsinki, Finland), MEG was recorded in a magnetically shielded room. The recording session for each patient was 30 min. The sampling rate was 600 Hz. Using scalp electrodes according to the international 10–20 system, with two additional electrodes for electrocardiogram monitoring, EEGs were obtained simultaneously with MEG. The EEG sampling rate was 256 Hz; the

high-pass filtering time constant was 0.3 s.

Using a 1.5-T MRI scanner (Magnetom VISION; Siemens AG, Erlangen, Germany) for the analysis of the MEG data (TE=60 ms, TR=100 ms, voxel size  $1.5 \times 1.5 \times 1.5 \text{ mm}^3$ ), MRI data were acquired.

### **2.3 MEG source analysis**

The MEG data were digitally filtered at a bandpass of 0.5–40 Hz for offline analyses. The segments containing GSWs were selected by visual inspection of the EEG and MEG. We selected GSWs lasting more than 1.5 s to examine the early parts of GSWs as well as the stereotyped spike-wave pattern. The distribution of the brain activity generating the GSWs was determined using dynamic statistical parametric mapping (dSPM).

### **2.4 Dynamic Statistical Parametric Mapping (dSPM)**

Clinical applications of MEG for epilepsy mostly use the single equivalent current dipole (ECD) model, which can localize spike sources accurately (Knowlton and Shih, 2004). However, the ECD model is of limited use if the underlying assumption of focality is not fulfilled, as for example, when the epileptiform activity occurs simultaneously across a wide area. For non-focal activity, distributed source models such as a dSPM are expected to be better suited

than the ECD model (Shiraishi et al., 2000).

The dSPM method (Dale et al., 2000) is based on a noise-normalized minimum L2-norm estimate. For dSPM, we used an anatomically constrained distributed source model, which subsumes that the sources are located in the cerebral cortex. The cortical surface was segmented from the MRI using software (FreeSurfer, Dale et al., 1999; Fischl et al., 1999b) and was subsampled to 5120 elements. The source model consisted of current dipole vectors located at each element. The forward solution was calculated using a boundary element model (BEM, Oostendorp and Van Oosterom, 1989; Hämäläinen and Sarvas, 1989) with conductivity boundaries determined from the segmented MRI.

The dSPM approach used to estimate the time course of activity at each cortical location is based on generalized least-squares or weighted minimum-norm solution (Hämäläinen and Ilmoniemi, 1994; Dale and Sereno, 1993). However, the estimate is normalized for noise sensitivity, thereby providing a statistical parametric map (Dale et al., 2000). Maps were calculated at 1.7-ms intervals. The significance of modulation at each site was calculated using an *F*-test (Dale et al., 2000; Dhond et al., 2001). These statistical maps differ from maps of estimated source strengths because the estimated noise variance is not constant across different cortical locations. However, because the same noise covariance estimates are used at all time points for a given cortical location, the source strength at a given location over time is directly

proportional to the statistical maps. The current approach provides dynamic statistical parametric maps (dSPM) of cortical activity with millisecond-order temporal resolution. The dSPM maps were superimposed on inflated geometrical representations of cortical surfaces that had been reconstructed from each patient's individual MRI (Dale et al., 1999; Fischl et al., 1999, 2001).

### **3 RESULTS**

#### **3.1 Early part of GSW**

We analyzed 11 GSWs obtained from 5 patients. For patient 3, hyperventilation was necessary to evoke GSWs. At the early parts of GSWs, dSPM showed an initial activation area in various cortical regions either unilaterally or bilaterally (Table 2). These regions varied among subjects, and even from one GSW to another in the same patient. The initial activation occurred 15–35 ms before the peak of a first EEG spike. After the initial activation, an abrupt activation was apparent in the MPFC and anterior cingulate. Although the time latency from the initial activation to the first medial prefrontal activation is not consistent, this activation appeared during the first spike-wave cycle. At the end of first slow wave components, 20–30 ms before the peak of a next EEG spike, strong activation in the bilateral MPFC and anterior



cingulated appeared. This activation was located in more anterior regions, sometimes including an orbital frontal cortex. In addition to the medial prefrontal activation, three patients (patient 1, 2, and 3) showed activation in the posterior cingulate and precuneus at the end of the slow wave or at the next spike component. At the peak of EEG spike components, strong and widespread cortical activation was observed.

### **3.2 Stereotyped GSW**

Once a rhythmic cycle of GSWs started, dSPM demonstrated a stereotyped pattern overall. After the peak of EEG spike components, widespread activation decreased gradually and appeared again at the peak of EEG positive spike before the next slow wave component. During the first half of slow wave components, no definite activation was observed. At the middle part of slow wave components, weak widespread lateral cortical activation appeared with or without medial prefrontal activation. Then the strong activation in the MPFC and anterior cingulate appeared at the end of slow wave components. In three patients (patients 1, 2, 3), this activation was followed by activation in the posterior cingulate and precuneus. Subsequently, it continued to produce strong and widespread activation at the next EEG spike component.

### **3.3 Illustrative cases**

### 3.3.1 Patient 1

The analyzed range of both the early part and stereotyped GSW are presented in Fig. 1. The dSPM of the early part of a GSW is portrayed in Fig. 2. Initial activation appeared in the left parietal cortex 35 ms before the first peak of EEG spike (time point a). The activation propagated over the left lateral frontal and temporal cortex (b). Near the peak of the EEG spike (c), a strong activation in the bilateral MPFC and anterior cingulate appeared. This activation disappeared in a short time; no definite activation was observed during the slow wave components. At the end of slow wave (d), the left lateral frontal and parietal cortexes were activated. Immediately thereafter (+12 ms), the bilateral MPFC, orbital frontal, posterior cingulate, and precuneus were activated simultaneously (e). Widespread strong activation was apparent at the peak of the EEG negative spike (g). The activation decreased gradually, and reactivated at the peak of the EEG positive spike (h).

The dSPM of a stereotyped GSW is depicted in Fig. 3. At the middle part of slow wave components (a), bilateral medial prefrontal activation and weak temporal activation appeared. This activation disappeared rapidly. At the end of slow wave components, widespread activation in the lateral frontal and temporal cortex (b) was followed by strong activation in the bilateral MPFC, anterior cingulate, lateral frontal, and temporal cortex (c). At the peak of EEG spike components (d), the medial prefrontal activation spread toward the posterior cingulate and

precuneus, and disappeared, with some remnant temporal activation (e). The medial prefrontal activation occurred again at the peak of EEG positive spike (f). At the middle part of the next slow wave component, the bilateral MPFC was activated (h), and continued to the next spike components.

### **3.3.2 Patient 2**

The dSPM of the early part of a GSW is portrayed in Fig. 5. The analyzed ranges are displayed in Fig. 4. The initial activation appears in the bilateral lateral frontal cortex 25 ms before the first peak of the EEG spike (time point a). At 95 ms after initial activation, the activation in the right MPFC and anterior cingulate appeared (b). This activation soon disappeared. At the end of first slow wave components, strong activation in the bilateral MPFC, anterior cingulate, lateral frontal, and parietal cortex appeared (c). Near the peak of the EEG spike, activation in the more anterior MPFC and anterior cingulate were observed, along with stronger lateral frontal activation (d). Subsequently, activation was observed in the bilateral posterior cingulate and precuneus in addition to the widespread lateral cortical activation (e). Activation in the posterior cingulate and precuneus once disappeared (f), then appeared again at the end of spike components (g), and continued until the onset of the next slow wave component (h).

The dSPM of the stereotyped GSW is presented in Fig. 6. At the end of slow wave components (a), the activation in the bilateral MPFC and anterior cingulate appeared. At the peak of EEG spike components (b, c), the MPFC, posterior cingulate, precuneus and lateral frontal cortex were activated simultaneously. This widespread activation disappeared after the spike components. At the middle part of slow wave components (d), activation in the right posterior cingulate and bilateral parietal cortex were observed. This activation soon disappeared. At the end of slow wave (e), bilateral medial prefrontal activation was apparent; it continued to the next spike-wave cycle.

#### **4 DISCUSSION**

We demonstrated that the cortical regions that constitute the “default mode network” are strongly involved during GSWs in some patients. Results show that focal cortical activation appears at the GSW onset.

Results of dSPM demonstrated strong activation in MPFC of all patients. In addition, dSPM showed activation in the posterior cingulate and precuneus in 3 of 5 patients simultaneously or slightly after medial prefrontal activation (Figs. 2, 3, 5, 6). Furthermore, dSPM showed that initial activation of GSW appears in the focal cortical regions (Table 2, Figs.

2, 5).

Recent dense-array EEG reports have described that the source of spike components of GSWs are located as frontopolar and in the orbital frontal cortex. The source of slow wave components is located in the MFC or frontotemporal cortex in five patients with idiopathic generalized epilepsy: including four absence epilepsies (Holmes et al., 2004; Tucker et al., 2007).

Results of these EEG studies suggest that absence seizures are not truly generalized, but are instead involve selective cortical networks, including orbital frontal and medial frontal regions. However, these results do not correspond to several fMRI studies showing involvement of posterior part of cortex, such as posterior cingulate and precuneus, in addition to the frontal region (Salek-Haddadi et al., 2003; Aghakhani et al., 2004; Gotman et al., 2005; Hamandi et al., 2006; Laufs et al., 2006; Moeller et al., 2009).

Although dense-array EEG studies can provide high spatial and temporal resolution, electrical scalp potentials are inherently limited by the conductivities of the skull and scalp. Subsequently, MEG studies were conducted for more detailed analyses.

Stefan et al. (2009) investigated the GSWs of seven patients with idiopathic generalized epilepsy: including two absence epilepsies (CAE) using a single or multiple dipole analysis and beamformer analysis. Those results demonstrate that the sources of spike components are

mainly located to frontal, perinsular, and thalamic regions, and suggest that GSW predominantly involves the “fronto–insular–thalamic network”. Involvement of posterior part of cortex was not observed.

Subsequently, Westmijse et al. (2009) analyzed the GSW of five patients with CAE using beamformer analysis, and also demonstrated that more sources of spike components can be found in the lateral and medial frontal regions. Furthermore, the parietal sources were found in four of five patients, although they have not described the “default mode network”.

We now report results of our MEG study, which showed that not only MPFC but also the posterior cingulate and precuneus that constitute a “default mode network” are strongly involved in the GSW process in some patients. Our results are of particular importance (beyond that of fMRI) because dSPM provides temporal information about the involvement of the default mode network.

Although we have demonstrated the involvement of default mode network in 3 of 5 patients, the remainder of patients and the previous MEG study by Stefan et al (2009) have not demonstrated the involvement of default mode areas except frontal regions. Is there any factor that causes this difference?

We consider two possible explanations. In the first, an arousal condition at the time of GSW recording might affect the electromagnetic nature of GSWs. During sleep, GSWs become

fragmented and irregular (Sato S. et al., 1973).

A possible methodical issue arises: dSPM identifies the locations of statistically increased current-dipolar strength relative to the noise level. We selected 40 s background MEG signals immediately before each analyzed GSW as noise. Therefore, an arousal condition during the noise period might affect the result of dSPM maps, especially alpha-wave-related regions.

Although previous MEG studies have not elucidated the arousal condition at the recording, in our study, GSWs recorded during drowsiness (patients 1, 2) showed the involvement of posterior cingulate and precuneus. On the other hand, GSWs recorded during a waking state (patients 4, 5) showed no involvement of these areas except the GSW of patient 3, which was evoked by hyperventilation.

In the second explanation, an antiepileptic medication might affect the GSW electromagnetic pathology. Seizures of idiopathic generalized epilepsy and GSW are well controlled by antiepileptic medications such as valproate (VPA). In our study, patients for whom seizures were controlled using VPA (patients 4, 5) showed GSWs of a short duration, and showed no involvement of the posterior part of the cortex. Patients who showed involvement of these areas (patients 1–3) did not take an effective antiepileptic medication. Their seizures were not controlled. Although patient 2 was taking VPA, its blood concentration level was low, and his seizures were not controlled at the time of recording. Moreover, all patients of a previous

MEG study that also showed parietal sources were not seizure-free at the time of the recording (Westmijse et al., 2009). Therefore, an effective antiepileptic medication might reduce pathological electromagnetic activity in the posterior part of the cortex in absence epilepsy.

In this study, dSPM revealed that the default mode areas are strongly “activated”. However, reports of studies using fMRI have described a negative BOLD response (deactivation) observed in the default mode areas (Gotman et al., 2005; Hamandi et al., 2006; Laufs et al., 2006; Moeller et al., 2009).

During epileptiform discharges, excitatory or inhibitory, one would expect increased neuronal activity and a consequent positive BOLD response. However, GSWs are commonly associated with negative BOLD response at the cortical level (Kobayashi et al., 2006).

Gotman (2008) suggested four possible mechanisms to explain the negative BOLD response during GSW: 1) A steal phenomenon secondary to increased cerebral blood flow in activated regions. (2) An abnormal coupling between neuronal activity and regional cerebral blood flow during GSW. (3) Decreased synaptic activity caused by reduced neuronal input or by functional deafferentation. (4) GABAergic-mediated inhibition resulting in decreased neuronal firing at a very low energy cost. In fact, that paper explained hypotheses 3 and 4 as highly probable.

In any case, the cortical regions that constitute a default mode network have an important



role in the GSW process because both our MEG study and fMRI studies have shown the involvement of the same areas. The involvement of the posterior part of cortex reported from fMRI studies has been regarded as a result of frontal epileptic discharges, not as a direct effect of epileptic discharges. However, our study suggests that GSWs directly affect the posterior part of the cortex as well as the medial frontal regions; it might suspend a default mode network strongly.

Focal cortical activation at the onset of a GSW is consistent with prior dense-array EEG and MEG studies. This might be explained using an animal study, the results of which suggest that the cortical activity is a dominant factor in the initiation of GSW (Meeren et al., 2002). In this study, the intracranial EEG of the rat model of absence seizures demonstrated that the somatosensory cortex drives thalamus during the first cycles of GSWs. Thereafter, cortex and thalamus drove each other, thereby amplifying and maintaining the rhythmic discharge. Although this rat model indicated the consistent cortical focus within the somatosensory cortex, and human EEG and MEG reports have described that the initial activation is mostly seen in the frontal cortex (Holmes et al., 2004; Stefan et al., 2009; Westmijse et al., 2009), our results revealed various locations of the cortical activation at the GSW onset. The variation in location suggests that no single cortical trigger zone exists for GSWs; they can arise from anywhere in the cortex as a part of the unstable thalamocortical network in human JAE (Blumenfeld, 2005).

The small number of patients that we examined might be regarded as a limitation of this study. Nevertheless, we used strict criteria of patient selection, excluding other forms of idiopathic generalized epilepsy: juvenile myoclonic epilepsy and GTC on waking. Therefore, our patients constitute a strictly homogeneous group in terms of diagnosis, despite their small number. Previous MEG studies have demonstrated that the cortical activated areas were influenced by a degree of myoclonic and absence components in patients with IGE (Stefan et al., 2009). All patients showed absence or GTC, none showed a myoclonic seizure.

In conclusion, results of our study show that the default mode network is strongly involved in the GSW process in some patients with JAE. We found also that focal cortical activation appears at the GSW onset.

## 5 ACKNOWLEDGMENTS

We confirm that we had read the Journal's position on issues involved in ethical publication and affirm that this report is consistent with those guidelines.

Disclosure: None of the authors has any conflict of interest to disclose.

## 6 REFERENCES

Aghakhani, Y., Bagshaw, A.P., Benar, C.G., Hawco, C., Anderman, F., Dubeau, F., Gotman, J.,

2004. fMRI activation during spike and wave discharges in idiopathic generalized epilepsy.

*Brain* 127, 1127-1144.

Commission on Classification and Terminology of the International League Against Epilepsy.,

1989. Proposal for revised classification of epilepsies and epileptic syndromes. *Epilepsia* 30,

389-399.

Dale, A.M., Sereno, M., 1993. Improved localization of cortical activity by combining EEG and

MEG with MRI cortical surface reconstruction: A linear approach. *Journal of Cognitive*

*Neuroscience* 5, 162-176.

Dale, A.M., Fischl, B., Sereno, M.I., 1999. Cortical surface-based analysis. I. Segmentation and

surface reconstruction. *Neuroimage* 9, 179-194.

Dale, A.M., Liu, A.K., Fischl, B., Buckner, R., Belliveau, J., Lewine, J., Halgren, E., 2000.

Dynamic statistical parametric mapping: combining fMRI and MEG for high-resolution

imaging of cortical activity. *Neuron* 26, 55-67.

Dhond, R., Buckner, R., Dale, A.M., Marinkovic, K., Halgren, E., 2001. Spatiotemporal maps of brain activity underlying word generation and their modification during repetition priming. *J Neurosci.* 21, 3564-3571.

Fischl, B., Sereno, M.I., Dale, A.M., 1999a. Cortical surface-based analysis II: inflation, flattening, a surface-based coordinate system. *Neuroimage* 9, 195-207.

Fischl, B., Sereno, M.I., Tootell, R.B., Dale, A.M., 1999b. High-resolution intersubject averaging and a coordinate system for the cortical surface. *Hum Brain Mapp.* 8, 272-284.

Fischl, B., Liu, A., Dale, A.M., 2001. Automated manifold surgery: constructing geometrically accurate and topologically correct models of the human cerebral cortex. *IEEE Trans Med Imaging* 20, 70-80.

Gotman, J., Grova, C., Bagshaw, A., Kobayashi, E., Aghakhani, Y., Dubeau, F., 2005. Generalized epileptic discharges show thalamocortical activation and suspension of the default state of the brain. *Proc Natl Acad Sci USA* 102, 15236-15240.

Gotman, J., 2008. Epileptic networks studied with EEG-fMRI. *Epilepsia* 49, 42-51.

Hämäläinen, M.S., Sarvas, J., 1989. Realistic conductivity geometry model of the human head for interpretation of neuromagnetic data. *IEEE Trans Biomed Eng.* 36, 165-171.

Hämäläinen, M.S., Ilmoniemi, R.J., 1994. Interpreting magnetic fields of the brain: minimum norm estimates. *Med Biol Eng Comput.* 32, 35-42.

Hamandi, K., Salek-Haddadi, A., Laufs, H., Liston, A., Friston, K., Fish, D.R., Duncan, J.S., Lemieux, L., 2006. EEG-fMRI of idiopathic and secondary generalized epilepsies. *Neuroimage* 31, 1700-1710.

Holmes, M., Brown, M., Tucker, D., 2004. Are “generalized” seizures truly generalized? Evidence of localized mesial frontal and frontopolar discharges in absence. *Epilepsia* 45, 1568-1579.

Kobayashi, E., Bagshaw, A.P., Grova, C., Dubeau, F., Gotman, J. 2006. Negative BOLD response to epileptic spikes. *Hum Brain Mapp.* 27, 488-497.

Knowlton, R.C., Shin, J. 2004. Magnetoencephalography in epilepsy. *Epilepsia* 45, 61-71.

Laufs, H., Lengler, U., Hamandi, K., Kleinschmidt, A., Krakow, K., 2006. Linking generalized spike-and-wave discharges and resting state brain activity by using EEG/fMRI in a patient with absence seizures. *Epilepsia* 47, 444-448.

Meeren, H., Pijn, J., Van Luijckelaar, E., Coenen, A., Lopes da Silva, F. 2002. Cortical focus drives widespread corticothalamic networks during spontaneous absence seizures in rats. *J Neurosci.* 22 , 1480-1495.

Moeller, F., Siebner, H.R., Wolff, S., Muhle, H., Granert, O., Jansen, O., Stephani, U., Siniatchkin, M., 2008. Simultaneous EEG-fMRI in drug-naïve children with newly diagnosed absence epilepsy. *Epilepsia* 49, 1510-1519.

Oostendorp, T., van Oosterom, A., 1989. Source parameter estimation in inhomogeneous volume conductors of arbitrary shape. *IEEE Trans Biomed Eng.* 36, 382-391.

Raichle, M.E., MacLeod, A.M., Snyder, A.Z., Powers, W.J., Gusnard, D.A., Shulman, G.L.,

2001. A default mode of brain function. *Proc Natl Acad Sci USA* 98, 676-682.

Rodin, E. 1999. Decomposition and mapping of generalized spike-wave complexes. *Clin*

*Neurophysiol.* 110, 1868-1875.

Sato, S., Dreifuss, F.E., Penry, J.K., 1973. The effect of sleep on spike-wave discharges in

absence seizures. *Neurology* 23, 1335-1345.

Salek-Haddadi, A., Lemieux, L., Merschhemke, M., Friston, K.J., Duncan, J.S., Fish, D.R.,

2003. Functional magnetic resonance imaging of human absence seizures. *Ann Neurol.* 53,

663-667.

Shiraishi, H., Ahlfors, S., Stufflebeam, S., Takano, K., Okajima, M., Knake, S., Hatanaka, K.,

Khosaka, S., Saitoh, S., Dale, A., Halgren, E., 2005. Application of magnetoencephalography in

epilepsy patients with widespread spike or slow-wave activity. *Epilepsia* 46, 1264-1272.

Stefan, H., Paulini-Ruf, A., Hopfengärtner, R., Rampp, S., 2009. Network characteristics of

idiopathic generalized epilepsies in combined MEG/EEG. *Epilepsy Res:*

doi:10.1016/j.eplepsyres.2009.03.015

Tucker, D.M., Brown, M., Luu, P., Holmes, M.D., 2007. Discharges in ventromedial frontal cortex during absence spells. *Epilepsy & Behavior* 11, 546-557.

Westmijse, I., Ossenblok, P., Gunning, B., Luijtelaar, G., 2009. Onset and propagation of spike and slow wave discharges in human absence epilepsy: A MEG study. *Epilepsia:*

doi:10.1111/j.1528-1167.2009.02162.x

## **Figure legends**

### **Figure 1**

Generalized spike and wave discharges (GSWs) on EEG (patient 1). MEG data corresponding to these EEG discharges were analyzed using dSPM. Vertical lines represent the analyzed range. The sampling rate was 256 Hz; the band-pass width was 0.5–70 Hz.

### **Figure 2**



The early part of GSW in patient 1 presented in Fig. 1: (A) MEG waveforms. (B) Top: EEG wave form. Bottom: A typical MEG waveform at one channel and a root mean square (RMS). (C) A dSPM map at each time point portrayed in (B). It is displayed on the inflated cortical surface, with darker gray representing the cortex buried in the sulci; lighter gray represents the gyral cortex. The threshold of displayed activity is  $p < 0.001$ ; full yellow represents  $p < 10^{-7}$ .

### **Figure 3**

The stereotyped GSW in patient 1 presented in Fig. 1: (A) MEG waveforms. (B) Top: EEG wave form. Bottom: A typical MEG waveform at one channel and a root mean square (RMS). (C) A dSPM map at each time point portrayed in (B). It is displayed on the inflated cortical surface, with darker gray representing the cortex buried in the sulci; lighter gray represents the gyral cortex. The threshold of displayed activity is  $p < 0.001$ ; full yellow represents  $p < 10^{-7}$ .

### **Figure 4**

Generalized spike and wave discharges (GSWs) on EEG (patient 2). The early part and each GSW were analyzed using dSPM. Vertical lines represent the analyzed range. The sampling rate was 256 Hz; the band-pass width was 0.5–70 Hz.

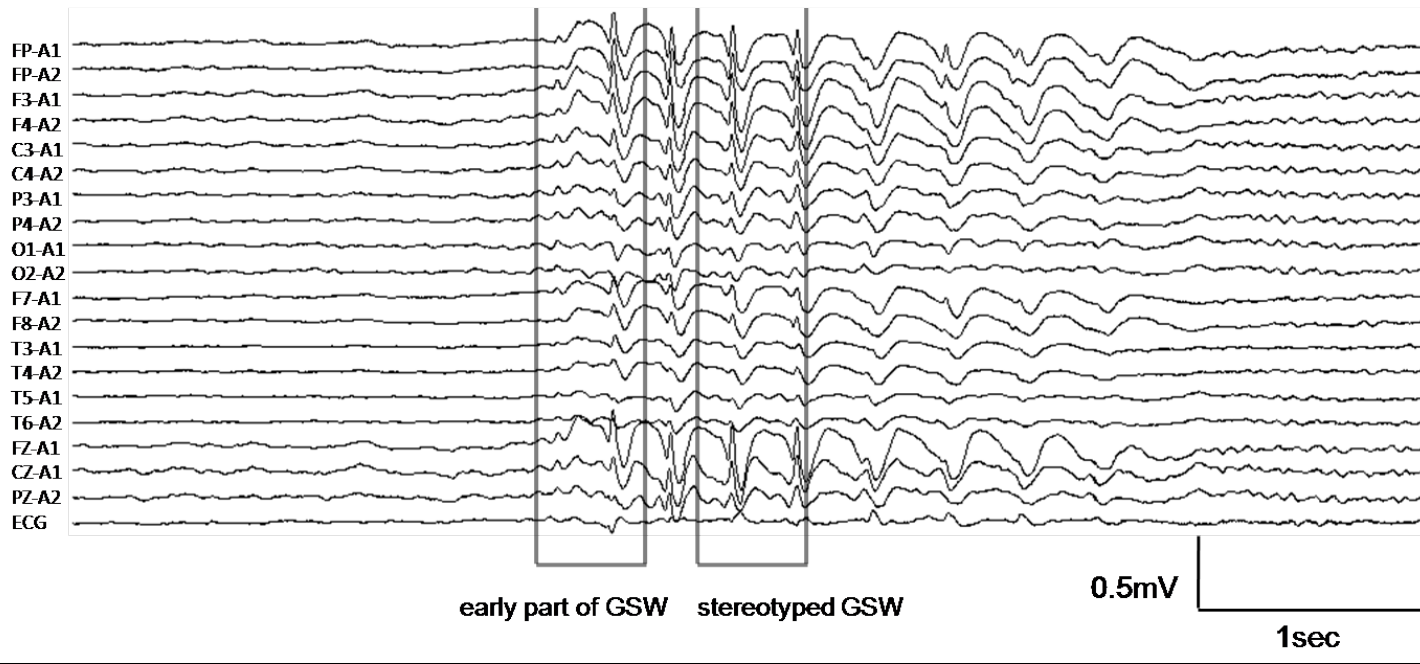
### **Figure 5**

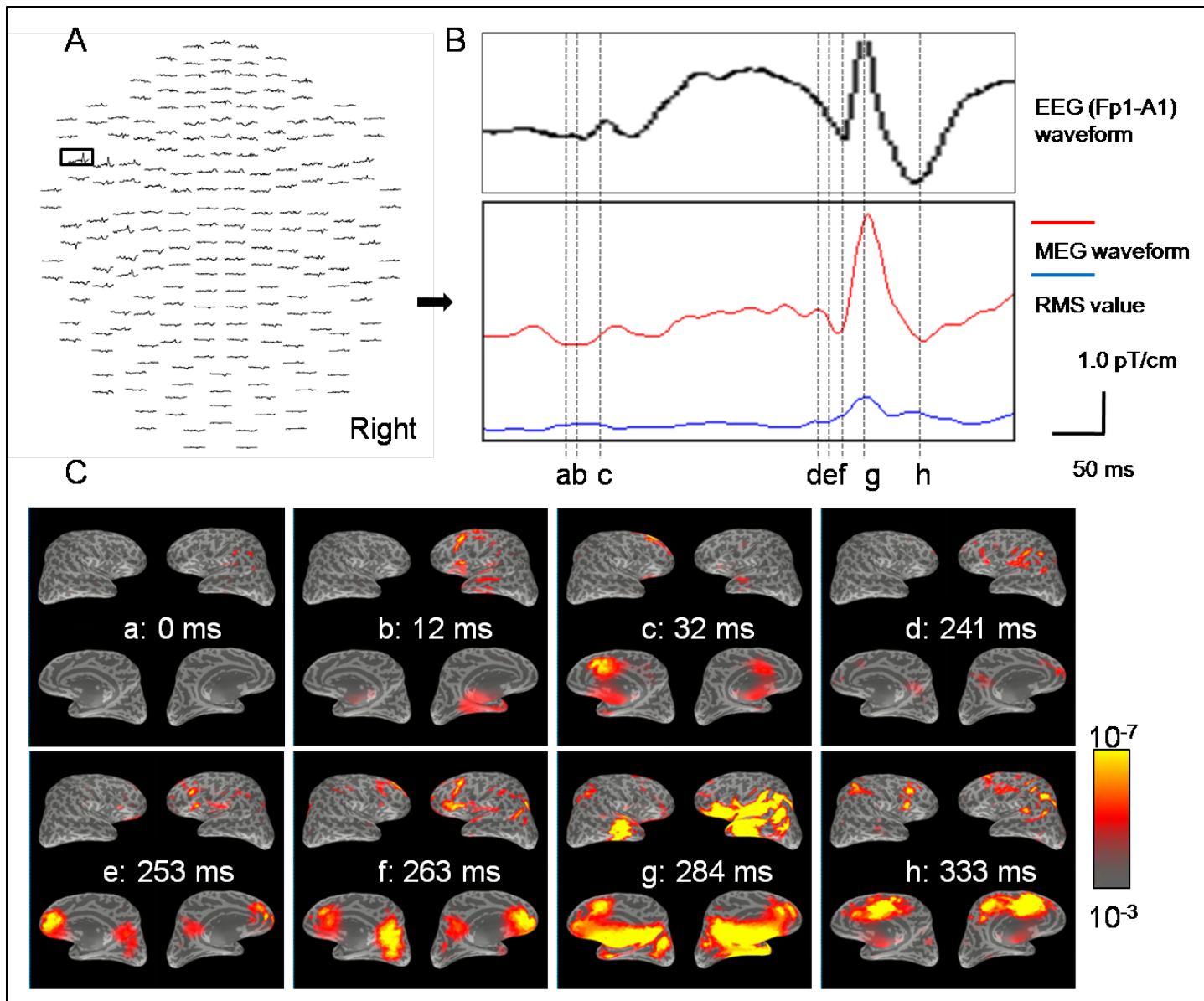
The early part of a GSW in patient 2 is depicted in Fig. 4: (A) MEG waveforms. (B) Top: EEG wave form. Bottom: A typical MEG waveform at one channel and a root mean square (RMS). (C) A dSPM map at each time point portrayed in (B). It is displayed on the inflated cortical surface, with darker gray representing the cortex buried in the sulci; lighter gray represents the gyral cortex. The threshold of displayed activity is  $p < 0.001$ ; full yellow represents  $p < 10^{-7}$ .

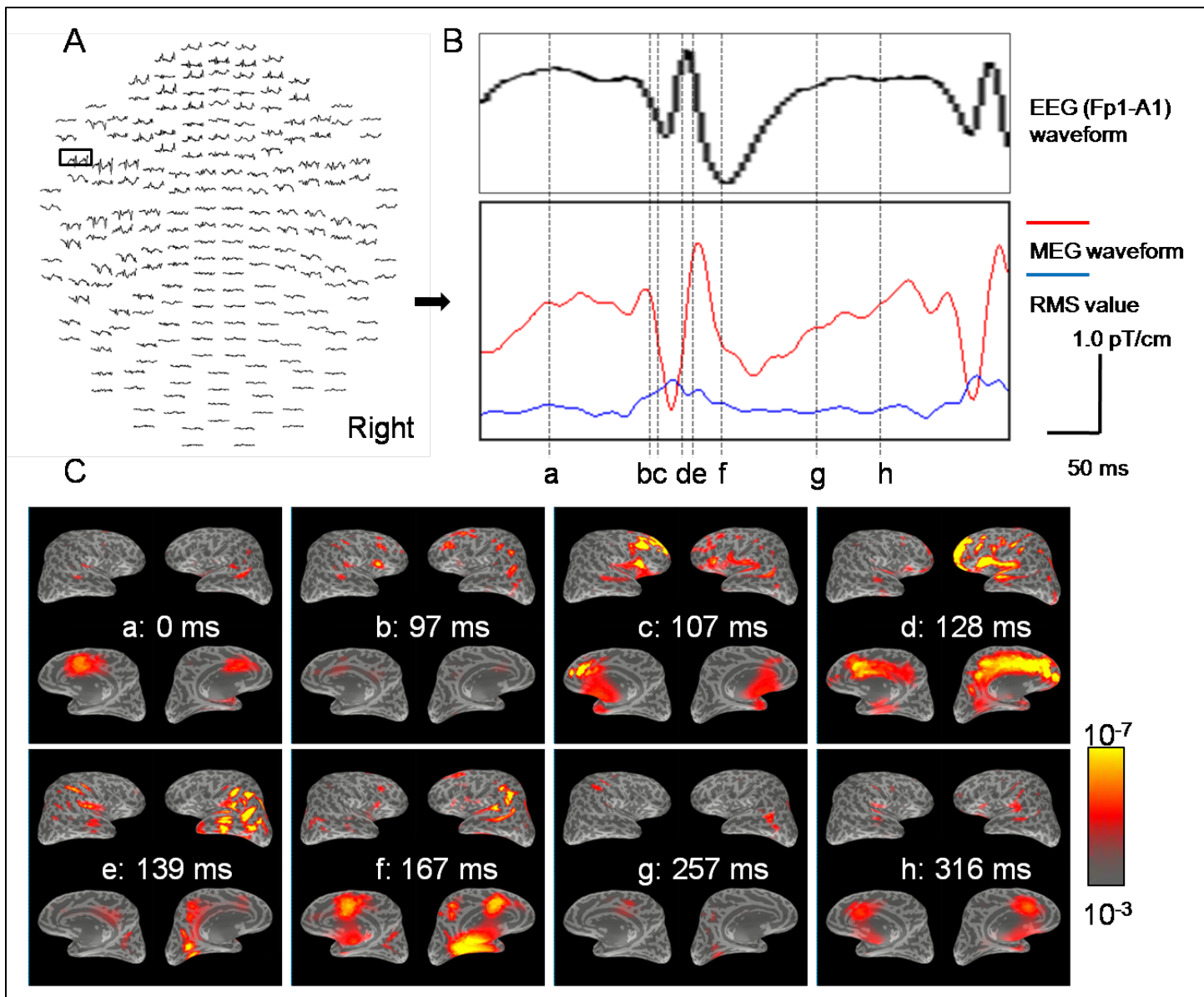
### **Figure 6.**

Stereotyped GSW in patient 2 shown in Fig. 4: (A) MEG waveforms. (B) Top: EEG wave form. Bottom: A typical MEG waveform at one channel and a root mean square (RMS). (C) A dSPM map at each time point portrayed in (B). It is displayed on the inflated cortical surface, with darker gray representing the cortex buried in the sulci; lighter gray represents the gyral cortex. The threshold of displayed activity is  $p < 0.001$ ; full yellow represents  $p < 10^{-7}$ .

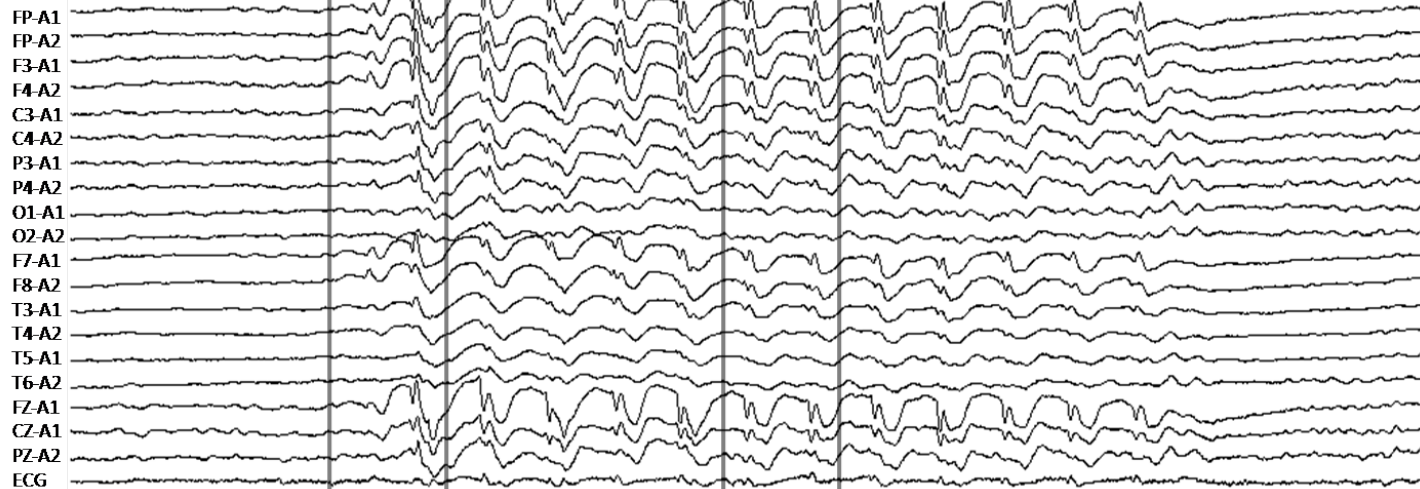
# Patient 1







**Patient 2**



early part of GSW

stereotyped GSW

0.3mV

1sec

