



Title	MEG time-frequency analyses for pre- and post-surgical evaluation of patients with epileptic rhythmic fast activity
Author(s)	Sueda, Keitaro; Takeuchi, Fumiya; Shiraiishi, Hideaki; Nakane, Shingo; Asahina, Naoko; Kohsaka, Shinobu; Nakama, Hideyuki; Otsuki, Taisuke; Sawamura, Yutaka; Saitoh, Shinji
Citation	Epilepsy Research, 88(2-3), 100-107 https://doi.org/10.1016/j.eplespsyres.2009.10.002
Issue Date	2010-02
Doc URL	http://hdl.handle.net/2115/42851
Type	article (author version)
File Information	ER88-2-3_100-107.pdf



[Instructions for use](#)

MEG time-frequency analyses for pre and post surgical evaluation of patients with epileptic rhythmic fast activity.

Keitaro Sueda⁽¹⁾, Fumiya Takeuchi⁽²⁾, Hideaki Shiraishi⁽¹⁾, Shingo Nakane⁽³⁾, Naoko Asahina⁽¹⁾, Shinobu Kohsaka⁽¹⁾, Hideyuki Nakama⁽⁴⁾, Taisuke Otsuki⁽⁴⁾, Yutaka Sawamura⁽⁵⁾, Shinji Saitoh⁽¹⁾

(1) Department of Pediatrics, Hokkaido University Graduate School of Medicine

(2) Department of Health Science, Hokkaido University School of Medicine,

(3) Division of Magnetoencephalography, Hokkaido University Hospital

(4) Department of Neurosurgery, Musashi Hospital, National Center of Neurology and Psychiatry

(5) Department of Neurosurgery, Hokkaido University Graduate School of Medicine

Corresponding author

Shinji Saitoh

Department of Pediatrics, Hokkaido University Graduate School of Medicine

North15 West 7, Kita-ku, Sapporo, 060-8638, Japan

TEL: +81-11-706-5954 FAX: +81-11-706-7898

ss11@med.hokudai.ac.jp

Keywords: magnetoencephalography; fast activity; Fourier transform; time-frequency analysis; symptomatic localization-related epilepsy; surgical evaluation

Number of test pages 22

Number of tables 0

Numbers of figures 3(color 3)

Abstract

Purpose: To evaluate the effectiveness of surgery for epilepsy, we analyzed rhythmic fast activity by magnetoencephalography (MEG) before and after surgery using time-frequency analysis. To assess reliability, the results obtained by presurgical MEG and intraoperative electrocorticography were compared.

Methods: Four children with symptomatic localization-related epilepsy caused by circumscribed cortical lesion were examined in the present study using 204 channel helmet-shaped MEG with a sampling rate of 600 Hz. One patient had dysembryoplastic neuroepithelial tumor (DNT) and three patients had focal cortical dysplasia (FCD). Aberrant areas were superimposed, to reconstruct 3-D MRI images, and illustrated as moving images.

Results: In three patients, short-time Fourier transform (STFT) analyses of MEG showed rhythmic activities just above the lesion with FCD and in the vicinity of DNT. In one patient with FCD in the medial temporal lobe, rhythmic activity appeared in the ipsilateral frontal lobe and temporal lateral aspect. These findings correlate well with the results obtained by intraoperative electrocorticography. After the surgery, three patients were relieved of their seizures, and the area of rhythmic MEG activity disappeared or become smaller. One patient had residual rhythmic MEG activity, and she suffered from seizure relapse.

Conclusion: Time-frequency analyses using STFT successfully depicted MEG rhythmic fast activity, and would provide valuable information for pre- and post-surgical evaluations to define surgical strategies for patients with epilepsy.

Introduction

Magnetoencephalography (MEG) is applied to localize the source of epileptiform discharges in patients with refractory epilepsy, particularly in symptomatic localization-related epilepsy, as it is noninvasive and exhibits excellent temporal and spatial resolution. MEG is a predictive tool for epileptic surgery. MEG localization of epileptiform discharges has been successfully achieved by single dipole modeling (SDM), which is mainly used to analyze interictal epileptiform spikes (Hämäläinen et al., 1993; Ebersole, 1997). However, the application of SDM appears to be limited to patients with localized spikes, since the algorithm is based on the presumption that the current epileptic discharge originates from a single spot.

Rhythmic EEG activities are often the hallmarks of underlying epileptogenesis. Rhythmic polyspike activities have been reported as indicative of an irritative epileptogenic zone in the electroencephalography (EEG) (Gambardella et al., 1996). A scalp EEG showed interictal focal paroxysmal beta activity in children with epilepsy caused by brain tumor, arteriovenous malformation, and cystic lesion (Hooshmand et al., 1980). In surveys of surgical outcomes, the locations of ictal rhythmic beta activities on scalp EEG and intracranial EEG have been correlated with the onset of seizures in patients with neocortical epilepsies (Talairach et al., 1992; Lee et al., 2000; Park et al., 2002; Worrell et al., 2002; Bonati et al., 2006). However, the resolution of EEG is not powerful enough to properly evaluate rhythmic activity because EEG activity is affected by the conductivity of brain structures (Hämäläinen et al., 1993), and in some cases EEG is unable to detect notable pathological activity (Iwasaki et al., 2005).

Recently, time-frequency analyses of EEG and MEG have been used to investigate rhythmic activities (Haykin et al., 1996; Grosse et al., 2002; Bosnyakova et al., 2006). Short-time Fourier transform (STFT) applies a short-time window to the signal and performs a series of Fourier transforms within this window as it slides across the recorded data (Oppenheim and Schaffer, 1999). This technique can be used to estimate the time-frequency components of the signal and visualize the spectral distributions. It has been proposed to apply this technique to patients with epilepsy (Kıymık et al., 2005), as it provides temporal changing information on the time-frequency domain.

Our current study was conducted to evaluate the effectiveness of surgery for epilepsy

using pre- and postoperative MEG to assess changes in epileptic rhythmic activity.

Patients and Methods

Patients

Four children with refractory symptomatic localization-related epilepsy induced by a circumscribed cortical lesion were enrolled in the present study. They underwent surgery between September 2005 and April 2008. Their guardians gave written informed consent for this study.

Methods

MEG

MEG data before and after surgery were recorded using a 204-channel, helmet-shaped neuromagnetometer (Neuromag Vectorview; Elekta-Neuromag Oy, Stockholm, Sweden) with pairs of orthogonal planar gradiometers at 102 locations. The recordings were carried out in a magnetically shielded room, with the patient in a supine position. The MEG data were collected for about 40 min for each patient at a sampling rate of 600 Hz. During the MEG examination, Patients 1, 2 and 4 received intravenous sodium thiopental for sedation, to avoid motion artifacts, while Patient 3 did not require sedation. A scalp EEG was recorded simultaneously using the international 10-20 system.

MEG data analysis

MEG data were filtered for offline analysis with a band pass of 3 to 100 Hz. The segments that contained abnormal paroxysms were selected manually. Single spikes were analyzed by SDM, to determine the distribution of brain activity generating the spike. Rhythmic fast activity discharges were analyzed by STFT, to determine the localization and value of each selected discharge.

SDM

The dipole-fit software (Neuromag, Helsinki, Finland) was used to calculate the equivalent current dipoles (ECDs). We defined acceptable ECDs as having goodness of fit (GOF) >70% and ECD strength of between 100 and 800 nAm. GOF is a measure of how well

the ECD model explains the measured signals. Acceptable ECDs were superimposed on the MRIs.

STFT analysis

STFT was used to reveal the distributions of MEG fast activity (Oppenheim and Schafer, 1999) and the MATLAB (MathWorks, Natick, MA, USA) program was used to execute the STFT for the MEG signals. Each signal was divided into small sequential frames, and fast Fourier transformation (FFT) was applied to each frame.

In the present study, the STFT was implemented using a 256-point window. The time of each window was 426.7 ms (i.e., $256 \text{ points} \times 1000 \text{ ms}/600 \text{ Hz}$). The window was shifted every four points, which corresponded to 6.7 ms (i.e., $1000 \text{ ms}/600 \text{ Hz} \times 4 \text{ points}$). FFT was applied to each window. This process was repeated for the whole signals that were selected. The time-frequency distributions are displayed as graphs (Figs. 1G, 2G, 3G and 4E).

A spectrum was considered to be aberrant when it was observed in the graph to be isolated from the background frequency spectrum. An aberrant frequency spectrum on the graph was superimposed onto the reconstructed 3D-MRI.

ECoG

The ECoG studies were performed during surgery. The ECoG data were collected using the Ceegraph system (Bio-Logic, Mundelein, IL, USA), with a sampling rate of 512 Hz. A 4×5 grid electrode array was used for Patients 1, and 4. A 4×8 grid electrode array was used for Patient 3. A four-channel strip electrode was used for Patient 2. Recording was performed for at least 1 min at each electrode location.

MRI

MRI was acquired with a 1.5 Tesla high-resolution MRI scanner (Magnetom VISION; Siemens AG, Erlangen, Germany) for both diagnostic purposes and co-registration with the MEG data. Axial T1-weighted images (WI), T2-WI, fluid-attenuated inversion recovery (FLAIR) images, and gadolinium-enhanced T1-WI were obtained.

Single-photon emission computed tomography (SPECT)

^{99m}Tc L-ethyl cysteinate dimer (^{99m}Tc-ECD)-SPECT was performed interictally and ictally for Patient 2, and interictally for Patient 3. We used a ring-type SPECT scanner (Headtome-SET070; Shimadzu Corp., Kyoto, Japan). The ^{99m}Tc-ECD was injected intravenously at a dose of 111 MBq into Patient 2 and at 600 MBq into Patient 3.

Positron emission tomography (PET)

¹⁸F-Fluorodeoxyglucose (FDG)-PET and ¹¹C-flumazenil (FMZ)-PET were performed for Patient 2 using the EXACT ECAT HR+ head scanner (Siemens). The injected doses of ¹⁸F-FDG and ¹¹C-FMZ were 185 MBq and 370 MBq, respectively.

Results

Case reports

Patient 1

A 17-month-old boy had daily seizures. At 1 month of age, he began to have daily seizures with loss of consciousness and tonic extension of bilateral upper limbs. His seizure was refractory to various antiepileptic drugs. Initially, his MRI finding was normal. At 16 months of age, a circumscribed lesion appeared on MRI with low intensity in the T1WI, high intensity in the T2WI, and FLAIR in right supra-marginal gyrus (Fig.1A). An interictal EEG revealed rare spikes at electrodes C4 and P4 and low-voltage 10-12-Hz fast activity at electrodes C3 and C4 (Fig.1B).

The 204ch MEG corresponding to the EEG fast activity showed rhythmic activities in the right central temporal areas (Fig. 2A). The ECDs were scattered over the cortical lesion(Fig. 1A, bottom panel). STFT analysis indicated a specific aberrant 15-18-Hz oscillation in the right central temporal areas (Fig. 2C). The specific oscillation at 15-18 Hz was generated at the FCD in the moving image (Fig. 3A).

The patient underwent craniotomy at 18 months of age. Intraoperative ECoG showed 18-19-Hz polyspike bursts at electrodes 9, 10, 12-15, 17, 18, and 19. These electrodes were located upon the resected cortical lesion (Fig. 1C, yellow bar). The frequencies of the MEG rhythmic activities (15-18 Hz) and ECoG polyspike (18-22 Hz) were comparable, and the locations of the MEG and ECoG oscillation almost overlapped. A total lesionectomy was performed.

The pathology was focal cortical dysplasia (FCD) with balloon cells (Palmini type 2B). The patient has remained seizure-free for 22 months and has developed steadily.

Patient 2

A 2-year-old girl had daily seizures. At age 10 months, she experienced an afebrile, generalized, tonic-clinic seizure. MRI showed a left-frontal cortical construction anomaly. At 15 months of age, she began to have seizures with extension of her right arm and leg, flexion of her

left arm and leg, and deviation of her head and eyes to the right. Although anti-epileptic drugs controlled the seizures, she was able to speak only a few words at 32 months of age.

T2WI and FLAIR MRI showed cortical thickening in the left frontal lobe, blurring of the gray-white matter junction and hyperintensity of the subcortical white matter. Interictal ^{99m}Tc -ECD-SPECT showed hypoperfusion in the left-frontal area and ictal ^{99m}Tc -ECD-SPECT revealed hyperperfusion in the left-frontal area. ^{18}F -FDG-PET showed hypometabolism in the left-frontal area, and ^{11}C -FMZ PET demonstrated decreased binding at the left-frontal area.

Interictal EEG demonstrated rhythmic, 13-14-Hz, low-voltage fast activity and a low number of sharp waves at electrodes Fp1, Fp2, F3, and F7. Ictal EEG showed desynchronization, followed by left frontal spikes and slow waves.

The 204ch MEG corresponding to the EEG fast activity showed rhythmic activities at the left frontal-temporal areas. The ECDs were not clustered due to the low number of isolated spikes with sufficient signal-to-noise ratio. STFT analysis indicated that a specific, aberrant, 15-20-Hz oscillation was generated at the left superior temporal gyrus and propagated to the middle and inferior frontal gyri in the moving image (Fig. 3B top panel).

The patient underwent the operation at 36 months. Intraoperative ECoG showed 13-25-Hz spikes and polyspikes at the orbito-frontal area.

The frequencies of the MEG oscillation (15-20 Hz) and ECoG polyspike (13-25 Hz) were comparable. ECoG polyspikes were located inside the area where the MEG oscillation was depicted by moving images.

Based on the FDG-PET findings, the patient underwent left-frontal lobe disconnection. The pathology was FCD with dysmorphic neuron and without balloon cells (Palmini type 2A). The patient had remained seizure-free for eight months and her development improved dramatically.

At age 44 months, eight months after operation, interictal EEG demonstrated spikes at electrodes Fp1, F3, F7 and fragment polyspikes at electrode F7. The MEG showed residual rhythmic activities at the left frontal-temporal area. STFT analysis of the moving image indicated that a specific, aberrant, 15-20-Hz oscillation was generated at the left superior temporal (Fig. 3B bottom panel). Subsequently, she had seizure relapse. The ECDs were clustered at the left pars opercularis. Additional resection of the left pars opercularis was

performed. The patient has since remained seizure-free for 8 months.

Patient 3

A 15-year-old girl had weekly, but sometimes daily, clusters of seizures. Her development was normal. At 6 years of age, she began to have weekly seizures with deviation of the eyes without loss of consciousness. At 10 years of age, she began to have the sensation of being in an elevator that was falling. Following the aura her head and eyes deviated to the right with loss of consciousness, and in some instances her seizure evolved into right-side clonic seizures. At 14 years of age, the first MRI showed a circumscribed mass of low intensity on T1WI and high intensity on T2WI in the left parietal-occipital region.

Interictal ^{99m}Tc -ECD SPECT showed hypoperfusion at the left parietal-occipital area, which corresponded with the lesion found on MRI. Interictal EEG revealed polyspikes with slow waves at electrodes F3, F4, F7, C3, and C4. The corresponding 204ch MEG showed rhythmic activities in the left frontal and central areas. The ECDs for these spikes were scattered in the anterior vicinity of the MRI lesion. STFT analysis indicated a specific aberrant 20-25 Hz oscillation in the left frontal and central areas. The specific oscillation at 20-25 Hz was generated in the vicinity of the lesion in the moving images (Fig. 3C).

She underwent craniotomy at 16 years of age. The intraoperative ECoG showed 18-25-Hz polyspike bursts at electrodes which were located at the anterior vicinity of the lesion. The frequencies of the MEG oscillation (20-25 Hz) and ECoG polyspike (18-25 Hz) almost corresponded. ECoG polyspikes were located inside the area where the MEG oscillation was depicted by moving images. A total lesionectomy was carried out; the tumor and the gyri involved by the tumor were resected simultaneously.

The tumor was diagnosed as dysembryoplastic neuroepithelial tumor (DNT). One month after the operation, her EEG and MEG showed no fast activity. The patient has been seizure-free for 24 months post-surgery and exhibited no neurological deficits.

Patient 4

A 9-year-old girl had daily seizures. Her seizures initially occurred at 1 month of age with complex partial seizure with motion arrest, loss of consciousness and cyanotic change. Her

seizures evolved to daily simple seizures, described as ictal fear and cephalic sensation, and complex partial seizures with motion arrest and autonomic change (cyanotic face) for 3 to 4 minutes without remarkable description of dystonic posturing. At 7 years of age, a circumscribed lesion appeared on the MRI in the T1WI at low intensity, in the T2WI and FLAIR at high intensity, in the left temporal para-hippocampal gyrus, uncus and hippocampus. At 8 years of age, an EEG performed just before her operation showed independent spikes at the right occipital and left frontal area, but these were not as intense in the left temporal area where the lesion existed. Furthermore, EEG and MEG showed intermittent, but prolonged, rhythmic activity at the left frontal and temporal area. STFT analysis of rhythmic MEG activity during the pre- and post-operative periods demonstrated widespread rhythmic activity in the ipsilateral frontal lobe and in the lateral aspect of the temporal lobe (Fig.3D left panel). This rhythmic activity disappeared after the operation and became localized to the left pre- and postcentral gyrus (Fig.3D right panel).

She underwent an operation at 8 years of age. The intraoperative ECoG showed continuous rhythmic spikes at approximately 20 Hz just before dysplasia resection at the lower area of the left pre- and postcentral gyrus and the supra marginal gyrus. This activity disappeared and became restricted to the left pre-frontal gyrus and supramarginal gyrus at lower amplitude. One month after surgery, STFT analysis indicated that the oscillation became more restricted and of lower power than in the preoperative MEG (Fig 3 E right panel).

Discussion

This study indicates that time-frequency analyses using STFT can reveal the distributions of rhythmic fast activity on MEG. This method is useful for presurgical and postsurgical evaluation. To improve outcomes from epileptic surgery, it is essential to define the precise location of the epileptogenic zone and the margin of surgical resection by the presurgical evaluation. For these purposes, MEG analysis is considered to be a suitable technique, as it offers good temporal and spatial resolution and noninvasive.

We used thiopental for three of the four patients. Thiopental produces fast activity in the beta range (12-30 Hz). However, these fast activities are bilaterally symmetric and developed in a frontal-central area, similar to those appearing during drowsiness (Feshchenko et al 1997, 2004). The fast activity in our study was generated unilaterally and not in a frontal-central area, thus the fast activity in our study was not attributed to thiopental.

Single-dipole modeling (SDM) has been used mainly to analyze the interictal epileptiform spikes on MEG. Oishi et al. (2006) reported that single clusters of ECDs indicated discrete epileptogenic zones that required complete resection for seizure-free outcome. In the present study, isolated interictal spikes were scarce in Patients 1 and 3, and the ECDs of Patients 1 and 3 were also scattered but not cluster. These ECDs were almost concordant with the high-power area of MEG fast activities, indicating that the SDM localizations were also useful for presurgical evaluation in these patients. In contrast, Patient 2 showed few ECDs, due to a scarcity of isolated spikes with sufficient signal-to-noise ratio. The ECDs in Patient 4 were clustered at two remote areas from epileptogenic area at left temporal lobe. These ECDs were discrete from the high-power area of MEG fast activities. ECDs might thereby reflect propagation from the source oscillation. The data obtained from the SDM were, therefore, insufficient for presurgical evaluation in our patients.

Ochi et al. (2007) used ECoG to investigate high frequency oscillation (HFO) at the epileptogenic focus and to assess the relationship between the outcome of surgery for epilepsy and the pattern of HFO. Their findings demonstrated the significant value of preoperative analysis of rhythmic activity. MEG provides higher temporal resolution than EEG and was thus able to show epileptiform discharges more clearly than EEG. For this reason, MEG has the

potential to more precisely analyze epileptic rhythmic discharges.

There were several advantages of the MEG findings for presurgical evaluation. In our study, epileptic rhythmic activity was demonstrated more clearly by MEG in all patients. Furthermore, the frequency of oscillation appeared faster by MEG than by EEG. For patients 1, 2, and 4, the EEG showed bilateral fast activity. For patient 3, EEG showed only a spike or polyspike and a slow wave complex that corresponded to the MEG fast activity. For patient 2, who was nonlesional on MRI, STFT analysis indicated the epileptic foci, and together with the FDG-PET findings, this information enabled us to plan the disconnection strategy for surgery. For patient 3, the data enabled us to place the intraoperative ECoG electrodes not only on the lesion, but also at the anterior vicinity of the lesion and source of the fast activity. Similarly, the STFT findings for patient 4, facilitated placing the ECoG electrodes. STFT analysis of fast activity is thus clearly beneficial for predicting the epileptic foci in patients with poor or several ECDs and for placing the ECoG electrodes.

Our study analyzed the changes in epileptic rhythmic activity before and after surgery for epilepsy and demonstrated the clinical value in predicting the outcome of surgery. For patient 3, the MEG polyspikes and spikes disappeared following surgery and the patient became seizure-free. For patient 2 and 4, especially, an aberrant rhythmic oscillation appeared in the remote area of the primary epileptic focus: FCD or DNT. For patient 4 this rhythmic activity disappeared after the operation. For patient 2, the MEG polyspikes persisted after surgery and her seizures relapsed. This remote rhythmic activity was defined as secondary epileptogenic focus. In some cases a supplementary operation, such as multiple sub-pial transection, is conducted to treat the secondary focus. Our operative strategy was lesionectomy and we planned further resection according to the seizure outcome and outcome of MEG after the operation. Postoperative MEG showing normal or notably improved aberrant rhythmic oscillation suggests a favorable outcome, whereas postsurgical residual MEG polyspikes may indicate a risk of seizure relapse. Our findings from MEG correlated with seizure outcome. Thus, MEG provides a useful postsurgical evaluation procedure to indicate the need for a secondary operation. In this way, MEG avoids redundant resection and is a safe and noninvasive procedure.

Concerning the correlation between the MEG and ECoG findings, the high-power area of MEG fast activity for patient 1 with FCD (shown in the red area of the 3-D movie; Fig

3A) and the area of ECoG polyspikes were consistent, with both oscillations colocalizing at the FCD. For patient 2 with FCD, the ECoG polyspikes were located within the high-power area of MEG fast activity (shown in the red area of the 3-D movie; Fig 3B). For patient 3 with DNT, the ECoG polyspikes were within the high-power area of MEG fast activity (shown in the red area of the 3-D movie; Fig 3C), and both areas were located near the tumor. For patient 4 with FCD, the high-power area of MEG fast activity (shown in the yellow area of the 3D-movie; Fig 3D left panel) was consistent with the area of ECoG polyspikes. Thus, the MEG fast activity locations demonstrated by STFT colocalized well with the ECoG polyspikes in patients, while MEG areas were rather wider. This could be due to the distance (several cm) between the cortical surface and the MEG sensors, the size of the planar gradiometer sensor, and the distance between sensors.

Guggisberg et al. (2008) showed the clinical value of MEG for the epileptic rhythmic activities in correlation with ECoG. Consistent with the results of previous studies, our findings suggest that STFT of MEG data can depict fast activity that indicate epileptogenic zones associated with FCD and DNT, which are the most significant etiologies of pediatric intractable symptomatic localization-related epilepsy. The excellent postsurgical outcomes achieved for our patients strongly support the predictive value of noninvasive MEG analysis. The rhythmic activities that are closely correlated to the ictogenesis in the cerebral cortex can be demonstrated stereoscopically by noninvasive MEG.

This STFT analysis is limited to patients who have aberrant frequency oscillation like fast activity in our study isolated from the background frequency spectrum. However, unlike ECD and other spatial filtering methods, STFT confers the following advantages. 1) STFT analyzed the original recorded magnetic field data directly. 2) Parameters do not need to be selected arbitrarily to make assumptions about current source and volume conductor, and thus to solve the inverse problem for source localization. 3) STFT indicates the temporal changes. 4) STFT can analyze oscillations that are generated simultaneously over a wide area and with low signal-to-noise ratio.

On the other hand, there were some limitations of this study. First, because the planar gradiometers evaluate the magnetic field just beneath the sensor, STFT could not reflect the depth of source. Second, because of the sensor size of planar gradiometer are $2.8\text{cm} \times 2.8\text{cm}$

and distance between sensor centers is 3.4cm, there might be a 1-2 cm errors between oscillation sources and projected position of sensor on 3D-MRI.

In conclusion, MEG can detect fast activity in symptomatic localized-related epilepsy more clearly and accurately than conventional EEG. STFT reveal the frequency and location of MEG fast activity that could not be analyzed by SDM. The MEG fast activity findings correlated well with the intraoperative ECoG findings and are therefore useful for presurgical evaluation. Ascertaining the presence of fast activity after epilepsy surgery could predict the prognosis of seizures. This noninvasive evaluation provides valuable information for pre- and post-surgical evaluations to define surgical strategies for patients with symptomatic localization-related epilepsy induced by circumscribed cortical lesions.

Acknowledgments

Acknowledgments

We thank Prof. Tadashi Ariga of the Department of Pediatrics, Hokkaido University Graduate School of Medicine, for his valuable editorial opinion. In addition, we thank Dr. Akiyoshi Kakita of the Brain Research Institute, Niigata University for pathology diagnoses. We confirm that we have read the Journal's position on issues involved in ethical publication and affirm that this report is consistent with those guidelines. This work was supported in part by Grants-in-aid for Scientific Research (18591136) from the Japan Society of the Promotion of Science, and the Japan Epilepsy Research Foundation

Disclosure of Conflicts of Interest

None of the authors has any conflict of interest to disclose.

REFERENCES

- Bonati, L.H., Naegelin, Y., Wieser, H.G., Fuhr, P., Ruegg, S., 2006. Beta activity in status epilepticus. *Epilepsia* 47, 207-210.
- Bosnyakova, D., Gabova, A., Kuznetsova, G., Obukhov, Y., Midzyanovskaya, I., Salonin, D., van Rijn C, Coenen, A., Tuomisto, L., van Luijelaar G. 2006. Time-frequency analysis of spike-wave discharges using a modified wavelet transform. *J Neurosci Methods* 154, 80-88.
- Ebersol, J.S., 1997. Magnetoencephalography/magnetic source imaging in the assessment of patients with epilepsy. *Epilepsia* 38(suppl.) 4, S1-5.
- Fernandes ,J.M., da Silva, A.M., Huiskamp, G., Velis, D.N., Manshanden, I., de Munck, J.C., da Silva, F.L., Cunha, J.P., 2005. What does an epileptiform spike look like in MEG? Comparison between coincident EEG and MEG spikes. *J Clin Neurophysiol.* 22, 68-73.
- Feshchenko, V.A., Veselis, R.A., Reinsel, R.A., 1997. Comparison of the EEG effects of midazolam, thiopental, and propofol: the role of underlying oscillatory systems. *Neuropsychobiology* 35, 211-20.
- Feshchenko, V.A., Veselis, R.A., Reinsel, R.A., 2004. Propofol-induced alpha rhythm. *Neuropsychobiology* 50, 257-266.
- Gambardella, A., Palmini, A., Andermann, F., Dubeau, F., Da Costa, J.C., Quesney, L.E., Andermann, E., Livier, A., 1996. Usefulness of focal rhythmic discharges on scalp EEG of patients with focal cortical dysplasia and intractable epilepsy. *Electroencephalogr Clin Neurophysiol.* 98, 243-249.

Grosse, P., Cassidy, M.J., Brown, P., 2002. EEG-EMG, MEG-EMG and EMG-EMG frequency analysis: physiological principles and clinical applications. *Clin. Neurophysiol.* 113, 1523–1531.

Guggisberg, A.G., Kirsch, H.E., Mantle, M.M., Barbaro, N.M., Nagarajan, S.S., 2008. Fast oscillations associated with interictal spikes localize the epileptogenic zone in patients with partial epilepsy. *Neuroimage* 39, 661–668.

Hämäläinen, M.S., Hari, R., Ilmoniemi, R., Knuutila, J., Lounasmaa, O.V., 1993. Magnetoencephalography: theory, instrumentation, and applications to noninvasive studies of the working human brain. *Rev. Modern Physics.* 65, 413–497.

Haykin, S., Racine, R.J., Xu, Y., Chapman, C.A. 1996. Monitoring neuronal oscillations and signal transmissions between cortical regions using time–frequency analysis of electroencephalographic activity. *Proc. IEEE* 84, 1295–1301.

Hooshmand, H., Morganroth, R., Corredor, C., 1980. Significance of focal and lateralized beta activity in the EEG. *Clin. Electroencephalogr.* 11, 140–144.

Iwasaki, M., Pestana, E., Burgess, R.C., Lüders, H.O., Shamoto, H., Nakasato, N., 2005. Detection of epileptiform activity by human interpreters: blinded comparison between electroencephalography and magnetoencephalography. *Epilepsia* 46, 59–68.

Kiyimik, M.K., Güler, I., Dizibüyük, A., Akin, M., 2005. Comparison of STFT and wavelet transform methods in determining epileptic seizure activity in EEG signals for real-time application. *Comput. Biol. Med.* 35, 603–616.

Lee, S.K., Kim, J.Y., Hong, K.S., Nam, H.W., Park, S.H., Chung, C.K., 2000. The clinical usefulness of ictal surface EEG in neocortical epilepsy. *Epilepsia* 41, 1450–1455.

Ochi, A., Otsubo, H., Donner, E.J., Elliott, I., Iwata, R., Funaki, T., Akizuki, Y., Akiyama, T.,

Imai, K., Rutka, J.T., Snead, O.C 3rd., 2007. Dynamic changes of ictal high-frequency oscillations in neocortical epilepsy: using multiple band frequency analysis. *Epilepsia* 48, 286-296.

Oishi, M., Kameyama, S., Masuda, H., Tohyama, J., Kanazawa, O., Sasagawa, M., Otsubo, H., 2006. Single and multiple clusters of magnetoencephalographic dipoles in neocortical epilepsy: Significance in characterizing the epileptogenic zone. *Epilepsia* 47, 355-364.

Oppenheim, A., Schaffer, R.W., 1999. *Discrete-Time Signal Processing*. Englewood Cliffs, Prentice Hall. New Jersey.

Park, S.A., Lim, S.R., Kim, G.S., Heo, K., Park, S.C., Chang, J.W., Chung, S.S., Choi, J.U., Kim, T.S., Lee, B.I., 2002. Ictal electrocorticographic findings related with surgical outcomes in nonlesional neocortical epilepsy. *Epilepsy Res.* 48, 199–206.

Santiuste, M., Nowak, R., Russi, A., Tarancon, T., Oliver, B., Ayats, E., Scheler, G., Graetz, G., 2008. Simultaneous magnetoencephalography and intracranial EEG registration: technical and clinical aspects. *J. Clin. Neurophysiol.* 25, 331-339.

Shiraishi, H., Watanabe, Y., Watanabe, M., Inoue, Y., Fujiwara, T., Yagi, K., 2001. Interictal and ictal magnetoencephalographic study in patients with medial frontal lobe epilepsy. *Epilepsia* 42, 875–882.

Talairach, J., Bancaud, J., Bonis, A., Szikla, G., Trottier, S., Vignal, J.P., Chauvel, P., Munari, C., Chodkiewicz, J.P., 1992. Surgical therapy for frontal epilepsies. *Adv. Neurol.* 57, 707–732.

Worrell, G.A., So, E.L., Kazemi, J., O'Brien, T.J., Mosewich, R.K., Cascino, G.D., Meyer, F.B., Marsh, W.R., 2002. Focal ictal beta discharge on scalp EEG predicts excellent outcome of frontal lobe epilepsy surgery. *Epilepsia* 43, 277–282.

Figure legends

FIG 1

(A) **Top panel:** FLAIR MRI showing FCD on right parietal-occipital area.

Bottom panel: ECDs located at the FCD (red dot).

(B) EEG at 1 year of age, just before the operation, demonstrating fast activity discharges at electrode C3, C4 interictally.

(C) ECoG during operation before resection of lesion indicates 18-22 Hz polyspike bursts at electrodes 9, 10, 12-15, 17, 18, and 19 (yellow bar). These electrodes are located on top of the FCD.

(D) FCD was exposed at the right supra-marginal gyrus during the operation.

(E) FCD was resected after the operation.

FIG 2

(A) 204ch MEG corresponding to interictal fast activity on the EEG (gray bar in FIG1(B)) demonstrates polyspikes at the right-central temporal area.

(B) One representative gradiometer (red circle in (A)) showing rhythmic activity.

(C) STFT graph showing specific rhythmic activities with 15-18 Hz oscillation at the right-central temporal area (red square).

(D) Enlarged section of red square in (C)

FIG3

(A) Specific oscillation at 15-18 Hz generated at the FCD in the superimposed 3-D MRI image of FIG.2C in patient 1.

(B) **Top panel:** Preoperative superimposed 3D MRI image in patient 2 showing specific oscillation generated at the superior temporal, middle-frontal gyrus, and inferior-frontal gyrus.

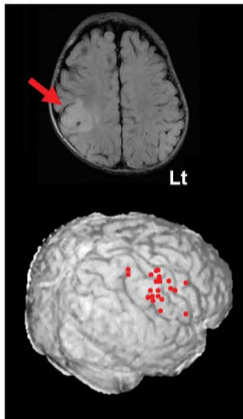
Bottom panel: Postoperative superimposed 3D MRI image in patient 2 showing specific oscillation generated at the superior temporal, middle-frontal gyrus, and inferior-frontal gyrus.

(C) Superimposed 3D MRI image in patient 3 showing specific oscillation generated in the vicinity of the DNT.

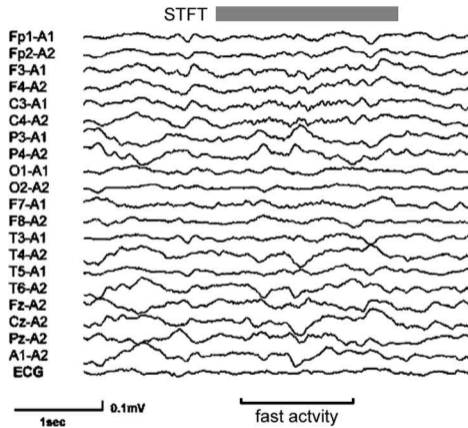
(D) Left panel: Preoperative superimposed 3D MRI image in patient 4 showing broad aberrant oscillation at the left lateral occipital lobe, at the inferior, middle, and superior temporal gyrus, at the angular gyrus, supra marginal gyrus and the inferior frontal gyrus (red and yellow area).

Right panel: Postoperative superimposed 3D MRI image in patient 4 showing broad aberrant oscillation at the left angular gyrus and at the inferior frontal gyrus (yellow area).

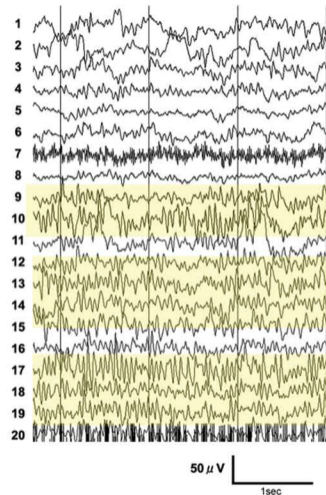
(A) MRI ; MEG-ECD



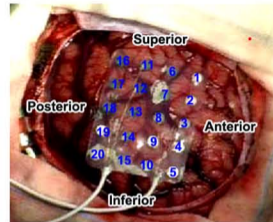
(B) EEG: 1y/o (pre-operation)



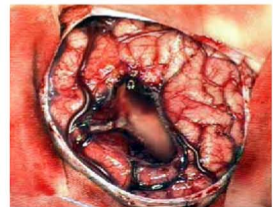
(C) ECoG: (pre-resection)



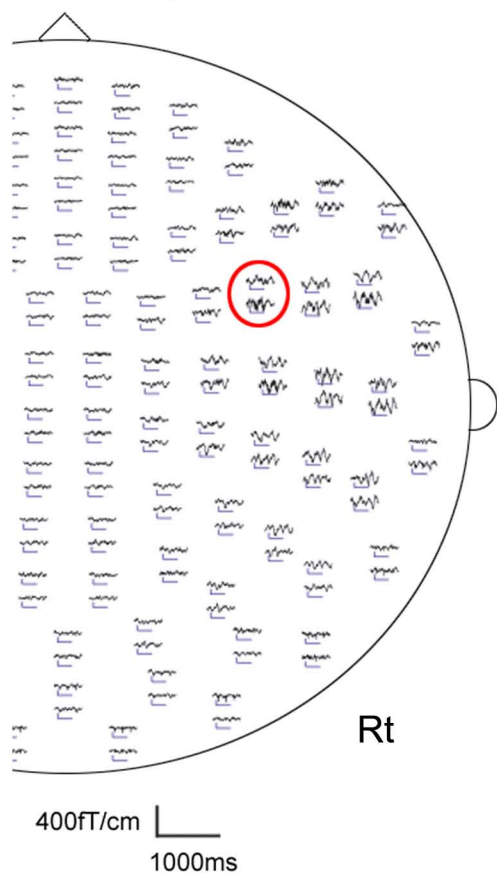(D) pre-resection



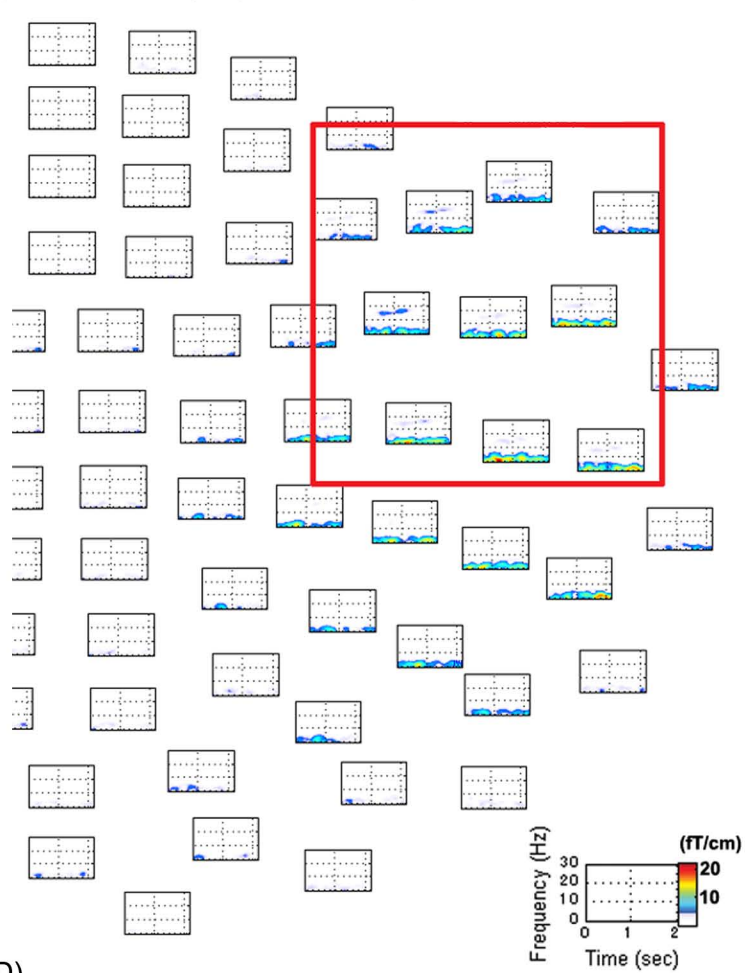
(E) post-resection



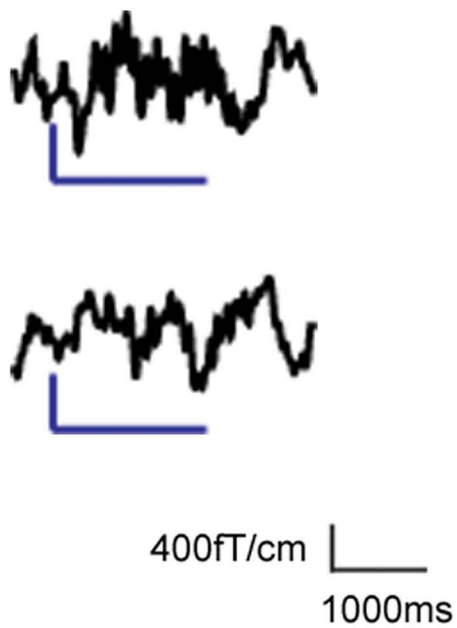
(A) MEG: 1y/o (pre-operation)



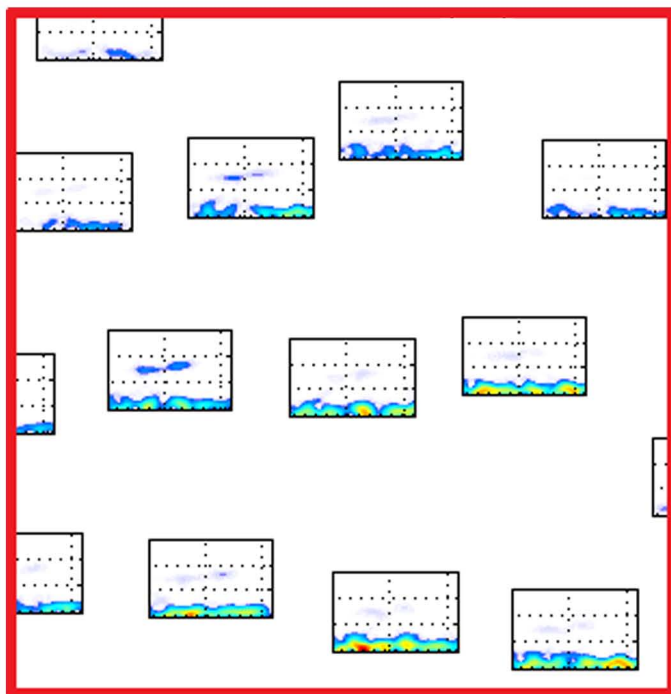
(C) MEG-STFT: 1y/o (pre-operation)




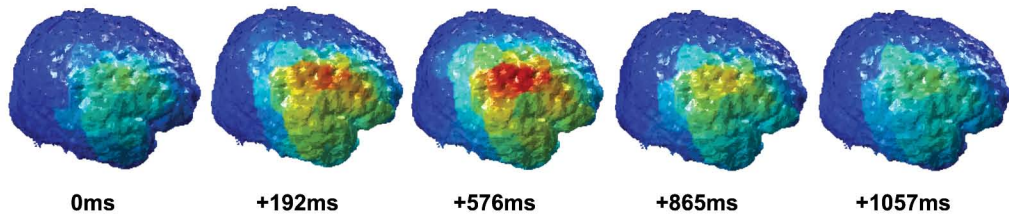
(B)



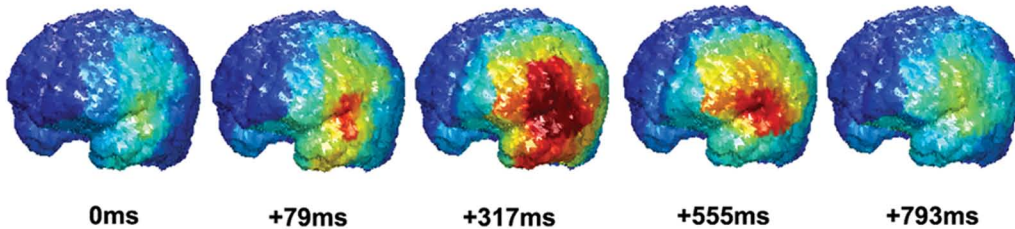
(D)



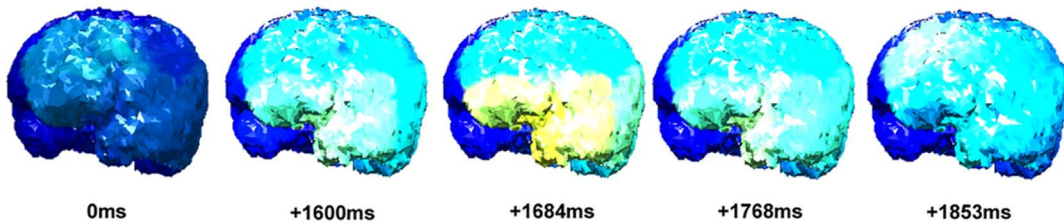
(A) Patient 1 3D-MRI overlay: 1y/o (pre-operation)



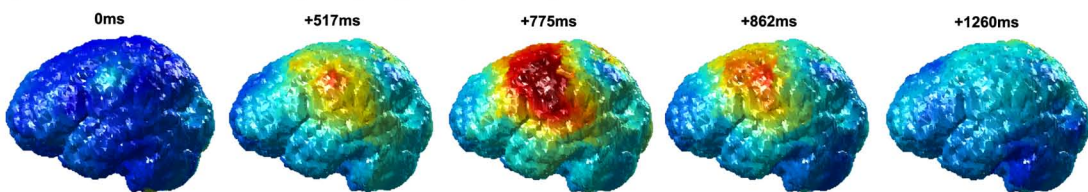
(B) Patient 2 3D-MRI overlay: 2y/o (pre-operation)




3D-MRI overlay: 3y/o (post-operation)



(C) Patient 3 3D-MRI overlay: 15y/o (pre-operation)



(D) Patient 4 3D-MRI overlay: 8y/o (pre-operation)



3D-MRI overlay: 9y/o (post-operation)

