



Title	Chemotherapy with Cisplatin and Vincristine for Optic Pathway/Hypothalamic Astrocytoma in Young Children
Author(s)	Sawamura, Yutaka; Kamoshima, Yuuta; Kato, Tsutomu; Tajima, Toshihiro; Tsubaki, Junko
Citation	Japanese Journal of Clinical Oncology, 39(5), 277-283 <a href="https://doi.org/10.1093/jjco/hyp012">https://doi.org/10.1093/jjco/hyp012</a>
Issue Date	2009-05
Doc URL	<a href="http://hdl.handle.net/2115/39669">http://hdl.handle.net/2115/39669</a>
Type	article (author version)
File Information	39-5_p277-283.pdf



[Instructions for use](#)

## Chemotherapy with Cisplatin and Vincristine for Optic Pathway/Hypothalamic Astrocytoma in Young Children

Yutaka Sawamura<sup>1</sup>, Yuuta Kamoshima<sup>1</sup>, Tsutomu Kato<sup>1</sup>, Toshihiro Tajima<sup>2</sup>, Junko Tsubaki<sup>2</sup>

Departments of <sup>1</sup>Neurosurgery and <sup>2</sup>Pediatrics, Hokkaido University Hospital,  
North-15, West-7, Kita-ku, Sapporo 060-8638, Japan

Address for corresponding author

Yutaka Sawamura, M.D., Ph.D.

Department of Neurosurgery, Hokkaido University Hospital,

North-15, West-7, Kita-ku, Sapporo 060-8638, Japan

Phone: +81 11 706-5987

Fax: +81 11 708-7737

E-mail: ysawamu@med.hokudai.ac.jp

Running head: CDDP/VCR for Chiasmatic/Hypothalamic Gliomas

**Abstract**

**Objective:** Optic pathway/hypothalamic astrocytomas in young children often show accelerated growth and require rather intensive induction chemotherapy.

**Methods:** Fifteen children (median age: 3 years) with a large optic pathway/hypothalamic astrocytoma were treated. All presented with progressive disease, and the tumor size was larger than 34 mm. Pilocytic astrocytoma was confirmed histologically in 10 patients. Eleven patients had visual disturbance, 6 had diencephalic syndrome, and 4 had hydrocephalus.

**Results:** The children received 6 to 8 cycles of cisplatin (20 mg/m<sup>2</sup>: days 1 to 5) and vincristine (1.4 mg/m<sup>2</sup>: days 1, 8, 15), every 4 weeks. Objective response was obtained in 11 patients (73%); 1 complete response, 8 partial responses, and 2 minor responses. Although the remaining 4 cases were evaluated as stable disease, all tumors decreased in volume. All children tolerated the chemotherapy well under careful audiological monitoring.

**Conclusion:** Although the present series was small, this chemotherapy is a useful regimen for induction therapy for children with an aggressive deep-seated pilocytic astrocytoma.

**Mini-Abstract**

Fifteen young children with large optic pathway/hypothalamic astrocytomas were treated with cisplatin and vincristine. Objective response was obtained in 11 patients (73%). This regimen is useful for induction therapy.

**Key words:** chemotherapy; cisplatin; hypothalamus; pilocytic astrocytoma; vincristine

## Introduction

Optic pathway glioma with contiguous involvement of the hypothalamus is a rare tumor that occurs in infants and young children, and most cases are pilocytic astrocytoma. This orphan tumor often shows aggressive growth in the deep brain and is one of the lethal brain tumors. Optic pathway gliomas involving the hypothalamus and/or other adjacent brain structures are associated with poorer survival than those localized in the optic nerve and chiasm [1-9]. It has also been reported that diagnosis at a very young age in children with chiasmatic/hypothalamic gliomas is a significant predictor of poor progression-free survival [4,5,9-14]. Although the behavior of the disease is unpredictable, especially in adolescents, young children with progressive optic pathway/hypothalamic astrocytoma (OPHA) require intensive treatment.

In young children with OPHA, radical surgical excision is often associated with visual, neurological, and endocrinological complications [8,15-17]. Hence, curative surgical resection is rarely achieved when the functional outcome is considered seriously. On the other hand, radiation therapy is effective in terms of tumor response, improvement of vision, and long-term tumor control rate. However, it is well known that the neurocognitive outcome after radiation therapy is significantly poorer in young patients, especially before school age [3,4,8,18-24]. In addition, radiotherapy may produce unacceptable long-term adverse effects, such as endocrinopathy, optic nerve injury, cerebrovascular complication, and secondary neoplasm [3,8,21,25].

Due to the adverse effects of other therapeutic modalities, chemotherapy has been recommended as a primary treatment for OPHA. Chemotherapy alone, however, is not consistently curative and is used to avoid or delay radiotherapy. Because of the rarity of this tumor, no randomized clinical study to evaluate chemotherapeutic regimen has been reported in the literature. However, carboplatin (CBDCA)-based regimens have been established by several investigators [2,4,5,12,13,21,26-36] and the reported objective primary response rates range from 4 to 60% [13,26,28,30,31,33]. There is a need to establish a more powerful chemotherapeutic regimen, particularly at the initiation of therapy in young children with rapidly progressive disease. Massimino *et al.* and Laithier *et al.* reported promising results using combination chemotherapy, including cisplatin (CDDP).

This report assessed the efficacy of another combination chemotherapy with CDDP and vincristine (VCR). The purpose of induction chemotherapy is to reduce the tumor volume of rapidly growing large OPHA and to improve progressive clinical symptoms in young children. Therefore, this study evaluated the primary response to CDDP/VCR chemotherapy as an induction therapy, but not long-term outcome.

## Patients and Methods

### *Patient Characteristics*

We retrospectively assessed a series of 15 patients who had a clinical diagnosis of sporadic OPHA from a review of clinical records since 1992, when high-resolution MRI became routinely available (Table 1). All children had an aggressive OPHA and progressive disease on neurological or neuroradiological examinations. The origin of the tumor, either chiasmatic or hypothalamic, was not always clearly defined due to the large size of the tumor and invasive nature, as shown in Figure 1 and 2.

Neurofibromatosis type 1 (NF-1) -associated gliomas, single optic nerve gliomas, small tumors obviously localized in the chiasm, unilateral hypothalamic gliomas, and quiescent cases in adolescents over 12 years of age were excluded because they have a different natural history and require different treatment strategies. At the time of final observation, no children showed clinical evidence of NF-1.

The median age at diagnosis and initial treatment was 2 years (range: 1 month to 8 years) and 3 years (range: 6 months to 11 years), respectively. At the initiation of CCDP/VCR chemotherapy none had previously undergone chemotherapy. Eleven patients had visual disturbance, 6 presented with diencephalic syndrome, and 4 had hydrocephalus. Histological diagnosis of pilocytic astrocytoma was verified in 10 patients by surgical biopsy and the remaining 5 patients were diagnosed by pathognomonic radiological appearance and typical clinical manifestations. On MRI, all cases had an appearance suggestive of pilocytic astrocytoma and were located in the midline with no remarkable laterality. As shown in Fig 2, two cases (Case No. 8 and 10) showed an infiltrative pattern in the whole optic pathway, including the bilateral optic nerves, chiasm, tracts, geniculate ganglions, internal capsules, optic radiations, and hypothalamus. The maximum diameters of 15 tumors, encompassing globular masses on gadolinium-enhanced T1-weighted image but excluding the part infiltrating the surrounding brain, ranged from 34 to 60 mm. No children presented with cerebrospinal fluid dissemination at diagnosis.

### *Treatment Protocol*

CDDP was administered as a 2-hour infusion at a dose of 20 mg/m<sup>2</sup>/day on days 1 to 5, and VCR was administered as an intravenous bolus injection at a dose of 1.4 mg/m<sup>2</sup>/day (maximum dose 2.0 mg/body/day) on days 1, 8, and 15. All patients received CDDP upon hospitalization. All patients received anti-emetic therapy using 5-HT<sub>3</sub> receptor antagonists from day 1 to day 5. CDDP was preceded and followed by hydration, including infusion of mannitol. In children younger than 2 years of age, doses were calculated according to weight (CDDP

0.7mg/kg/day and VCR 0.05mg/kg/day) and CDDP was administered as a 24-hour infusion. There was a 4-week interval between cycles. Treatment was completed in all 15 children. By 1996, 5 children had received 8 cycles of chemotherapy, and after 1997, the remaining 10 children were given 6 cycles. Informed consent forms were signed by each of patients' legal guardians prior to surgery and chemotherapy.

Because many children had severe visual loss, audiological monitoring was frequently performed before CDDP administration. Prior to each cycle of chemotherapy, hearing was monitored with pure-tone audiometry and, in young children, cochlear function was evaluated with distortion product otoacoustic emission. CDDP dosage was reduced to 15 mg/m<sup>2</sup>/day if hearing loss was greater than 40 dB in the 4000- to 8000-Hz range, and CDDP was replaced with CBDCA if there was greater than 20 dB hearing loss in the 50- to 2000-Hz range. VCR dosage was modified slightly in subsequent cycles for myelosuppression. The protocol was approved by the Ethics Committee of Hokkaido University Hospital and formal consent was obtained from the parents.

When a remarkable tumor volume remained at the completion of CDDP/VCR therapy, alternative subsequent therapy was allowed. To avoid ototoxicity by an increasing cumulative dose of CDDP, in 6 such patients, second-line chemotherapy using CBDCA/VCR followed CDDP/VCR chemotherapy. For patients with tumor relapse during the observation period, surgical resection, radiation therapy, and alternative chemotherapy were considered.

### *Evaluation of Response*

For all patients, MR imaging with gadolinium enhancement of the whole neuraxis was conducted prior to the initiation of therapy and MRI scans of the tumor site were repeated before each chemotherapy cycle. At least one MRI examination was performed each month during CDDP/VCR therapy to evaluate even a minimal change of tumor volume. Follow-up MRI and clinical assessments, including ophthalmological examination, were performed every 3 months for the first year after the completion of treatment and every 6 months, thereafter. In all children, endocrinological tests were performed regularly, even if a patient showed normal hormone secretion at onset. In the event of possible tumor progression, neurological, MRI, ophthalmological, and endocrinological reevaluations were performed.

Response to chemotherapy was assessed according to the International Society of Paediatric Oncology criteria [37] with minor modifications: complete response (CR) was defined as a complete disappearance of tumor on spinal MRI and thin-slice brain MRI, partial response (PR) required a reduction in solid tumor of more than 50% on MRI, and stable disease (SD) was

the absence of tumor progression. In addition, minor response (MR) was defined as tumor shrinkage of more than 25% but less than 50%, as the product of the maximum perpendicular diameter of the lesion with no evidence of a new lesion. The volume of the solid part of the tumor was calculated, taking into account enhanced T1-weighted MRI. To determine complete disappearance of tumor and to exclude any tiny, residual tumor, scarce and faint high-signal intensity lesion on FLAIR or 3D CISS images (three-dimensional constructive interference in steady state) were strictly measured on high-resolution thin-slice MRI.

## **Results**

### *Responses*

The median follow-up period was 63 months (range: 22 to 193 months) at the time of this report. The prescribed chemotherapy of 6 to 8 cycles had been completed in 14 children. A 1-year-old child showed a decrease in creatinine clearance after 4 cycles and mild high-tone hearing loss at 4000–8000kHz after 7 cycles; therefore, the eighth cycle was omitted for this patient.

Radiological response was evaluated just after the last cycle of the CDDP/VCR regimen (Table 1). None of the patients achieved a complete response. PR was reached in 4 patients and MR in 7 patients. Thus, eleven of the 15 patients (73%) showed an objective response (defined as CR, PR or MR). Although the remaining 4 cases were evaluated as SD, none suffered from disease progression during treatment and their tumors also decreased slightly in volume on MRI (Fig.2).

There was no difference in the response to the chemotherapy between the children with or without diencephalic syndrome. In all 6 children who presented with diencephalic syndrome, the symptoms, such as serious emaciation, were ameliorated during the chemotherapy. In all 11 children with visual disturbance, deterioration of visual loss was ceased or partially improved. As a result, there was no symptomatically and radiologically progressive disease during the CDDP/VCR chemotherapy.

As described above, the number of cycles was actually changed in 1997, because of the high-tone hearing loss (bilateral 40dB at 4000kHz) observed in one child, to shorten the hospitalization period, and preliminary but sufficient effects were observed at 6 cycles in the preceding cases. The 5 children who were treated with more than 6 cycles obtained 2 PR and 3 MR. This appeared to be better than the result of the patients treated with 6 cycles. The difference from the number of cycles was not clear due to the small number of samples and individual features of the tumors.

The tumors in 3 children showed continuous regression for several months, without

additional therapy after the completion of CDDP/VCR chemotherapy; thus, the best radiological response was CR in one patient, PR in 8 patients, MR in 2 patients, and SD in 4 patients. The primary response of the 2 cases that exhibited an infiltrative pattern to the whole optic pathway was evaluated as SD, according to the definition of the response to chemotherapy of measuring the perpendicular diameter. As shown in Figure 2, the bulky part of these tumors decreased remarkably in volume.

The progression-free survival could not be calculated in all patients after induction CDDP/VCR chemotherapy because 6 patients received contiguous chemotherapy using CBDCA and VCR after the induction therapy and another patient resulting in SD received temozolomide without relapse. The remaining 8 patients who achieved CR or PR were observed without additional therapy and the median progression free survival was 55 months (range 15 to 188 months). Among them, 2 patients exhibited no relapse during the follow-up period of 90 and 188 months, respectively. The remaining 6 patients exhibited relapse at the primary tumor site on surveillance MRI and the progression-free periods were 15, 26, 34, 55, 56, and 65 months, respectively, after induction CDDP/VCR therapy. All subsequently underwent salvage therapy.

### *Toxicity*

CDDP ototoxicity was serially monitored in all children during and after CDDP/VCR chemotherapy. CDDP dosage was reduced in 3 children due to decreased perception at 4000–8000kHz. Two children showed minimal monolateral loss and one boy retained mild, bilateral, high-tone hearing loss 10 years after chemotherapy (40dB at 4000kHz); the other children maintained normal hearing function. No patients required hearing aids. The hematological toxicity of CDDP/VCR chemotherapy was evaluated at the completion of this therapy. All patients developed CTC grade 2 or 3 neutropenia. Two red blood cell transfusions were necessary in seriously emaciated children and no platelet transfusions were required in 89 assessable cycles. Four patients who had CTC grade 4 neutropenia received granulocyte-colony stimulating factor at least once. One patient exhibited self-limiting renal insufficiency (transient CTC grade 1 level of glomerular filtration rate) due to CDDP. One child exhibited peripheral neuropathy with bilateral finger weakness (CTC grade 2) after 6 cycles, which resolved spontaneously. No child showed chronic abnormalities in peripheral blood examination. Six children who underwent thorough cognitive evaluation before starting CDDP/VCR treatment showed no cognitive impairment after chemotherapy. All children, except one who was blind at birth, retained functional vision in at least one eye.



## Discussion

Grade-II diffuse astrocytoma and grade-I pilocytic astrocytoma, categorized as low-grade gliomas, exhibit quite different prognoses; however, due to the difficulty of obtaining biopsy specimens from the brainstem, hypothalamus, and optic pathway, pilocytic astrocytomas occurring in the eloquent brain have been described as “low-grade glioma” in the literature. During the last decade, several authors have reported the effectiveness of various chemotherapies for “low-grade” optic nerve gliomas, optic pathway gliomas, chiasmatic gliomas, hypothalamic gliomas, diencephalic gliomas, chiasmatic/hypothalamic gliomas, and optic pathway/hypothalamic gliomas [2,4,5,12,13,21,26-36]. It is of note that, in these series, the vast majority of the reported cases appeared to be pilocytic astrocytoma [11,27]. In addition, most of the published series included NF-1-associated gliomas that may present with behavior that is different from sporadic cases [6,19,21]. To clearly evaluate the efficacy of chemotherapy for OPHA, it may be better to separately assess pilocytic astrocytomas, including not only histologically-verified cases, but also clinically-diagnosed typical cases occurring to this region.

It has been suggested that a platinum-containing regimen may be most effective for treating pilocytic astrocytoma [2]. Table 2 summarizes the published data indicating the response rates of chemotherapeutic regimens, including CDDP or CBDCA [5,12,13,26,28-31,33]. Packer *et al.* published landmark papers on the chemotherapeutic management of low-grade gliomas [33-35]. The authors established a regimen using concurrent CBDCA and VCR in a 10-week induction phase followed by maintenance therapy. Although their series included diffuse astrocytomas and NF-1 associated gliomas, it produced a progression-free survival of 75% and 68% at 2 and 3 years, respectively. Among 58 children with diencephalon gliomas, of which most were considered as pilocytic astrocytoma, 33 patients (57%) showed an objective response, including CR, PR, or MR; only 3 patients (5%) resulted in PD.

CBDCA has been utilized as a key drug in the platinum-based chemotherapeutic regimen [4,5,13,26-28,30-35]. A few studies have applied CDDP in a regimen for optic pathway/hypothalamic gliomas. Laithier *et al.* treated 85 progressive optic pathway tumors by administering multiagent chemotherapy for 16 months [5]. This first-line chemotherapy included alternating procarbazine plus CBDCA, etoposide plus CDDP, and VCR plus cyclophosphamide. Fifty-one children (60%) had significant tumor shrinkage (CR, PR, SD) and only 11 patients were not responsive to chemotherapy.

Massimino *et al.* reported the largest series using CDDP, in which they treated 34 children (median age: 45 months) with unresectable low-grade glioma with 10 monthly cycles of CDDP

(30mg/m<sup>2</sup>/day on days 1 to 3) and etoposide (150mg/m<sup>2</sup>/day on days 1 to 3) [12]. Twenty-nine of the 34 patients had chiasmatic/hypothalamic glioma. An objective response was obtained in 24 patients (71%) and the others had stable disease. Acute toxicity was unremarkable and 8 of 28 patients (28%) evaluated for acoustic neurotoxicity revealed a loss of perception of high frequencies. They concluded that combined CDDP and etoposide treatment is one of the most effective regimens for low-grade glioma in children and allows the avoidance of radiotherapy in the vast majority of patients.

In the present series, we used a similar CDDP dose per cycle and obtained a similar result (73% objective response). Although the ototoxicity (3 of 15 patients) in our series seems milder than that in Massimino's series (8 of 28 patients), this may be attributable to the different cumulative CDDP dosages. Concerning the primary response rate, as summarized in Table 2, regimens containing CDDP might be superior to those of CBDCA for the treatment of pilocytic astrocytomas. Several investigators have reviewed the literature and suggested that CDDP is superior to CBDCA in terms of therapeutic effectiveness in the treatment of all platinum-sensitive solid tumors, although CBDCA has a similar mechanism of action and preclinical spectrum of activity to CDDP [38,39].

Ototoxicity and nephrotoxicity limit the use of CDDP. Because serious visual disturbance is a major symptom of large OPHA, children with this disease, hearing loss significant cannot be compromised as an adverse effect of therapy. In addition, audiological monitoring in very young children is not easy. Serial intensive monitoring of cochlear function during CDDP chemotherapy may require hospitalization; however, the incidence and severity of ototoxicity reported by Massimino *et al.* and in our series may be acceptable [12]. Regarding the efficacy of CDDP, the authors believe that a chemotherapeutic regimen including CDDP, at least as induction chemotherapy, is worthwhile for young children with aggressive OPHA.

In addition to platinum-based chemotherapy, several authors have recently reported the efficacy of oral temozolomide in children with progressive optic pathway/hypothalamic low-grade gliomas [40-42]. Gururangan *et al.* treated 26 patients with recurrent or progressive optic pathway gliomas. In this series, 14 patients (54%) obtained disease stabilization and 4 patients achieved objective response (3 PR and 1 MR) [40]. Lafay-Cousin *et al.* treated 9 children with carboplatin allergic response using weekly vinblastine, and obtained 1 CR, 1 PR, 5 objective effects, and 2 SD [43]. These new agents with low toxicity seem attractive, however the response rates appeared relatively low. They might be useful for maintenance chemotherapy. Although, the toxicity of the CDDP/VCR regimen is higher than those of vinblastine or temozolomide, young children with aggressive OPHA require a chemotherapeutic regimen with high efficacy as first line treatment.

In our series, only 2 of the 15 children survived without any additional therapy after CDDP/VCR induction therapy. The remaining 13 patients required contiguous maintenance therapy or salvage therapy at relapse. However, it is obvious that eradication of OPHA is rarely obtained solely by induction chemotherapy. During their long clinical course over several years, various maintenance chemotherapy, salvage chemotherapy, salvage surgery, and even radiation therapy had to be considered. The role of induction chemotherapy may be to sufficiently control an aggressive tumor at disease onset and to improve progressive symptoms, including visual deterioration, but not to actually cure the disease.

### *Conclusion*

Combination chemotherapy using cisplatin and vincristine is an effective regimen, at least for induction therapy in young patients with progressive optic pathway/hypothalamic astrocytomas. However, this regimen alone was seldom curative.

### **Acknowledgements**

This study was supported in part by Clinical Cancer Research, Health and Labor Sciences Research Grants (H17-ganrinsyou-ippan-005) from the Ministry of Health, Labor and Welfare.

## References

1. Balcer LJ, Liu GT, Heller G, Bilaniuk L, Volpe NJ, Galetta SL et al. Visual loss in children with neurofibromatosis type 1 and optic pathway gliomas: relation to tumor location by magnetic resonance imaging. *Am J Ophthalmol* 2001;131:442-445
2. Brown MT, Friedman HS, Oakes WJ, Boyko OB, Hockenberger B, Schold SC Jr. Chemotherapy for pilocytic astrocytomas. *Cancer* 1993;71:3165-3172
3. Cappelli C, Grill J, Raquin M, Pierre-Kahn A, Lellouch-Tubiana A, Terrier-Lacombe M-J et al. Long-term follow up of 69 patients treated for optic pathway tumours before the chemotherapy era. *Arch Dis Child* 1998;79:334-338
4. Fouladi M, Wallace D, Langston JW, Mulhern R, Rose SR, Gajjar A et al. Survival and functional outcome of children with hypothalamic/chiasmatic tumors. *Cancer* 2003;97:1084–1092
5. Laithier V, Grill J, Le Deley MC, Ruchoux M-M, Couanet D, Doz F et al. Progression-free survival in children with optic pathway tumors: dependence on age and the quality of the response to chemotherapy--results of the first French prospective study for the French Society of Pediatric Oncology. *J Clin Oncol* 2003;21:4572-4578
6. Opocher E, Kremer LC, Da Dalt L, van de Wetering MD, Viscardi E, Caron HN et al. Prognostic factors for progression of childhood optic pathway glioma: a systematic review. *Eur J Cancer* 2006;42:1807-1816
7. Steinbok P, Hentschel S, Almqvist P, Cochrane DD, Poskitt K. Management of optic chiasmatic/hypothalamic astrocytomas in children. *Can J Neurol Sci* 2002;29:132-138
8. Sutton LN, Molloy PT, Sernyak H, Goldwein J, Phillips PL, Rorke LB et al. Long-term outcome of hypothalamic / chiasmatic astrocytomas in children treated with conservative surgery. *J Neurosurg* 1995;83:583-589
9. Tow SL, Chandela S, Miller NR. Long-term outcome in children with gliomas of the anterior visual pathway. *Pediatr Neurol* 2003;28:262-270
10. Chan MY, Foong AP, Heisey DM, Harkness W, Hayward R, Michalski A. Potential prognostic factors of relapse-free survival in childhood optic pathway glioma: a multivariate analysis. *Pediatr Neurosurg* 1998;29:23-28
11. Komotar RJ, Burger PC, Carson BS, Brem H, Olivi A, Goldthwaite PT et al. Pilocytic and pilomyxoid hypothalamic/chiasmatic astrocytomas. *Neurosurgery* 2004;54:72–79
12. Massimino M, Spreafico F, Cefalo G, Riccardi R, Tesoro-Tess JD, Gandola L et al. High response rate to cisplatin/etoposide regimen in childhood low-grade glioma. *J Clin Oncol* 2002;20:4209–4216

13. Silva MM, Goldman S, Keating G, Marymont MA, JKalapurakal J, Tomita T. Optic pathway hypothalamic gliomas in children under three years of age: the role of chemotherapy. *Pediatr Neurosurg* 2000;33:151-158
14. Tihan T, Fisher PG, Kepner JL, Godfraind C, McComb RD, Goldthwaite PT et al. Pediatric astrocytomas with monomorphous pilomyxoid features and a less favorable outcome. *J Neuropathol Exp Neurol* 1999;58:1061–1068
15. Hoffman HJ, Humphreys RP, Drake JM, Rutka JT, Becker LE, Jenkin D et al. Optic pathway/hypothalamic gliomas: a dilemma in management. *Pediatr Neurosurg* 1993;19:186-195
16. Sawamura Y, Kamada K, Kamoshima Y, Yamaguchi S, Tajima T, Tsubaki J et al. Role of surgery for optic pathway / hypothalamic astrocytomas in children. *Neuro Oncol* 2008;10:725-733
17. Wisoff JH, Abbott R, Epstein F; Surgical management of exophytic chiasmatic-hypothalamic tumors of childhood. *J Neurosurg* 1990;73:661-667
18. Erkal HS, Serin M, Cakmak A. Management of optic pathway and chiasmatic-hypothalamic gliomas in children with radiation therapy. *Radiother Oncol* 1997;45:11-15
19. Grill J, Laithier V, Rodriguez D Raquin MA, Pierre-Kahn A, Kalifa C. When do children with optic pathway tumours need treatment? An oncological perspective in 106 patients treated in a single centre. *Eur J Pediatr* 2000;159:692–696
20. Fisher BJ, Bauman GS, Leighton CE, Stitt L, Cairncross JG, Macdonald DR. Low-grade gliomas in children: tumor volume response to radiation. *J Neurosurg* 1998;88:969-974
21. Janss AJ, Grundy R, Cnaan A, Savino PJ, Packer RJ, Zackai EH, et al. Optic pathway and hypothalamic/chiasmatic gliomas in children younger than age 5 years with a 6-Year follow-up. *Cancer* 1995;75,1051-1059
22. Lacaze E, Kieffer V, Streri A, Lorenzi C, Gentaz Ez, Habrand J-L, et al. Neuropsychological outcome in children with optic pathway tumours when first-line treatment is chemotherapy. *Br J Cancer* 2003;89:2038-2044
23. Marcus KJ, Goumnerova L, Billett AL, Lavally B, Scott RM, Bishop K, et al. Stereotactic radiotherapy for localized low-grade gliomas in children: final results of a prospective trial. *Int J Radiat Oncol Biol Phys* 2005;61:374-379
24. Tao ML, Barnes PD, Billett AL, Leong T, Shrieve D, Scott R, et al. Childhood optic chiasm gliomas: radiographic response following radiotherapy and long-term clinical outcome. *Int J Radiat Oncol Biol Phys* 1997;39:579-587
25. Packer RJ, Savino PJ, Bilaniuk LT, Zimmerman RA, Schatz NJ, Rosenstock JG, et al.

- Chiasmatic gliomas of childhood. A reappraisal of natural history and effectiveness of cranial irradiation. *Childs Brain* 1983;10:393-403
26. Aquino VM, Fort DW, Kamen BA. Carboplatin for the treatment of children with newly diagnosed optic chiasm gliomas: a phase II study. *J Neurooncol* 1999;41:255-259
  27. Gnekow AK, Kortmann RD, Pietsch T, Emser A. Low grade chiasmatic-hypothalamic glioma-carboplatin and vincristine chemotherapy effectively defers radiotherapy within a comprehensive treatment strategy -- report from the multicenter treatment study for children and adolescents with a low grade glioma -- HIT-LGG 1996 -- of the Society of Pediatric Oncology and Hematology (GPOH). *Klin Pediatr* 2004;216:331-342
  28. Gururangan S, Cavazos CM, Ashley D, Herndon JE, Bruggers CS, Moghrabi A, et al. Phase II study of Carboplatin in children with progressive low-grade gliomas. *J Clin Oncol* 2002;20:2951–2958
  29. Kato T, Sawamura Y, Tada M, Ikeda J, Ishii N, Abe H. Cisplatin / vincristine chemotherapy for hypothalamic/visual pathway astrocytomas in young children. *J Neuro-Oncol* 1998;37:263-270
  30. Mahoney DH Jr, Cohen ME, Friedman HS, Kepner JL, Gemer L, Langston JW, et al. Carboplatin is effective therapy for young children with progressive optic pathway tumors: a Pediatric Oncology Group phase II study. *Neuro-Oncol* 2000;2:213-220
  31. Mitchell AE, Elder JE, Mackey DA, Waters KD, Ashley DM. Visual improvement despite radiologically stable disease after treatment with carboplatin in children with progressive low-grade optic/thalamic gliomas. *J Pediatr Hematol Oncol* 2001;23: 572-577
  32. Moghrabi A, Friedman HS, Burger PC, Tien R, Oakes WJ, Carboplatin treatment of progressive optic pathway gliomas to delay radiotherapy. *J Neurosurg* 1993;79:223-227
  33. Packer RJ, Ater J, Allen J, Phillips P, Geyer R, Nicholson HS, et al. Carboplatin and vincristine chemotherapy for children with newly diagnosed progressive low-grade gliomas. *J Neurosurg* 1997;86:747–754
  34. Packer RJ, Lange B, Ater J, Nicholson HS, Allen J, Walker R, et al. Carboplatin and vincristine for recurrent and newly diagnosed low-grade gliomas of childhood. *J Clin Oncol* 1993;11:850-856
  35. Packer RJ, Sutton LN, Bilaniuk LT, Radcliffe J, Rosenstock JG, Siegel KR, et al. Treatment of chiasmatic/hypothalamic gliomas of childhood with chemotherapy: an update. *Ann Neurol* 1988;23:79-85
  36. Prados MD, Edwards MSB, Rabbitt J, Lamborn K, Davis RL, Levin VA. Treatment of pediatric low-grade gliomas with a nitrosourea-based multiagent chemotherapy regimen. *J*

- Neurooncol 1997;32: 235–241
37. Gnekow AC. Recommendations of the Brain Tumor Subcommittee for the reporting of trials: SIOP Brain Tumor Subcommittee-International Society of Pediatric Oncology. *Med Pediatr Oncol* 1995;24:104-108
  38. Go RS, Adjei AA. Review of the comparative pharmacology and clinical activity of cisplatin and carboplatin. *J Clin Oncol* 1999;17:409-422
  39. Lokich J, Anderson N. Carboplatin versus cisplatin in solid tumors: an analysis of the literature. *Ann Oncol* 1998;9:13-21
  40. Gururangan S, Fisher MJ, Allen JC, Herndon JE, Quinn JA, Reardon DA, et al. Temozolomide in children with progressive low-grade glioma. *Neuro-Oncol* 2007;9:161-168
  41. Kuo DJ, Weiner HL, Wisoff J, Miller DC, Knopp EA, Finlay JL. Temozolomide is active in childhood, progressive, unresectable, low-grade gliomas. 2003;*J Pediatr Hematol Oncol* 25:372-378
  42. Quinn JA, Reardon DA, Friedman AH, Rich JN, Sampson JH, Provenzale JM, et al. Phase II trial of temozolomide in patients with progressive low-grade glioma. *J Clin Oncol* 2003;21:646-651
  43. Lafay-Cousin L, Holm S, Qaddoumi I, Nicolin G, Ute Bartels U, Tabori U, et al. Weekly vinblastine in pediatric low-grade glioma patients with carboplatin allergic reaction. *Cancer* 2005;103:2636-2642

Case No	Age at diagnosis	Biopsy	Age at CDDP/VCR	Cycles of CDDP/VCR	Primary response at completion of CDDP/VCR	Best radiological response before salvage
1	1 month	yes	6 months	8	MR	PR
2	5 months	yes	9 months	6	PR	PR
3	1 year	no	1 year	6	MR	PR
4	1 year	yes	1 year	6	MR	MR
5	1 year	no	1 year	8	MR	PR
6	1 year	yes	1 year	7	PR	PR
7	2 years	yes	2 years	6	PR	PR
8	2 years	no	3 years	6	SD	SD
9	3 years	yes	3 years	8	MR	CR
10	3 years	no	4 years	6	SD	SD
11	3 years	yes	4 years	6	SD	SD
12	4 years	yes	5 years	8	PR	PR
13	3 years	no	5 years	6	MR	MR
14	5 years	no	6 years	6	SD	SD
15	8 years	yes	11 years	6	MR	PR

**Table 1**

Summary of 15 children treated with cisplatin/vincristine chemotherapy.

CR: complete response, MR: minor response, PR: partial response, SD: stable disease

Author year	Cases	Agents	DS	objective response CR+PR+MR	PD
Packer 1997	58	CBDCA + VCR	55/58 (95%)	33/58 (57%)	3/58 (5%)
Aquino 1999	12	CBDCA	10/12 (83%)	4/12 (33%)	2/12 (17%)
Mahoney 2000	50	CBDCA	37/50 (74%)	2/50 (4%)	11/50 (22%)
Silva 2000	12	CBDCA or CBDCA+VCR	11/14 (79%)	8/14 (57%)	3/14 (21%)
Mitchell 2001	12	CBDCA	10/12 (83%)	1/12 (8%)	2/12 (17%)
Gururangan 2002	80	CBDCA	69/80 (86%)	23/80 (28%)	11/80 (14%)

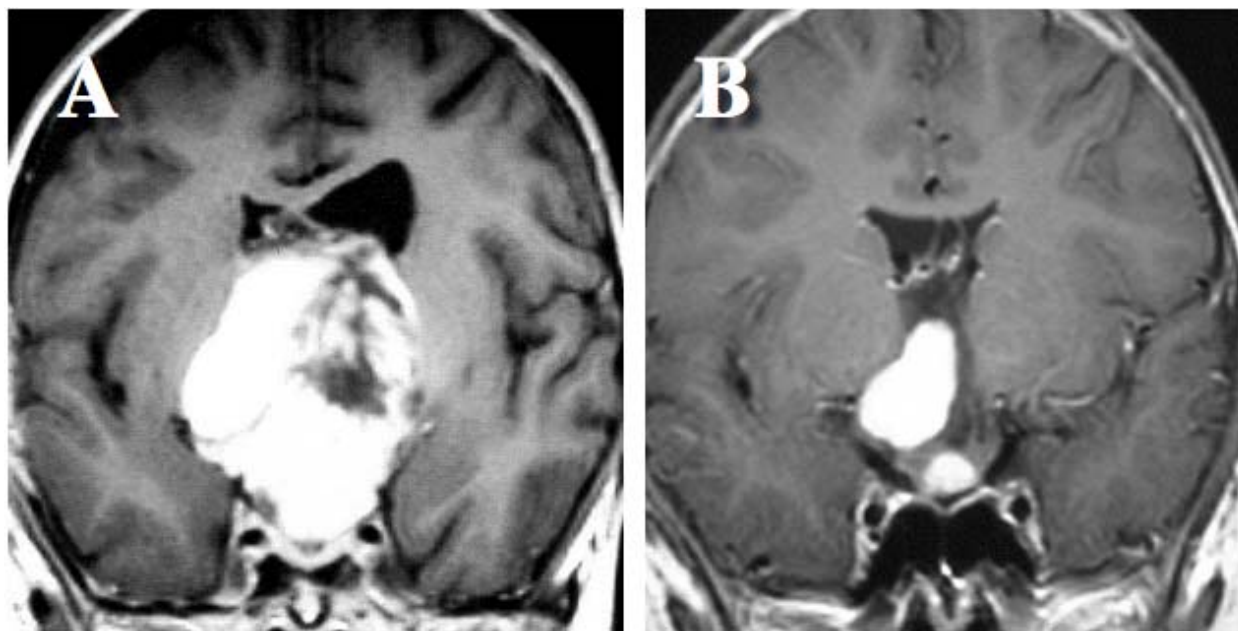


Massimino 2002	34	CDDP+etoposide	34/34 (100%)	24/34 (71%)	0/34 (0%)
Laithier 2003	85	procarbazine+CBDCA, etoposide+CDDP, VCR+cyclophosphamide	74/85(87%)	51/85(60%)	11/85(13%)
present study	15	CDDP+VCR	15/15 (100%)	11/15 (73%)	0/15 (0%)

**Table 2**

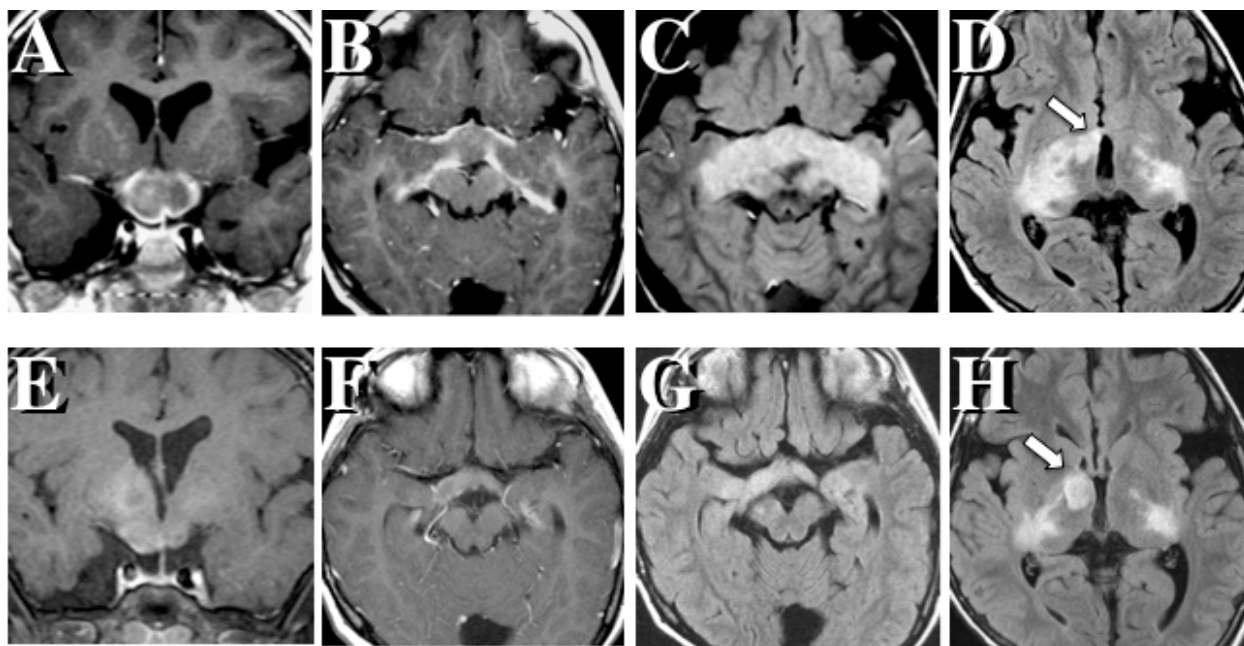
Summary of reported results of platinum-based chemotherapy

MR: minor response, PR: partial response, DS: disease stabilization, PD: progressive disease, CBDCA: carboplatin, VCR: vincristine, CDDP: cisplatin

**Figure 1 legend**

A 5-year-old boy (Case Number 12 in Table 1) presented with consciousness disturbance.

Contrast-enhanced T1-weighted image shows a large chiasmatic-hypothalamic mass causing obstructive hydrocephalus (A). He underwent biopsy and ventricle-peritoneal shunt. After 5 cycles of CDDP/VCR chemotherapy, this pilocytic astrocytoma rapidly and remarkably regressed in size (evaluated as a partial response) and his symptoms were ameliorated (B).



**Figure 2 legend**

This 4-year-old boy (Case Number 10 in Table 1) presented with a 3-year history of slowly progressive visual loss. MRI (A, B, C, D) had a tumor involving the entire optic pathway, including the bilateral intraorbital and intracranial optic nerves, chiasm, tracts, geniculate ganglions, internal capsules, and optic radiations. Tumor infiltration to the hypothalamus and thalamus was also evident. Surgical biopsy was not performed due to the tumor location. Although the tumor remarkably decreased in volume after 6 cycles of CDDP/VCR (E, F, G, H), this case was evaluated as stable disease (SD) according to the definition of response to chemotherapy. Only a part in the right anterior thalamus (arrow) slightly increased in size and later showed cystic change. (A, B, E, F: gadolinium-enhanced T1 images; C, D, G, H: FLAIR images)