



Title	Chemical Shift MR Images of Parotid Gland in Sjogren's Syndrome Utilizing Low Field MR System : Comparison with MR Sialography and Salivary Secretion Function
Author(s)	Kamishima, Tamotsu
Citation	北海道大学. 博士(医学) 甲第7173号
Issue Date	2005-03-25
DOI	10.14943/doctoral.k7173
Doc URL	http://hdl.handle.net/2115/32662
Type	theses (doctoral)
File Information	7173.pdf



[Instructions for use](#)

学位論文

**Chemical Shift MR Images of Parotid Gland in Sjogren's Syndrome Utilizing Low Field MR System
Comparison with MR Sialography and Salivary Secretion Function**

低磁場装置を用いたシェーグレン症候群の化学シフトMR画像
—MRシアログラフィー・唾液分泌能との比較—

北海道大学

神島 保

Abstract:

Purpose: To compare the chemical shift imaging and MR sialography in patients with Sjogren's syndrome utilizing low (0.3T) magnetic field.

Methods: We evaluated 8 controls (16 glands) and 30 patients (60 glands) with parotitis of Sjogren's syndrome in the retrospective manner. MR images were obtained at 0.3T system (HITACHI MRP-7000) with use of a coil for temporomandibular joint. MR sialography was graded according to the grading system established for the conventional sialography. The signal decrease rate between in and opposed phase image, and standard deviation (S.D.) of the parotid parenchymal signal in opposed phase images were measured.

Result: MR sialography and chemical shift images were obtained in 38 and 46 glands respectively. MR sialography was graded as 0 in 15, 1 in 12, 2 in 4, and 3 in 5 glands. Mean signal decrease rate in in/opposed phase was 37.6%, and mean S.D. of the parotid parenchymal signal in the opposed phase image was 655.9. The salivary secretion function was related to heterogeneity on opposed phase ($r=-0.3$) but not to the MR sialography grading.

Conclusion: Heterogeneity on opposed phase image assessable in the low field magnet system may be a useful parameter to add in the evaluation of the Sjogren's parotitis.

Key Words: Sjogren's syndrome, Chemical shift imaging, MR sialography

Introduction

Sjogren's syndrome (SS), also known as 'autoimmune exocrinopathy' [1] or 'autoimmune epithelitis' [2], is a chronic inflammatory disease that primarily affects females, characterized clinically by dry eyes (kerato-conjunctivitis sicca) and dry mouth (xerostomia) and histologically by lymphocytic infiltration and destruction of the salivary and lacrimal glands [3]. Criteria are in the process of being validated for keratoconjunctivitis sicca [4], but the definition of xerostomia remains to be established. Several methods have been proposed for the evaluation of this latter component of SS, such as measurement of unstimulated salivary flow [5,6], sialochemistry [7], sequential salivary scintigraphy [8], sialography using liposoluble [9] or hydrosoluble contrast media [10], magnetic resonance imaging (MRI) [11] and minor salivary gland biopsy [12].

MR sialography and conventional MR images of high field MR system has become an alternative imaging technique for the evaluation of parotitis in SS [13], however the diagnostic value of the low field MR system has not been fully evaluated. We compared the chemical shift imaging and MR sialography in patients with SS.

Materials and Methods

The study group consisted of 30 consecutive female patients aged 29-75 years (mean 54 years) attending the Rheumatology Center, Sapporo Yamanoue Hospital, diagnosed as SS according to the American Rheumatism Association criteria: 1) objective evidence of keratoconjunctivis sicca, as documented by rose bengal or fluorescein dye staining; 2) objective evidence of diminished salivary gland flow; 3) minor salivary gland biopsy, obtained through normal mucosa, with the specimen containing at least 4 evaluable salivary gland lobules, and having an average of at least 2 foci/4 mm²; 4) evidence of a systemic autoimmune process, as manifested by the presence of autoantibodies, such as rheumatoid factor and/or antinuclear antibody. The diagnosis of SS was made when 3 criteria was present [14]. The mean duration of subjective xerostomia in the SS patients was 7.6 years (range 6 months to 11 years). Subjects who had been treated during the last 12 months with either immunosuppressive agents or drugs known to reduce salivary secretion were excluded. The control group was constituted of 8 healthy female controls (mean 53 years, range 30 to 78 years). Both patients and controls gave informed consent to participate in the study, which was performed according to the criteria of the Helsinki Declaration and approved by the institutional review board for human research.

MR images were obtained in 0.3T system (HITACHI MRP-7000) with use of a coil for temporo-mandibular joint. MR parameters were TR/TE 9990/255 for 3D MR sialography, TR/TE 760/40 for in-phase, and TR/TE 760/11 msec for opposed phase imaging. FOV was 24 cm for all studies. Chemical shift images were obtained in the dual echo technique (Figure 1). MR sialography (Figure 2) was graded according to the grading system established for the conventional sialography [15], where grade 0 is normal, grade 1 is

punctuate, grade 2 is globular, and grade 3 is cavitory lesions observed in the parotid gland, by experienced investigators in accordance with their interpretation without knowledge of the other imaging findings and the results of Saxon test at the time of image interpretation. The signal decrease rate calculated from in- and opposed phase images and standard deviation (S.D.) of the parotid parenchymal signal in opposed phase images were measured on chemical shift imaging. Here signal decrease rate was defined as area signal intensity on in-phase minus area signal intensity on opposed-phase divided by area signal intensity on in-phase.

Signal decrease rate and S.D. of the area signal intensity was calculated on the workstation (skyimage-su, OLIMPUS). Here the boundary of the parotid glands was manually traced once by author for each in- and opposed phase image. Compensative adjustment for the signal decay due to the use of the surface coil was not performed. When Saxon test was performed, four sterilized gazes were weighted inside a plastic container and again weighted after 2 min of patient mastication without swallowing. Weight variation was taken as a measure of salivary flow with a lower normal value of 2 gram [16].

Statistical Analysis

Comparison of signal decrease rate calculated with in/opposed phase between normal subjects and patients, signal decrease rate between patients with MR sialography grade 0 vs. grade 1-3, and signal decrease rate between patients with preserved and decreased salivary flow (less than 2 g), S.D. of the area signal intensity of the gland on opposed phase between normal subjects and patients, S.D. of the area signal intensity between patients with MR sialography grade 0 vs. grade 1-3, S.D. of the area signal intensity between patients with preserved and decreased salivary flow (less than 2 g), and salivary flow between patients with MR sialography grade 0 vs. grade 1-3 were performed using Cochran-Cox test. When salivary flow is concerned, data from the right parotid gland was utilized as a representative. The level of statistical significance was established at 5% for all tests. Correlation coefficient of signal decrease rate/S.D. of the area signal intensity and salivary secretion function was analyzed and r –value was measured

Results

For normal subjects, chemical shift images were obtained in 16 glands. Mean signal decrease rate calculated from in/opposed phase images was 15.0%, and mean S.D. the parotid parenchymal signal in the opposed phase image was 359.1. For patients, MR sialography and chemical shift images was obtained in 38 and 46 glands respectively. Failure rate was 5% (2 of 38) for MR sialography and 0% (0 of 46) for chemical shift imaging. MR sialography was graded as 0 in 15, 1 in 12, 2 in 4, and 3 in 5 glands. Mean signal decrease rate calculated from in/opposed phase was 37.6%, and mean S.D. the parotid parenchymal signal in the opposed phase image was 655.9. The relationship among signal decrease rate, S.D. of the

area signal intensity of the gland on opposed phase, MR sialography grade, and salivary secretion function is shown on figure 3 and 4.

Discussion

Diagnosis of SS is made clinically based on the sicca syndrome and the connective tissue disorder (for example, rheumatoid arthritis) combined with serology of antinuclear antibodies. For those cases in which the diagnosis is in question, some would favor performing a lip biopsy of the minor salivary gland tissue over sialography [12]. Ultrasonography or sialography, be it MR or conventional, is used primarily to stage disease. Here, high field (1.5 Tesla) magnet MR sialography is reported to be useful with high spatial resolution for staging purpose in patients suspect of SS [13].

Low field system, primarily used for evaluation of musculoskeletal physiology and pathology [17], is more accessible and has advantages of not being affected by the interference of the artifact derived from dentures and other metallic materials situated in the head and neck area. Because of the limited spatial resolution in imaging parotid duct, it is not suitable for the evaluation of the parotid duct abnormalities in patients with SS. Also the resolution of conventional T1- and T2-weighted images is not high enough to depict minimal abnormalities especially in early stage of the disease. On the other hand, there is a study to suggest that MR imaging analysis of premature fat deposition may be useful to evaluate the parotitis in patients with SS [18]. We speculated that chemical shift images on low field magnet be useful in evaluating the premature fat deposition in SS patients, as chemical shift MR imaging techniques, which are based on the difference in resonance frequency of water ($-OH$) and fat ($-CH_2-$) protons, can conclusively demonstrate fatty content. And the result was favorable. There was relationship between loss of salivary secretion function and fat deposition reflected as signal decrease rate, which was observed in comparison between normal subjects and patients (Figure 3a). Also irregularity of the distribution of the fat deposition assessed as the value of S.D. of the signal on out of phase image was different between normal subjects and patients (Figure 3d). Furthermore there was relationship between S.D. of the signal on out of phase image and decreased salivary flow (Figure 3f). This was not applied to the relationship between signal decrease rate and salivary flow (Figure 3c). In the observation of this result, fat deposition is possible indicator of disease process and irregularly distributed fat deposition are related to impaired salivary secretion function, namely the progression of the disease in Sjogren's parotitis. MR sialography grading and salivary secretion function had no relationship each other (Figure 3g). The reason may be explained by the fact that the MR sialography grading was not accurate enough, possibly because of the limited image quality.

Limitation to this study is that conventional sialography was not performed in most of the patients. However, in the working up for the confirmation of the diagnosis of SS, conventional sialography was not selected as first line examination because it is not only invasive but also time-consuming and only one gland is tested at a time. Exposure to radiation is another disadvantage. Furthermore, it is not mandatory for diagnosis

according to the American Rheumatism Association criteria [14]. Although chemical shift MR imaging is sensitive technique to detect fat deposition, estimation of the amount of the fat is difficult because the signal drop on opposed phase images relative to in phase image depends proportional relationship between proton bound to water and fat. Therefore in case fat is dominant in the gland, signal drop is not observed. So when we see heterogeneous signal on opposed phase MR images, we can assume protons bound to fat or water are globally, not diffusely distributed in the gland. CT was not performed for the purpose of measuring the amount of fat deposition. We considered that measuring the amount of fat deposition in the gland at the cost of radiation exposure is not justified because it has little clinical impact.

Bilateral signal heterogeneity observed on opposed phase MR images caused by fat deposition in the parotid gland may not be specific to Sjogren's parotitis. In salivary glands affected by other disorders, immature fat deposition is likely to occur. For example, sialosis refers to a bilateral, painless enlargement of the salivary glands that may be caused by systemic disorders such as diabetes mellitus, alcoholism, hypothyroidism, and malnutrition [19]. Some medications may provoke sialosis (including some antibiotics, diuretics, and psychotropic medications).

So far, low field magnet has not been applied to evaluate the changes in the major salivary glands of SS patients in any literature as far as we know, and also there is no study where chemical shift imaging is utilized to assess the immature fat deposition of the parotid gland. We consider signal heterogeneity on opposed phase MR images may be nonspecific, but may indicate the existence of salivary gland abnormality and related to degraded salivary secretion function, therefore useful in assessing the extent of damage especially after the diagnosis of SS is established.

In conclusion, low field MR sialography may reflect ductal abnormality, but not an adequate grading tool with insufficient spatial resolution. Chemical shift imaging in the low field magnet is a quick, non-invasive technique for studying the fat deposition of the salivary glands in patients with SS.

MR imaging finding of SS is bilateral, global heterogeneous signal on opposed phase images, however further studies including MR investigation of parotitis affected by other disorders are needed to obtain more conclusive information.

Acknowledgement

I'll appreciate Dr. Akira Sagawa at the Center for Rheumatism and connective tissue disease, Sapporo Yamanoue Hospital for the valuable advices.

References

1. Strand V, Talal N. Advances in the diagnosis and concept of Sjogren's syndrome (autoimmune exocrinopathy). *Bull Rheum Dis* 1980; 30:1046 -52.
2. Moutsopoulos HM. Sjogren's syndrome: autoimmune epithelitis. *Clin Immunol Immunopathol* 1994; 72:162 -5.
3. Moutsopoulos HM, Chused TM, Mann DL et al. Sjogren's syndrome (sicca syndrome): current issues. *Ann Intern Med* 1980; 92:212 -26.
4. Vitali C, Bombardieri S. Diagnostic criteria for Sjogren's syndrome: the state of the art. *Clin Exp Rheumatol* 1990; 8 (suppl 5): 13 -6.
5. Mason DK, Harden RM, Boyle JA, Jasani MK, Williamson J, Buchanan WW. Salivary flow rates and iodine uptake trapping capacity in patients with Sjogren's syndrome. *Ann Rheum Dis* 1967; 26:311 -15.
6. Speight PM, Kaul A, Melsom RD. Measurement of whole unstimulated salivary flow in the diagnosis of Sjogren's syndrome. *Ann Rheum Dis* 1992; 51:499 -502.
7. Jezequel N, Depasse F, Jouquan J et al. Salivary lactoferrin in primary Sjogren's syndrome. *Clin Exp Rheumatol* 1989; 7:123 -5.
8. Schall GL, Anderson LG, Wolf RO et al. Xerostomia in Sjogren's syndrome: evaluation by sequential salivary scintigraphy. *JAMA* 1971; 216:2109 -16.
9. Miyachi K, Naito M, Maeno Y et al. Sialographic study in patients with and without antibodies to Sjogren's syndrome A (Ro). *J Rheumatol* 1983;10:387 -94.
10. Vitali C, Tavoni A, Simi U et al. Parotid sialography and minor salivary gland biopsy in the diagnosis of Sjogren's syndrome: a comparative study of 84 patients. *J Rheumatol* 1988; 15:262 -7.
11. Valesini G, Gualdi GF, Priori R et al. Magnetic resonance imaging of the parotid glands and lip biopsy in the evaluation of xerostomia in Sjogren's syndrome. *Scand J Rheumatol* 1994; 23:103 -6.
12. Whitcher JP, Daniels TE, Sherman MD. Correlation of labial salivary gland biopsies with ocular and oral findings in patients with Sjogren's syndrome. *Adv Exp Med Biol* 1994; 350:667 -70.
13. Ohbayashi N, Yamada I, Yoshino N, Sasaki T. Sjogren's syndrome: comparison of assessments with MR sialography and conventional sialography. *Radiology*. 1998 Dec; 209 (3): 683-8.
14. Fox RI, Robinson CA, Curd JG, Kozin F, Howell FV. Sjogren's syndrome. Proposed criteria for classification. *Arthritis Rheum*. 1986 May;29(5):577-85.
15. Rubin P, Holt J F. Secretory sialography in disease of the major salivary glands. *Am. J. Roentgenol.*, 77:575, 1957
16. Kohler PF, Winter ME. A quantitative test for xerostomia. The Saxon test, an oral equivalent of the Schirmer test. *Arthritis Rheum*. 1985 Oct; 28(10):1128-32.
17. Kersting-Sommerhoff B, Hof N, Lenz M, Gerhardt P. MRI of peripheral joints with a low-field dedicated system: a reliable and cost-effective alternative to high-field units? *Eur Radiol*. 1996; 6(4):561-5.
18. Izumi M, Eguchi K, Nakamura H, Nagataki S, Nakamura T. Premature fat deposition in the salivary

glands associated with Sjogren's syndrome: MR and CT evidence. *AJNR Am J Neuroradiol.* 1997 May; 18(5):951-8.

19. Yousem DM, Kraut MA, Chalian AA. Major salivary gland imaging. *Radiology.* 2000 Jul; 216(1):19-29.

Tables and Figures

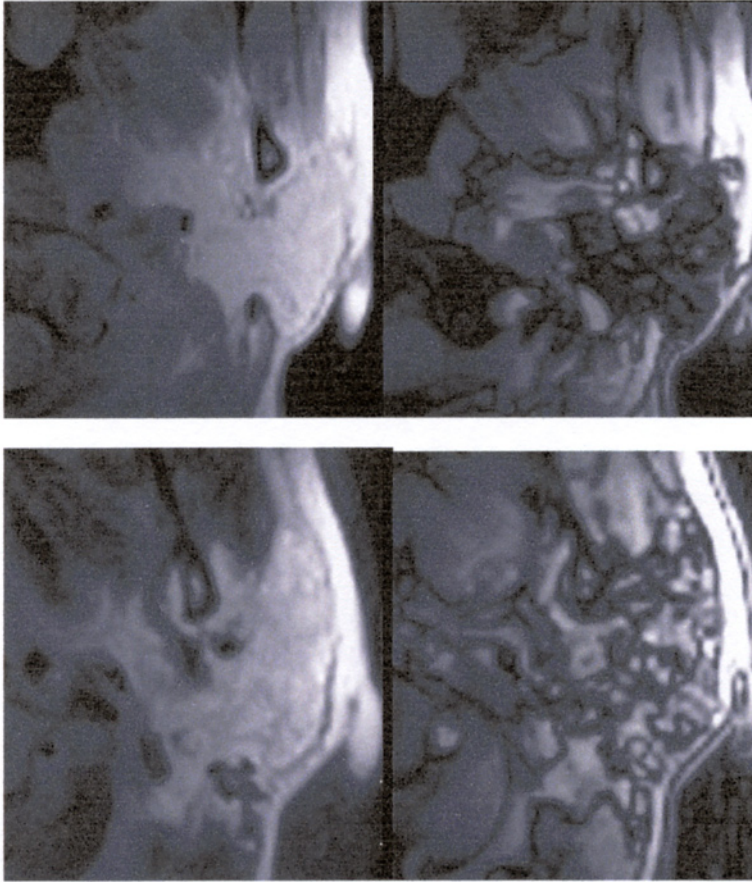


Figure 1a

Figure 1b

Figure 1c

Figure 1d

Figure 1a, b

Dual echo chemical shift MR images ((a) in-phase image; TR / TE / FA = 760 / 40 / 25, (b) opposed phase image; TR/TE/FA = 760 / 11 / 25)) of the left parotid gland of 40 year old normal volunteer woman.

Parenchymal signal intensity is homogenous on in-phase and on opposed phase, signal decrease ratio was 28.0% and standard deviation of the area signal intensity was 389.

Figure 1c, d

Dual echo chemical shift MR images ((c) in-phase image; TR / TE / FA = 760 / 40 / 25, (d) opposed phase image; TR / TE / FA = 760 / 11 / 25)) of the left parotid gland of 50 year old woman suffering from Sjogren's parotitis. Parenchymal signal intensity is homogenous on in-phase and heterogeneous on opposed phase),

signal decrease rate was 37.2% and standard deviation of the area signal intensity was 678.

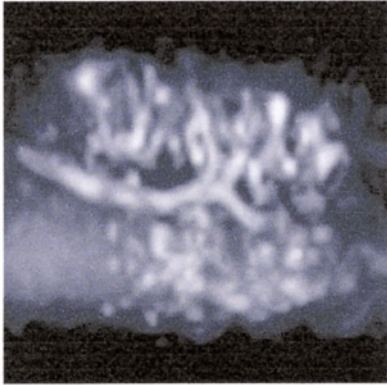


Figure 2

MR sialography (TR / TE = 9990/255) of the grade 2 parotitis in 50 year old woman. Cysts sized 1 to 5 mm are seen in the left parotid gland.

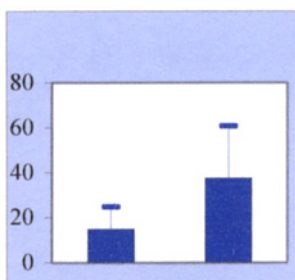


Figure 3(a) Relationship of signal decrease rate on chemical shift images between normal subjects (left column, n=16) and patients (right column, n=33). Signal decrease rate is significantly higher in patients than in normal subjects ($p < 0.001$).

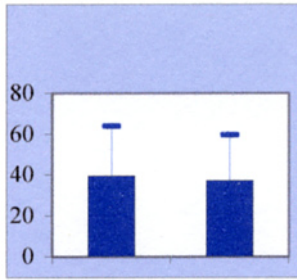


Figure 3(b) Relationship of signal decrease rate on chemical shift images between grade 0 (left column, n=15) and grade 1-3 (right column, n=18) on MR sialography. There is no statistical difference.

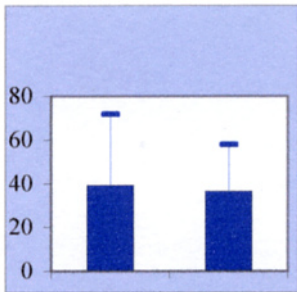


Figure 3(c) Relationship of signal decrease rate on chemical shift images between preserved (left column, n=6) and abnormal (right column, n=16) salivary secretion function with a cutoff value of 2g at Saxon test. There is no statistical difference.

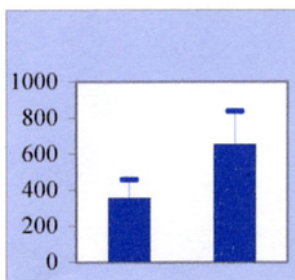


Figure 3(d) Relationship of standard deviation of the area signal intensity between normal subjects (left column, n=16) and patients (right column, n=33). Signal decrease rate is significantly higher in patients than in normal subjects ($p < 0.001$).

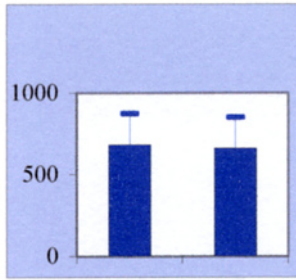


Figure 3(e) Relationship of standard deviation of the area signal intensity between grade 0 (left column, n=15) and grade 1-3 (right column, n=18) on MR sialography. There is no statistical difference.

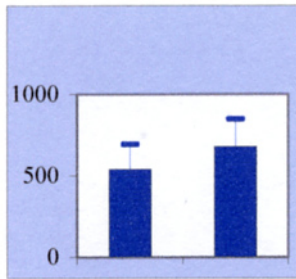


Figure 3(f) Relationship of standard deviation of the area signal intensity between preserved (left column, n=6) and abnormal (right column, n=16) salivary secretion function with a cutoff value of 2g at Saxon test. Standard deviation is statistically higher in parotid glands with abnormal salivary secretion function than those with preserved function ($p < 0.05$).

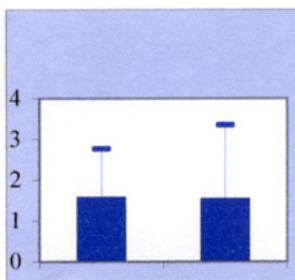


Figure 3(g) Relationship of salivary flow between grade 0 (left column, n=6) and grade 1-3 (right column, n=11) on MR sialography. There is no statistical difference.

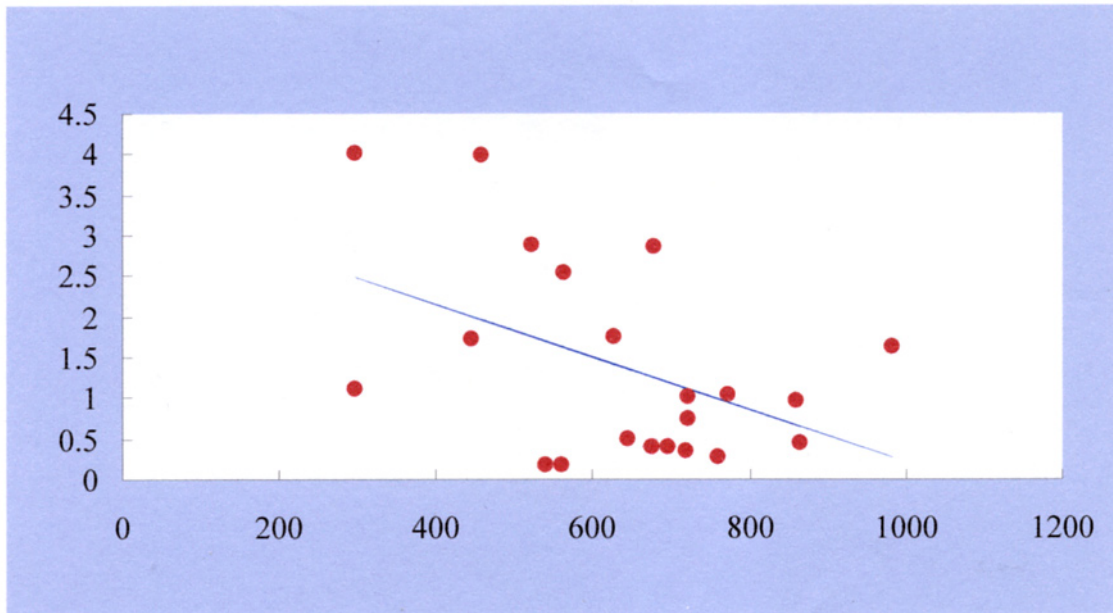


Figure 4a Relationship between standard deviation of the area signal intensity and salivary secretion function (Saxon test).

X-axis is standard deviation of the area signal intensity of the right gland on opposed phase image (n=23), and Y-axis is salivary flow (gram). There was a weak relationship ($r=-0.3$, $p<0.05$) between them. This result may show that the irregularity of the fat deposition is related to the damage to the salivary secretion function, namely the progress of the disease.

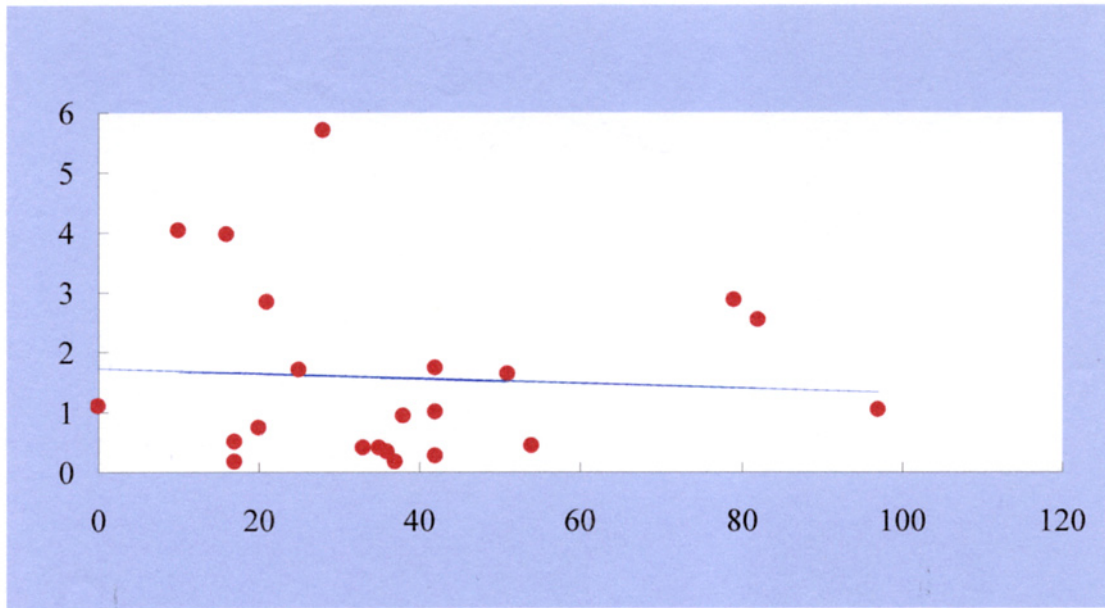


Figure 4b Relationship between signal decrease rate on chemical shift images and salivary secretion function (Saxon test).

X-axis is signal decrease rate of the right parotid gland on chemical shift images (n=22), and Y-axis is salivary flow (gram). There was no relationship between them.