



Title	Amicrobial pustulosis associated with IgA nephropathy and Sjögren's syndrome
Author(s)	Natsuga, Ken; Sawamura, Daisuke; Homma, Erina; Nomura, Toshifumi; Abe, Masataka; Muramatsu, Ryuichi; Mochizuki, Toshio; Koike, Takao; Shimizu, Hiroshi
Citation	Journal of the American Academy of Dermatology, 57(3), 523-526 https://doi.org/10.1016/j.jaad.2007.05.023
Issue Date	2007-09
Doc URL	http://hdl.handle.net/2115/30143
Type	article (author version)
File Information	JAAD57-3.pdf



[Instructions for use](#)

Journal of the American Academy of Dermatology

CASE REPORTS

Amicrobial pustulosis associated with IgA nephropathy and Sjogren's syndrome

**Ken Natsuga, MD ^{a*}, Daisuke Sawamura, MD, PhD ^a, Erina Homma, MD ^a,
Toshifumi Nomura, MD ^a, Masataka Abe, MD, PhD ^a, Ryuichi Muramatsu, MD ^b,
Toshio Mochizuki, MD, PhD ^c, Takao Koike, MD, PhD ^c, and Hiroshi Shimizu,
MD, PhD ^a**

**From the Department of Dermatology^a and Department of Medicine II^c, Hokkaido
University Graduate School of Medicine, Sapporo, Japan; and Division of
Dermatology, Iwamizawa Municipal General Hospital, Iwamizawa, Japan^b**

*Correspondence and reprint requests to:

Ken Natsuga, M.D.

Department of Dermatology,

Hokkaido University Graduate School of Medicine,

N15, W7, Sapporo 060-8638, Japan

Telephone: +81-11-716-1161 ext. 5962

Fax: +81-11-706-7820

e-mail: natsuga@med.hokudai.ac.jp

Funding Sources: None

Conflict of Interest Disclosure: None declared

809 words, 2 tables, 2 figures, and 11 references

SUMMARY

Amicrobial pustulosis is a rare clinical entity characterized by a relapsing pustular eruption involving mainly the skin folds. We describe a case of amicrobial pustulosis associated with autoimmune diseases (APAD). The patient suffered from IgA nephropathy and Sjogren's syndrome. Skin symptoms improved dramatically after corticosteroid pulse therapy and tonsillectomy.

Amicrobial pustulosis associated with autoimmune diseases (APAD) is an extremely rare cutaneous manifestation of systemic autoimmune conditions. This disease was first recognized as an entity in 1991 by Crickx et al.¹ and since then only less than twenty cases have been described to date in the English literature.²⁻⁸ Although the definite diagnostic criteria have not been fully established, almost all the reported APAD cases showed similar characteristics; no pathogenic microorganisms isolated, ineffective antibiotic therapeutics, and underlying autoimmune diseases. Here we report a case of APAD associated with IgA nephropathy and Sjogren's syndrome.

CASE REPORT

A 31-year-old man was referred to our dermatology clinic complaining of multiple pustules over his entire body. He noticed an itchy eruption first on his thighs two years ago, and pustular lesions occurred on his whole body six months ago. He visited a local hospital three months ago because of worsening of the symptoms. Systemic corticosteroids (prednisone, 0.5mg/kg/day, PO) ameliorated his condition in two weeks, although a month of oral minocycline 100mg daily with topical clindamycin phosphate and nadifloxacin was ineffective. After tapering systemic corticosteroids, his skin symptoms recurred.

His past medical history was unremarkable. He has not taken any drugs that could have caused his eruption. His family had no health problems.

On physical examination, he presented with multiple pustules measuring up to 5 mm in diameter on his scalp, auricles, axillae, and thighs (Fig 1). Skin specimens of a pustule from his thigh showed diffuse infiltration of neutrophils extending from the epidermis

into the papillary dermis (Fig 2). The infiltration of eosinophils was not observed. The epidermis revealed spongiform abscess. On direct immunofluorescence, there was no deposition of IgG, IgA, IgM, and complements. Bacterial cultures from the pustules detected no microorganisms, except in one sample a small number of *Staphylococcus aureus* were detected from a swab culture implying a secondary colonization. No fungal organisms were detected. Topical nadifloxacin 1% cream was ineffective. Partial clinical improvement was observed after a four week application of clobetasol propionate 0.05% ointment.

Laboratory examinations including complete blood count, complements, hepatic, and renal functions were within the normal limits except for IgG 2409mg/dl (normal range, 870-1700mg/dl), IgA 922mg/dl (normal range, 110-410mg/dl), IgE 21878.2IU (normal range, 0-400IU), C-reactive protein 1.25mg/dl (normal range, 0-0.39mg/dl), and an erythrocyte sedimentation rate of 69mm in the first hour. Antinuclear (1:160), anti-SS-A 41.6index (normal, 0-9.9index), and anti-double-strand DNA 12.0U/ml (normal 0-10U/ml) antibodies were found, while other autoantibodies including rheumatoid factor, anti-Sm, and anti-SS-B were not present. M-protein was not detected upon serum immunoelectrophoresis. The diagnosis of Sjogren's syndrome was made from the findings of positive anti-SS-A antibody, dry eyes confirmed by the Schirmer test, and from focal aggregates of lymphocytes from a salivary gland biopsy. Urinalysis showed hematuria and proteinuria of 300 mg per day, which lead to a renal biopsy. The kidney specimens showed diffuse mesangial proliferation and extracellular matrix expansion where IgA deposits were confirmed by immunofluorescence (Fig 2). The diagnosis of IgA nephropathy was made. The patient underwent corticosteroid pulse therapy and

tonsillectomy for IgA nephropathy, which resulted in a complete remission of his skin symptoms for six months (Fig 1).

DISCUSSION

APAD is a rare clinical entity, the diagnosis of which can be made after excluding pustular dermatoses summarized in Table I. Bacterial and fungal cultures should be promptly performed to rule out infectious disease. The characteristic distribution of pustules on cutaneous folds, such as the ear, scalp, and external genital area may be helpful in the diagnosis of APAD. A relatively chronic clinical course can be seen. Histological features include intraepidermal spongiform pustules with a neutrophilic infiltrate in the dermis. Topical and systemic antibiotics fail to improve skin symptoms. Systemic corticosteroids,²⁻⁴ topical corticosteroids,^{2,5} chloroquine,³ dapsone,⁴ cyclosporine A,⁴ colchicin,⁶ cimetidine,⁷ and zinc⁸ have been used to treat APAD. Interestingly, all the patients previously described with APAD were female, whereas our patient was male. Female predominance may be explained by the underlying autoimmune disorders, such as SLE, which are known to show a similar female prevalence.

The reported APAD cases all had immunological abnormalities including several antibody subtypes and hypergammaglobulinemia, although most of them did not necessarily meet the diagnostic criteria for a particular autoimmune disease. Only four cases fulfilling the typical classification criteria for rheumatic diseases have been reported (Table II). Three cases harbored systemic lupus erythematosus (SLE),^{2,3,6} one of which overlapped with systemic sclerosis.³ One case had Sjogren's syndrome.⁴ We have added IgA nephropathy to the list of autoimmune disorders leading to amicrobial pustulosis. Whereas the treatment of IgA nephropathy is controversial,⁹ some retrospective studies demonstrated the efficacy of corticosteroid pulse therapy and tonsillectomy,^{10,11} which were significantly effective for APAD in our case. Marzono et

al. demonstrated an impaired neutrophil function in some APAD patients,⁷ though no additional data regarding the pathomechanisms in APAD are currently available. Our case might be a clue to performing further studies clarifying the mechanism of pustule formation in autoimmune diseases.

REFERENCES

1. Crickx B, Diego ML, Guillevin L, Picard C, Grossin M, Belaich S. Pustulose amicrobienne et lupus erythemateux systemique. Communication no. 11. Journees Dermatologiques de Paris, March 1991.
2. Lagrange S, Chosidow O, Piette JC, Wechsler B, Godeau P, Frances C. A peculiar form of amicrobial pustulosis of the folds associated with systemic lupus erythematosus and other auto-immune diseases. *Lupus* 1997;6:514-20.
3. Stefanidou MP, Kanavaros PE, Stefanaki KS, Tosca AD. Amicrobial pustulosis of the folds. A cutaneous manifestation associated with connective tissue disease. *Dermatology* 1998;197:394-6.
4. Kuyama M, Fujimoto W, Kambara H, Egusa M, Saitoh M, Yamasaki O, et al. Amicrobial pustular dermatosis in two patients with immunological abnormalities. *Clin Exp Dermatol* 2002;27:286-9.
5. Inui S, Azukizawa H, Asada H, Itami S. Amicrobial pustulosis with antinuclear antibodies and rheumatoid factor. *Br J Dermatol* 2006;154:568-9.
6. Kerl K, Masouye I, Lesavre P, Saurat JH, Borradori L. A case of amicrobial pustulosis of the folds associated with neutrophilic gastrointestinal involvement in systemic lupus erythematosus. *Dermatology* 2005;211:356-9.
7. Marzano AV, Capsoni F, Berti E, Gasparini G, Bottelli S, Caputo R. Amicrobial pustular dermatosis of cutaneous folds associated with autoimmune disorders: a new entity? *Dermatology* 1996;193:88-93.
8. Beneton N, Wolkenstein P, Bagot M, Cosnes A, Wechsler J, Roujeau JC, et al. Amicrobial pustulosis associated with autoimmune diseases: healing with zinc supplementation. *Br J Dermatol* 2000;143:1306-10.
9. Appel GB, Waldman M. The IgA nephropathy treatment dilemma. *Kidney Int* 2006;69:1939-44.
10. Hotta O, Miyazaki M, Furuta T, Tomioka S, Chiba S, Horigome I, et al. Tonsillectomy and steroid pulse therapy significantly impact on clinical remission in patients with IgA nephropathy. *Am J Kidney Dis* 2001;38:736-43.
11. Xie Y, Nishi S, Ueno M, Imai N, Sakatsume M, Narita I, et al. The efficacy of tonsillectomy on long-term renal survival in patients with IgA nephropathy. *Kidney Int* 2003;63:1861-7.

FIGURE LEGENDS

Fig 1.

Multiple pustules on the left ear auricle (A), and the left thigh (B). Complete remission of the pustules was observed after corticosteroid pulse therapy and tonsillectomy(C).

Fig 2.

Skin biopsy specimen of a pustule from his thigh showed a neutrophil infiltrate in the epidermis and the dermis (A). (Hematoxylin-eosin stain; original magnification x10.)

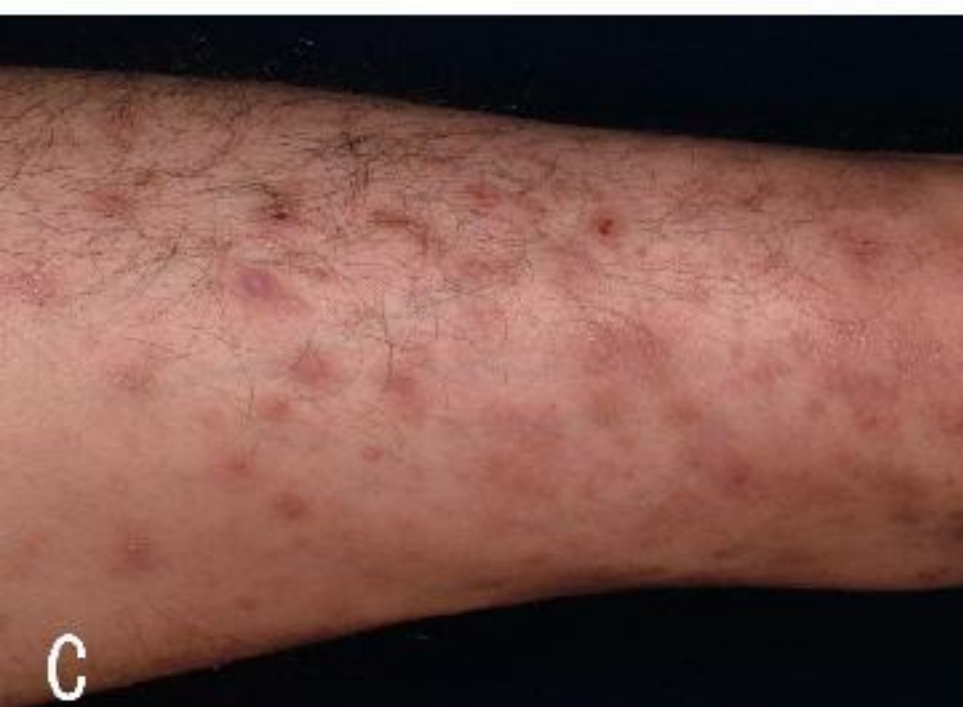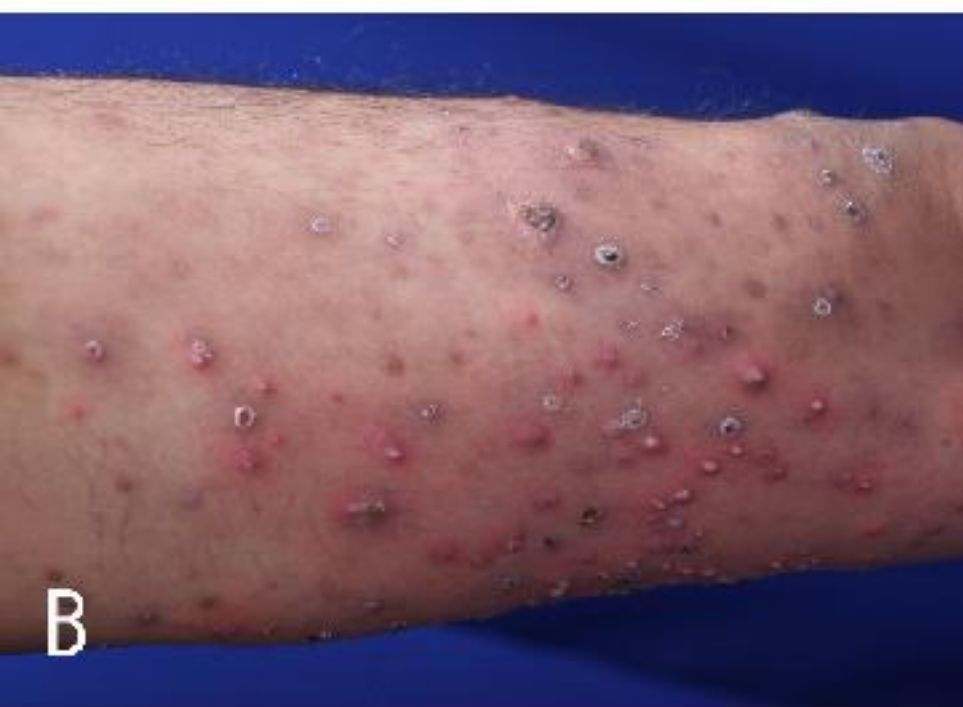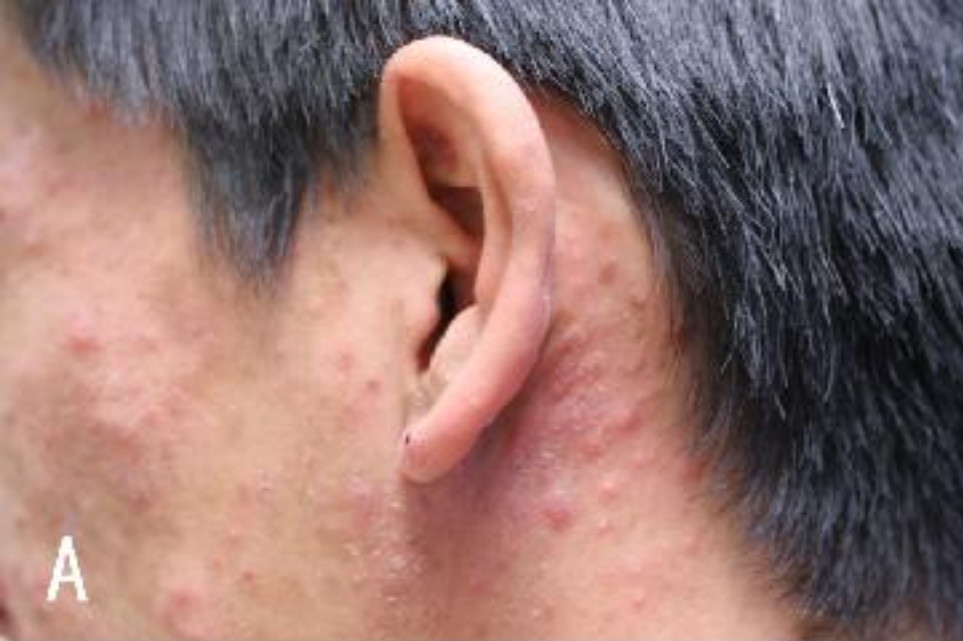Intraepidermal spongiform abscesses were observed (B). (Hematoxylin-eosin stain; original magnification x200.) Immunofluorescence study of the renal biopsy specimen revealed IgA deposits in the glomerular mesangium (C). (Original magnification x400.)

Table I.

Differential diagnosis of APAD

Table II.

Reported cases of amicrobial pustulosis with rheumatic diseases



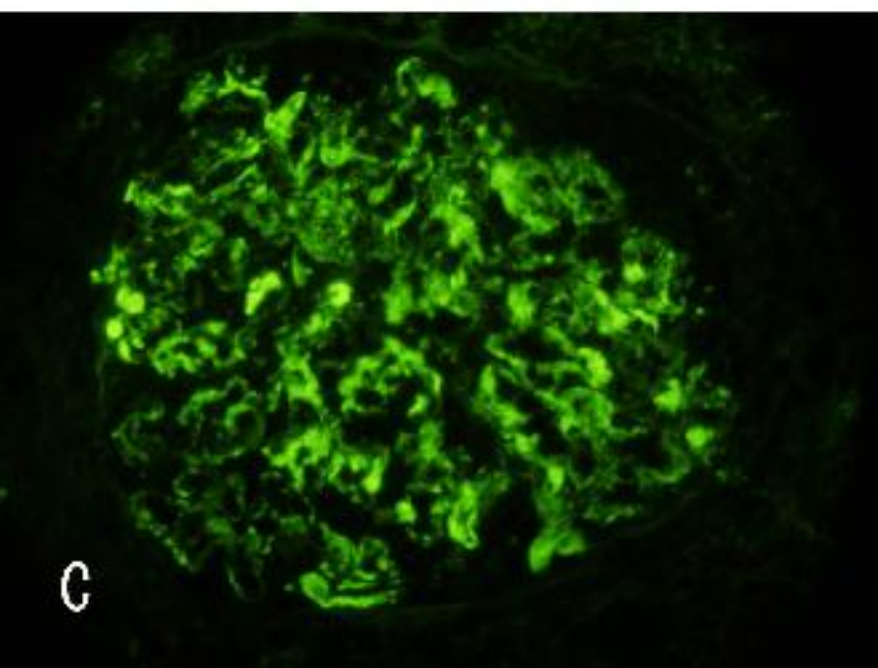
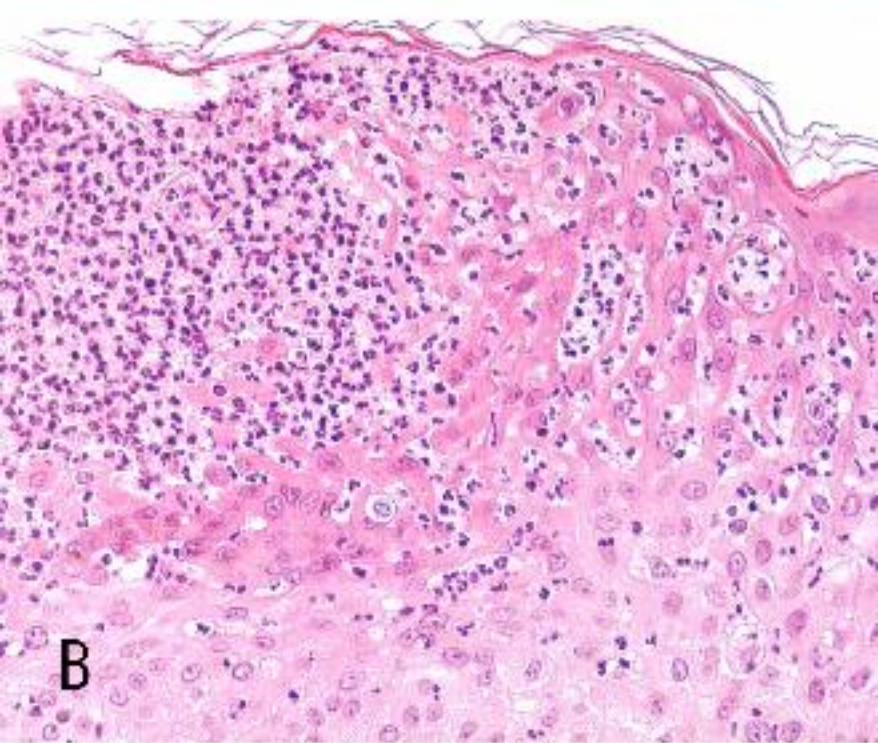
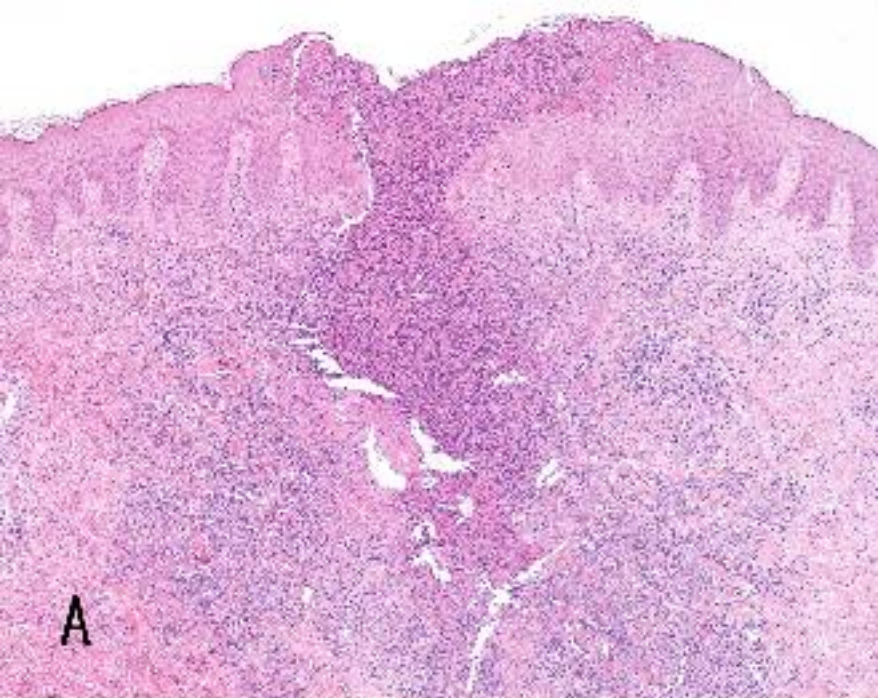


Table I. Differential diagnosis of APAD

Infection

Suppurative folliculitis

Furunculus

Impetigo contagiosa

Drug eruption

Acute generalized exanthematous pustulosis

Miscellaneous diseases

Pustular psoriasis

Subcorneal pustulosis (Sneddon-Wilkinson disease)

Sweet's syndrome

Behcet syndrome

Bowel associated dermatosis-arthritis syndrome

Iododerma

Bromoderma

Table II. Reported cases of amicrobial pustulosis with rheumatic diseases

Case	Sex/Age, y	Underlying diseases	Treatment	Clinical course	Reference
1	F/32	SLE	Systemic and topical CCS	Improved and relapsed after tapering CCS	2
2	F/50	SLE, SSc	Chloroquine, systemic CCS	Improved	3
3	F/63	SjS, DLE	Cyclosporin A, systemic CCS	Improved	4
4	F/36	SLE	Colchicin	Improved	6
5	M/31	SjS, IgA nephropathy	Systemic and topical CCS, CPT and tonsillectomy	Improved and relapsed after tapering CCS; CR after CPT and tonsillectomy	Our case

SLE, systemic lupus erythematosus; CCS, corticosteroids; SSc, systemic scleroderma; SjS, Sjogren's syndrome; DLE, discoid lupus erythematosus; CPT, corticosteroid pulse therapy; CR, complete remission