



<b>Title</b>	Evaluation of hydroxyapatite ceramic vertebral spacers with different porosities and their binding capability to the vertebral body : an experimental study in sheep
<b>Author(s)</b>	Ito, Manabu; Kotani, Yoshihisa; Hojo, Yoshihiro; Abumi, Kuniyoshi; Kadosawa, Tsuyoshi; Minami, Akio
<b>Citation</b>	Journal of Neurosurgery-Spine, 6(5), 431-437
<b>Issue Date</b>	2007-05
<b>Doc URL</b>	<a href="http://hdl.handle.net/2115/24338">http://hdl.handle.net/2115/24338</a>
<b>Rights</b>	The final version of the paper was published in JOURNAL OF NEUROSURGERY-SPINE, 6(5). For reuse of any of the materials, including editorial copy, figures, or tables please contact the Journal of Neurosurgery at <a href="mailto:jneuro@virginia.edu">jneuro@virginia.edu</a>
<b>Type</b>	article (author version)
<b>File Information</b>	JNSS6-5.pdf



[Instructions for use](#)

**Effects of Porosity Changes in Hydroxyapatite Ceramics Vertebral Spacer on Its Binding Capability to the Vertebral Body -An Experimental Sheep Study-**

Manabu Ito,MD,1  
Yoshihisa Kotani,MD,1  
Norihiro Hojo,MD,1  
Kuniyoshi Abumi, MD,1  
Tsuyoshi Kadosawa,DVM,2  
Akio Minami, MD1

- 1: Department of Orthopaedic Surgery, Hokkaido University Graduate School of Medicine, Sapporo, Japan.  
2.Department of Veterinary Medicine, Rakuno Gakuen University, Ebetsu, Japan.

Corresponding author: Manabu Ito,MD

Department of Orthopaedic Surgery, Hokkaido University Graduate School of Medicine,  
N15 W7 North-Ward,Sapporo, 060-8638 Japan

Tel:+81-11-706-5934 Fax:+81-11-706-6054 e-mail: [maito@med.hokudai.ac.jp](mailto:maito@med.hokudai.ac.jp)

**Key words:**

Spinal fusion, Anterior vertebral spacer, Bone graft substitute, Hydroxyapatite,

**Running head:**

Hydroxyapatite ceramics for anterior vertebral spacer

**Source of support:** This study was supported by PENTAX Co.

**Abstract:**

**Object.** This study aimed at evaluating the degree of bone ingrowth and bonding stiffness at the surface of hydroxyapatite ceramic (HAC) spacer with different porosity using an animal model and at discussing the ideal porous characteristics of HAC for anterior vertebral spacer.

**Methods.** Twenty-one adult sheep (age 1-2 yrs., avg. 70kg) were used. Surgery consisted of lumbar anterior interbody fusion at L2/3 and L4/5, insertion of HAC (size: 10x13x24mm) with 3 different porosities (0%, 3%, 15%) and single rod anterior instrumentation. At postoperative 4 and 6 months, the lumbar spine was harvested. Bonding conditions of bone-HAC interface were evaluated radiographically and biomechanically. A histologic evaluation was also conducted to examine the state of bone ingrowth at the surface of HAC.

Biomechanical testing showed that the bonding strength of HAC at postoperative 6 months were 0.047MPa in 0% porosity, 0.39MPa in 3%, and 0.49MPa in 15%. The histologic study showed that there was a soft tissue layer at the surface of HAC with 0% porosity. Direct bonding was observed between bone and HAC with 3% or 15% porosity. Microradiographic images showed direct bonding between the bone and HAC with 3% or 15% porosity. No direct bonding was observed in HAC with 0% porosity.

**Conclusions.** Dense HAC anterior vertebral spacers did not achieve direct bonding to the bone in the sheep model. HAC vertebral spacers with 3% or 15% porosity showed the proof of direct bonding to the bone at postoperative 6 months. The higher porosity HAC spacer showed better bonding stiffness to the bone,

## **Introduction:**

Among various biomaterials, hydroxyapatite ceramics (HAC) have been widely used as bone graft substitutes in spinal surgery. There are two types of HAC that have been used for different locations and purposes. One type of HAC is a solid structural type, which has been commonly used for anterior spinal fusion after cervical discectomies or posterior lumbar interbody fusions.<sup>2,10,14,16,19,23</sup> Another type of HAC is a morcelized graft material with high porosity for posterior or posterolateral spinal fusion in patients with unstable lumbar spine and spinal deformity.<sup>3,11,15,18</sup> Up to the present, there have been numerous animal and clinical studies evaluating the effectiveness of HAC for spinal surgery with conflicting results. Some studies reported that HAC was superior or equivalent to autogenous bone graft.<sup>8,10,13,16</sup> Pintar et al. showed that the fusion rate of dense HAC was similar to that of autogenous tricortical iliac bone graft in a goat model.<sup>13</sup> Suetsuna et al. and Kim et al. reported good clinical results of anterior cervical fusion using porous HAC.<sup>10,16</sup> On the other hand, there have been other reports regarding complications related to HAC, such as cracks, non-union and spinal cord compression due to its protrusion into the spinal canal.<sup>5,9,23</sup> Recently, some investigators tried to use high porous HAC as a carrier material for bone morphogenic proteins and autogenous stem cells to supply osteoinductive and/or osteogenic components with osteoconductive HAC material.<sup>3,11,15</sup>

As a synthetic interbody fusion material, there have been no clinical studies regarding the use of porous HAC blocks or spacers for posterior lumbar interbody fusion (PLIF) and for anterior reconstruction surgery in the thoracolumbar spine. One of the main reasons for the scarcity of reports about the use of porous HAC spacer for load sharing purposes may be due to the relative mechanical weakness and brittleness of porous HAC. In order to improve the mechanical strength of HAC for PLIF or anterior reconstruction in the lumbar spine, some clinical studies have tried to use dense HAC despite less bone ingrowth at the HAC-bone interface and the possibility of loosening.<sup>2</sup> To date, the ideal porosity, pore sizes and biomechanical strength of HAC for interbody fusion in load bearing situations remain unclear. Since optimal porous characteristics and biomechanical strength of HAC may differ according to the areas to which it is applied in the spine, determination of porous sizes and orientations of HAC are indispensable for achievement of high quality fusion at bone-HAC interface and satisfactory long-term clinical results in anterior spinal reconstruction surgery.

This study aimed at evaluating the degree of bone ingrowth and bonding stiffness at the surface of HAC spacer with different porosity using an animal model and at discussing the ideal porous characteristics of HAC spacer for anterior spinal reconstruction.

## **Materials and Methods:**

**Animal model and surgical technique.** Twenty-one adult male Suffolk sheep (age 1-2 yrs., weight 65-80kg avg. 70kg) were used under an experimental protocol approved by the institutional animal review board. Anesthesia was induced by intravenous administration of ketamine(10mg/kg) and diazepam(0.15mg/kg), and maintained with endotracheal inhalation of 2% isoflurane throughout the operation.

The animals were placed in the right lateral decubitus position and the left side of the lumbar vertebrae was exposed via a retroperitoneal approach after sterile preparation. After total removal of intervertebral discs at L2-3 and L4-5 and upper and lower cartilage endplates at both levels in order to obtain the bleeding bony surface, a HAC spacer (PENTAX Co., Tokyo, Japan) was inserted in these spaces with mild distraction. The HAC used in this study was chemically synthesized by sintering HA powder at 1200°C and shaping it into a 10x13x24mm block after fabrication (Fig.1). During synthesis, foaming liquid was mixed with HA powder to produce different size of pores in a HAC block. The animals were randomly divided into the three following groups according to the porosity of HAC. Group1(n=7); 0% porosity HAC (dense HAC), Group 2(n=7): 3% porosity HAC, Group 3(n=7): 15% porosity HAC. The surface image of each HAC taken with a scanning electron microscope (SEM) is shown in Fig.2.

Compressive stiffness of 0%, 3%, and 15% HAC was 735MPa, 710MPa, and 245MPa, respectively. Two HAC spacers of the same porosity were implanted at L2-L3 and L4-L5 in each animal. After complete discectomy and placement of HAC at L2-L3 and L4-L5, a single screw and rod system (Kaneda-SR, Depuy Acromed, Raynham, MA) were applied across L2-L3 and L4-L5 to afford immediate stability over the surgical sites.

At postoperative 4 and 6 months, the animals were euthanized and the whole lumbar spine was harvested. In each group, 3 animals were euthanized at postoperative 4 months and the other 4 animals at 6 months after surgery.

**Radiographic analysis.** Bonding conditions of bone-HAC interface were evaluated radiographically using CT scan. Two HAC-bone interfaces were evaluated in each animal. Bonding conditions between HAC and adjacent vertebral bodies on CT images were classified into four grades (slip out, suspicious fusion, probable fusion, absolute fusion)(Fig. 3). After taking CT scans, all soft tissues and the spinal implants were removed from the lumbar spine.

**Biomechanical testing.** Six motion segments containing HAC in each animal group euthanized at postoperative 6 months and 4 motion segments in each group euthanized at postoperative 4 months were examined biomechanically. Interfacial tensile strength

between the HAC and the vertebral body was evaluated by a detachment test under displacement control using the servohydraulic MTS 858 Mini Bionix 2 System (MTS systems, Minneapolis, MN). The vertebral bodies around HAC spacer were removed by an automated burr so as to preserve the HAC-vertebral body interface. Then, the upper and lower bodies were anchored with stainless steel screws and secured in metal fixtures with polyester resin (Fig.4). The tensile load was applied to the top of the upper vertebral body at a constant speed of 0.5mm/sec. Load-displacement curves were recorded by a data-sampling program (MultiPurpose TestWare, Minneapolis, MN) on a personal computer (COMPAQ Deskpro EN,Houston,TX). The curves were analyzed to yield peak loads at tensile failure. Tensile failure strength (MPa) was calculated as the failure load (N) divided by the cross-sectional area of HAC-bone interface. The detached surface of the vertebral body was recorded by a digital camera (Nikon D1, Nikon Co., Tokyo, Japan) immediately after the detachment test, and the cross-sectional area of the HAC on digital images was measured by I mage J Software (NIH, Bethesda, MD).

**Histologic analysis.** Four motion segments from each group were examined histologically. Among the 4 segments in each group, two segments were taken from the animals euthanized at postoperative 4 months and the other 2 were from the animals



euthanized at postoperative 6 months. Histologic analysis was also conducted to examine the state of bone ingrowth at the surface of HAC. The specimens were subjected to undecalcified tissue processing and frontal sections of the spinal unit containing HAC were examined by light microscopy. The specimens were sectioned by a diamond saw into an appropriate thickness and were then ground to obtain 1mm thickness. Hematoxylin and eosin and toluidine blue-O staining were performed. Direct bonding of HAC to the bone was measured on a histology slide by the ratio of direct bonding surface to the total surface of HAC. Three slices of histology slides of one HAC spacer were randomly selected for measurement and the average was chosen for the representative value (direct bonding ratio: DBR).

**Microradiographic analysis.** Microradiographic evaluation was conducted using micro-CT scan (Hitachi MTC-225CB, Meedico Corp. Japan) to examine the interface between the HAC and vertebral bodies of representative animal in each group.

**Statistical analysis.** Chi-square test was used to analyze the data obtained by CT images for radiographic assessment of fusion. Unpaired t-test was used to assess the interfacial tensile strength and DBR. A difference of P-value less than 0.05 was considered to be statistically significant.

## **Results:**

All the animals tolerated the surgery and remained alive throughout the observation periods with no evidence of severe pain or neurological impairment. One animal had postoperative superficial wound infection, which had healed within 2 weeks after surgery.

### **Radiographic analysis.**

The results of radiographic evaluation are shown in table 1. There were 2 animals with 0% HAC spacer slipping out and 4 with 3% HAC slipping out from the disc space. There was no 15% HAC spacer slipping out on CT images. Dense HAC (0% porosity) showed the lowest fusion rate both at 4 months and 6 months after surgery. Fusion rates with 0% HAC were 0% and 25% at postoperative 4 months and 6 months respectively. 3% HAC showed 50% fusion rate at postoperative 6 months. 15% HAC showed the highest fusion rate (75%) at postoperative 6 months. There was no significant statistical difference among the groups.

### **Biomechanical evaluation.**

As to bonding strength of HAC at postoperative 4 months, 15% HAC averaged  $0.071 \pm 0.018$  MPa and 0% HAC and 3% showed  $0.061 \pm 0.028$  MPa and  $0.058 \pm 0.058$  MPa respectively. There was no statistical difference among the groups at postoperative 4

months. Bonding stiffness in all groups was extremely low at postoperative 4 months. At postoperative 6 months, averaged bonding strength was  $0.047 \pm 0.026$  MPa in 0% HAC,  $0.39 \pm 0.32$  MPa in 3% HAC, and  $0.49 \pm 0.29$  MPa in 15% HAC. Statistical significance was observed in bonding strength between postoperative 4 months and 6 months in the group of 3% and 15% HAC. There were significant statistical differences in bonding stiffness between 0% and 3% HAC and between 0% and 15% HAC at 6 months after surgery.

After the detachment test, remnant parts of 3% and 15% HAC were left at the detachment surface of the vertebral bodies, which showed that bonding stiffness between HAC and the bone was bigger than the mechanical stiffness of HAC itself (Fig.5).

### **Histological evaluation of HAC-Bone interface.**

A soft tissue layer was observed at the interface between 0% HAC and the vertebral bodies. Around 0% HAC spacer, there was also cartilage tissue as well as fibrous tissue. There was no direct bonding between 0% HAC and the bone (Fig.6a). On the contrary, there were areas indicating direct bonding between 3% and 15% HAC spacer and the vertebral bodies (Fig.6b), though there were some areas showing soft tissues between

HAC and the bone. There was also a new bone formation in the pores adjacent to the vertebral bodies in the group of 3% and 15% HAC.

DBR (direct bonding ratio) of 0% HAC was 0% both at postoperative 4 months and 6 months. DBR of 3% HAC at postoperative 4 months and 6 months was  $11.3 \pm 13.5\%$  and  $17.7 \pm 20.5\%$  respectively. DBR of 15% HAC at postoperative 4 months and 6 months was  $9.1 \pm 8.0\%$  and  $20.8 \pm 27.1\%$  respectively. Though high porous HA tended to have higher DBR, there was no statistically significant difference among the groups.

#### **Microradiographic analysis.**

Microradiographic images of 15% HAC at postoperative 6 months are shown in Fig.7. There was no gap between trabecular bones of the vertebral bodies and the surface of HAC.

#### **Discussion:**

There have been many experimental or clinical studies in terms of the clinical benefits and drawbacks of hydroxyapatite ceramics in spinal surgery.<sup>4,6,9,13,21</sup> The main use of HAC in spinal surgery has been as a bone graft expander for posterolateral spinal fusion, interspinous blocks after cervical laminoplasty, and anterior strut graft after cervical discectomy.<sup>7,15</sup> To obtain better bony ingrowth into HAC, high porous HAC

has been reported to be beneficial compared with low porous HAC.<sup>15</sup> Therefore, industrial companies have been striving to produce higher porous HAC for posterolateral spinal fusion or interspinous blocks after cervical laminoplasty. However, since higher porosity HAC showed biomechanical weakness and brittleness, which often led to cracks or collapse, several reports did not recommend porous HAC for anterior column support after resection of intervertebral discs.<sup>9,23</sup> Therefore, there have been some reports utilizing dense HAC spacer for anterior cervical fusion after discectomy.<sup>4,13</sup> Our literature search revealed that the porosity of HAC clinically used for anterior spinal fusion had a large variety ranging from 0% to 70%.<sup>4,9,10,13,21,23</sup>

Several attempts have been made to compensate the biomechanical weakness of high porous HAC in clinical situations by using a titanium cage as an outside shell so that the titanium cage sustains the load and inner HAC can act only for fusion to the adjacent vertebral bodies.<sup>1,3,12,20</sup> Considering biomechanical characteristics of HAC with different porosities, hybrid types of HAC vertebral spacers would be the best so that the dense HAC would be outside for load bearing and inner porous HAC for direct bonding in a vertebral spacer. At present, however, these composite materials of HAC are not commercially available for clinical practice.

To pursue the biomechanical stiffness of HAC, some industrial companies are

producing dense HAC for anterior spinal reconstruction surgery. There have been no clinical and experimental studies, however, which scientifically prove what is the lowest porosity of HAC for direct bonding between HAC and bone when used for anterior column support in spinal surgery. The present animal study showed that HAC with 0% porosity had no possibility of direct bonding to the bone at 6 months after implantation. It is still unknown whether 0% HAC spacer could obtain direct bonding to the bone later than postoperative 6 months. This animal study showed that HAC should require at least 3% porosity for anterior strut graft in order to obtain direct bonding between HAC and the bone. Though there was no statistical difference in DBA between 3% and 15% porosity in the histologic evaluation, biomechanical bonding strength of 15% HAC tended to be superior to that of 3% HAC. This result was compatible with previous studies indicating that higher porosity offered greater possibility for bony ingrowth into the surface of HAC.<sup>15,22</sup>

Taking into account the fact that compressive strength of 15% HAC is equal to human cortical bone of the femur, porosity lower than 15% can be used as an alternative graft material for anterior spinal reconstruction surgery from a biomechanical standpoint. Biomechanical strength of HAC decreases as its porosity increases. When HAC with high porosities was used for anterior strut graft, standalone HAC grafting may cause

higher rates of collapse because of its biomechanical weakness. Some studies recommended the combined use of metal instrumentation with HAC spacers to afford more biomechanical stiffness to the surgical site for better fusion.<sup>17,23</sup> Ideal porosity and biomechanical strength of HAC for anterior strut graft need to be identified in future studies.

Other factors to obtain better direct bonding between HAC and the bone were its surface characteristics. The present study utilized smooth surfaced HAC spacers so that there were some animals whose 0% or 3% HAC was slipping out at the final follow-up. Lower rate of slipping out in 15% HAC might be due to its rough surface than that of 0% or 3% HAC. The rough surface of HAC may be better to prevent HAC from slipping out at the site of implantation. Optimal surface design is another important factor for preventing HAC spacers from slipping out and obtaining better contact between HAC spacer and bone. Development in manufacturing process of HAC spacers may help to advance the surface design of HAC spacer in the future.

### **Conclusions.**

Dense HAC anterior vertebral spacers did not achieve direct bonding to the bone at 6 months after surgery in a sheep model. HAC vertebral spacers with 3% or 15% porosity showed the capability of direct bonding to the bone at postoperative 6 months. Though

there was no statistical significance, there was a tendency that HAC with 15% porosity gained stronger bonding to the bone than that with 3% porosity.



**Acknowledgement:**

The authors thank Yoshie Tominaga,BS, and Takehiko Nakajima,BS, PENTAX Co, for their technical support. Also thanks to Kiyoshi Kaneda, MD, and Robert Reid Inc. for donating Kaneda-SR implants.

## References:

1. Agrillo U, Mastronardi L, Puzzilli F: Anterior cervical fusion with carbon fiber cage containing coralline hydroxyapatite: Preliminary observations in 45 consecutive cases of soft-disc herniation: **J Neurosurg(Spine3)** **96**:273-276,2002.
2. Asazuma T, Masuoka K, Motosuneya T, Tsuji T, Yasuoka H, Fujiwara K: Posterior lumbar interbody fusion using dense hydroxyapatite blocks and autogenous iliac bone. Clinical and radiographic examinations. **J Spinal Disord Tech** **18**:s41-s47, 2005.
3. Blattert TR, Delling G, Dalal PS, Toth CA, Balling H, Weckback A: Successful transpedicular lumbar interbody fusion by means of a composite of osteogenic protein-1(rhBMP-7) and hydroxyapatite carrier. A comparison with autograft and hydroxyapatite in the sheep spine. **Spine** **27**:2697-2705,2002.
4. Cook SD, Reynolds MC, Whitecloud TS, Routman AS, Harding AF, Kay JF, et al: Evaluation of hydroxyapatite graft materials in canine cervical spine fusions. **Spine** **11**:305-309,1986.
5. Cook SD, Dalton JE, Tan EH, Tejeiro WV, Young MJ, Whitecloud TS: In vivo evaluation of anterior cervical fusions with hydroxyapatite graft material. **Spine** **19**:1856-1866,1994.

6. Emery SE, Fuller DA, Stevenson S: Ceramic anterior spinal fusion. Biologic and biomechanical comparison in a canine model. **Spine** **21**:2713-2719,1996.
7. Hirabayashi S, Kumano K: Contact of hydroxyapatite of hydroxyapatite spacers with split spinous process in double-door laminoplasty for cervical myelopathy. **J Orthop Sci** **4**:264-268,1999.
8. Iseda T, Nakano S, Suzuki Y, Miyahara D, Uchinokura S, Moriyama T, et al: Radiographic and scintigraphic courses of union in cervical interbody fusion: hydroxyapatite grafts versus iliac bone autografts. **J Nucl Med** **41**:1642-1645, 2000.
9. Ito M, Abumi K, Shono Y, Kotani Y, Minami A, Kaneda K: Complications related to hydroxyapatite vertebral spacer in anterior cervical spine. **Spine** **27**:428-431,2002.
10. Kim P, Wakai S, Matsuo S, Moriyama T, Kirino T: Bisegmental cervical interbody fusion using hydroxyapatite implants: surgical results and long-term observation in 70 cases. **J Neurosurg** **88**:21-27,1998.
11. Kwon B, Jenis LG: Carrier materials for spinal fusion. **Spine J** **5**:224-230S,2005.
12. Papavero L, Zwönitzer R, Burkard I, Klose K, Herrmann HD: A composite bone graft substitute for anterior cervical fusion. Assessment of osseointegration by quantitative computed tomography. **Spine** **27**:1037-1043,2002.

13. Pinter FA, Maiman DJ, Hollowell JP, Yogananda N, Droese KW, Reinartz JM, et al: Fusion rate and biomechanical stiffness of hydroxyapatite versus autogenous bone grafts for anterior discectomy. An in vivo animal study. **Spine** **19**:2524-2528,1994.
14. Senter HJ, Kortyna R, Kemp WR: Anterior cervical discectomy with hydroxyapatite fusion. **Neurosurgery** **25**:39-43,1989.
15. Spivak JM, Hasharoni A: Use of hydroxyapatite in spine surgery. **Eur Spine J** **10**:s197-s204,2001.
16. Suetsuna F, Yokoyama T, Kenuka E, Harata S: Anterior cervical fusion using porous hydroxyapatite ceramics for cervical disc herniation: a two-year follow-up. **Spine J** **1**:348-357,2001.
17. Takahashi T, Tominaga T, Yoshimoto T: Biomechanical evaluation of hydroxyapatite intervertebral graft and anterior cervical plating in a porcine cadaveric model. **Bio-Medical Materials and Engineering** **7**:121-7,1997.
18. Takahashi T, Tomonaga T, Watabe N, Yokobori T, Sasada H, Yoshimoto T: Use of porous hydroxyapatite graft containing recombinant human bone morphogenetic protein-2 for cervical fusion in a caprine model. **J Neurosurg (Spine 2)** **90**:224-230,1999.

19. Thalgott JS, Fritts K, Giuffre JM, Timlin M: Anterior interbody fusion of the cervical spine with coralline hydroxyapatite. **Spine** **24**:1295-1299, 1999.
20. Thalgott JS, Giuffre JM, Klezl Z, Timlin M: Anterior lumbar interbody fusion with titanium mesh cages, coralline hydroxyapatite, and demineralized bone matrix as part of a circumferential fusion. **Spine J** **2**:63-69,2002.
21. Toth JM, An HS, Lim TH, Ran Y, Weiss NG, Lundberg WR, et al: Evaluation of porous biphasic calcium phosphate ceramics for anterior cervical interbody fusion in a caprine model. **Spine** **20**:2203-2210, 1995.
22. Wigfield CC, Nelson RJ: Nonautologous interbody fusion materials in cervical spine surgery. How strong is the evidence to justify their use?. **Spine** **26**:687-94,2001.
23. Zdeblick TA, Cooke ME, Kunz DN, Wilson D, McCabe RP: Anterior cervical discectomy and fusion using a porous hydroxyapatite bone graft substitute. **Spine** **19**:2348-57,1994.

### **Figure Legends:**

Fig.1: A rectangular block of HAC was used in this study. The width, height, and length of the block were 10mm, 13mm, and 24mm.

Fig.2a: Surface of 0% HAC is shown by scanning electron microscope (SEM) (x3000). The surface of HAC is smooth and there is no pore on its surface.

Fig.2b: Surface of 3% HAC is shown by SEM (x3000). There are numerous small pores seen on its surface. The pore diameter was approximately 1 $\mu$ m.

Fig.2c: Surface of 15% HAC is shown by SEM (x3000). There are both small pores and large pores in the same image. The diameter of a small pore was 1 $\mu$ m and that of a large pore was 20 $\mu$ m.

Fig.3: Radiologic finding was graded into the four following categories. Fig.3.a is a typical CT image of slipping out of HAC spacer. Fig. 3b is suspicious fusion. Fig.3c is probable fusion. Fig.3d is definite fusion.

Fig 4: This is the biomechanical testing set-up used in this study. Pure detachment strength at the HAC-bone interface was measured. The vertebral bodies excluding the area of pure HAC-bone interface was removed by an automated diamond burr.

Fig.5: The surface of vertebral body after detachment test was shown. The remnant of HAC was left on the vertebral body. Since the bonding strength of HAC to the bone was

bigger than the mechanical stiffness of HAC, the cracks occurred inside the HAC with 3% and 15% porosity.

Fig.6a: A histologic image of the interface between 0% HAC and bone is shown (x100).

B indicates bone, C does cartilage and H does hydroxyapatite spacer. Soft tissue layer or cartilage layer was seen at the interface between 0% HAC and the bone. There was no evidence of direct bonding of 0% HAC to the bone.

Fig 6b: A histologic image of 15% HAC is shown (x100). B indicates bone and H does

hydroxyapatite spacer. Direct bonding of 15% HAC to bone is evident without any soft tissue layer between HAC and the bone.

Fig.7: A microradiographic image of around 15% HAC showed that there was no gap

between 15% HAC spacer and the bone and trabecular bone directly connected to the bone. B indicates bone and H does hydroxyapatite.







*Figure 1*




Figure 2a




Figure 2b

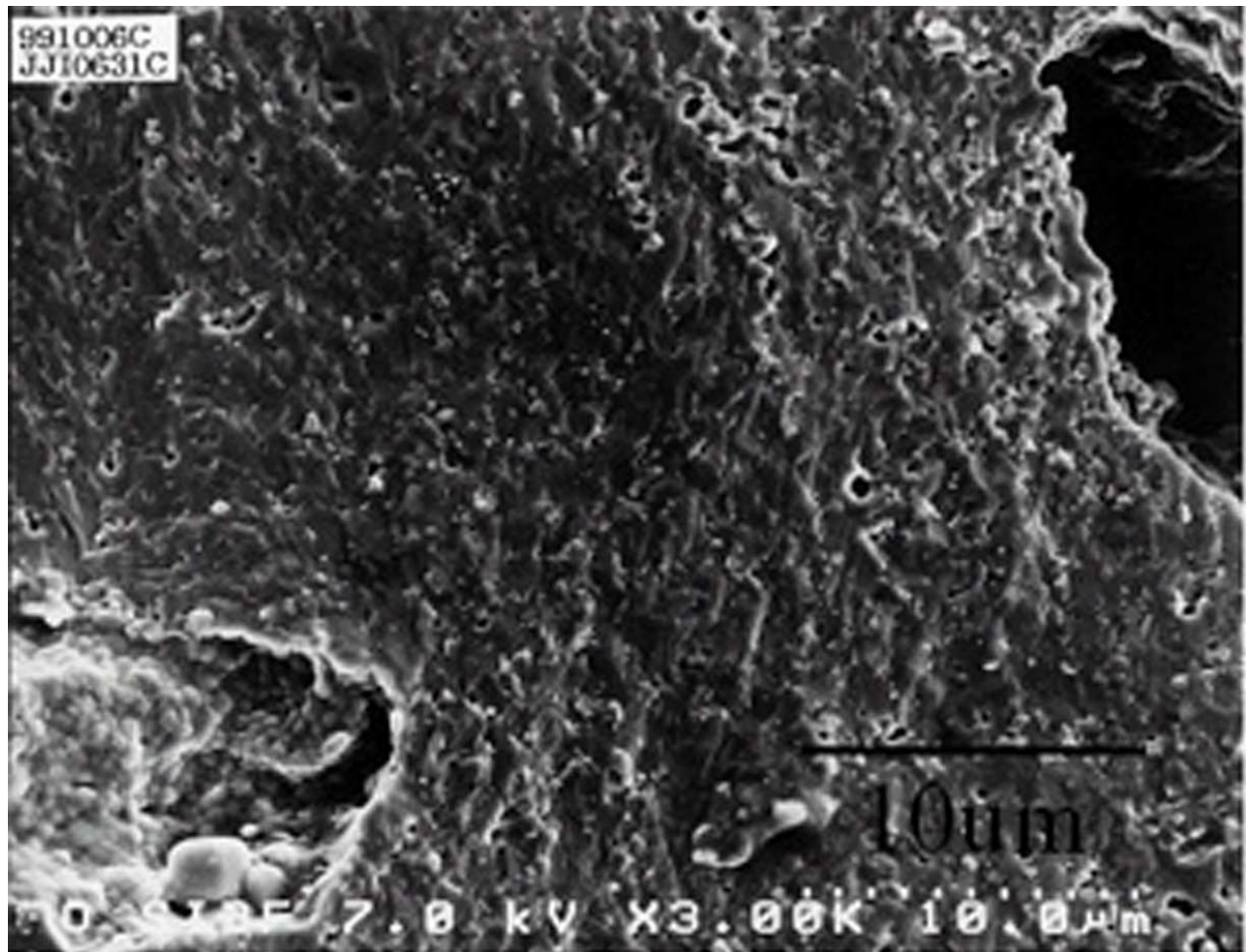


Figure 2c

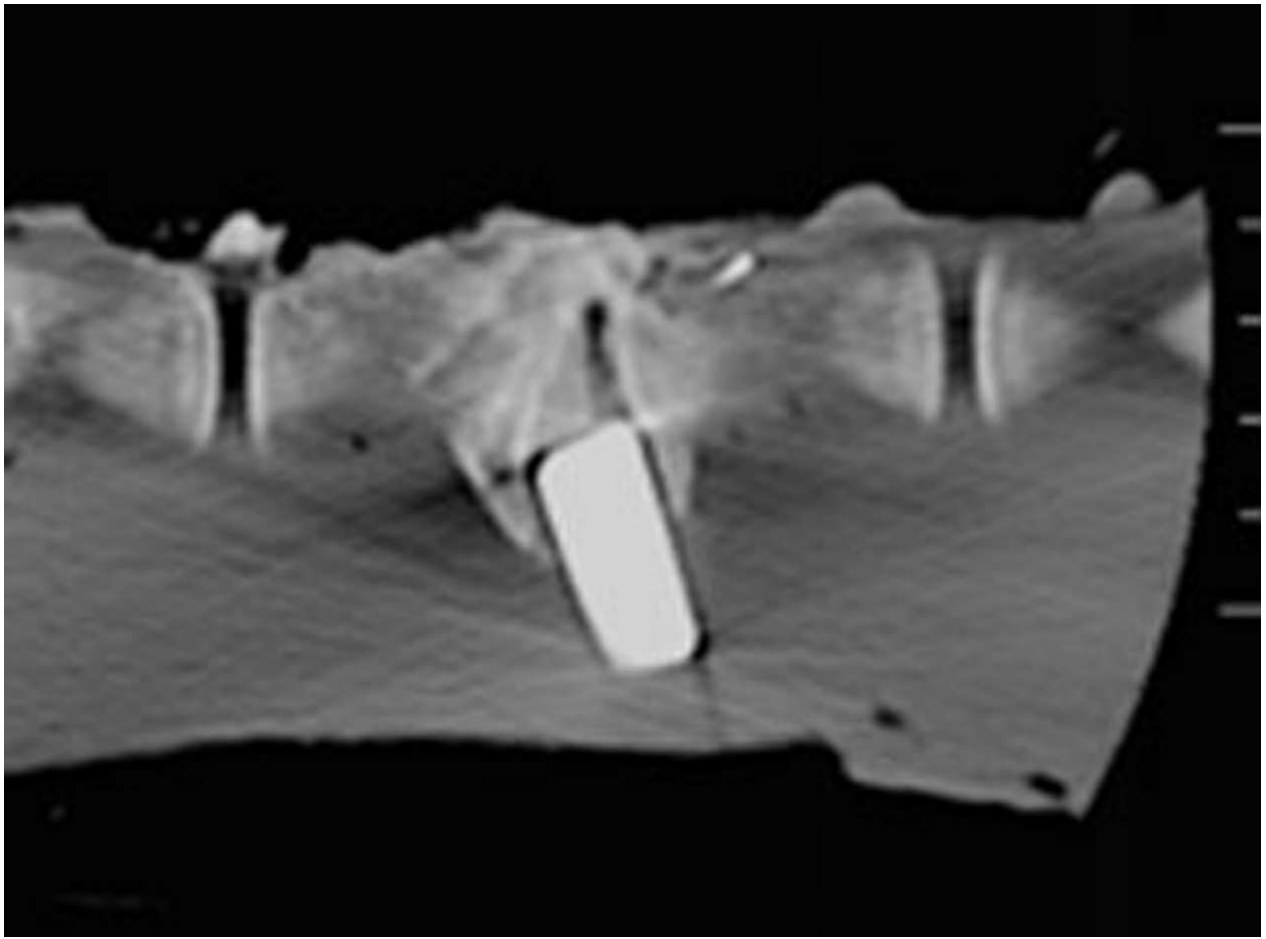


Figure 3a

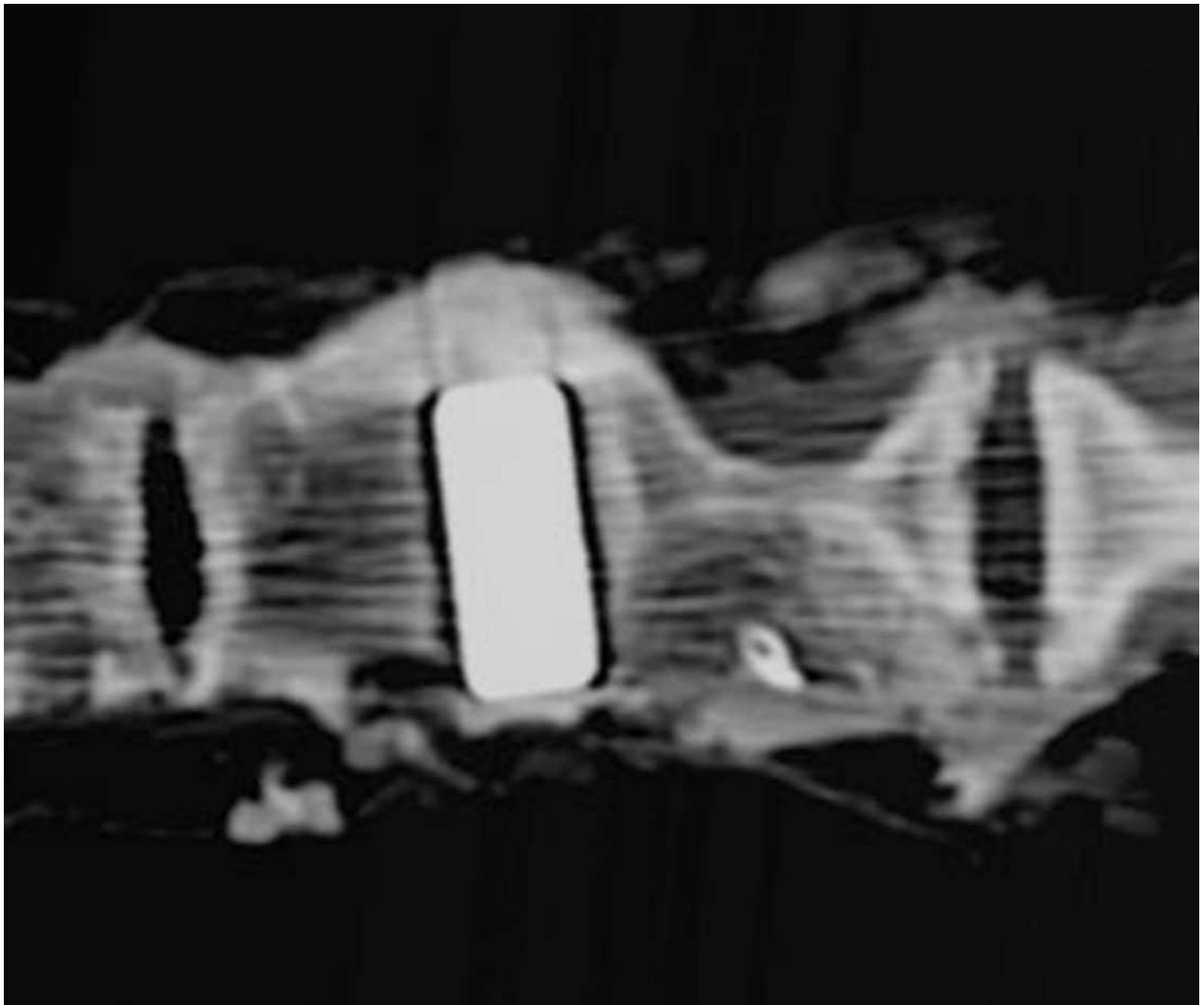


Figure 3b

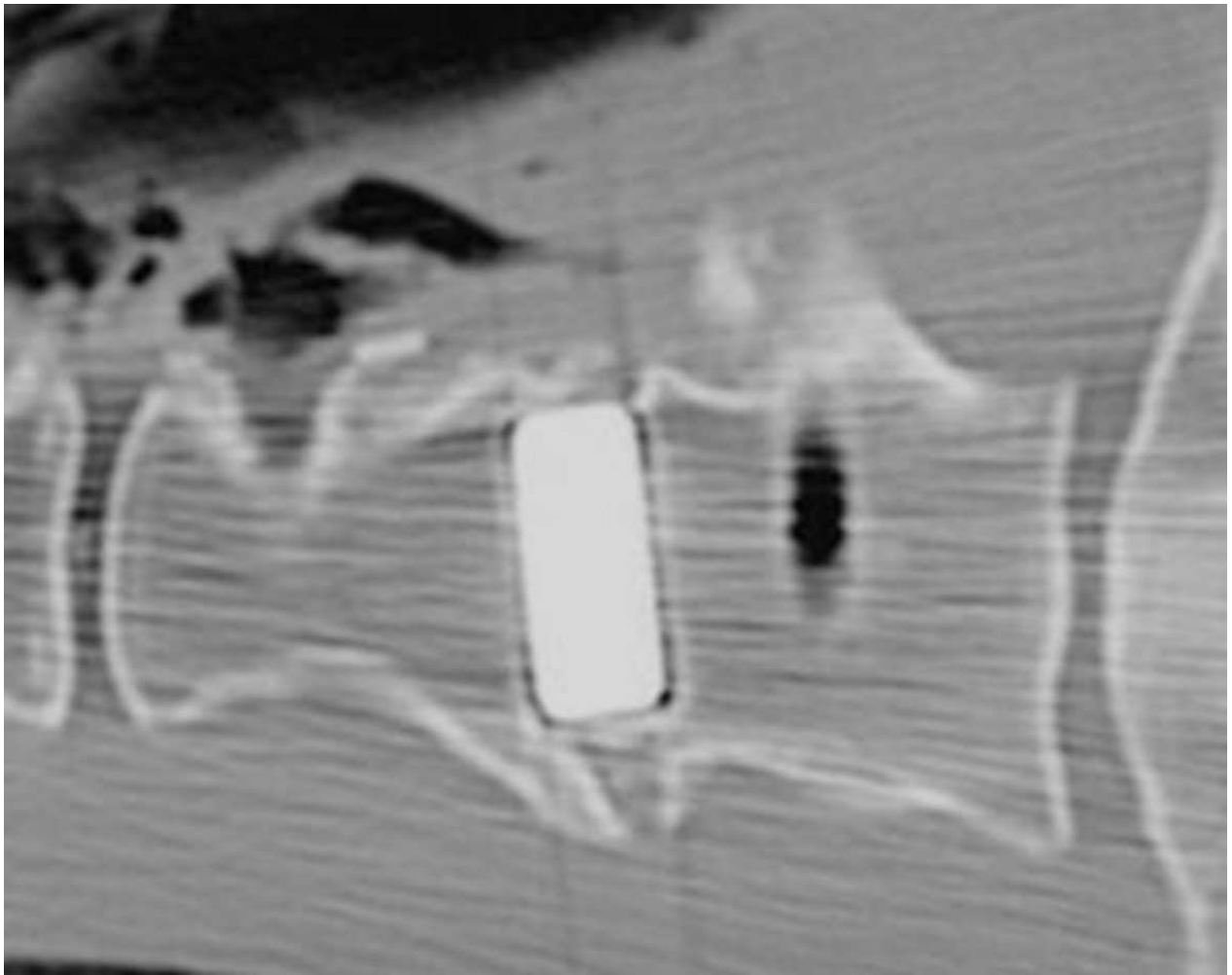


Figure 3c

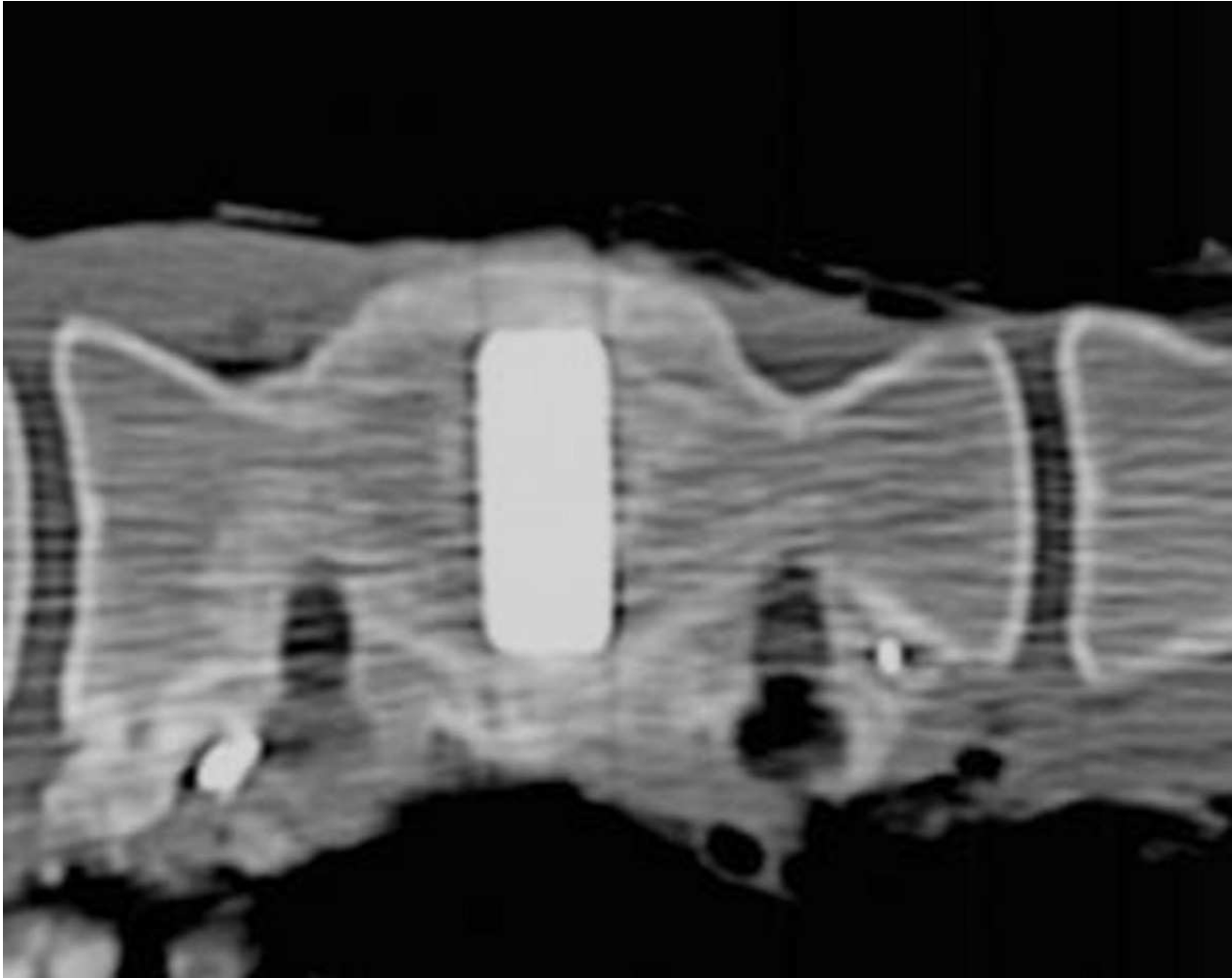
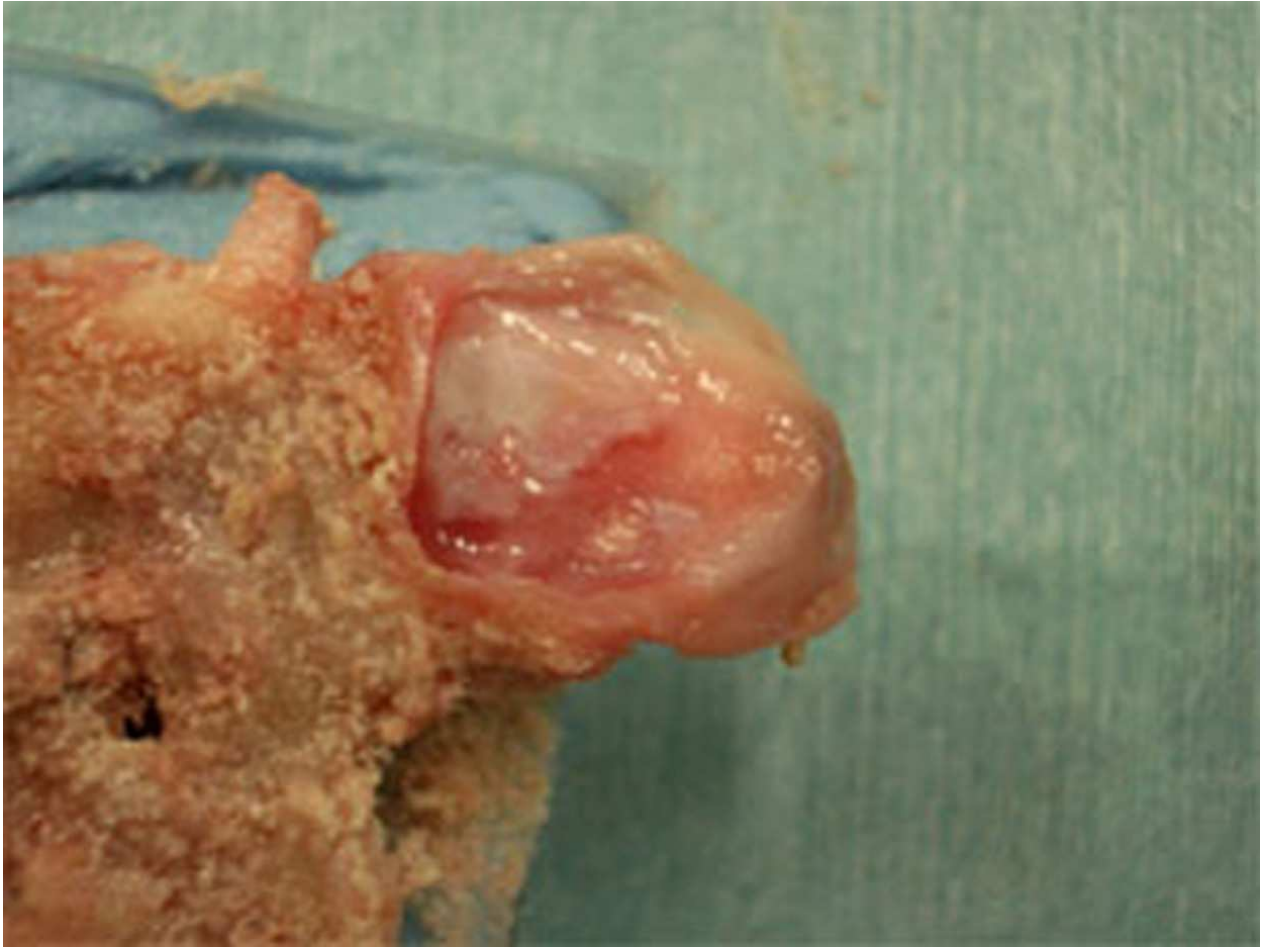

Figure 3d





*Figure 4*



*Figure 5*

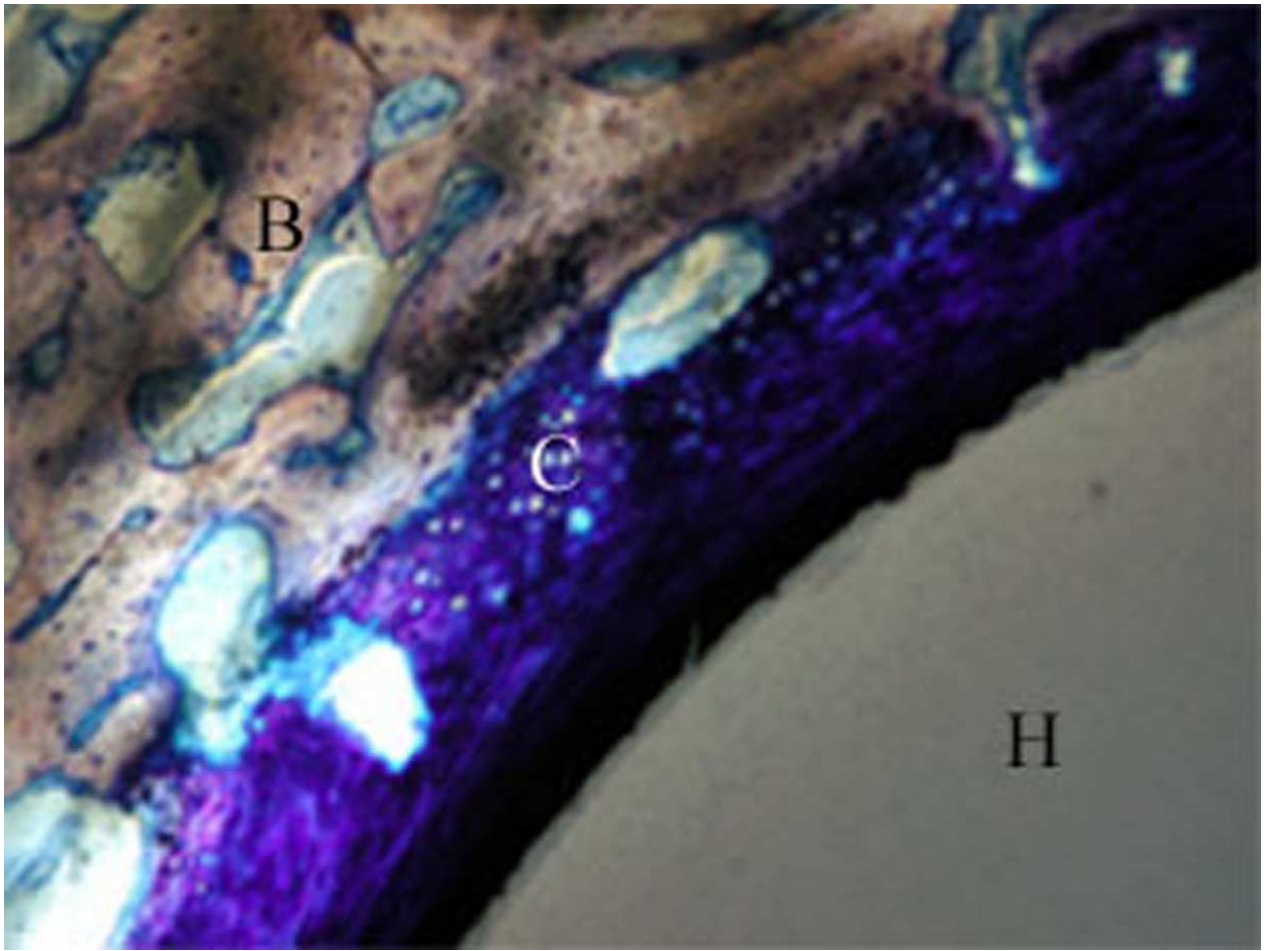


Figure 6a

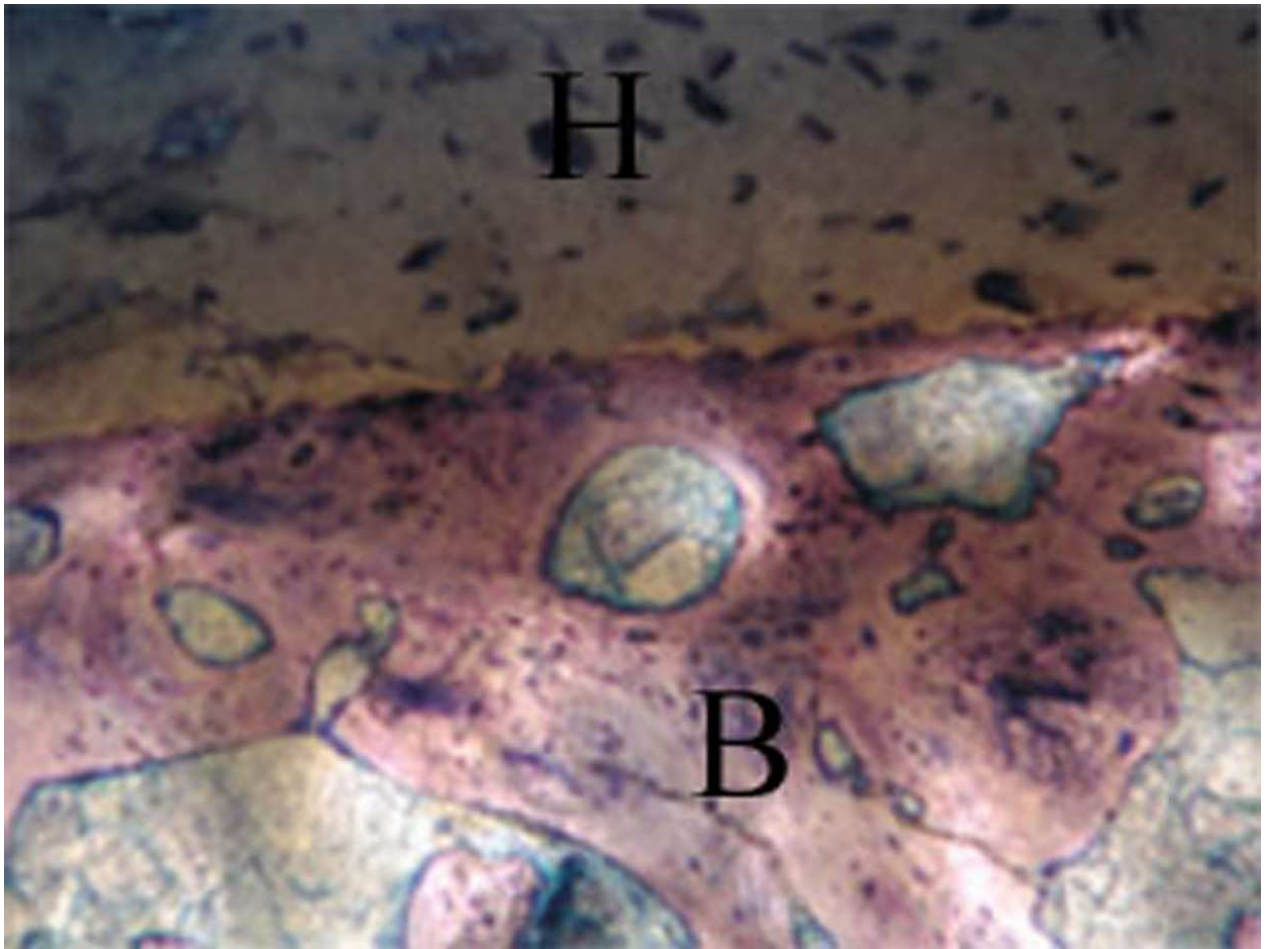


Figure 6b




Figure 7

Table 1: Radiographic Evaluation of Fusion between HAC Spacer and Bone

Absolute	0	0	0	0	1	3
Probable	0	2	0	4	1	3
Suspicious	5	5	4	2	4	2
Slip out	1	1	2	2	0	0
Porosity of HAC	0%	0%	3%	3%	15%	15%
Time after Surgery	4 months	6 months	4 months	6 months	4 months	6 months
Fusion rates	0%(0/6)	25%(2/8)	0%(0/6)	50%(4/8)	33%(2/6)	75%(6/8)

Two HAC spacers were inserted in each animal and CT image of each HAC was evaluated.

Absolute or probable fusion was defined as radiologic fusion between HAC spacer and bone.