



Title	Spontaneous perigraft hematoma suggesting transgraft hemorrhage seven years after thoracic aortic replacement with a Dacron graft
Author(s)	Shiuya, Norihiko; Kunihara, Takashi; Matsuzaki, Kenji; Sugiki, Takashi
Citation	European Journal of Cardio-Thoracic Surgery, 30(2), 402-404 https://doi.org/10.1016/j.ejcts.2006.05.014
Issue Date	2006-08
Doc URL	http://hdl.handle.net/2115/14842
Type	article (author version)
File Information	EJCS30-2.pdf



[Instructions for use](#)

Spontaneous perigraft hematoma suggesting transgraft hemorrhage seven years after
thoracic aortic replacement with a Dacron graft

Norihiko Shiiya, Takashi Kunihara, Kenji Matsuzaki , Takashi Sugiki

Department of Cardiovascular Surgery, Hokkaido University Hospital
N14W5, Kita-ku, Sapporo 060-8648, Japan

Corresponding author: Norihiko Shiiya

Department of Cardiovascular Surgery, Hokkaido University Hospital
N14W5, Kita-ku, Sapporo 060-8648, Japan

TEL: +81-11-716-1161 ext. 6042, FAX: +81-11-706-7612

e-mail: shiyanor@med.hokudai.ac.jp

Word count of the text: 1052 words

Word count of the abstract: 81 words

Abstract

As a previously unrecognized late graft-related complication, we report a case of spontaneous perigraft hemorrhage, which was evidenced by contrast extravasation on computed tomographic scan seven years after thoracic aortic replacement with a knitted Dacron graft. There was no anastomotic problem or graft tear, and the hematoma seemed to result from transgraft hemorrhage. Inadequate graft healing and use of a knitted graft in the thoracic aorta seem underlying. Surgeons should be aware of this complication and we advocate careful long-term follow-up.

Key Words: graft-related complication, knitted graft, thoracic aorta

As a previously unrecognized late graft-related complication, we report a case of spontaneous perigraft hemorrhage, which was evidenced by contrast extravasation on computed tomography seven years after thoracic aortic replacement with a knitted Dacron graft. There was no anastomotic problem or graft tear, and the hematoma seemed to result from transgraft hemorrhage. We discuss possible mechanisms and emphasize the need for careful long-term follow-up.

Case

The patient was a 71 year-old man who had undergone ascending and total arch aortic replacement with a 22-mm Gelseal graft with four side branches (Vascutek, Renfrewshire, Scotland). Annual follow-up by CT scan revealed perigraft hematoma and contrast extravasation seven years after surgery. The graft diameter was 30-mm, which remained stable for recent six years. He was not anticoagulated throughout this period. Because the patient was asymptomatic and CT findings did not suggest anastomotic problem, he was followed up for six months, when the hematoma became enlarged (Figure 1) and reoperation was performed. Preoperative serum fibrin degradation product level was normal.

At reoperation, loose fresh clots surrounding the right dorso-lateral aspect of the graft

were found near the origins of the branch grafts. Graft surface was exposed to this space without external encapsulation, but no exact point of leakage was found. All the anastomotic sites were completely encapsulated into surrounding tissue and no dehiscence was noted. Leaving short segments of completely healed peri-anastomotic portions, we removed the graft and replaced it with a 24-mm branched woven graft (Hemashield, Boston Scientific, Natick, MA). The burst strength of the explanted graft was 0.34538kN, which meets the acceptance criteria (0.3kN) of the manufacturer. Scanning electron microscopes showed the integrity of the graft fabric (Figure 2). Microscopic examination revealed a typical foreign body cellular reaction. However, portion of the graft exposed to hematoma showed no evidence of tissue ingrowth. There was no evidence of infection.

Discussion

The Gelseal graft is a warp-knitted Dacron prosthesis with 750 ml/cm²/min porosity that is sealed with gelatin to achieve imperviousness. It has triaxial conformation, in which an extra yarn is knitted into the basic fabric, to enhance dimensional stability and reduce porosity. Because of the imperviousness and triaxial conformation, it has been widely used in the thoracic aorta in Europe and Japan, and easy handling and better

healing has been expected. Higher porosity and the sealant gelatin that is hydrolyzed within approximately 14 days, have been reported advantageous for graft healing [1]. Therefore this graft should have, at least theoretically, a better healing property, and suboptimal tissue ingrowth can not be explained.

Several other factors may influence graft healing. Perigraft fluid collection can interfere with tissue ingrowth, which is common early after surgery and may be related to sealant resorption. Branched configuration of the graft may also block tissue ingrowth by preventing the graft surface from contacting with the surrounding tissue. In the abdominal aorta, late perigraft hematoma is reported common at the graft bifurcation [2]. Implant site is also a factor affecting graft healing [3], and tissue ingrowth in the mediastinum may not occur as readily as that in the retroperitoneum.

Several mechanisms may be possible to explain perigraft hemorrhage, which include anastomotic dehiscence, graft tear, and transgraft hemorrhage. In our patient, operative findings and examination of the explanted graft did not reveal anastomotic problem or graft tear, and transgraft hemorrhage was suggested. On CT scan, absence of contrast extravasation at peri-anastomotic area and patchy inhomogeneous enhancement within the hematoma may be characteristic.

Transgraft hemorrhage has been reported clinically after thrombolytic therapy,

predominantly with knitted grafts [4]. Because graft healing in humans consists of flow surface formation by compacted fibrin and incomplete tissue ingrowth from outside, graft imperviousness depends on the fibrin matrix and porosity of the fabric if tissue ingrowth is less than optimal. In such a situation, transgraft hemorrhage may occur by excessive fibrinolysis. In our patient, no tissue ingrowth was found in the area of hemorrhage. However, hemorrhage occurred spontaneously and laboratory examination did not reveal hyperfibrinolysis. Therefore involvement of such a mechanism remains speculative.

Alternatively, transgraft hemorrhage may occur as a result of graft dilation. This type of complication has been considered to be a form of structural graft failure [5]. Knitted grafts are known to dilate after implantation, and their use in the thoracic position may aggravate it, because the thoracic aorta has larger radius and consequently higher wall tension. In our case, however, graft dilation was uniform and not progressive after initial dilation. Because this graft has large crimp size, the external diameter, which is roughly equal to the in vivo size after flattening of the crimps, is about 20% larger than the labeled size. The extent of subsequent dilation thus seems around 10-15%. Such dilation is a usual finding in our experiences with this graft, and is consistent with a recent report with this graft [6]. Because hematoma became apparent after stabilization of the

graft diameter, dilation by itself is not enough to explain transgraft hemorrhage.

From these considerations, exact mechanism of perigraft hemorrhage remains uncertain.

However, suboptimal tissue ingrowth and use of a knitted graft seem underlying.

Because graft healing depends on complex graft-host relationships and cannot be predicted, we used a woven graft with lower porosity for reoperation, although healing of woven grafts is generally worse than that of knitted grafts.

We have implanted the Gelseal grafts in the thoracic aorta in about 400 cases, and such a complication was identified in one other case. In this patient, CT scan ten years after descending aortic replacement showed contrast extravasation that was similar to the reported case. However, other mechanisms of hemorrhage could not be completely ruled out because the patient underwent stent grafting and the graft was not explanted.

Although such a complication has not been reported, it may be explained by difference in the follow-up protocol. We routinely perform yearly follow-up CT scan. Our patient was asymptomatic, and the hematoma would have never been found if referral-based follow-up had been used. Although clinical significance of such asymptomatic contrast extravasation has been doubted and conservative management has been advocated [4], previously reported cases developed hematoma after thrombolytic therapy, and hemostasis can thus be expected after its cessation. We chose to treat our patients

surgically, because the hematoma developed spontaneously and enlarged progressively.

Surgeons must be aware of this complication and we advocate careful long-term

follow-up.

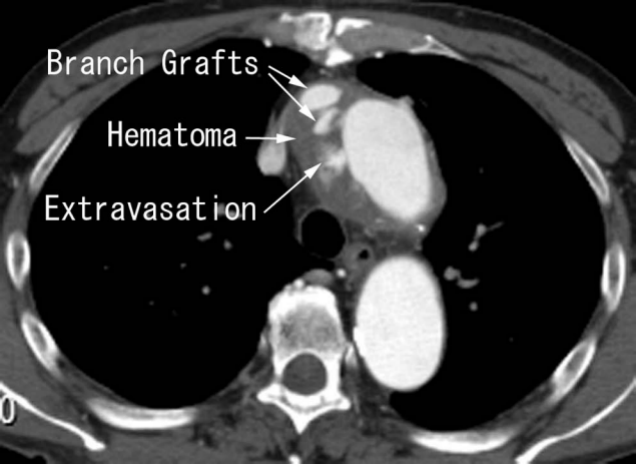
Figure Legends

Figure 1. Computed tomography showing perigraft hematoma and contrast extravasation on the right dorso-lateral aspects of the graft near the origin of the branch grafts.

Figure 2. Scanning electron microscopy of the portion of explanted graft without external encapsulation.

References




1. Jonas RA, Ziemer G, Schoen FJ, Britton L, Castaneda AR. A new sealant for knitted Dacron prostheses: minimally cross-linked gelatin. *J Vasc Surg* 1988;7:414-9.
2. Kalman PG, Rappaport DC, Merchant N, Clarke K, Johnston KW. The value of late computed tomographic scanning in identification of vascular abnormalities after abdominal aortic aneurysm repair. *J Vasc Surg* 1999;29:442-50.
3. Wu MH, Shi Q, Kouchi Y, Onuki Y, Ghali R, Yoshida H, Kaplan S, Sauvage LR. Implant site influence on arterial prosthesis healing: a comparative study with a triple implantation model in the same dog. *J Vasc Surg* 1997;25:528-36.
4. Pope M, Kalman PG. Aortic transgraft hemorrhage after systemic thrombolytic therapy. *Ann Vasc Surg* 1997;11:292-4.
5. Nunn DB. Structural failure of Dacron arterial grafts. *Semin Vasc Surg* 1999;12:83-91.
6. Mattens E, Engels P, Hamerlijnc R, Kelder J, Schepens M, de Valois J, Vermeulen F, Wijers L. Gelseal versus Gelweave dacron prosthetic grafts in the descending thoracic aorta: a two-year computed tomography scan follow-up study. *Cardiovasc Surg* 1999;7:432-5.



Branch Grafts

Hematoma

Extravasation



x100	x400
x1000	