



Title	Extracellular matrix metalloproteinase inducer in interstitial pneumonias.
Author(s)	Odajima, Nao; Betsuyaku, Tomoko; Nasuhara, Yasuyuki; Itoh, Tomoo; Fukuda, Yuh; Senior, Robert M.; Nishimura, Masaharu
Citation	Human Pathology, 37(8), 1058-1065 https://doi.org/10.1016/j.humpath.2006.03.006
Issue Date	2006-08
Doc URL	http://hdl.handle.net/2115/14651
Type	article (author version)
File Information	HP2006-37-8.pdf



[Instructions for use](#)

Elsevier Editorial System(tm) for Human Pathology

Manuscript Draft

Manuscript Number: YHUPA-D-06-00010R1

Title: Extracellular Matrix Metalloproteinase Inducer in Interstitial Pneumonias

Article Type: Original Article

Keywords: matrix metalloproteinases; bronchiolization; squamous metaplasia; basigin; CD147

Corresponding Author: Dr. Tomoko Betsuyaku, PhD, MD

Corresponding Author's Institution: Hokkaido university school of medicine

First Author: Nao Odajima, MD

Order of Authors: Nao Odajima, MD; Tomoko Betsuyaku, PhD, MD; Yasuyuki Nasuhara, PhD, MD; Tomoo Itoh, MD, PhD; Yuh Fukuda, PhD, MD; Robert M Senior, MD; Masaharu Nishimura, PhD, MD

Abstract: Extracellular matrix metalloproteinase inducer (EMMPRIN), a glycosylated transmembrane protein that induces matrix metalloproteinases (MMPs), is minimally expressed in the normal adult lung. We previously reported that it is upregulated in murine bleomycin-induced lung injury. In this study, we determined the expression of EMMPRIN and its association with MMPs-2, -7, and -9 in interstitial pneumonias (IPs). We performed immunohistochemistry for EMMPRIN and MMPs on lung tissue from 22 subjects with various IPs. We did bronchoalveolar lavage (BAL) on 9 of these subjects and 13 others with IPs to measure the soluble EMMPRIN in BAL fluid. For comparison, immunohistochemistry or BAL was done on 14 subjects without IPs. The staining intensity for each protein was scored from 0 to 3 in various epithelial cell types. Soluble EMMPRIN in BAL fluid was measured by an enzyme-linked immunosorbent assay. EMMPRIN was prominent in abnormal epithelial cells. It was more prominent in hyperplastic type II cells compared to epithelium in alveolar bronchiolization. It was also elevated in BAL fluid from the subjects with IPs. MMPs were expressed in cells expressing EMMPRIN, although the profile of MMPs varied among the different abnormal epithelial cell types with MMP-2 and MMP-7 in hyperplastic type II cells and MMP-7

and MMP-9 in cells showing squamous metaplasia and cells comprising bronchiolization. These results suggest a role of EMMPRIN in reepithelialization in IPs.

Dr. Ricardo V. Lloyd
Editor in Chief
Human Pathology
8-March-2006

Ms. Ref. No.: YHUPA-D-06-00010

Thank you for the review of our manuscript, "Extracellular Matrix Metalloproteinase Inducer in Interstitial Pneumonias". We appreciate the constructive comments from you and the reviewers. We are pleased to enclose a revised manuscript, marked version of the manuscript and point-by-point responses to the comments of the reviewers.

In the revised manuscript, we added a new table (labeled Table 2) according to the suggestion of reviewer 2. That table demonstrates that we have analyzed the three histological patterns of IPs, UIP, NSIP, and OP, separately. While the present findings do not point to mechanisms for EMMPRIN induction in IPs or a role of EMMPRIN in the development of IPs, we speculate that EMMPRIN affects reepithelialization in IPs via its capacity to induce the expression of MMPs, particularly in hyperplastic type II cells. We feel that the manuscript has been improved as a result of the review process and look forward to a favorable response to this revision.

Thank you for your attention.

Sincerely,

Tomoko Betsuyaku, M.D., Ph.D.

POINT-BY-POINT RESPONSE

Reviewer: 1

Reviewer #1:

General Comments:

The authors examined the expression of extracellular matrix metalloproteinase inducer (EMMPRIN) and matrix metalloproteinases (MMPs) -2, -7, and -9 in interstitial pneumonias (IPs) and normal lung tissue, using immunohistochemistry. In IPs, increased immunoreactivity for EMMPRIN and MMPs was detected in hyperplastic Type II cells, squamous metaplasia, and "bronchiolization". Soluble EMMPRIN was also elevated in bronchoalveolar lavage (BAL) fluid from patients with IPs. The authors concluded: "These results suggest a functional role of EMMPRIN in IPs" (Abstract, page 2).

The problem with this study is that the authors lump usual interstitial pneumonia, nonspecific interstitial pneumonia, and organizing pneumonia together as IPs. Although it is true that each of the three histological patterns can be classified as an IP, they are a very diverse group and their pathogeneses are most likely different. Therefore, for scientific purposes they should be analyzed separately. The data presented in the manuscript do not suggest a functional role of EMMPRIN in IPs. It merely indicates that reactive epithelial cells of all kinds may overexpress EMMPRIN.

Otherwise, the scientific methods appear to be valid, the manuscript is well written, and the figures are of acceptable quality.

We appreciate the reviewer's comments. According to the reviewer's suggestions, we have added new data demonstrating the individual scores for each type of abnormal epithelial cells and analyzed them in UIP, NSIP and OP, separately (new Table 2 in the revised manuscript). To reflect this change we have revised the manuscript as follows:

“Neither squamous metaplasia nor bronchiolization was observed in OP. Only hyperplastic type II cells were present, and these cells expressed EMMPRIN to various degrees. Accordingly, we evaluated EMMPRIN only in UIP and NSIP. There were no statistical differences in the score of EMMPRIN in each type of epithelial cells between UIP and NSIP. Therefore, we compared the immunoreactive scores for EMMPRIN between each type of hyperplastic epithelial cell in UIP and NSIP together.” (page 9, line 17)

“We assessed the immunohistochemical localization and scored the degree of intensity for MMP-2, MMP-7 and MMP-9 in each type of abnormal epithelial cells in UIP and NSIP, together.” (page 10, line 14 in the revised manuscript).

We agree that the data presented in the manuscript do not present a functional role of EMMPRIN in IPs. Accordingly, we have revised the last sentence in the abstract to read.

“These results suggest a role of EMMPRIN in reepithelialization in IPs.”(page2, line1).

We also added some additional comments in the conclusion in the text as follows.

“While the present findings do not point to mechanisms for EMMPRIN induction in IPs or a role of EMMPRIN in the development of IPs, we speculate that EMMPRIN affects reepithelialization in IPs via its capacity to induce the expression of MMPs that influence epithelial cell migration, particularly in hyperplastic type II cells.”(page15, line9).

Specific Recommendations:

Subjects for Immunohistological Studies (page 5): The study population should be further detailed. The authors should mention if these cases were idiopathic or there

were associated conditions (e.g. connective tissue disease).

In the revised version, the following was added in the materials and methods.

“For immunohistochemistry, the study population consisted of 22 patients with IP; 9 with UIP (all idiopathic), 9 with NSIP (3 SJS, 1 PM/DM) and 4 with OP (1 PM/DM).” (page 5, line 18).

Subjects for Analysis of EMMPRIN in BAL Fluid (page 6): The authors collected BAL fluid from patients with UIP and NSIP "who were clinically and/or pathologically diagnosed". What were the clinical criteria for UIP and NSIP? (Probable UIP can be diagnosed by high resolution computer tomography, but it would be very unusual to diagnose NSIP without pathological confirmation.)

To clarify the characteristics of the subjects for analysis of EMMPRIN in BAL fluid we have revised the manuscript as follows;

“We collected BAL fluids from 22 IP subjects who were diagnosed as UIP (n=13), including 3 pathological UIP, and pathological NSIP (n=9).” (page 6, line 9)

As recommended by the reviewer, we have added the following description of procedures for the method for diagnosis of UIP and NSIP in the revised manuscript.

“In each subject the diagnosis was based on standard clinical criteria and histopathological study (14). Measurements of vital capacity, forced expiratory volume in 1 second, and diffusing capacity for carbon monoxide were performed on all the subjects (CHESTAC-55V; Chest Co., Tokyo, Japan). High-resolution computed tomography scans, arterial blood gas analysis, and serum Krebs von den Lungen-6 measurements (21) were also performed for all the subjects.” (page 5, line 8)

Quantification of Immunohistochemistry (page 6): The authors used a semi-quantitative scoring system. The term "Quantification" is misleading.

According to the reviewer's suggestion, “Quantification of Immunohistochemistry” has been changed into “Semi-quantification of Immunohistochemistry” in the revised manuscript. (page 7, line 4 in the revised manuscript)

Reviewer #2: The authors report the measurement of EMMPRIN in BAL and its localization in lung as well as the localization of MMPs 2, 7, and 9 in interstitial pneumonias. The work is interesting but raises some major concerns.

Major comments:

1. The manuscript is mostly descriptive and immunolocalization of MMP2, 7, and 9 in epithelial cells in idiopathic interstitial pneumonias has been widely documented: Am J Pathol 149: 1241, 2006; Lab Invest 78: 687, 1998; Am J Physiol Lung Cell Mol Physiol 279: L562, 2000; Am J Respir Crit Care Med, 162: 1949, 2000; Proc Natl Acad Sci 99: 6292, 2002; PLoS Med 2:e251. 2005.

As the reviewer pointed out, the role of MMPs in IP lungs has been investigated for a number of years. We have added another recent paper to our references:

<18> **Pardo A**, Gibson K, Cisneros J, Richards TJ, Yang Y, Becerril C, Yousem S, Herrera I, Ruiz V, Selman M, Kaminski N. Up-Regulation and Profibrotic Role of Osteopontin in Human Idiopathic Pulmonary Fibrosis. PLoS Medicine 2005; 2:e251.

However, we wish to emphasize that our study is novel in that we focused on the expression of EMMPRIN, which has the capacity to stimulate production of MMPs in various types of abnormal epithelial cells in IP lungs. To our knowledge, our study is the first to examine EMMPRIN in IPs and also the first to assess MMPs in relation to EMMPRIN in IPs.

2. The staining intensity is not a good method to score the proteins. It is well known that in any immunostaining experiment there are differences in the intensity from slide to slide and even in different areas of the same slide.

We agree with the reviewer that there is a limitation in the method of visual scoring the immunointensity in general. To determine the variation by a single observer, the scoring of the immunointensity was performed twice in a blind manner. Pearson's correlation coefficients between the two observations were 0.91 ($p < 0.0001$) for EMMPRIN, 0.97 ($p < 0.0001$) for MMP-2, 1.0 for MMP-7, and 0.98 ($p < 0.0001$) for MMP-9, respectively. Thus, only the latter data set is demonstrated. The following sentences have been added in the revised manuscript.

“Scoring was performed in a blind manner twice, in which the observer (N. O.) was unaware of the clinical details of the subjects. Based on the good Pearson's correlation coefficients between the two observations; 0.91 ($p < 0.0001$) for EMMPRIN, 0.97 ($p < 0.0001$) for MMP-2, 1.0 for MMP-7, and 0.98 ($p < 0.0001$) for MMP-9, only the latter data set is presented.” (page 7, line 13)

“Statistical analysis was performed by single factor analysis of variance, and Fisher's protected least significant difference test was applied as a *post hoc* test for multiple comparisons, while Student's unpaired *t*-test was used for comparisons between two groups and Pearson's correlation coefficients were calculated to assess the test-retest reliability (StatView J 5.0, SAS Institute Inc., Cary, NC).” (page 8, line 8)

3. The authors propose that EMMPRIN may be involved in alveolar reepithelialization via MMP however, this association is based only by their localization and is mainly speculative.

We agree with the reviewer's comment. Accordingly, we have revised the last sentence in the abstract to read.

“These results suggest a role of EMMPRIN in reepithelialization in IPs.”(page2, line1).

We also added some additional comments in the conclusion in the text as follows.

“While the present findings do not point to mechanisms for EMMPRIN induction in IPs or a role of EMMPRIN in the development of IPs, we speculate that EMMPRIN affects reepithelialization in IPs via its capacity to induce the expression of MMPs that influence epithelial cell migration, particularly in hyperplastic type II cells.”(page15, line9).

We hope that additional studies will be undertaken to evaluate the functional role of EMMPRIN in IPs.

4. This manuscript would be greatly enriched if the authors analyze the expression of MMPs in the EMMPRIN-deficient mice.

We agree and this thought led to our comment about EMMPRIN-deficient mice in the original manuscript (page 15, line 3). The findings of this study have prompted us to begin investigations of the role of EMMPRIN in the induction of MMPs as well as in the pathogenesis of fibrosis using EMMPRIN-deficient mice. We think, however, that these studies are beyond the scope of the present report.

Minor comments:

In the Introduction line 12 it should say in vitro instead of in vivo.

As recommended we have corrected “in vitro” in the revised manuscript (page 3, line 13).

Extracellular Matrix Metalloproteinase Inducer in Interstitial Pneumonias

Nao Odajima¹, Tomoko Betsuyaku¹, Yasuyuki Nasuhara¹, Tomoo Itoh², Yuh Fukuda³,
Robert M. Senior⁴, Masaharu Nishimura¹

¹First Department of Medicine, ²Department of Surgical Pathology, Hokkaido University Hospital, Sapporo, ³Department of Analytic Human Pathology, Nippon Medical School, Tokyo, and ⁴Departments of Medicine, and Cell Biology & Physiology, Washington University School of Medicine, St. Louis, MO

Correspondence: Tomoko Betsuyaku, M.D., Ph.D.

First Department of Medicine Hokkaido University School of Medicine, N-15, W-7,
Kita-ku, Sapporo, Japan, 060-8638. E-mail: bytomoko@med.hokudai.ac.jp

Fax: +81-11-706-7899; Phone: +81-11-706-5911

Key Words: matrix metalloproteinases; bronchiolization; squamous metaplasia;

basigin; CD147

This research was supported by the Respiratory Failure Research Group of the Ministry of Health, Labor, and Welfare of Japan to M.N., and by grants from the Ministry of Education, Science, Culture, and Sports of Japan (14570532) to T.B., and NIH/NHLBI HL47328 and the Alan A. and Edith L. Wolff Charitable Trust to R.M.S.

ABSTRACT

Extracellular matrix metalloproteinase inducer (EMMPRIN), a glycosylated transmembrane protein that induces matrix metalloproteinases (MMPs), is minimally expressed in the normal adult lung. We previously reported that it is upregulated in murine bleomycin-induced lung injury. In this study, we determined the expression of EMMPRIN and its association with MMPs-2, -7, and -9 in interstitial pneumonias (IPs). We performed immunohistochemistry for EMMPRIN and MMPs on lung tissue from 22 subjects with various IPs. We did bronchoalveolar lavage (BAL) on 9 of these subjects and 13 others with IPs to measure the soluble EMMPRIN in BAL fluid. For comparison, immunohistochemistry or BAL was done on 14 subjects without IPs. The staining intensity for each protein was scored from 0 to 3 in various epithelial cell types. Soluble EMMPRIN in BAL fluid was measured by an enzyme-linked immunosorbent assay. EMMPRIN was prominent in abnormal epithelial cells. It was more prominent in hyperplastic type II cells compared to epithelium in alveolar bronchiolization. It was also elevated in BAL fluid from the subjects with IPs. MMPs were expressed in cells expressing EMMPRIN, although the profile of MMPs varied among the different abnormal epithelial cell types with MMP-2 and MMP-7 in hyperplastic type II cells and MMP-7 and MMP-9 in cells showing squamous

metaplasia and cells comprising bronchiolization. These results suggest a role of EMMPRIN in reepithelialization in IPs.

Abbreviations

BAL, bronchoalveolar lavage

CVD, collagen vascular disease

EGF, epidermal growth factor

ELISA, enzyme-linked immunosorbent assay

EMMPRIN, extracellular matrix metalloproteinase inducer

IP, interstitial pneumonia

KL-6, krebs von den lungen-6

MMP, matrix metalloproteinase

NSIP, nonspecific interstitial pneumonia

OP, organizing pneumonia

PM/DM, polymyositis/dermatomyositis

TGF- β , transforming growth factor- β

SjS, Sjögren's syndrome

UIP, usual interstitial pneumonia

INTRODUCTION

Extracellular matrix metalloproteinase inducer (EMMPRIN) is a highly glycosylated protein of 43-66 kD with a protein core of ~27 kD, that has been identified as a member of the immunoglobulin superfamily (1, 2). It is also known as CD147 and M6 in humans, HT7, neurothelin and 5A11 in chickens, gp42 and basigin in mice, and OX-47 and CE9 in rats, and the molecule must be glycosylated to be functional (3). EMMPRIN is strongly expressed in fetal lung epithelium (4, 5), which suggests a physiologic role in development. Although it is essentially absent in normal adult lungs (6) and most other adult tissues, upregulation has been reported in diverse human pathologic processes, such as myocardial fibrosis, hepatitis C virus-associated cirrhotic liver (7), and chronic smokers' lung (6), as well as in various malignant tumors (8). A defined property of EMMPRIN is its capacity to stimulate production of matrix metalloproteinases (MMPs) by mesenchymal cells in vitro, including MMP-1 (interstitial collagenase), MMP-2 (gelatinase A), MMP-3 (stromelysin-1) (9, 10), MMP-9 (gelatinase B) (11) and membrane type 1-MMP (MMP-14) (12).

Interstitial pneumonias (IPs) are a heterogeneous group of chronic, fibrosing lung disorders, in which primary injury to the epithelium and basement membrane or secondary injury to these structures due to persistent inflammation leads to migration of

fibroblasts and myofibroblasts into air spaces with deposition of extracellular matrix. The term IPs encompasses situations in which the fibrosing process is associated with a known condition is present such as collagen vascular disease (CVD), environmental or drug-induced exposure, or when it arises without a known association and then is designated idiopathic pulmonary fibrosis. Pathologically, the patterns of IPs have been classified as usual interstitial pneumonia (UIP), nonspecific interstitial pneumonia (NSIP) and organizing pneumonia (OP), in addition to other classifications (13). UIP appears to be the result of abnormal wound-healing, with features of progressive extracellular matrix accumulation, decreased fibroblast-myofibroblast cell death, epithelial cell apoptosis and abnormal reepithelialization, and epithelial to mesenchymal transition, leading to irreversible pulmonary structural remodeling. MMPs, such as MMP-2, MMP-7 (matrilysin) and MMP-9, are expressed in hyperplastic epithelial cells in distorted parenchymal areas in human IPs (14-18); however, the mechanisms that are involved in their upregulation in IPs have not been fully elucidated.

We previously reported that EMMPRIN is expressed by bronchiolar epithelium in bleomycin-induced lung injury in mice (19). These findings suggested to us the possibility that EMMPRIN might be upregulated in IPs and might have a role in the upregulation of MMPs in IPs. The aims of this study were to assess the

immunohistochemical localization of EMMPRIN in IPs and to assess its relationship to MMPs. To further assess EMMPRIN expression in IPs we quantified soluble EMMPRIN levels in bronchoalveolar lavage (BAL) fluids from IP patients.

MATERIALS AND METHODS

Two groups of subjects were studied, one group for histological analysis and the other for analysis of EMMPRIN in BAL fluid. There was overlap between the groups in that 1 UIP and 8 NSIP subjects were in both groups. In each subject the diagnosis was based on standard clinical criteria and histopathological study (13). Measurements of vital capacity, forced expiratory volume in 1 second, and diffusing capacity for carbon monoxide were performed on all the subjects (CHESTAC-55V; Chest Co., Tokyo, Japan). High-resolution computed tomography scans, arterial blood gas analysis, and serum Krebs von den Lungen-6 measurements (21) were also performed for all the subjects. Informed consent was obtained from each subject, and the Ethics Committee of Hokkaido University approved the study protocols.

Subjects for Immunohistological Studies

For immunohistochemistry, the study population consisted of 22 subjects with

IP; 9 with UIP (all idiopathic), 9 with NSIP (3 SjS, 1 PM/DM) and 4 with OP (1 PM/DM). The diagnosis of each subject was based on standard histopathological analyses of lung tissues obtained by video-assisted thoracoscopy-guided lung biopsy or surgical lobectomy. The control lung specimens were obtained from 7 nonsmokers (all female, 65 ± 3 yrs) who underwent lung lobectomy for small peripheral tumors.

Subjects for Analysis of EMMPRIN in BAL Fluid

BAL was performed in a lung segment demonstrating disease radiographically. We collected BAL fluids from 22 IP subjects who were diagnosed as UIP (n=13), including 3 pathological UIP, and pathological NSIP (n=9). BAL fluids from seven age-matched nonsmoking volunteers served as controls, which had been used in a previous study (6).

Immunohistochemistry

Immunohistochemistry was performed as described previously (6). Primary antibodies were anti-human EMMPRIN monoclonal antibody (clone 1G6.2, Chemicon, Temecula, CA) at 1:1,000, mouse anti-human MMP-2 monoclonal antibody (clone 42-5D11, Daiichi Fine Chemical, Toyama, Japan) at 1:250, mouse anti-human MMP-7

monoclonal antibody (Clone ID2, NeoMarkers, Fremont, CA) at 1:500, and mouse anti-human MMP-9 monoclonal antibody (Clone 56-2A4, Chemicon) at 1:250.

Semi-Quantification of Immunohistochemistry

Because of the heterogeneity in amount and distribution of abnormal appearing epithelial cells (hyperplastic type II cells, squamous metaplasia and bronchiolization) within the lungs, the immunostained tissue sections from one block per subject were thoroughly investigated to find more than one group of cells for each cell type. Staining intensities for EMMPRIN, MMP-2, MMP-7 and MMP-9 expression were then scored for each cell type at the same magnification using a visual scoring method with grades ranging from 0 to 3 (0 = no staining; 1 = moderate staining; 2 = intense staining; 3 = very intense staining), as previously described (20). We evaluated co-localization of EMMPRIN with MMPs on serial sections from the same tissue block. Scoring was performed in a blind manner twice, in which the observer (N. O.) was unaware of the clinical details of the subjects. Based on the good Pearson's correlation coefficients between the two observations; 0.91 ($p < 0.0001$) for EMMPRIN, 0.97 ($p < 0.0001$) for MMP-2, 1.0 for MMP-7, and 0.98 ($p < 0.0001$) for MMP-9, only the latter data set is presented.

Quantification of EMMPRIN in BAL Fluid

The concentration of EMMPRIN in BAL fluid was determined by an enzyme-linked immunosorbent assay (ELISA) as previously described (6). All assays were performed in duplicate and mean values were used.

Statistical Analysis

Results are expressed as mean \pm standard error of the mean (SEM). Statistical analysis was performed by single factor analysis of variance, and Fisher's protected least significant difference test was applied as a *post hoc* test for multiple comparisons, while Student's unpaired *t*-test was used for comparisons between two groups and Pearson's correlation coefficients were calculated to assess the test-retest reliability (StatView J 5.0, SAS Institute Inc., Cary, NC). $P < 0.05$ was considered statistically significant.

RESULTS

Characteristics of Subjects for Immunohistochemical study

Clinical characteristics of the IP subjects are summarized in Table 1. The mean interval between onset of symptoms and pathological diagnosis was 12.9 months

(UIP; 5.1 months, NSIP; 24.4 months, OP; 4.5 months). One OP subject was receiving inhaled corticosteroid therapy and two NSIP subjects were taking oral corticosteroids. There were no significant differences in age, pulmonary function, serum Krebs von den Lungen-6 (KL-6) level or arterial blood gas values among the subjects with UIP, NSIP and OP.

Immunohistochemical Analysis of EMMPRIN

EMMPRIN was barely detectable in the airway and alveolar epithelium in normal lung tissues, and was only weakly expressed in alveolar macrophages in the lungs of the control subjects (Fig. 1A). In IP lungs, EMMPRIN was intensely expressed by the various types of epithelial cells lining the abnormal airspaces, such as hyperplastic type II cells, squamous metaplasia and bronchiolization, as well as in alveolar macrophages (Fig. 1B-D). However, it was barely detected in fibroblast foci and interstitial fibroblasts.

Because EMMPRIN was markedly expressed by abnormal epithelial cells in IP lungs, the immunoreactive intensity of EMMPRIN was scored for each type of epithelial cell (Table 2). Neither squamous metaplasia nor bronchiolization was observed in OP. Only hyperplastic type II cells were present, and these cells expressed

EMMPRIN to various degrees. Accordingly, we evaluated EMMPRIN only in UIP and NSIP. There were no statistical differences in the EMMPRIN score in each type of epithelial cell between UIP and NSIP. Therefore, we compared the immunoreactive scores for EMMPRIN between each type of hyperplastic epithelial cell in UIP and NSIP together. Because there were no differences in staining scores for EMMPRIN between non-ciliated and ciliated bronchiolization (2.4 ± 0.2 vs. 2.0 ± 0.2 , NS), the staining score for EMMPRIN in bronchiolization was averaged for both cell types. The EMMPRIN staining score was significantly higher in hyperplastic type II cells when compared with bronchiolization (2.8 ± 0.1 vs. 2.2 ± 0.1 , $p < 0.05$). However, the staining scores did not differ between hyperplastic type II cells and squamous metaplasia (2.8 ± 0.1 vs. 2.5 ± 0.1 , NS) (Fig. 3A).

Expression of MMPs in Diverse Abnormal Epithelial Cells

We assessed the immunohistochemical localization and scored the degree of intensity for MMP-2, MMP-7 and MMP-9 in each type of abnormal epithelial cells in UIP and NSIP together. MMP-2 expression was most prominent in hyperplastic type II cells when compared with the other types of hyperplastic epithelium (2.4 ± 0.1 vs. 1.6 ± 0.2 and 1.5 ± 0.2 , respectively, $p < 0.05$) (Figs. 2A-C and 3B). In contrast, expression

of MMP-9 was marked in squamous metaplasia and bronchiolization, but only weakly detected in hyperplastic type II cells (1.9 ± 0.2 and 2.1 ± 0.2 vs. 1.4 ± 0.1 , respectively, $p < 0.05$) (Figs. 2D-F and 3C). MMP-7 was strongly and comparably expressed in hyperplastic type II cells, squamous metaplasia and bronchiolization (2.5 ± 0.2 , 2.4 ± 0.2 and 2.4 ± 0.2 , respectively) (Figs. 2G-I and 3D).

EMMPRIN in BAL Fluids

The mean interval between onset of symptoms and collection of BAL fluids was 20.8 months (UIP; 13.9 months, NSIP; 27.6 months). BAL was performed in subjects at steady state, except for 2 UIP and 1 NSIP subjects, who were in acute exacerbation. One UIP subject and 3 NSIP subjects were undergoing oral corticosteroid therapy. Total number of cells and differential cell counts in BAL fluid are summarized in Table 3. Total cell number and percentage of neutrophils were significantly elevated in IP subjects when compared with normal controls. EMMPRIN levels were significantly elevated in BAL fluid from IP subjects when compared with BAL fluids from control subjects (152.8 ± 14.3 pg/ml vs. 81.3 ± 9.7 , $p < 0.05$). Among the IP subjects, there were no significant differences in EMMPRIN levels in BAL fluid between UIP and NSIP (152.2 ± 19.9 pg/ml vs. 153.7 ± 21.3 , NS) (Fig. 4). There were

no significant differences between nonsmokers, former smokers and current smokers among the subjects with IP (179.4 ± 19.8 pg/ml, 113.4 ± 26.4 and 154.7 ± 24.1 , respectively, NS) (data not shown).

DISCUSSION

In this study, we have observed the prominent expression of EMMPRIN in abnormal lung epithelial cells in diverse IPs with differences in intensity in different epithelial cell types. The expression was more prominent in hyperplastic type II cells compared to epithelium in alveolar bronchiolization (Table 4). We have also observed MMPs in those abnormal epithelial cells. However, the profiles of MMPs also vary between different epithelial cell types and match previous reports of MMPs in IPs (14-18).

Furthermore, we found that EMMPRIN levels were significantly elevated in BAL fluid in IPs, but did not correlate with the different histological types of IPs. Although smoking is associated with elevated EMMPRIN in BAL fluid (6), the elevation of EMMPRIN in BAL fluid in IP subjects was not due to smoking. Because EMMPRIN is increased in IPs with unfavorable as well as favorable prognosis it does not appear that EMMPRIN in BAL fluid can be used as a prognostic indicator. The

molecular basis for the release of EMMPRIN from lung epithelial cells is uncertain. However, release of soluble EMMPRIN by tumor cells was reported to involve MMP-dependent cleavage (22). Alternatively, microvesicle shedding might occur. EMMPRIN release from tumor cell has been amplified by 4 beta-phorbol 12-myristate 13-acetate, an analogue of diacylglycerol, suggesting a signaling cascade responsible for EMMPRIN release (23).

Although the present study clearly demonstrates upregulation of EMMPRIN in abnormal lung epithelial cells in IPs, the mechanisms for upregulation are not yet established. Caveolin-1, an integral membrane protein, oligomerizes and plays a central role in the formation of the flask-shaped membrane structures known as caveolae (24), and controls self-aggregation of EMMPRIN (25, 26). Transforming growth factor- β (TGF- β) and epidermal growth factor (EGF) upregulate EMMPRIN expression in corneal epithelial cells (27) and human breast epithelial cells in vitro (28). Considering that these growth factors are associated with IPs (29), it seems reasonable to speculate that TGF- β and EGF may affect the expression of EMMPRIN in IPs. Interestingly, beta-catenin, a key regulatory protein of the Wnt signaling pathway, may be involved in EMMPRIN expression, as EMMPRIN is co-localized with beta-catenin on the plasma membranes of hepatocytes and biliary epithelium in hepatitis C

virus-associated liver injury (7). Taken together, it appears likely that the release and expression of EMMPRIN in IPs is affected by a variety of factors.

Repair of epithelium after injury is an important step in normal wound-healing processes, such as in IPs (30, 31). It is uncertain whether the appearance of abnormal epithelial cells protects against or promotes fibrosis (32). We have reported that MMP-9 is required for alveolar bronchiolization, probably by facilitating migration of Clara cells and other bronchiolar cells into regions of alveolar injury in mice (33). Recent studies report MMP-7 in alveolar and bronchiolar epithelial cells in various types of pulmonary fibrosis (18), and that mice with MMP-7 deficiency resist development of pulmonary fibrosis in response to intratracheal bleomycin (17). According to previous reports showing the expression of MMP-1 in hyperplastic epithelial cells and alveolar macrophages in IPs (16, 17, 29), it is also speculated to be co-localized with EMMPRIN in those cells. Taken together, our findings suggest that EMMPRIN may be involved in reepithelialization in IPs via effects on MMP expression in various types of abnormal epithelial cells. Alternatively, EMMPRIN upregulation may simply reflect a response to another underlying pathologic mechanism, including reepithelialization. Possible mechanisms underlying EMMPRIN-mediated MMP induction have been uncovered in carcinoma cells (8). Homophilic interactions

between EMMPRIN molecules on the plasma membranes of cells (34) or heterophilic interactions between EMMPRIN molecules and a putative receptor on different cells (10) may induce MMPs. To elucidate the role of EMMPRIN in induction of MMPs in alveolar injury and fibrosis we are studying EMMPRIN-deficient mice (35).

In summary, lungs affected by IPs show EMMPRIN which is not present in normal lung. Cells expressing EMMPRIN co-express MMPs, but the profile of MMPs varies between different epithelial cell types. The increase in EMMPRIN expression in abnormal epithelial cells is reflected by increased levels of soluble EMMPRIN in BAL fluid. While the present findings do not point to mechanisms for EMMPRIN induction in IPs or a role of EMMPRIN in the development of IPs, we speculate that EMMPRIN affects reepithelialization in IPs via its capacity to induce the expression of MMPs that influence epithelial cell migration, particularly in hyperplastic type II cells.

Acknowledgments

We would like to thank Ms. Yoko Suzuki for technical assistance with immunohistochemistry and ELISA.

References

1. Miyauchi T, Kanekura T, Yamaoka A, Ozawa M, Miyazawa S, Muramatsu T. Basigin, a new, broadly distributed member of the immunoglobulin superfamily, has strong homology with both the immunoglobulin V domain and the beta-chain of major histocompatibility complex class II antigen. *J Biochem (Tokyo)* 1990;107:316-23.
2. Biswas C, Zhang Y, DeCastro R, Guo H, Nakamura T, Kataoka H, Nabeshima K. The human tumor cell-derived collagenase stimulatory factor (renamed EMMPRIN) is a member of the immunoglobulin superfamily. *Cancer Res* 1995;55:434-439.
3. Kanekura T, Miyauchi T, Tashiro M, Muramatsu T. Basigin, a new member of the immunoglobulin superfamily: genes in different mammalian species, glycosylation changes in the molecule from adult organs and possible variation in the N-terminal sequences. *Cell Struct Funct* 1991;16:23-30.
4. Fan QW, Kadomatsu K, Uchimura K, Muramatsu T. Embigin/Basigin subgroup of the immunoglobulin superfamily: different modes of expression during mouse embryogenesis and correlated expression with carbohydrate antigenic markers. *Dev Growth Differ* 1998;40:277-86.

5. Igakura T, Kadomatsu K, Kaname T, Muramatsu H, Fan QW, Miyauchi T, Toyama Y, Kuno N, Yuasa S, Takahashi M, Senda T, Taguchi O, Yamamura K, Arimura K, Muramatsu T. A null mutation in basigin, an immunoglobulin superfamily member, indicates its important roles in peri-implantation development and spermatogenesis. *Dev Biol* 1998;194:152-65.
6. Betsuyaku T, Tanino M, Nagai K, Nasuhara Y, Nishimura M, Senior RM. Extracellular matrix metalloproteinase inducer is increased in smokers' bronchoalveolar lavage fluid. *Am J Respir Crit Care Med* 2003;168:222-27.
7. Shackel NA, McGuinness PH, Abbott CA, Gorrell MD, McCaughan GW. Insights into the pathobiology of hepatitis C virus-associated cirrhosis: analysis of intrahepatic differential gene expression. *Am J Pathol* 2002;160:641-54.
8. Toole BP. Emmprin (CD147), a cell surface regulator of matrix metalloproteinase production and function. *Curr Top Dev Biol* 2003;54:371-89.
9. Kataoka H, DeCastro R, Zucker S, Biswas C. Tumor cell-derived collagenase-stimulatory factor increases expression of interstitial collagenase, stromelysin, and 72-kDa gelatinase. *Cancer Res* 1993;53:3154-8.
10. Guo H, Zucker S, Gordon MK, Toole BP, Biswas C. Stimulation of matrix metalloproteinase production by recombinant extracellular matrix

- metalloproteinase inducer from transfected Chinese hamster ovary cells. *J Biol Chem* 1997;272:24-7.
11. Zucker S, Hymowitz M, Rollo EE, Mann R, Conner CE, Cao J, Foda HD, Tompkins DC, Toole BP. Tumorigenic Potential of Extracellular Matrix Metalloproteinase Inducer. *Am J Pathol* 2001;158:1921-8.
 12. Sameshima T, Nabeshima K, Toole BP, Yokogami K, Okada Y, Goya T, Kono M, Wakisaka S. Glioma cell extracellular matrix metalloproteinase inducer (EMMPRIN)(CD147) stimulates production of membrane-type matrix metalloproteinases and activated gelatinase A in co-cultures with brain-derived fibroblasts. *Cancer Lett* 2000;157:177-84.
 13. American Thoracic Society/European Respiratory Society International multidisciplinary consensus classification of the idiopathic interstitial pneumonias. *Am J Respir Crit Care Med* 2002;165:277-304.
 14. Hayashi T, Stetler-Stevenson WG, Fleming MV, Fishback N, Koss MN, Liotta LA, Ferrans VJ, Travis WD. Immunohistochemical study of metalloproteinases and their tissue inhibitors in the lungs of patients with diffuse alveolar damage and idiopathic pulmonary fibrosis. *Am J Pathol* 1996;149:1241-56.
 15. Suga M, Iyonaga K, Okamoto T, Gushima Y, Miyakawa H, Akaike T, Ando M.

- Characteristic elevation of matrix metalloproteinase activity in idiopathic interstitial pneumonias. *Am J Respir Crit Care Med* 2000;162:1949-56.
16. Fukuda Y, Ishizaki M, Kudoh S, Kitaichi M, Yamanaka N. Localization of matrix metalloproteinases-1, -2, and -9 and tissue inhibitor of metalloproteinase-2 in interstitial lung diseases. *Lab Invest* 1998;78:687-8.
17. Zuo F, Kaminski N, Eugui E, Allard J, Yakhini Z, Ben-Dor A, Lollini L, Morris D, Kim Y, DeLustro B, Sheppard D, Pardo A, Selman M, Heller RA. Gene expression analysis reveals matrilysin as a key regulator of pulmonary fibrosis in mice and humans. *Proc Natl Acad Sci USA* 2002;99:6292-7.
18. Pardo A, Gibson K, Cisneros J, Richards TJ, Yang Y, Becerril C, Yousem S, Herrera I, Ruiz V, Selman M, Kaminski N. Up-Regulation and Profibrotic Role of Osteopontin in Human Idiopathic Pulmonary Fibrosis. *PLoS Medicine* 2005; 2:e251.
19. Betsuyaku T, Kadomatsu K, Griffin GL, Muramatsu T, Senior RM. Increased basigin in bleomycin-induced lung injury. *Am J Respir Cell Mol Biol* 2003;28:600-6.
20. de Boer WI, Sont JK, van Schadewijk A, Stolk J, van Krieken JH, Hiemstra PS. Monocyte chemoattractant protein 1, interleukin 8, and chronic airways

- inflammation in COPD. *J Pathol* 2000;190:619-26.
21. Yokoyama A, Kohno N, Hamada H, Sakatani M, Ueda E, Kondo K, Hirasawa Y, Hiwada K. Circulating KL-6 predicts the outcome of rapidly progressive idiopathic pulmonary fibrosis. *Am J Respir Crit Care Med* 1998;158:1680-4.
22. Tang Y, Kesavan P, Nakada MT, Yan L. Tumor-stroma interaction: positive feedback regulation of extracellular matrix metalloproteinase inducer (EMMPRIN) expression and matrix metalloproteinase-dependent generation of soluble EMMPRIN. *Mol Cancer Res* 2004;2:73-80.
23. Sidhu SS, Mengistab AT, Tauscher AN, LaVail J, Basbaum C. The microvesicle as a vehicle for EMMPRIN in tumor-stromal interactions. *Oncogene* 2004;23:956-63.
24. Liu P, Rudick M, Anderson RGW. Multiple functions of caveolin-1. *J Biol Chem* 2002;277:41295-8.
25. Tang W, Hemler ME. Caveolin-1 regulates matrix metalloproteinases-1 induction and CD147/EMMPRIN cell surface clustering. *J Biol Chem* 2004;279:11112-8.
26. Tang W, Chang SB, Hemler ME. Links between CD147 function, glycosylation, and caveolin-1. *Mol Biol Cell* 2004;15:4043-50.
27. Gabison EE, Mourah S, Steinfels E, Yan L, Hoang-Xuan T, Watsky MA, Wever

- BD, Calvo F, Mauviel A, Menashi S. Differential expression of extracellular matrix metalloproteinase inducer (CD147) in normal and ulcerated corneas: role in epithelio-stromal interactions and matrix metalloproteinase induction. *Am J Pathol* 2005;166:209-19.
28. Menashi S, Serova M, Ma L, Vignot S, Mourah S, Calvo F. Regulation of extracellular matrix metalloproteinase inducer and matrix metalloproteinase expression by amphiregulin in transformed human breast epithelial cells. *Cancer Res* 2003;63:7575-80.
29. Selman M, Ruiz V, Cabrera S, Segura L, Ramirez R, Barrios R, Pardo A. TIMP-1, -2, -3, and -4 in idiopathic pulmonary fibrosis. A prevailing nondegradative lung microenvironment? *Am J Physiol Lung Cell Mol Physiol* 2000;279:L562-74.
30. Selman M, King TE Jr, Pardo A. Idiopathic pulmonary fibrosis: prevailing and evolving hypotheses about its pathogenesis and implications for therapy. *Ann Intern Med* 2001;134:136-51.
31. Fukuda Y, Ferrans VJ, Schoenberger CI, Rennard SI, Crystal RG. Patterns of pulmonary structural remodeling after experimental paraquat toxicity. The morphogenesis of intraalveolar fibrosis. *Am J Pathol* 1985;118:452-75.
32. Portnoy J, Mason RJ. Role of alveolar type II epithelial cells in pulmonary fibrosis.

- In: Lynch III JP, editor. Idiopathic Pulmonary Fibrosis. New York, NY: MARCEL DEKKER; 2004. p. 573-608.
33. Betsuyaku T, Fukuda Y, Parks WC, Shipley JM, Senior RM. Gelatinase B is required for alveolar bronchiolization after intratracheal bleomycin. *Am J Pathol* 2000;157:525-35.
34. Yoshida S, Shibata M, Yamamoto S, Hagihara M, Asai N, Takahashi M, Mizutani S, Muramatsu T, Kadomatsu K. Homo-oligomer formation by basigin, an immunoglobulin superfamily member, via its N-terminal immunoglobulin domain. *Eur J Biochem* 2000;267:4372-80.
35. Chen S, Kadomatsu K, Kondo M, Toyoma Y, Toshimori K, Ueno S, Miyake Y, Muramatsu T. Effects of flanking genes on the phenotypes of mice deficient in basigin/CD147. *BBRC* 2004;324:147-53.

Figure Legends

Fig. 1. Immunohistochemical localization of EMMPRIN

EMMPRIN is barely detectable in bronchiolar epithelial cells in airways in one of the controls (A). In UIP, hyperplastic type II cells (B, arrowheads) and squamous metaplasia (C, arrows) are strongly immunostained for EMMPRIN, and bronchiolization shows weaker-staining for EMMPRIN (D: non-ciliated type, arrows).

Original magnification, $\times 400$.

Fig. 2. Immunohistochemical localization of MMP-2, MMP-9 and MMP-7

MMP-2 is strongly detected in hyperplastic type II cells (A, arrowheads), but is weakly detected in squamous metaplasia (B, arrows) and bronchiolization (C, non-ciliated type, arrows) in UIP. MMP-2 deposition is also found in fibroblasts (C, *). MMP-9 is weakly detected in hyperplastic type II cells (D, arrowheads), while MMP-9 is strongly detected in squamous metaplasia (E, arrow) as well as in bronchiolization (F: non-ciliated type, arrow) in UIP. MMP-7 is strongly detected in hyperplastic type II cells (G, arrowheads) and squamous metaplasia (H, arrow). Non-ciliated bronchiolization (I, arrows) in UIP also shows strong immunoreactivity. Original magnification, $\times 400$.

Fig. 3. Expression of EMMPRIN, MMP-2, MMP-7 and MMP-9 in abnormal epithelial cells in IPs

Hyperplastic type II cells showed significantly higher expression of EMMPRIN when compared with bronchiolization ($p < 0.05$) (A). The staining score for MMP-2 was significantly higher in hyperplastic type II cells when compared with squamous metaplasia and bronchiolization ($p < 0.05$) (B), but that for MMP-9 was significantly higher in squamous metaplasia and bronchiolization when compared with hyperplastic type II cells ($p < 0.05$) (C). There were no significant differences among the diverse hyperplastic epithelial cells in staining score for MMP-7 (NS) (D). type II = hyperplastic type II cells, sq meta = squamous metaplasia, br = bronchiolization. *; $p < 0.05$ vs. hyperplastic type II cells.

Fig. 4. EMMPRIN in BAL fluid

EMMPRIN levels were significantly elevated in BAL fluid from IP subjects, as compared to control subjects ($p < 0.05$), but not different between UIP and NSIP (open circles, normal controls; closed circles, UIP; shaded circles, NSIP). *; $p < 0.05$ vs. controls.

Table1 Clinical Characteristics of IP patients for Immunohistological Study

	UIP	NSIP	OP
Number of subjects, female/male	9, 5/4	9, 8/1	4, 3/1
age, yr	64 ± 2	59 ± 5	49 ± 14
cigarette smoking, never/former/current	3/5/1	9/0/0	3/1/0
Pack-yr of cigarettes	34 ± 8	0	62
VC, % pred	93 ± 6	78 ± 6	90 ± 16
FEV ₁ /FVC, %	80 ± 2	83 ± 2	73 ± 6
D _{LCO} , % pred	73 ± 9	67 ± 7	78 ± 12
serum KL-6, U/ml	769 ± 110	1738 ± 362	585 ± 294
PaO ₂ , torr	85 ± 3	78 ± 6	79 ± 5
A-aDO ₂ , torr	14 ± 2	18 ± 5	22 ± 3
CVD-IP	0	3 SJS, 1 PM/DM	1 PM/DM

(Mean ± SE)

Table 2

[Click here to download high resolution image](#)**Table 2 Expression of EMMPRIN in Abnormal Epithelial Cells**

case no. disease		EMMPRIN			
		hyperplastic type II cells	squamous metaplasia	bronchiolization	
				non-ciliated	ciliated
1	UIP	3	3	3	2
2	UIP	1	2	1	1
3	UIP	3	3	3	2
4	UIP	3	3	3	2
5	UIP	3	3	3	2
6	UIP	3	2	1	1
7	UIP	3	2	3	3
8	UIP	2	2	2	2
9	UIP	3	3	3	3
Mean		2.7 ± 0.2	2.6 ± 0.2	2.4 ± 0.3	2.0 ± 0.2
10	NSIP	3	2	2	1
11	NSIP	3	3	2	2
12	NSIP	3	3	3	3
13	NSIP	3	3	3	2
14	NSIP	3	2	2	2
15	NSIP	3	2	2	1
16	NSIP	3	2	2	2
17	NSIP	3	2	3	2
18	NSIP	3	3	2	2
Mean		3.0 ± 0	2.1 ± 0.1	2.3 ± 0.2	1.9 ± 0.2
19	OP	1	ND	ND	ND
20	OP	1	ND	ND	ND
21	OP	2	ND	ND	ND
22	OP	3	ND	ND	ND
Mean		1.8 ± 0.5	ND	ND	ND

ND: not detected

Table 3 **Bronchoalveolar Lavage Fluids**

		Total Cells × 10 ⁴ /ml	Cell Differentials (%)			
			AM	Lym	Neu	Eos
IP	(n=22)	32.2 ± 3.8 †	70.0 ± 4.5	21.4 ± 3.9	5.9 ± 1.5 †	3.7 ± 0.9
control	(n=7)	13.4 ± 1.3	81.2 ± 5.4	18.1 ± 5.3	0.3 ± 0.1	0.3 ± 0.3

† : p<0.05 vs. control.

(Mean ± SE)

Table 4 Expression of EMMPRIN, MMP-2, MMP-7, and MMP-9 in Abnormal Epithelial Cells in Interstitial Pneumonias

	EMMPRIN	MMP-2	MMP-7	MMP-9
Hyperplastic type II cells	+++	++	+++	+
Squamous metaplasia	+++	+	+++	++
Bronchiolization	++	+	+++	++

Fig. 1

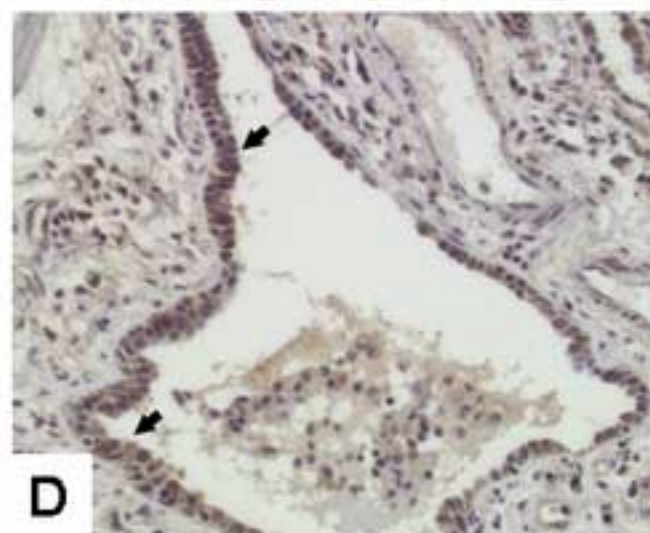
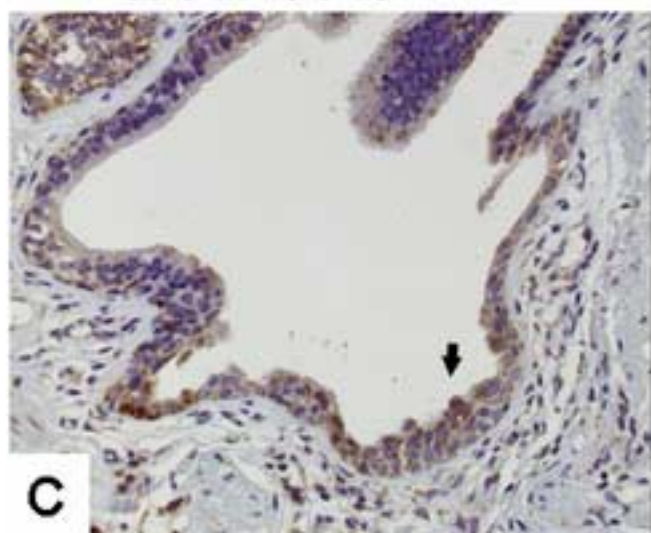
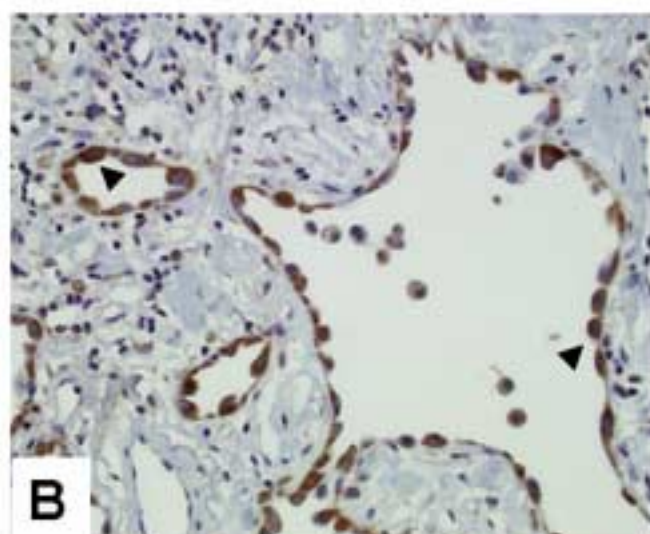
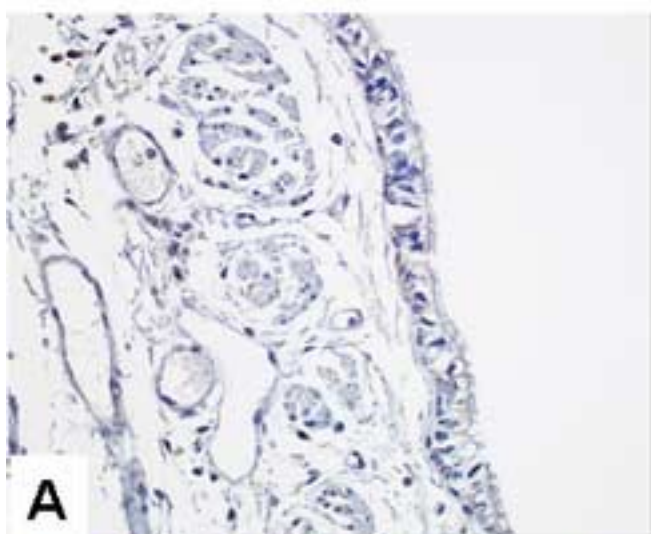


Fig. 2

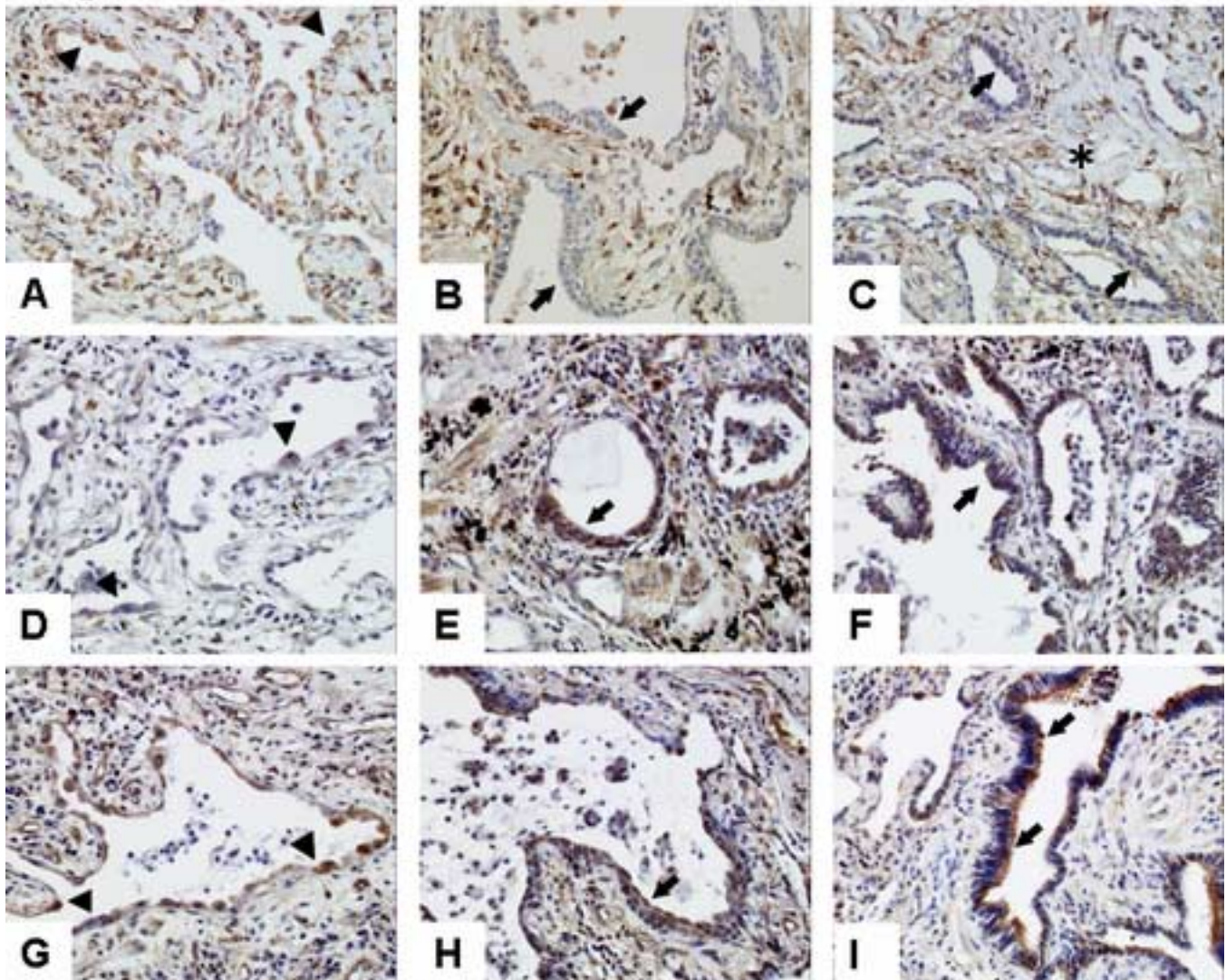


Fig. 3

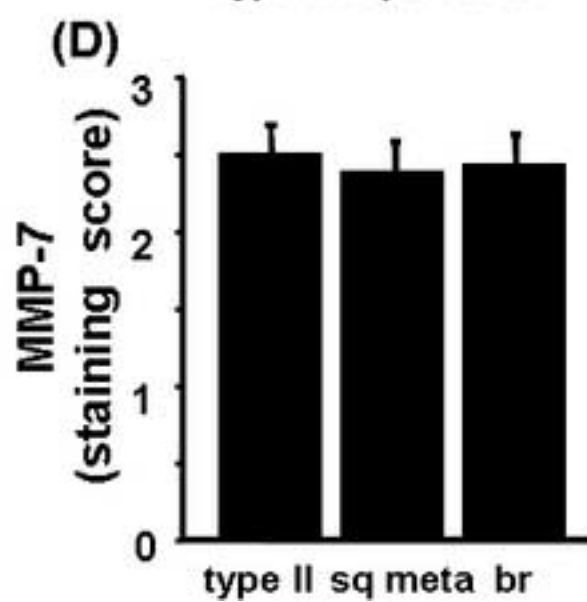
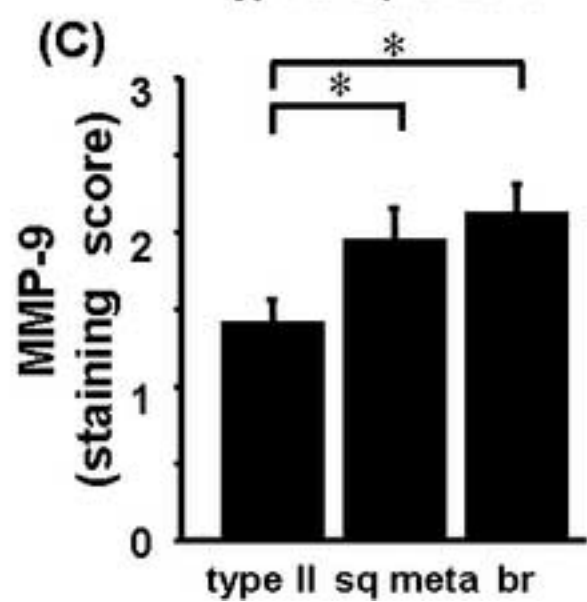
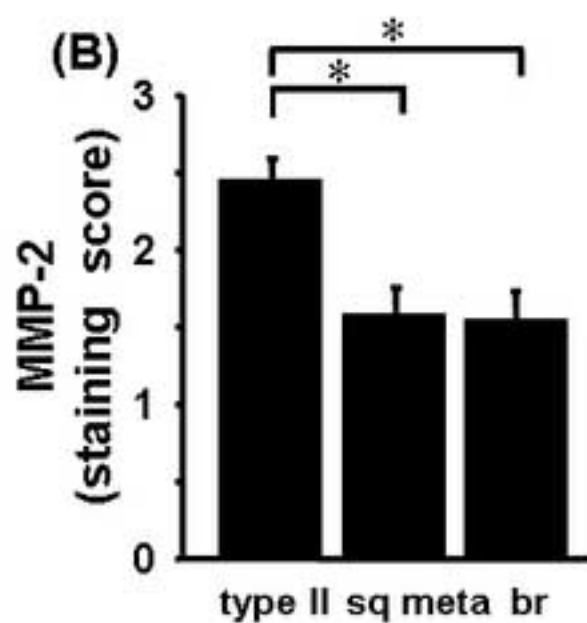
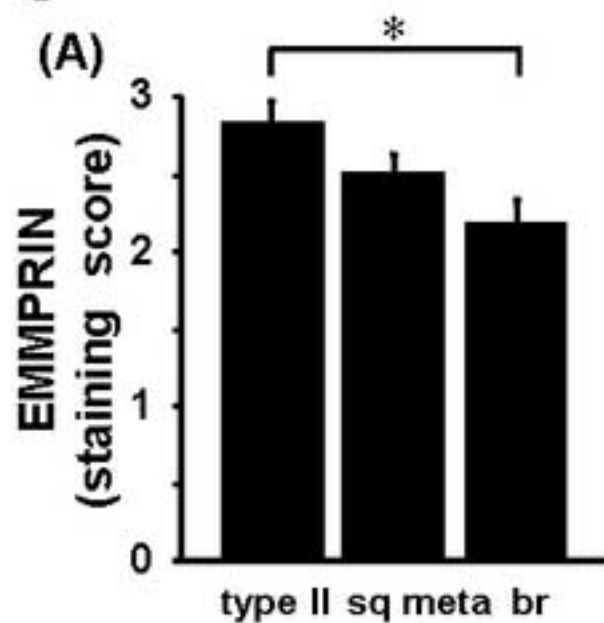


Fig. 4

