



Title	STUDIES ON THE TUBAL PATENCY OF THE COW : I. EXPERIMENTS MADE WITH SLAUGHTERHOUSE MATERIALS
Author(s)	KOIKE, Toshio; KAWATA, Keiichiro
Citation	Japanese Journal of Veterinary Research, 7(1-4), 61-69
Issue Date	1959
DOI	10.14943/jjvr.7.1-4.61
Doc URL	http://hdl.handle.net/2115/4650
Type	bulletin (article)
File Information	KJ00002373212.pdf



[Instructions for use](#)

STUDIES ON THE TUBAL PATENCY OF THE COW

I. EXPERIMENTS MADE WITH SLAUGHTERHOUSE MATERIALS

Toshio KOIKE

*Department of Veterinary Surgery, Faculty of Veterinary
Medicine, Hokkaido University, Sapporo, Japan*

and

Keiichiro KAWATA

*Department of Veterinary Obstetrics, Faculty of Veterinary
Medicine, Hokkaido University Sapporo, Japan*

(Received for publication, April 15, 1959)

INTRODUCTION

Numerous studies on the infertility of the cow, one of the important problems in veterinary medicine, have been made by many investigators. As for its causes, dysfunction of the ovaries and uteri have been regarded as playing an important role, while diseases of the oviduct have not been taken into consideration so much in this regard.

However, CARPENTER et al. stated that pathological changes were recognized in the oviduct in 187 cases of 1,221 clinical infertile cows (15.3%). SPRIGGS also noted similar pathological changes in 50 cases of 1,250 infertile cows (4%). Likewise, LOMBARD et al. after having investigated their strictly chosen materials, reported that 98 cases of 154 infertile cows showed more or less anomalies in the oviducts (63.3 %). With slaughterhouse materials, RICHTER et al., FUJIMOTO, ROWSON, DAVISON, CEMBROWICZ, SKAARUP-THYGESEN, MOBERG, and others have reported separately that there existed pathological changes in the oviduct in 3~10 per cent. These reports suggest that infertility in the cow may be caused to a great extent by various diseases of the oviduct. Especially, it is assumed that disturbances in patency of the oviduct have some close relation to infertility. As for diagnosis of disturbances of the oviduct, since RUBIN who first introduced the tuboinsufflation method for humans, hydrotubation, chromotubation and utero-salpingography have been employed for the same purpose. In the veterinary area, in addition to rectal palpation of the oviduct and ovarian bursa, the tuboinsufflation test has been made only experimentally by several investigators. Since 1953 the present authors have also studied tubal patency of the cow and the goat, and have already published several reports on this subject.

The present report deals mainly with an outline of experiments for tubal

patency employing the post mortem hydrotubation test in bovine genitalia obtained from a slaughterhouse.

MATERIALS AND METHODS

1. Apparatus

A scheme of a new apparatus for the hydrotubation test devised by the present authors is shown in figure 1. This apparatus is composed of the following several elements; a manometer (A), a safety valve (B), a valve with three openings (C), a syringe (D), a catheter (E) and three hard rubber tubes for connecting these elements.

2. Materials

Forty-seven genital organs of Holstein-Friesian cows were obtained at random for the experiments at the Sapporo Slaughterhouse. Unfortunately, the ages or clinical histories of the animals were not known.

3. Methods

The hydrotubation test was tried with the authors' apparatus within 6 hours after slaughter. Each genital organ was divided into two parts, so that the one included the right uterine horn and the right oviduct, and the other those of the left. Each oviduct was injected slowly with some quantity of physiological saline distilled water from the uterine horn. Pressure was applied until the water came out from the *ostium abdominale tubae uterinae*. The pressure at this time was provisionally designated by the authors as "the first passing-pressure (F.P.P.)". Injection of the water into the oviduct was continued until a manometer indicated 200 mmHg pressure, and then was stopped. The descent of pressure was measured.

After these genital organs had been examined macroscopically, the uteri and oviducts were brought to histological examination. Specimens for histological examination were taken from the *corpus uteri*, *cornu uteri*, *isthmus tubae uterinae*, *ampulla tubae uterinae* and *infundibulum tubae uterinae*. After having been fixed with 10 per cent formol solution, these specimens were embedded in paraffin. Sections were made from them and stained with hematoxylin-eosin solution for microscopical examination.

At the same time, uterine contents were taken aseptically with a swab and cultured on blood agar medium for 24~48 hours at 37°C.

RESULTS

1. Hydrotubation

From the results of the hydrotubation test on 94 slaughterhouse materials (47 animals), types of tubal patency were classified into the following 4 groups (table 1). Type I showed

FIGURE 1. *Hydrotubation Test Apparatus*

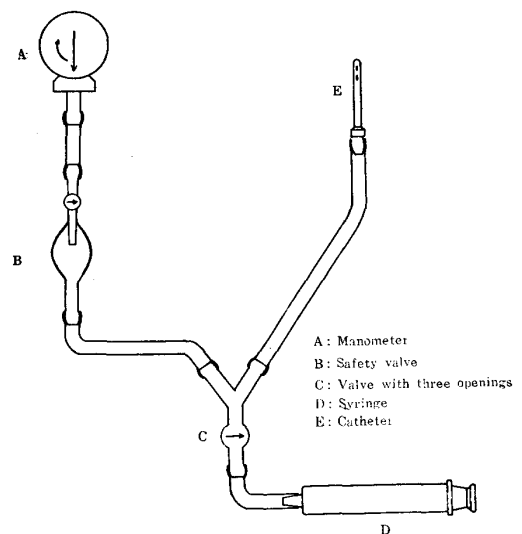


TABLE 1. Type of Tubal Patency

TYPE OF TUBAL PATENCY	F. P. P.* (mmHg)	NO. OF OVIDUCTS	PER CENT
I	80~150	60	63.8
II	150~200	7	7.5
III	150~200	20	21.2
IV	—	7	7.5

Note: * First passing-pressure.

80~150 mmHg in F.P.P. followed by a sudden decrease. Sixty cases belonged to this type (63.8%). Type II indicated 150~200 mmHg in F.P.P. with a subsequent sudden decrease. Seven cases fell into this group (7.5%). Type III showed the same value in F.P.P. as type II, but the decrease in pressure was slower. This type was noted in 20 cases (21.2%). Finally, type IV included those which did not allow water to pass through the oviduct even at a pressure more than 200 mmHg. Seven cases belonged to this group (7.5%). The relation between the changes in pressure in these 4 types and the time after the water was stopped, is graphed in figure 2.

Of all the materials, those which showed a bilateral good patency (I & I) were found in 23 cows (49.0%), as seen in table 2. At the same time cows with a unilateral good patency (I & II, I & III and I & IV) were noted in 14 (29.8%), and only one case showed a bilateral considerably bad patency (II & II) (2.1%). Finally, 9 animals revealed a bilateral bad patency or complete blockage (III & III, III & IV and IV & IV) (19.1%).

2. Macroscopical findings

On the uteri, pregnancy appeared in 5 cases (10.6%), doubtful endometritis in 28 (59.6%), other diseases in 3 (6.4%), and normal uteri in only 11 cases (23.4%). As for the ovaries, 33 cases (70.2%) were normal, 13 cases (27.7%) showed ovarian cyst, and 1 case (2.1%) presented severe ovarian adhesions. However, no change was observed macroscopically in the oviducts.

3. Bacteriological findings

Bacteriological examination of uterine contents revealed the presence of the following microorganisms: staphylococci (11 cases), streptococci (3), corynebacterium group (1), and grampositive short and large bacilli (1).

The found relationships between tubal patency and the macroscopical changes in the uteri and the ovaries on the one hand and the results of the bacterial examination on

FIGURE 2. Relation between Changes in Pressure and Time After Stopping of Water

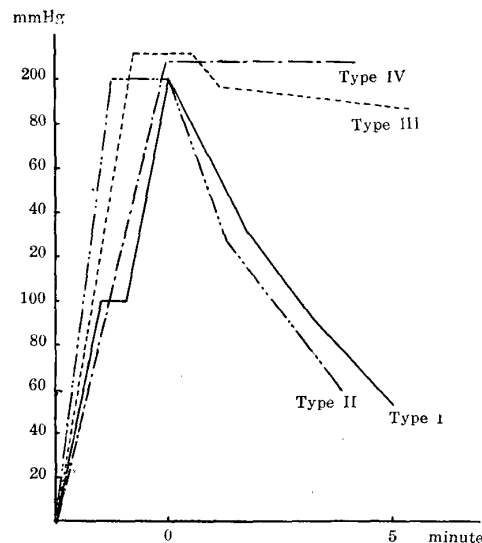


TABLE 2. *Results of Macroscopical Examination of Uterus and Ovary, and Bacteriological Examination of Uterine Contents*

TYPE OF TUBAL PATENCY	NO. OF CASES	MACROSCOPICAL CHANGES IN UTERUS				MACROSCOPICAL CHANGES IN OVARY			MICROORGANISMS IN UTERINE CONTENTS	
		Normal	Pregnancy	Doubtful Endometritis	Others	Normal	Cystic Ovary	Adhesion	Positive	Negative
I & I	23 (49.0%)	5	3	13	2	18	4	1	6	17
I & II	5	1	2	2	0	5	0	0	0	5
I & III	7	1	0	5	1	6	1	0	3	4
I & IV	2	2	0	0	0	0	2	0	0	2
II & II	1 (2.1%)	0	0	1	0	1	0	0	1	0
III & III	5	1	0	4	0	1	4	0	3	2
III & IV	3	1	0	2	0	1	2	0	0	3
IV & IV	1	0	0	1	0	1	0	0	1	0
Total	47 (100.0%)	11	5	28	3	33	13	1	14	33
		47				47			47	

TABLE 3. *Histological Diagnosis of the Uterus*

HISTOLOGICAL DIAGNOSIS		NO. OF CASES	PER CENT
Pathological	Endometritis		
	<i>Endometritis catarrhalis acuta</i>	1	2.1
	<i>Endometritis catarrhalis chronica</i>	13	27.7
	<i>Endometritis catarrhalis et cystica chronica</i>	3	6.4
	<i>Endometritis purulenta subacuta</i> (Pyometra)	1	2.1
	<i>Endometritis purulenta chronica</i>	1	2.1
	Panmetritis	1	2.1
	Myoma	1	2.1
Physio- logical	Pregnant uterus	5	10.6
	Estrous uterus	6	12.8
	Normal	15	31.9
Total		47	100.0

uterine contents on the other are summarized in table 2.

4. Histological findings

Uterus: Results of histological examination of the uterus are shown in table 3. The main pathological change was endometritis (19 cases). Of the cases of endometritis, *endometritis catarrhalis chronica* was most common (27.7%). In most of the endometritis cases, desquamation of the endometrial epithelium, hyperemia, edema and cellular infiltration with lymphocytes or plasma cells in the *tunica propria* were the symptoms principally recognized. Eosinophilic or neutrophilic leucocytic infiltration was sometimes noted. In 3 cases, *endometritis catarrhalis et cystica chronica* was diagnosed. In these cases, besides catarrhal changes in the uterine mucosa, a marked distention of the uterine glands was noted, and at the same time cystic degeneration was observed in the ovaries. Panmetritis and myoma were seen each in 1 case.

As for physiological changes, pregnancy and estrus were noted in 5 and 6 cases, respectively.

Oviduct: Distribution of the main histopathological changes in the oviduct is as shown in table 4. Of 60 cases of type I tubal patency, 2 presented obviously the findings of salpingitis at the portions of the *ampulla tubae uterinae* and *infundibulum tubae uterinae*. In other cases except these 2, pathological changes, such as hyperemia, cellular infiltration, epithelial desquamation, epithelial proliferation or dilatation of the tubes, were observed. But the degree of the changes was slight. Of 7 cases of type II, 5 were diagnosed salpingitis. Especially, 2 of these 5 cases showed inflammatory changes in all portions of the oviduct. The remaining 2 cases showed slight changes similar to those in type I. In 2 cases of 20 materials of type III, salpingitis was localized in some parts of the tubes: in one case in the *isthmus tubae uterinae* and in the other in the *infundibulum tubae uterinae*.

TABLE 4. *Distribution of Main Pathological Changes in the Oviduct*

TUBAL PATENCY		HISTOLOGICAL DIAGNOSIS	NO. OF AFFECTED OVIDUCTS	AFFECTED REGIONS			
Type	No. of Oviducts			Is.(a) ^{*1}	Is.(b) ^{*2}	A. ^{*3}	In. ^{*4}
I	60	{ <i>Salpingitis catarrhalis subacuta</i>	1	•	•	1	1
		{ <i>Salpingitis catarrhalis chronica</i>	1	•	•	1	1
II	7	{ <i>Salpingitis catarrhalis subacuta</i>	1	•	•	1	1
		{ <i>Salpingitis catarrhalis chronica</i>	3 ^{*5}	2	2	2	3
		{ Hydrosalpinx	1	•	•	•	1
III	20	{ <i>Salpingitis catarrhalis subacuta</i>	1	•	•	•	1
		{ Cystic degeneration	1	1	•	•	•
IV	7	{ <i>Salpingitis catarrhalis subacuta</i>	1	•	•	1	1
Total	94		10	3	2	6	9

Notes *1 *Isthmus tubae uterinae*, proximal portion to the uterus.

*2 *Isthmus tubae uterinae*, distal portion to the uterus.

*3 *Ampulla tubae uterinae*.

*4 *Infundibulum tubae uterinae*.

*5 Including 2 oviducts affected in all regions.

The other 18 tubes of type III cases were almost normal. Of 7 cases of type IV, salpingitis was recognized in only one case. Other materials of type IV showed mild pathological changes at the *ampulla tubae uterinae* or *infundibulum tubae uterinae*.

Thus, Salpingitis was diagnosed in 10 oviducts of 7 animals. It should be noted that subacute or chronic inflammatory changes were mainly observed. As for the affected region, salpingitis generally localized on the upper portion of the oviduct near the *ostium abdominale tubae uterinae*. Those which revealed inflammatory changes throughout the tubal portion were only 2. In addition, a majority of oviducts in every tubal patency type showed mild or slight pathological changes mentioned above.

DISCUSSION

From the results of the hydrotubation test on 94 slaughterhouse materials (47 animals), 60 oviducts (63.8%) showed good tubal patency, while the others (36.2%) presented more or less anomalies in tubal patency. According to DAWSON, the fluid injection test practised post mortem appeared efficient in demonstrating patency of the microscopically normal tubes, but it indicated blockage in only 35 per cent of the tubes which on section appeared impassable to ova.

As for the form of bovine tubal patency, the following 4 types were distinguished: easy passage (type I), temporary occlusion (type II), difficult passage (type III) and occlusion (type IV).

Individually, cows with bilateral good tubal patency (I & I) were 23 (49.0%), numbering half of the animals studied, while it is noteworthy that cows with unilateral bad patency or blockage (I & III and I & IV) and those with bilateral one (III & III, III & IV and IV & IV) were both 9 (19.1%, respectively). From this fact, it is assumed that disturbance of tubal patency may influence considerably the function of the oviduct as the path for sperm and ovum or as the place at which fertilization occurs.

Histologically, salpingitis was detected in only 10 oviducts among 94 materials (10.6%). In most of the other oviducts, however, slight histopathological changes mainly with hyperemia and cellular infiltration in the *tunica propria*, epithelial proliferation or desquamation were noted. These findings were detected mostly in the parts near the ovary. Salpingitis also localized mainly at the similar parts.

In this regard, it is interesting that SKAARUP-THYGESEN, MOBERG, and others have stated that removal of the persistent corpus luteum, artificial rupture of the graffian follicle by manipulation per rectum and breaking of the cystic follicle per rectum might be the principal causes of various disturbances of the oviduct.

Thus, from the present results, it is obvious that histopathological changes of the oviduct are less numerous than the disturbances of tubal patency as shown by means of hydrotubation. This may indicate that the disturbances of tubal patency are not always due to histological alterations in the oviduct. However, further studies are needed to clarify these problems.

As for the relationship between tubal patency and uterine conditions, it seems that the oviduct at pregnancy reveals a good patency, though the present authors could not make sure of that point because of the small number of cases. Where endometritis was detected, a clear relation to tubal patency was not discerned. Neither was a significant relationship noted between tubal patency and bacteriological findings of the uterine contents.

Of 7 cases (10 oviducts) diagnosed as salpingitis, those combined with endometritis numbered 5 (7 oviducts). However, as seen in the table 4, on the basis of the fact that the main pathological changes of the oviducts are limited mostly to the portions near the ovary, not near the uterus, the assumption that endometritis, in general, may extent easily over the oviduct seems to be premature.

Furthermore, though, in various stages of the sexual cycle of the cow, especially in estrus, tubal patency may be influenced considerably by a large amount of mucus or other estrous changes in the oviduct, correlation among them could not be established with certainty, because of the shortage of cases.

SUMMARY

For the purpose of diagnosing tubal infertility of the cow, a new apparatus

for performance of the hydrotubation test was devised by the present authors.

Forty-nine genital organs obtained from a slaughterhouse were examined by means of the hydrotubation method. In 24 materials, disturbances of tubal patency were noted in various degrees unilaterally or bilaterally. Especially, in 9 cases of them, severe obstructions for tubal patency were found.

Histologically, only 10 oviducts showed findings of localized salpingitis, while the others did not reveal any marked pathological alterations. Thus, histological changes of the oviduct were less in number than the disturbances of tubal patency as shown by means of hydrotubation. This seems to indicate that the disturbances of tubal patency are not always due to histological alterations. In addition, from the fact that the principal pathological changes were found localized mainly at the portions near the *ostium abdominale tubae uterinae*, it is suggested that most causes of salpingitis may probably be various treatment failures practiced per rectum against ovarian diseases.

However, in order to clarify the causes of obstruction to tubal patency, much is to be studied.

The authors wish to express their gratitude to Emeritus Professor R. KUROSAWA, formerly the chief of the Department of Veterinary Surgery, for his kind instructions. The authors also indebted to Professor S. YAMAGIWA and Assistant Professor Y. FUJIMOTO, of the Department of Veterinary Pathology, for their kind guidance.

REFERENCES

- 1) CARPENTER, C. M., W. W. WILLIAMS & H. L. GILMAN (1921): *J. Amer. vet. med. Ass.*, **59**, 173.
- 2) CEMBROWICZ, H. J. (1946): *Thesis, Cambridge* (Cited from MOBERG).
- 3) DAVISON, W. F. (1944): *Vet. Rec.*, **56**, 359.
- 4) DAWSON, F. L. M. (1958): *Ibid.*, **70**, 487.
- 5) FUJIMOTO, Y. (1956): *Jap. J. vet. Res.*, **4**, 129.
- 6) KOIKE, T., K. KAWATA & T. SAKAI (1955): *Jap. J. Animal Reprod.*, **1**, 62 (in Japanese).
- 7) LOMBARD, L., B. B. MORGAN & S. H. MCNUTT (1951): *Amer. J. vet. Res.*, **12**, 69.
- 8) MOBERG, R. (1954): *Vet. Rec.*, **66**, 87.
- 9) RICHTER, J., F. ROTH & A. KOKKONEN (1927): *Berl. tierärztl. Wschr.*, **43**, 885.
- 10) ROWSON, L. E. A. (1942): *Vet. Rec.*, **54**, 311.
- 11) RUBIN, I. C. (1927): *Amer. J. Obstet. Gynec.*, **14**, 557.
- 12) SKAARUP-THYGESEN, A. (1949): *Maanedsskr. Dyrloeg.*, **60**, 261 (Cited from MOBERG).
- 13) SPRIGGS, D. W. (1945): *Vet. Rec.*, **57**, 469.

EXPLANATION OF PLATE

- Fig. 1. Left *isthmus tubae uterinae*, proximal portion to the uterus of No. 55, type II tubal patency. H.-E. stain. $\times 35$. Histological diagnosis: *salpingitis catarrhalis chronica*. The figure shows marked cellular infiltration in the *tunica propria*.
- Fig. 2. Transitional portion to the apex of right uterine horn of No. 50, type III tubal patency. H.-E. stain. $\times 35$. Histological diagnosis: cystic degeneration. Left portion of the picture is a cut section of the dilated tubal cavity. In the central and right portion many distended uterine glands are seen.
- Fig. 3. Right *ampulla tubae uterinae* of No. 55, type II tubal patency. H.-E. stain. $\times 100$. Histological diagnosis: *salpingitis catarrhalis chronica*. A marked cellular focus in the central portion of the picture.
- Fig. 4. Left *ampulla tubae uterinae* of No. 96, type IV tubal patency. H.-E. stain. $\times 100$. Histological diagnosis: *salpingitis catarrhalis subacuta*. Intense cellular infiltration.
- Fig. 5. Right *ampulla tubae uterinae* of No. 96, type II tubal patency. H.-E. stain. $\times 400$. Histological diagnosis: *salpingitis catarrhalis subacuta*. Considerably marked cellular infiltration mainly with lymphocytes and plasma cells.
- Fig. 6. Right *infundibulum tubae uterinae* of No. 96, type II tubal patency. H.-E. stain. $\times 400$. Histological diagnosis: *salpingitis catarrhalis subacuta*. A cellular focus consists of lymphocytes and plasma cells. In the left portion two capillaries show dilatation.

