



Title	FRENKELIA SP. FROM THE RED-BACKED VOLE, CLETHRIONOMYS RUFOCANUS BEDFORDIAE, IN HOKKAIDO, JAPAN
Author(s)	FUJITA, Osamu; OKU, Yuzaburo; OHBAYASHI, Masashi
Citation	Japanese Journal of Veterinary Research, 36(1), 69-71
Issue Date	1988-01-30
DOI	10.14943/jjvr.36.1.69
Doc URL	http://hdl.handle.net/2115/3085
Type	bulletin (article)
File Information	KJ00002376922.pdf



[Instructions for use](#)

BRIEF COMMUNICATION

FRENKELIA SP. FROM THE RED-BACKED VOLE,
CLETHRIONOMYS RUFOCANUS BEDFORDIAE,
IN HOKKAIDO, JAPAN

Osamu FUJITA, Yuzaburo OKU and Masashi OHBAYASHI

(Accepted for publication December 28, 1987)

Key words : Sarcocystidae, *Frenkelia*, Japan, *Clethrionomys rufocanus*

The genus *Frenkelia* is a tissue cyst-forming coccidium. The life cycle is obligatorily heteroxenous, with carnivorous birds as definitive hosts and rodents as intermediate hosts (ROMMEL & KRAMPITZ, 1975; KRAMPITZ et al., 1976; ROMMEL et al., 1977). *Frenkelia* is very similar to *Sarcocystis* except that its cyst is formed in the brain and spinal cord of the intermediate hosts. Up to this time *Frenkelia* sp. has not been reported in Japan.

Twenty-nine red-backed voles, *Clethrionomys rufocanus bedfordiae*, were trapped near Sapporo city, Hokkaido, Japan during the period of November 11 to 19, 1987. Their brains were removed by necropsy for examination. In six voles many thin-walled lobulated cysts, 0.5-1.0 mm in diameter, were found in fresh squash specimens (Fig.1). Histologically, the cysts were observed in both cortex and medulla of the cerebrum, cerebellum and brain stem. The cyst was deeply lobulated, thin-walled and divided into numerous compartments by septa (Fig.2). Bradyzoites were crescent-shaped, 8.3-10.6 (average 8.7) μ by 1.5-2.7 (average 1.9) μ in the fresh specimen (Fig. 3), and periodic acid-Schiff positive. Lesions caused by the parasite were hemorrhage, perivascular and meningeal mononuclear cell infiltration and gliosis, but those were very slight. Granulomatous encephalitis, which have been reported in rats infected with *F. microti* (HAYDEN et al., 1976) was not observed in this case.

In the genus *Frenkelia*, two species are widely accepted; *F. microti* (FINDLAY & MIDDLETON, 1934) BIOCCA, 1968 and *F. glareoli* (ERHARDOVA, 1955) BIOCCA, 1968 (syn. *F. clethrionomyobuteonis* ROMMEL & KRAMPITZ, 1975) (FRENKEL et al., 1979). The differences in these species are in the shape and size of cyst formed in the brain of the intermediate hosts (FRENKEL et al., 1979). Cysts of *F. glareoli* are spherical or

egg-shaped and up to 0.4 mm in diameter (FRENKEL et al., 1979). The bank vole, *Clethrionomys glareolus*, is the experimental and natural intermediate host of *F. glareoli* (KRAMPITZ et al., 1976). The spherical cyst was also reported from *C. rufocanus* in the U. S. S. R. (TADROS et al., 1972). The cyst of *F. microti* is lobulated and 0.2-1.0 mm in diameter (FRENKEL et al., 1979) and is similar to that of the present *Frenkelia* sp. The range of experimental intermediate hosts of *F. microti* is wide, i. e., *Microtus agrestis*, *M. arvalis*, *Apodemus sylvaticus*, *A. flavicollis*, *A. agrarius*, *Rattus norvegicus*, *Mesocricetus auratus*, *Mus musculus*, *Mastomys natalensis*, *Cricetus cricetus*, *Chinchilla laniger* and *Oryctolagus cuniculus* (ROMMEL & KRAMPITZ, 1975; KRAMPITZ & ROMMEL, 1977). However, experimental infection of *Clethrionomys glareolus* with *F. microti* have not proved successful (KRAMPITZ & ROMMEL, 1977). The lobulated cyst has been observed in North America (HAYDEN et al., 1976; KENNEDY & FRELIER, 1986) and Europe (TADROS et al., 1972). The definitive hosts of *F. microti* and *F. glareoli* are the common European buzzard, *Buteo buteo* (ROMMEL & KRAMPITZ, 1975; KRAMPITZ & ROMMEL, 1977). Though *Buteo buteo japonicus* breeds and is found not rarely in Hokkaido, the definitive host of the present *Frenkelia* sp. has not yet been determined.

The authors would like to thank to Mr. Mark MICALLEF, Cancer Institute, Hokkaido University, for the reading the manuscript.

REFERENCES

- 1) FRENKEL, J. K., HEYDORN, A. O., MEHLHORN, H. & ROMMEL, M. (1979): Sarcocystinae: *Nomina dubia* and available names. *Z. Parasitenkd.*, **58**, 115-139
- 2) HAYDEN, D. W., KING, N. W. & MURTHY, A. S. K. (1976): Spontaneous *Frenkelia* infection in a laboratory-reared rat. *Vet. Pathol.*, **13**, 337-342
- 3) KENNEDY, M. J. & FRELIER, P. F. (1986): *Frenkelia* sp. from the brain of a porcupine (*Erethizon dorsatum*) from Alberta, Canada. *J. Wildl. Dis.*, **22**, 112-114
- 4) KRAMPITZ, H. E., ROMMEL, M., GEISEL, O. & KAISER, E. (1976): Beiträge zum Lebenszyklus der Frenkelien. II. Die ungeschlechtliche Entwicklung von *Frenkelia clethrionomyobuteonis* in der Rötelmaus. *Z. Parasitenkd.*, **51**, 7-14
- 5) KRAMPITZ, H. E. & ROMMEL, M. (1977): Experimentelle Untersuchungen über das Wirtsspektrum der Frenkelien der Erdmaus. *Berl. Muench. Tieraerztl. Wochenschr.*, **90**, 17-19
- 6) ROMMEL, M. & KRAMPITZ, H. E. (1975): Beiträge zum Lebenszyklus der Frenkelien. I. Die Identität von *Isospora buteonis* aus dem Mäusebussard mit einer Frenkelienart (*F. clethrionomyobuteonis* spec. n.) aus der Rötelmaus. *Berl. Muench. Tieraerztl. Wochenschr.*, **88**, 338-340
- 7) ROMMEL, M., KRAMPITZ, H. E. & GEISEL, O. (1977): Beiträge zum Lebenszyklus der Frenkelien. III. Die sexuelle Entwicklung von *F. clethrionomyobuteonis* im Mäusebussard. *Z. Parasitenkd.*, **51**, 139-146
- 8) TADROS, W. A., BIRD, R. G. & ELLIS, D. S. (1972): The fine structure of cysts of *Frenkelia* (The M-organism). *Folia Parasitol.*, **19**, 203-209

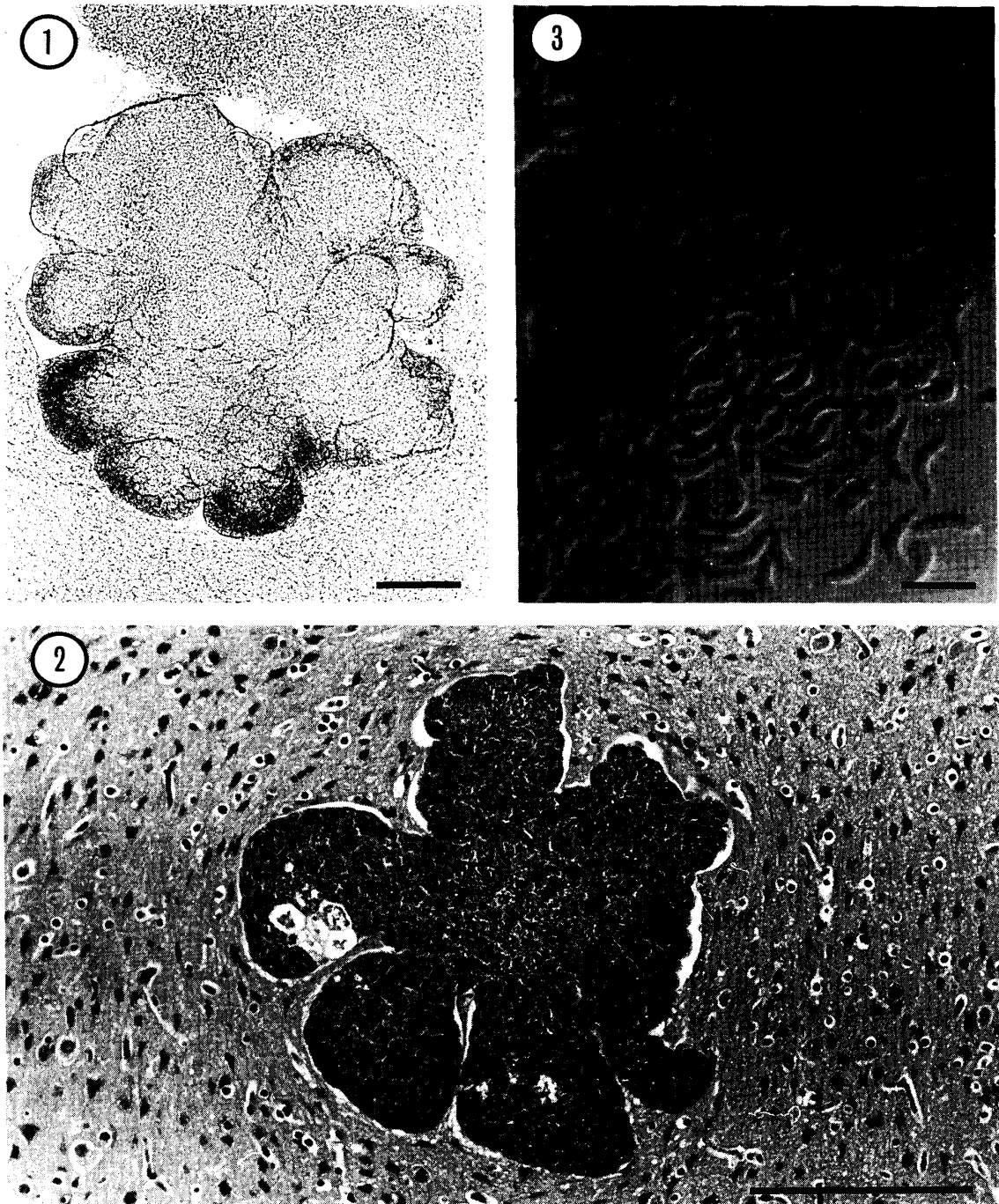


Fig. 1 Squash preparation of the brain, showing lobulated, thin-walled and septate cyst Unstained, (scale=0.2 mm)

Fig. 2 Cyst in the cerebral cortex without inflammation H-E stain, (scale=0.2 mm)

Fig. 3 Crescent-shaped bradyzoites
Differential interference microphotograph, (scale=10 μ)