



Title	Sustained hypomyelination and high serum thyroid hormone in aged black tremor hamster
Author(s)	Kim, Hyoung-Ook; Kimura, Takashi; Ochiai, Kenji; Yazawa, Hajime; Itakura, Chitoshi; Umemura, Takashi
Citation	Japanese Journal of Veterinary Research, 51(2), 113-120
Issue Date	2003-08-29
DOI	10.14943/jjvr.51.2.113
Doc URL	<a href="http://hdl.handle.net/2115/2972">http://hdl.handle.net/2115/2972</a>
Type	bulletin (article)
File Information	KJ00000699578.pdf



[Instructions for use](#)

## Sustained hypomyelination and high serum thyroid hormone in aged black tremor hamster

Hyoung-Ook Kim<sup>1)</sup>, Takashi Kimura<sup>1)</sup>, Kenji Ochiai<sup>1)</sup>, Hajime Yazawa<sup>2)</sup>,  
Chitoshi Itakura<sup>3)</sup>, and Takashi Umemura<sup>1)\*</sup>

(Accepted for publication : June 18, 2003)

### Abstract

Oligodendrocytes and myelin in the *corpus callosum* of black tremor and normal hamsters aged over 1.5 years were ultrastructurally examined to determine the myelination index (ratio of myelin thickness/diameter of axon), percentage of naked axons, and proportions of oligodendroglial subtypes (light, medium and dark). The mutant hamsters were remarkably hypomyelinated, with a low myelination index and a high proportion of naked axons, and high proportions of the dark subtypes. Serum concentrations of thyroid hormones ( $T_3$  and  $T_4$ ) in 6-week-old mutant hamsters were 2-fold ( $T_3$ ) to 3-fold ( $T_4$ ) higher than those of age-matched normal animals. However, in the aged animals (over 1.5 years old) only  $T_4$  levels of the mutant hamsters were higher in the mutant than normal hamsters. The black tremor hamsters were hypomyelinated throughout their life and high serum level of thyroid hormones might have played a role in the hypomyelination.

Key words : attractin, black tremor hamster, hypomyelination, oligodendrocyte, thyroid hormones

### Introduction

Black tremor hamsters have been established and maintained at Nippon Institute for Biological Science, Laboratory Animal Re-

search Station. They originated from an inbred colony of the APG strain of Syrian hamster. The mutant phenotype is due to a single autosomal recessive gene, designated 'black tremor : *bt*<sup>2</sup>', and it is thought that both tremor

---

<sup>1)</sup>Laboratory of Comparative Pathology, Department of Veterinary Clinical Sciences, Hokkaido University Graduate School of Veterinary Medicine, Sapporo 060-0818, Japan

<sup>2)</sup>Nippon Institute for Biological Science, Kobuchizawa, Yamanashi 408-0041, Japan

<sup>3)</sup>Brain Science Institute, The Institute of Physical and Chemical Research, Wako, Saitama 351-0198, Japan

\*Corresponding author : Takashi Umemura, Laboratory of Comparative Pathology, Hokkaido University Graduate School of Veterinary Medicine, Sapporo 060-0818, Japan

TEL : 81-11-706-5191 FAX : 81-11-706-5194

E-mail : umemura@vetmed.hokudai.ac.jp

and the characteristic black coat color are effects of the same 'bt' gene<sup>19</sup>.

The main features of myelin disorders in this hamster have been described as diffuse central nervous system (CNS) myelin deficiency<sup>21</sup>. Myelin sheaths of axons are thin in all neuronal axons, and small axons less than 1  $\mu\text{m}$  in diameter in the white matter of the spinal cords are unmyelinated. The number of glial cells is in the normal range and the peripheral nerve fibers are normally myelinated<sup>21</sup>.

Recent genetic investigations on this mutant hamster revealed that this mutant hamster has an insertional mutation of the attractin gene<sup>13</sup>. The mutant animals show darkened coat color and diffuse hypomyelination with vacuolation in the CNS, while the biochemical components of the myelin are normal<sup>12</sup>.

Many mutant strains of laboratory rodents with various genetic disorders of myelin have been reported and are invaluable models for the study of myelinogenesis. The majority of the mutants are mouse strains, including quaking<sup>30</sup>, shiverer<sup>8</sup>, twitcher<sup>17</sup>, jimpy<sup>6</sup> and myelin-deficient mice<sup>18</sup>. A few other mutant laboratory animals such as myelin-deficient rat<sup>7</sup>, zitter rat<sup>12</sup> and the black mutant hamster with myelin deficiency<sup>21</sup> have also been reported. This mutant hamster has been called black mutant hamster<sup>21</sup>, black tremor hamster<sup>13,19</sup> or CBB hamster<sup>11</sup>.

Oligodendrocytes can be divided ultrastructurally into three subtypes: light, medium and dark<sup>20</sup>. The light cells are large in size and actively dividing immature young cells, whereas the dark cells are small and post-mitotic old cells after myelination. The medium cells have mixed characteristics of both light and dark cells. The relative numbers of actively mitotic light/medium oligodendrocytes and the post-mitotic dark oli-

godendrocytes may reflect the myelination activity in the CNS.

The thyroid hormones, thyroxine ( $T_4$ ) and 3, 5, 3'-triiodo-L-thyronine ( $T_3$ ), profoundly affect the development, growth and homeostasis of many vertebrate tissues<sup>1,14,22,27,28</sup> and play especially important roles in brain development and normal CNS myelination<sup>25</sup>. Thyroid hormones also participate in regulating the expression of some enzymes involved in the myelination of the CNS and of the major protein constituents of myelin<sup>1,4,10,26,27</sup>.

Hyperthyroidism accelerates the deposition of myelin whereas hypothyroidism delays it<sup>5,29</sup>. However, sustained high levels of thyroid hormones in the neonatal rat result in increased oligodendroglial cell death and myelin deficit<sup>15</sup>.

We previously reported that the hypomyelination in the 3- to 14-week-old mutant hamsters was related with low myelinogenetic activity and early maturation of oligodendrocytes<sup>9</sup>. In this study, we compared the ultrastructural features of CNS myelin, oligodendrocytes and serum thyroid hormones in young (6-week-old) and aged (over 1.5-year-old) mutant and normal hamsters. Our data show that the hypomyelination and higher proportion of inactive oligodendrocytes are sustained in aged mutant hamsters. The hyperthyroidism of the mutant hamsters might be related with hypomyelination in the CNS.

## Materials and Methods

### Animals

A total of 18 hamsters was used in this study, 3 mutant hamsters and 3 normal hamsters (male, 6 weeks old) for serum thyroid hormone measurement, 6 mutant hamsters (3 males and 3 females, over 1.5 years old) and 6 normal hamsters (age and gender-matched control) for thyroid hormone meas-

urement and ultrastructural study.

All animals were given food and water *ad libitum* and housed in a controlled conventional environment (12 hour light-dark cycle and temperature of  $24 \pm 1$  °C in an artificial draft).

#### *Necropsy*

The animals were anesthetized by intraperitoneal injection of an overdose of 50 mg/kg of body weight of pentobarbital sodium (Nembutal; Abbott Laboratories, North Chicago, USA). Before perfusion, about 1 ml of blood was extracted from the heart, and then the animals were euthanatized by perfusion through the left ventricle of 200 ml each of buffer and fixative (4 % paraformaldehyde or modified Karnovsky's fixative containing 1 % paraformaldehyde and 3 % glutaraldehyde in 0.1 M phosphate buffer, pH 7.4). After fixation, the hamsters were necropsied and the brains were removed and sectioned coronally based on the optic chiasm.

#### *Electron microscopy*

The corpus callosum was selected for the ultrastructural investigation of myelin and oligodendrocytes, because this region lacks neurons and ependymal cells, and most of the cells present there are glial cells<sup>20</sup>. After overnight fixation of the trimmed brain specimens with the same perfusion fixative 4°C, the tissues were postfixed with 1 % osmium tetroxide in phosphate-buffered saline (pH 7.4), dehydrated through a graded series of alcohol and embedded in epoxy resin (Epon 812). Semithin sections were cut and stained with 1 % toluidine blue. After orientation of the epon blocks, thin sections (silver to gold) were prepared and stained with uranyl acetate and lead citrate, and then examined with a JEM-100SX electron microscope (JEOL, Japan) at 80 kv.

Random areas were selected for the calculation of myelination index. The diameters and myelin thickness were counted from electron micrographs of 100–200 axons. The index was calculated as the ratio of myelin thickness/diameter of axon. More than 100 oligodendrocytes of each of the aged hamsters were classified into the three subtypes according to their ultrastructure.

#### *Serum thyroid hormone measurement*

Blood was allowed to stand for 30 min at room temperature, and then centrifuged at 3000 rpm for 10 min. Serum was drained and measured for thyroid hormones (T<sub>3</sub> and T<sub>4</sub>).

The T<sub>3</sub> and T<sub>4</sub> were measured by a non-radioisotope immunochemical method using an immunoassay system (ADVIA Centaur, Bayer Medical Co.) with special reagents including anti-T<sub>3</sub> mouse monoclonal antibody labeled with acrydium ester and anti-T<sub>4</sub> mouse monoclonal antibody labeled by acrydium ester. Minimal detection sensitivities were 10.0 ng/dl (T<sub>3</sub>) and 0.3 µg/dl (T<sub>4</sub>).

#### *Statistical analysis*

Paired data obtained in this study were compared by two-way ANOVA (Analysis of Variance) with a significance level of 0.05 or Student's *t*-test, with values of  $p < 0.05$  considered significant.

## **Results**

#### *Myelination index and proportion of naked axons in aged animals*

The myelination index of mutant hamsters was less than half that of normal hamsters, which was significant ( $p < 0.05$ ) by two-way ANOVA. The percentage of naked axons was 10%, the same as that in normal hamsters, but about half of the axons were still unmyelinated in the mutant hamsters (Fig 1).

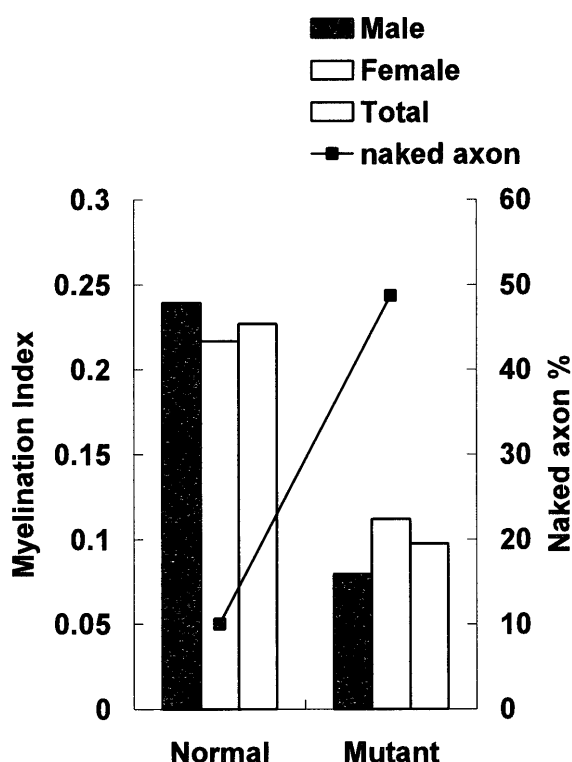


Fig. 1. Myelination index and percentages of naked axons. The bars represent the means of myelination indexes of three animals each for male and female of both mutant and normal hamsters over 1.5 years of age. The lines indicate the mean percentages of naked axons in three males and females of mutant and normal hamsters aged over 1.5 years.

#### Subtyping of oligodendrocytes

The oligodendrocytes were classified into three types, light, medium and dark cells, based on ultrastructural features including the electron density of the cytoplasm<sup>20</sup>. Briefly, the light oligodendrocytes were large cells with pale nucleus and cytoplasm, containing small organelles as well as many ribosomes. The dark cells were much smaller than the light oligodendrocytes and had a dense nucleus and cytoplasm. The medium cells were between the dark and light cells in terms of cytoplasmic density and cell size. According to these criteria, all three subtypes of

oligodendrocytes were found in both normal and mutant hamsters; however, their proportions were different in the two groups (Table 1). The light and medium cells accounted for the majority of the oligodendrocyte population in normal hamsters. In the mutant hamsters, the dark cells were the main subtype (Table 1).

#### Serum thyroid hormone analysis

The serum  $T_3$  level was two fold higher and the serum  $T_4$  level was over three fold higher in 6-week-old mutant hamsters compared with the respective levels in age-matched normal animals (Table 2). In the aged animals, the  $T_3$  levels of mutant animals were almost equivalent to those of normal animals, but the  $T_4$  levels were still significantly higher than those of normal animals (Table 2).

#### Discussion

The clinical signs of the mutant black tremor hamsters become apparent around 2 weeks after birth, and complete clinical recovery does not occur throughout their lives<sup>21</sup>. In our previous report<sup>9</sup>, we found hypomyelination and early maturation of oligodendrocytes in the CNS of 3-, 7- and 14-week-old mutant hamsters. These pathological abnormalities were found to be maintained in the aged mutant hamsters in the present study, and this may explain the lifelong duration of clinical signs in the mutant hamsters.

Although the initial stage of myelogenesis in young animals is thought to be the most important, myelinogenesis occurs repeatedly during life span of animals<sup>16</sup>. If oligodendrocytes are somehow damaged, new myelinating oligodendrocytes replace the dead cells by proliferation and/or migration of the remaining progenitor cells and maintain the myelination. Exhaustion of the surviving

Table 1 . Percentages of oligodendrocyte subtypes of aged normal and mutant hamsters

Animals	Cell types			
	Light	Medium	Dark	
Male	Normal	41 <sup>a</sup>	30	28
	Mutant	21	24	55
Female	Normal	45	25	31
	Mutant	20	11	69

Electron micrographs of more than 100 oligodendrocytes were taken for each animal and the percentages of oligodendrocyte subtypes were calculated from the electron micrographs.

<sup>a</sup> Means of three animals ; the figure is rounded to the nearest whole number.

Table 2 . Serum thyroid hormone levels of young ( 6 weeks old ) and aged ( over 1.5 years old ) normal and mutant hamsters

Animals	Thyroid hormones		
	T <sub>3</sub> (ng/dl)	T <sub>4</sub> (μg/dl)	
Young <sup>a</sup>	Normal	20.0	2.3
	Mutant	46.7	6.5
Aged <sup>b</sup>	Normal	46.8	5.6
	Mutant	45.1	6.9

<sup>a</sup> Means of three animals ; both the T<sub>3</sub> and T<sub>4</sub> levels of mutant animals were significantly higher than those of normal animals ( $p < 0.05$ ).

<sup>b</sup> Means of six animals ; only the T<sub>4</sub> level of mutant animals was significantly higher than that of normal animals by two-way ANOVA at a significance level 0.05.

progenitor cells or developing oligodendrocytes results in failure of remyelination. In the mutant hamsters, the proportion of dark oligodendrocytes, post-mitotic inactive oligodendrocytes, was higher than that in normal hamsters from 7 weeks until 1.5 years of ages. These results demonstrating a paucity of actively myelinating oligodendrocytes may explain why the hypomyelination of the mutant hamsters is not be repaired throughout their life.

Oligodendrocytes can be generated from

glial progenitor cells which express A2B5 antigen *in vitro*<sup>3,24,31</sup>. The differentiation of oligodendrocytes depends on both the intrinsic program of the progenitor cells and environmental factors. For example, T<sub>3</sub> blocks progenitor cell proliferation and promotes differentiation of the progenitor cells into oligodendrocytes<sup>2</sup>. The injury of oligodendrocyte and myelin sheaths by excess thyroid hormones has been shown to contribute to the oxidative stress produced by an excess of thyroid hormones in advanced aged animals<sup>23</sup> and to the

increased oligodendroglial cell death by apoptosis in neonatal animals<sup>15</sup>).

We have demonstrated for the first time that the black tremor hamsters have high levels of serum T<sub>3</sub> and T<sub>4</sub> at 6 weeks of age. The hyperthyroidism was ameliorated in aged mutant animals, but the serum T<sub>4</sub> levels remained significantly higher than those of normal age-matched controls. Our previous<sup>9</sup>) and the present results demonstrate that the mutant hamsters display hypomyelination and early maturation of oligodendrocytes before 7 weeks of age, together with severe hyperthyroidism. The magnitude of these abnormalities is then maintained at almost the same level until 1.5 years of age, and meanwhile the mutant hamsters become affected by mild hyperthyroidism. Zitter rat and mahogany mouse also show darkened coat color and diffuse hypomyelination in the CNS without biochemical abnormalities of myelin<sup>12</sup>), however, hyperthyroidism and early maturation of oligodendrocytes have not previously been reported in the literatures. Although we could not explain the relationship between the hyperthyroidism and any attractin gene abnormality, the hyperthyroidism might be one of the causes of the hypomyelination and early maturation of the oligodendrocytes in the CNS of black mutant hamsters. Further studies are required for an identification of the relationship between hyperthyroidism and attractin gene abnormality.

### References

- 1) Almazan, G., Honegger, P., and Matthieu, J. M. 1985. Triiodothyronine stimulation of oligodendroglial differentiation and myelination. A developmental study. *Dev. Neurosci.*, 7 : 45-54.
- 2) Baas, D., Bourbeau, D., Sarlieve, L. L., Ittel, M. E., Dussault, J. H., and Puymirat, J. 1997. Oligodendrocyte maturation and progenitor cell proliferation are independently regulated by thyroid hormone. *Glia*, 19 : 324-332.
- 3) Behar, T., McMorris, F. A., Novotny, E. A., Barker, J. L., and Dubois-Dalcq, M. 1988. Growth and differentiation properties of O-2A progenitors purified from rat cerebral hemispheres. *J. Neurosci. Res.*, 21 : 168-180.
- 4) Bhat, N. R., Sarlieve, L. L., Rao, G. S., and Pieringer, R. A. 1979. Investigations on myelination *in vitro*. Regulation by thyroid hormone in cultures of dissociated brain cells from embryonic mice. *J. Biol. Chem.*, 254 : 9342-9344.
- 5) Dussault, J. H. and Ruel, J. 1987. Thyroid hormones and brain development. *Ann. Rev. Physiol.*, 49 : 321-334.
- 6) Hirano, A., Sax, D. S., and Zimmerman, H. M. 1969. The fine structure of the cerebella of jimpy mice and their "normal" litter mates. *J. Neuropath. Exp. Neurol.*, 28 : 388-400.
- 7) Hof, L. and Csiza, C. K. 1982. Developmental changes in glycolipid synthesizing enzymes in the brain of a myelin-deficient mutant Wistar rat. *J. Neurochem.*, 39 : 1434-1439.
- 8) Inoue, Y., Nakamura, R., Mikoshiba, K., and Tsukada, Y. 1981. Fine structure of the central myelin sheath in the myelin deficient mutant Shiverer mouse, with special reference to the pattern of myelin formation by oligodendroglia. *Brain Res.*, 219 : 85-94.
- 9) Kim, H. O., Matsuda, K., Kimura, T., Ochiai, K., Yazawa, H., Itakura, C., and Umemura, T. 2003. Impaired myelogenesis and early maturation of oligodendrocytes in black tremor hamster with central nervous system myelin deficiency. *J. Toxicologic Pathol.*, *in press*.
- 10) Koper, J. W., Hoeben, R. C., Hochstenbach,

- F. M. H, van Golde, L. M. G., and Lopes-Cardozo, M. 1986. Effects of triiodothyronine on the synthesis of sulfolipids by oligodendrocyte-enriched glial cultures. *Biochem. Biophys. Acta*, 887 : 327-334.
- 11) Kunishita T, Tabira T, Umezawa H, Mizutani M, and Katsui Y. 1986. A new myelin-deficient mutant hamster : biochemical and morphological studies. *J. Neurochem.* , 46 : 105-111.
  - 12) Kuramoto, T., Kitada, K., Inui, T., Sasaki, Y., Ito, K., Hase, T., Kawaguchi, S., Ogawa, Y., Nakao, K., Barsh, G. S., Nagao, M., Ushijima, T., and Serikawa, T. 2001. Attractin/mahogany/zitter plays a critical role in myelination of the central nervous system. *Proc. Natl. Acad. Sci. USA*, 98 : 559-564.
  - 13) Kuramoto, T., Nomoto, T, Fujiwara, A., Mizutani, M., Sugimura, T., and Ushijima, T. 2002. Insertional mutation of the Attractin gene in the black tremor hamster. *Mamm. Genome*, 13 : 36-40.
  - 14) Legrand, J. 1986. Thyroid hormone effects on growth and development. In : *Thyroid Hormone Metabolism* , pp. 503-534, Henneemann, G. ed., Marcel Dekker, Inc, New York.
  - 15) Marta, C. B., Adamo, A. M., Soto, E. F., and Pasquini, J. M. 1988. Sustained neonatal hyperthyroidism in the rat affects myelination in the central nervous system. *J. Neurosci. Res.* , 53 : 251-259.
  - 16) Matsushima, G. K., and Morell, P. 2001. The neurotoxicant, cuprizone, as a model to study demyelination and remyelination in the central nervous system. *Brain Pathol.* , 11 : 107-116
  - 17) Mikoshiba, K., Fujishiro, M., Kohsaka, S., Okano, H., Takamatsu, K., and Tsukada, Y. 1985. Disorders in myelination in the twitcher mutant : immunohistochemical and biochemical studies. *Neurochem. Res.* , 10 : 1129-1141.
  - 18) Mikoshiba, K., Okano, H., Inoue, Y., Fujishiro, M., Takamatsu, K., Lachapelle, F., Baumann, N., and Tsukada, Y. 1987. Immunohistochemical, biochemical and electron microscopic analysis of myelin formation in the central nervous system of myelin deficient (mld) mutant mice. *Dev. Brain Res.* , 35 : 111-121.
  - 19) Mizutani, M., Katsui, Y., Umezawa, H., and Kuramasu, S. 1986. Genetical analysis and characterization of a new mutant, black tremor appearing in the Syrian hamster. *Jikken Dobutsu* , 35 : 175-179.
  - 20) Mori, S. and Leblond, C. P. 1970. Electron microscopic identification of three classes of oligodendrocytes and a preliminary study of their proliferative activity in the corpus callosum of young rats. *J. Comp. Neurol.* 139 : 1-28.
  - 21) Nunoya, T., Tajima, M., Mizutani, M., and Umezawa, H. 1985. A new mutant strain of Syrian hamster with myelin deficiency. *Acta Neuropathol.* , 65 : 305-312.
  - 22) Oppenheimer, J. H. 1991. Thyroid hormone action at the molecular level. In : *Werner and Ingbar's The Thyroid* , pp. 204-224, Braverman, L. E. and Utiger, R. D. eds., J. B. Lippincott Company, Philadelphia.
  - 23) Pasquini, J. M. and Adamo, A. M. 1994. Thyroid hormones and the central nervous system. *Dev. Neurosci.* , 16 : 1-8.
  - 24) Raff, M. C., Miller, R. H., and Noble, M. 1983. A glial progenitor cell that develops *in vitro* into an astrocyte or an oligodendrocyte depending on culture medium. *Nature* , 303 : 390-396.
  - 25) Rodriguez-Pena, A. 1999. Oligodendrocyte development and thyroid hormone. *J. Neurobiol.* , 40 : 497-512.
  - 26) Sarlieve, L. L., Bouchon, R., Koehl, C., and Neskovic, N. M. 1983. Cerebroside and



- sulfatide biosynthesis in the brain of Snell dwarf mouse : effects of thyroxine and growth hormone in the early postnatal period. *J. Neurochem.* , 40 : 1058-1062.
- 27) Schwartz, H. L. 1983. Effect of thyroid hormone on growth and development. In : *Molecular Basis of Thyroid Hormone Action*, pp. 413 - 444, Oppenheimer, J. H. and Samuels, H. H. eds., Academic Press, New York.
- 28) Tosic, M., Torch, S., Comte, V., Dolivo, M., Honegger, P., and Matthieu, J. M. 1992. Triiodothyronine has diverse and multiple stimulating effects on expression of the major myelin protein genes. *J. Neurochem.* , 59 : 1770-1777.
- 29) Walters, S. N. and Morell, P. 1981. Effects of altered thyroid states on myelinogenesis. *J. Neurochem.* , 36 : 1792-1810.
- 30) Watanabe, I. and Bingle, G. J. 1972. Demyelination in "quaking" mouse : Electron microscopic study. *J. Neuropath. Exp. Neurol.* , 31 : 352-362.
- 31) Williams, B.P., Abney, E.R., and Raff, M. C. 1985. Macrogial cell development in embryonic rat brain : studies using monoclonal antibodies, fluorescence activated cell sorting , and cell culture . *Dev. Biol.* , 11 : 126-134.