



Title	Ultrasonographic evaluation of portal vein hemodynamics in experimentally bile duct ligated dogs
Author(s)	MWANZA, Timothy; MIYAMOTO, Toru; OKUMURA, Masahiro; KADOSAWA, Tsuyoshi; FUJINAGA, Toru
Citation	Japanese Journal of Veterinary Research, 45(4), 199-206
Issue Date	1998-02-27
DOI	10.14943/jjvr.45.4.199
Doc URL	http://hdl.handle.net/2115/2612
Type	bulletin (article)
File Information	KJ00002398578.pdf



[Instructions for use](#)

Ultrasonographic evaluation of portal vein hemodynamics in experimentally bile duct ligated dogs.

Timothy Mwanza, Toru Miyamoto, Masahiro Okumura,
Tsuyoshi Kadosawa and Toru Fujinaga.

(Accepted for publication, Jan. 14, 1998)

Abstract

The purpose of this study was to evaluate the relationship between the results of laboratory examinations and ultrasonographic findings, especially portal vein hemodynamics in experimentally bile duct ligated dogs.

Biliary obstruction was accomplished by surgically occluding the common bile duct in five dogs. All the dogs became visibly jaundiced within 24 hours after surgery. The total protein and albumin/globulin ratio showed a gradual decrease throughout the examination period, while blood urea nitrogen reached its peak in the 6th week and decreased to pre ligation values by the 10th week. Similar trends were noted in the alkaline phosphatase, alanine aminotransferase, aspartate aminotransferase, and direct and total bilirubin. Total cholesterol and fasting serum bile acid levels rapidly increased after surgery to peak values between the 2nd and 4th week, and then gradually decreased, but still remained high throughout the experiment period. The portal flow volume and velocity significantly ($p < 0.05$) decreased while only a slight increase was noted in the congestion index after bile duct ligation. The cross sectional area of the portal vein changed insignificantly. Bile duct and gallbladder distention was evident within the 1st week after ligation but there was little change in the echogenicity of the liver parenchyma.

The results of this study suggest that the determination of Doppler ultrasound parameters of hepatic hemodynamics, especially the portal vein flow indices, may contribute to a better noninvasive assessment of the canine patient with biliary obstructive disease.

Key words : bile duct ligation, dog, hemodynamics, portal vein, ultrasonography

Introduction

Common bile duct ligation has been used as a model for the production of hepatic cirrhosis in the dog^{1,16,20,23}. Ligation leads to a significant infiltration of connective tissues in the portal zone and enhanced proliferation of bile duct epithelial

cells and hepatocytes. Hepatocyte necrosis, degeneration and inflammatory infiltration further characterize the cirrhotic changes in the livers of bile duct ligated dogs¹⁶. The obstruction of the cystic or common bile duct stops the flow of bile from the gallbladder and intrahepatic biliary ducts creating increased pressure and cholestasis²⁰.

Laboratory of Veterinary Surgery, Department of Veterinary Clinical Sciences, Graduate School of Veterinary Medicine, Hokkaido University, Sapporo 060–0818, Japan.

Fax Number : 011–706–5227.

Correspondence to : Toru Fujinaga.

E-Mail: torufujina@vetmed.hokudai.ac.jp

Blood flow in the liver can be changed by a variety of diseases including hepatocellular disease, tumors and portal systemic shunts^{18,21}. Changes in systemic circulation in humans with liver cirrhosis have been studied and there are some indications that the magnitude of these changes is related to the impairment of hepatic function¹⁰. Recent technological developments in pulsed Doppler equipment make it possible to obtain qualitative and quantitative functional data in a noninvasive manner from various major blood vessels^{4,13,14,22}. The determination of portal blood flow indices like velocity, volume and vessel lumen especially in disease have, however, received less attention in veterinary medicine^{7,15}.

The purpose of this experiment was therefore to evaluate the results of laboratory and ultrasonographic examinations of the liver after experimental bile duct ligation. The main parameters that are known to change during liver disease,^{2,8,12} ie, liver enzymes and the cross sectional area of the portal vein, the portal blood flow volume, flow velocity and the congestion index of the portal vein were evaluated by ultrasonography over a 10 week period.

Materials and Methods.

Experimental animals.

Five adult dogs weighing between 10–15 kg were used in these experiments. They belonged to the experimental animal pool of the Laboratory of Veterinary Surgery were fed a commercial dry food diet without restriction. The dogs were utilised for these experiments before and up to 10 weeks after ligation of the common bile duct. Before the ligation, physical, hematological, biochemical and ultrasound examinations were carried out in order to establish baseline values for each dog. Physical examinations including the determination of body weight, temperature, heart rate and respiration rate were done.

Bile duct ligation.

The dogs were fasted for 24 hours before surgery. They were premedicated with flunitrazepam (0.03 mg/kg intravenously) and atropine sulfate (0.03 mg/kg subcutaneously) and prepared for a sterile procedure. The operations were made under pentobarbital anaesthesia (15–25 mg/kg intravenously). The abdomen was entered through a midline cranial abdominal laparotomy. The common bile duct was identified at the edge of the hepatoduodenal ligament and double ligated as close to the duodenum as possible with non absorbable suture material. Residual bile was aspirated from the gall bladder. The abdomen was then irrigated with warm lactated Ringer's solution before closure. Subcutaneous tissue and skin were closed routinely and an antibiotic administered for 7 days. The wounds were checked and cleaned daily until suture removal after 10 days.

Laboratory examination.

A complete blood cell count (CBC) was determined in each dog before ligation and every day for 5 days and thereafter weekly for 10 weeks. Serum biochemical profiles were analysed before, and weekly after bile duct ligation. The samples for a CBC were immediately analysed after collection using a hematological cell counter (Serono Diagnostics System 9000, Baker Instruments Corporation, Allentown, USA). Sera were separated after the blood had coagulated by 10 minutes centrifugation at 1,500×g. They were then immediately frozen and stored at –20°C until analysis. They were analysed for total protein (TP), albumin/globulin (A/G) ratio, blood urea nitrogen (BUN), alkaline phosphatase (ALP), alanine amino transferase (ALT), aspartate amino transferase (AST), direct bilirubin (DBil), total bilirubin (TBil), total cholesterol (TChol) and fasting serum bile acids (FSBA). The A/G ratio was calculated from the results of cellulose acetate membrane electrophoresis. An automatic chemical analyzer (Cobas Mira-S,

Nippon Roche, Tokyo, Japan) was used for all the other tests.

Ultrasound examination.

Before the ultrasound examinations, the dogs were fasted for 24 hours. The examinations included a determination of the cross sectional area of the portal vein, the congestion index, portal vein flow volume and flow velocity. The examinations were carried out using a commercially available ultrasound system (HITACHI EUB-565A, Hitachi Med. Co., Tokyo, Japan). The gallbladder was scanned on the right side by placing the transducer approximately 6–8 cm cranial to the xiphoid and 4–6 cm dorsal to the sternum. The transducer was angled toward the midline to produce transverse oblique scans through the gallbladder¹⁴.

Portal blood flow was determined according to the method described by Kantrowitz et al.⁷, Lamb and Mahoney⁹, and Nyland and Fisher¹⁶. The scanhead was positioned in the 11th or 12th intercostal space and the beam directed dorsal medially. The uniform insonation method was used in which a large Doppler sample volume that overlapped the walls of the portal vein was taken. A continuous computer drawn mean velocity curve was then analysed without arithmetic correction. Only incident angles of 65° or less were used. Three determinations were averaged to obtain the final velocity. The congestion index of the portal vein was calculated by dividing the portal vein cross sectional area by the average blood flow velocity. This is the ratio between the cross sectional area (cm²) and the blood flow velocity (cm/sec) of the portal vein as determined by the Doppler system¹².

Statistical analysis.

The paired t-test was used to compare the biochemical baseline data and the data after bile duct ligation. The value of $p < 0.05$ was considered significant.

Results

Physical examination.

The animals tolerated the operations very well and the operation wounds healed within 10 days after surgery. Bile duct ligation induced anorexia for a few days. Icteric discoloration of the mucous membranes and skin occurred after 1 day and lasted for about 2 weeks after which the animals were apparently healthy.

Laboratory examination.

A mild leucocytosis with neutrophilia and monocytosis was noted in the first 5 days after surgery. The values however returned to normal for the rest of the experiment period.

The biochemical changes before and after ligation are summarized in Table 1. All the dogs showed a steady decrease in serum TP and A/G ratio throughout the examination period. BUN rose to 29 ± 8 mg/dl in the 6th week but returned to the pre ligation values by the 10th week. The ALP activity increased rapidly and reached a significantly high value of $5,260 \pm 455$ IU/l in the 2nd week. A decrease was then noted although the values were still significantly higher than the preligation levels. Similar trends were also observed in the other liver-specific enzyme activities. DBil and TBil rose from preligation values of 0.1 ± 0.3 and 0.1 ± 0.0 mg/dl to 11.7 ± 0.5 and 11.9 ± 1.0 mg/dl in the 5th week respectively, and then gradually decreased to almost normal levels by the 10th week. TCho increased from a preligation value of 137 ± 25 mg/dl to 364 ± 105 mg/dl in the 5th week and then gradually decreased to 217 ± 20 mg/dl in the 10th week. The FSBA concentration reached 255 ± 11 mmol/l in the 2nd week and decreased to 31 ± 12 mmol/l in the last week.

Ultrasound examination.

The distention of the cystic duct was evident within the first few days after ligation (Figs. 1A : Day 7 and 1B : 3 weeks). This progressive dilatation of the cystic duct continued until the

Table 1. Serum biochemical changes before and after bile duct ligation.

Parameter	Weeks after bile duct ligation										
	0	1	2	3	4	5	6	7	8	9	10
TP (g/dl)	6.3 ± 0.2	6.2 ± 0.2	5.9 ± 0.4	5.6 ± 0.2*	5.5 ± 0.2*	5.3 ± 0.1*	4.5 ± 0.3*	5.1 ± 0.2*	4.5 ± 0.2*	4.8 ± 0.2*	4.4 ± 0.1*
A/G ratio	1.4 ± 0.5	1.4 ± 0.4	1.2 ± 0.1	1.0 ± 0.2	1.0 ± 0.3	0.9 ± 0.4	0.7 ± 0.1	0.7 ± 0.2	0.7 ± 0.4	0.7 ± 0.4	0.6 ± 0.4
BUN (mg/dl)	8.1 ± 0.3	8.5 ± 2.1	120 ± 1.4	9.7 ± 0.6	10.0 ± 0.4	21.0 ± 5.8*	29.0 ± 8.0*	20.0 ± 3.8*	20.0 ± 4.1*	15.0 ± 1.3*	9.0 ± 0.5*
ALP (IU/l)	43 ± 19	3,000 ± 70*	5,260 ± 455*	4,710 ± 798*	2,297 ± 703*	2,036 ± 473*	1,452 ± 326*	704 ± 240*	244 ± 128*	194 ± 160*	144 ± 130*
ALT (IU/l)	31 ± 9	210 ± 5*	375 ± 4*	319 ± 3*	414 ± 63*	498 ± 92*	416 ± 237*	342 ± 202*	176 ± 53.3*	116 ± 25.4*	84 ± 11.0*
AST (IU/l)	34 ± 14	455 ± 28*	1,110 ± 23.5*	470 ± 75*	252 ± 141*	216 ± 96*	179 ± 72*	81 ± 40	62 ± 24	42 ± 18	77 ± 20
DBil (mg/dl)	0.1 ± 0.3	5.8 ± 0.1	6.1 ± 0.2	6.7 ± 1.6	4.8 ± 0.5*	11.7 ± 0.5*	4.1 ± 0.1*	1.6 ± 0.1	3.5 ± 0.1*	0.2 ± 1.2	0.2 ± 0.4
TBil (mg/dl)	0.1 ± 0.0	4.1 ± 0.2	4.6 ± 0.1	3.9 ± 0.5	7.4 ± 0.9*	11.9 ± 1.0*	4.3 ± 1.0*	2.4 ± 1.0	4.2 ± 1.6*	0.5 ± 0.3	0.2 ± 0.2*
TCHol (mg/dl)	137 ± 25	276 ± 17*	307 ± 160*	330 ± 104*	338 ± 45*	364 ± 105*	261.4 ± 46*	256.7 ± 42*	245 ± 35*	235 ± 75*	217 ± 20*
FSBA (μmol/l)	6 ± 0	150 ± 52*	255 ± 11*	229 ± 34*	220 ± 11*	196 ± 25*	179 ± 15*	96 ± 39*	76 ± 20*	55 ± 11*	31 ± 12*

Mean ± SD

n=5

* = p < 0.05

TP: Total protein

A/G ratio: Albumin/globulin ratio

BUN: Blood urea nitrogen

ALP: Alkaline phosphatase

ALT: Alanine aminotransferase

AST: Aspartate aminotransferase

DBil: Direct bilirubin

TBil: Total bilirubin

TCHol: Total cholesterol

FSBA: Fasting serum bile acids

end of the experiment (Figs. 2A : 5 weeks, Fig. 2B : 7 weeks and 2C : 10 weeks). The demarcation point between the cystic duct and the common bile duct could not be identified on any scan. The gallbladder was mildly distended by the 3rd week with small amounts of echogenic bile within the cystic duct and common bile duct lumen and gallbladder. The distention and accumulation of sludge within the gall bladder continued until the end of the experiment. Bile stasis seen as diffusely echogenic sludge within the gall bladder lumen was observed in all the dogs.

There were no significant observations in the portal flow dynamics during the first 3 weeks. Major changes occurred in the portal blood flow velocity and volume starting in the 4th week. The results starting in the 3rd week are shown in Table 2. The portal flow volume decreased to 26.6 ± 1.7 ml/min in the 10th week from the pre ligation average of 33.8 ± 1.2 ml/min and the flow velocity significantly decreased from 19.2 ± 0.5 cm/sec to 9.7 ± 1.5 cm/sec in the 10th week. There was no significant change in the average congestion index. Only a slight increase was noted compared to the preligation measurements. The cross sectional area of the portal vein changed insignificantly from 0.5 ± 0.4 cm² to 0.8 ± 0.27 cm² in the 10th week.

Discussion

Doppler ultrasonography provides the opportunity to determine non-invasively the blood flow in different body organs, including the liver. The technique has been used to establish the volume and the direction and characteristics of portal flow. Other parameters like the cross sectional area of the portal vein, the flow velocity and the congestion index change during liver cirrhosis¹²⁾. Improved noninvasive determination of these parameters in addition to laboratory evaluations may contribute to a better assessment of the canine patient with liver disease⁵⁾.

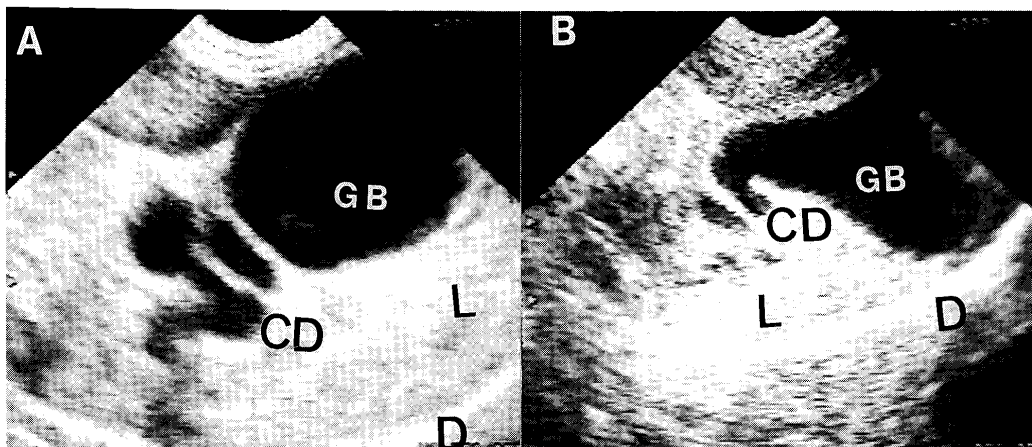


Fig. 1. Sagittal scans through the liver after common bile duct ligation. Distention of cystic duct and gall bladder can be seen. A: 1 week, B: 3 weeks; GB: Gallbladder, L: Liver, CD: Cystic duct, D: Diaphragm.

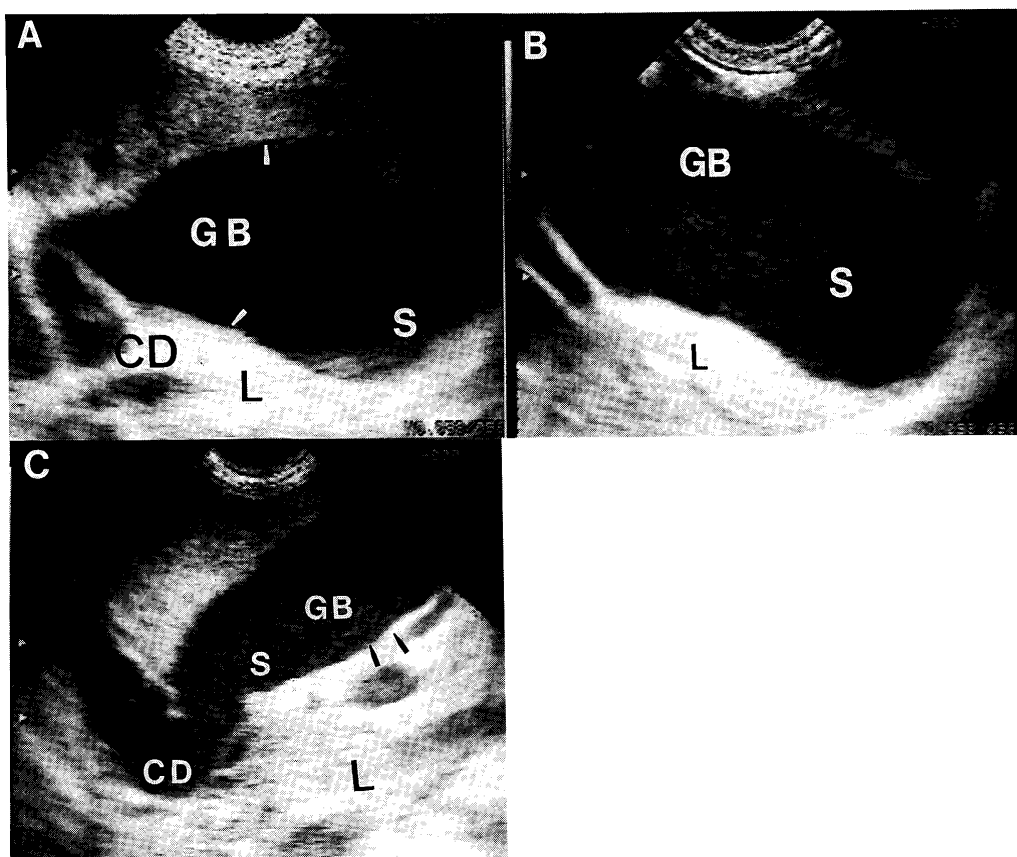


Fig. 2. At 5 weeks (A), note the echogenic walls of the gall bladder and sludge within. The whole lumen is filled with echogenic sludge at 8 weeks (B). Extreme distention of both the cystic and common bile duct and gallbladder can be seen at 10 weeks (C). GB: Gallbladder, L: Liver, CD: Cystic duct, S: Sludge, Arrowheads: Gallbladder wall.

Table 2. Portal vein blood flow before and after bile duct ligation.

Parameter	Weeks after bile duct ligation									
	0	3	4	5	6	7	8	9	10	
Flow (ml/min)	33.8 ± 1.2	32.9 ± 2	31.0 ± 1.6 *	28.7 ± 1.0 *	28.6 ± 1.6 *	26.5 ± 1.0 *	26.7 ± 1.4 *	26.9 ± 1.8 *	26.6 ± 1.7 *	
CI (cm×sec)	33.8 ± 1.2	0.03 ± 0.01	0.03 ± 0.01	0.03 ± 0.02	0.03 ± 0.01	0.05 ± 0.01	0.07 ± 0.01	0.07 ± 0.01	0.08 ± 0.01	
PV CSA (cm ²)	0.5 ± 0.04	0.5 ± 0.04	0.5 ± 0.01	0.5 ± 0.04	0.5 ± 0.08	0.6 ± 0.05	0.8 ± 0.18	0.8 ± 0.50	0.8 ± 0.27	
Velocity (cm/sec)	19.2 ± 0.5	19.1 ± 0.3	18.5 ± 0.3 *	16.7 ± 0.8 *	15.1 ± 0.6 *	13.6 ± 0.7 *	11.2 ± 1.5 *	11.2 ± 2.3 *	9.7 ± 1.5 *	
Mean ± SD	CI: Congestion index.									
n=5	PV CSA: Portal vein cross section area.									
*=p<0.05										

Apart from a transient anorexia and a slight leucocytosis, which were possibly a physiological response to surgery, the animals tolerated the operations very well.

The results of the present study showed that the distention of the cystic duct occurred very early after ligation of the common bile duct and could be easily identified by ultrasound. The obstruction of the cystic and common bile duct stopped the flow of bile from the gallbladder and intrahepatic biliary ducts creating increased pressure and cholestasis³. By the 7th day after the ligation gross cystic dilatation could be observed. Since ALP is a bile duct associated enzyme, it has a very early and high activity in the serum of dogs after bile duct ligation^{5,26}. Using the dilatation of bile ducts as a criterion of biliary obstruction had a sensitivity of 94% and a specificity of 100% in the diagnosis of human biliary obstruction²⁵. Since the canine liver is much more difficult to scan than the human liver due to the small size of the structures and its location further cranial under the rib cage, multiple scans are necessary in order to visualize the biliary tract consistently¹⁷.

The correlation between portal blood flow and bilirubin or serum protein levels in patients with cirrhosis have been reported¹¹, suggesting that liver function depends on portal blood flow. The function of the liver parenchyma depends on adequate perfusion, hence malperfusion may lead to clinical disease⁶. A similar increase in the activity of liver-specific enzymes was noticed in

dogs chronically intoxicated with a liver specific toxin leading to acute and active liver disease¹⁵. Hepatic parenchyma cell damage is reflected by increased serum ALT and AST levels, while high increases in the ALP activity reflects a dysfunction of the biliary system¹⁵. The hepatic blood inflow (portal blood flow plus hepatic arterial flow) is one of the most important factors determining hepatic function. Chin *et al.* demonstrated that portal venous flow was reduced in patients with cirrhosis and splenorenal shunts². However, even when portal venous flow is not reduced, portal blood supply to the liver cells may be reduced because of intrahepatic shunting. Portal sinusoidal flow decreases with progression of the stage of liver disease, and is significantly reduced in the advanced stage when large intrahepatic portal systemic shunts develop². This would explain the apparent reduction in liver enzyme values towards the end of the experiment while blood flow continued to decline. At this time there is very little functional liver mass available.

Humans with liver cirrhosis maintain normal portal blood flow for a long time before it is finally reduced^{8,12,18}. However, the congestion index tended to be 2.5 times higher than in normal subjects while the velocity is reduced. Although the congestion index did not change significantly in our experiments, a similar trend could be observed. The significant changes in the congestion index and portal vein diameter in human cirrhosis occurred in the chronic stage, which

was possibly not reached in our study due to limited time frame. In humans, the congestion index and the portal vein flow velocity changed the most and may allow for a noninvasive diagnosis of liver disease. The congestion index is also affected by other factors including portal venous pressure, portal vascular resistance in the liver, portal blood flow volume, and the development of portal systemic shunts. Invasive studies had shown that portal pressure increased and portal flow was reduced^{1,23)}.

The true incidence of liver and biliary disease in the dog is unknown and probably it is underestimated. This may be due to the inability to specifically evaluate the biliary system with current methods. Ultrasonography has proven to be beneficial in the diagnosis of biliary disease^{19,24)}. In normal dogs, neither hepatic arteries nor intra- or extra-hepatic biliary channels can be routinely visualised by ultrasound. Biliary vessels can be distinguished from dilated portal venous vessels by their extensive branching pattern compared with the straighter blood vessels¹⁵⁾. The presence of channels without echogenic walls within the liver in a dog with jaundice will lead the examiner to suspect biliary obstruction. Gallstones, bile sludge, or neoplasms within the gallbladder can all be easily identified^{3,16)}.

Doppler ultrasound provided complementary functional information about the liver and the biliary system which may help to minimise the need for invasive procedures such as laparotomy or laparoscopy. Doppler ultrasound might be a useful tool for evaluating changes in portal blood flow which may affect liver function.

References

- 1) Bosch, J., Enriquez, R., Grossmann, R. J. and Storer, E. H. 1983. Chronic bile duct ligation in the dog: Characterization of a portal hypertensive model. *Hepatology*, 3: 1002-1007.
- 2) Chin, N., Ohnishi, K., Iida, S. and Nomura, F. 1988. Role of intrahepatic portal-systemic shunts in the reduction of portal blood supply to liver cells in cirrhosis. *Am. J. Gastroenterol.*, 83: 718-722.
- 3) Finn, S., Park, R. D., Twedt, D. C. and Curtis, C. R. 1991. Ultrasonographic assessment of sinclide-induced gallbladder emptying: An aid to the diagnosis of biliary obstruction. *Vet. Radiol.*, 33: 269-276.
- 4) Gill, R. W. 1979. Pulsed Doppler with B-mode imaging for quantitative blood flow measurement. *Ultrasound Med. Biol.*, 5: 223-225.
- 5) Guelfi, J. F., Braun, P., Benard, P. and Rico, A. G. 1982. Value of so called cholestatic markers in the dog: an experimental study. *Res. Vet. Sci.*, 33: 309-312.
- 6) Ingh, T. S. G. A. M. van den, Rothuizen, J. and Meyer, H. P. 1995. Circulatory disorders of the liver in dogs and cats. *Vet. Quart.*, 17: 70-76.
- 7) Kantrowitz, B. M., Nyland, T. G. and Fisher, P. E. 1989. Estimation of portal blood flow using duplex real-time and pulsed Doppler ultrasound imaging in the dog. *Vet. Radiol.*, 30: 222-226.
- 8) Kawasaki, T., Moriyasu, F., Kimura, T., Someda, H., Tamada, T., Yamashita, Y., Ono, S., Kajimura, K., Hamato, N. and Okuma, M. 1990. Hepatic function and portal hemodynamics in patients with liver cirrhosis. *Am. J. Gastroenterol.*, 85: 1160-1164.
- 9) Lamb, C. and Mahoney, P. N. 1994. Comparison of three methods for calculating portal blood flow velocity in dogs using duplex-Doppler ultrasonography. *Vet. Radiol. Ultrasound*, 35: 190-194.
- 10) Ljubicic, N., Duvnjak, M., Rotkvic, I. and Kopjar, B. 1990. Influence of the degree of liver failure on portal blood flow in patients with liver cirrhosis. *Scand. J. Gastroenterol.*, 25: 395-400.
- 11) Moreno, H. A., Burchell, A. R., Rousselot, L. M., Panke, W. F., Slafsky, F. and Burke, J. H. 1967. Portal blood flow in cirrhosis of the liver. *J. Clin. Invest.*, 46: 436-445.
- 12) Moriyasu, F., Nishida, O., Ban, N., Nakamura, T., Sakai, M., Miyake, T. and Uchino, H. 1986. "Congestion Index" of the portal

- vein. *Am. J. Roentgenol.*, 146 : 735–739.
- 13) Miyamoto, T., Hagio, M., Mwanza, T., Kobayashi, T., Okumura, M. and Fujinaga, T. 1995. Quantitative measurement of canine renal arterial blood flow using Doppler ultrasonography. *J. Vet. Med. Sci.*, 57 : 785–788.
 - 14) Mwanza, T., Miyamoto, T., Okumura, M., Hagio, M. and Fujinaga, T. 1996. Ultrasonographic and angiographic examination of normal canine liver vessels. *Jpn. J. Vet. Res.*, 44 : 179–188.
 - 15) Mwanza, T., Miyamoto, T., Okumura, M., Kadosawa T. and Fujinaga, T. 1997. Ultrasonography, biochemical and hematological profiles in liver disease caused by intravenous administration of dimethylnitrosamine in dogs. *Jpn. J. Vet. Res.*, 45 : 153–161.
 - 16) Nyland, T. G. and Fisher, P. E. 1990. Evaluation of experimentally induced canine hepatic cirrhosis using Doppler ultrasound. *Vet. Radiol.*, 31 : 189–194.
 - 17) Nyland, T. G. and Gillett, N. A. 1982. Sonographic evaluation of experimental bile duct ligation in the dog. *Vet. Radiol.*, 23 : 252–260.
 - 18) Ohlsson, E. G., Rutherford, R. B., Haalebos, M. P., Wagner, H. N. and Zuidema, G. 1970. The effects of biliary obstruction on hepatoplanchnic blood flow in dogs. *J. Surg. Res.*, 10 : 201–208.
 - 19) Ohnishi, K., Saito, M., Nakayama, T., Ida, S., Nomura, F. Koen, H. and Okuda, K. 1985. Portal venous hemodynamics in chronic liver disease : Effects of posture change and exercise. *Radiology*, 155 : 757–761.
 - 20) Raptopoulos, V., Fabian, T. M., Silva, W., Karellas, A. and Compton, C. C. 1985. The effect of time and cholecystectomy on experimental biliary tree dilatation. *Invest. Radiol.*, 20 : 276–286.
 - 21) Shasha, S. M., Better, O. S., Chaimovitz, C., Donan, J. and Kishon, Y. 1976. Hemodynamic studies in dogs with chronic bile-duct ligation. *Clin. Sci.*, 50 : 533–537.
 - 22) Suter, P. F. 1976. Hepatic circulatory anatomy and its role in liver disease. *Am. Anim. Hosp. Assoc., Proc. 43rd Annual Meeting* : 240–243.
 - 23) Taylor, K. J. W., Burns, P. N., Woodcock, J. P. and Wells, P. N. T. 1979. Blood flow in deep abdominal and pelvic vessels : Ultrasonic pulsed Doppler analysis. *Radiology*, 154 : 487–493.
 - 24) Willems, B., Villeneuve, J-P. and Huet, P. M. 1986. Effect of propranolol on hepatic and systemic hemodynamics in dogs with chronic bile duct ligation. *Hepatology*, 6 : 92–97.
 - 25) Wu, J. and Norton, P. 1996. Animal models of liver fibrosis. *Scand. J. Gastroenterol.*, 31 : 1137–1143.
 - 26) Zeman, R. K., Taylor, K. J. W., Rosenfield, A. T., Schwartz, A. and Gold, J. A. 1981. Acute experimental biliary obstruction in the dog : Sonographic findings and clinical implications. *Am. J. Roentgenol.*, 136 : 965–967.