



Title	STUDY ON THE PIGS INFECTED WITH VIRULENT TESCHEN DISEASE VIRUS (KNM STRAIN) WITH SPECIAL REFERENCE TO IMMUNOFLUORESCENCE
Author(s)	WATANABE, Hiroshi; POSPISIL, Zdenek; MENSIK, Jarmir
Citation	Japanese Journal of Veterinary Research, 19(4), 87-102
Issue Date	1971-12
DOI	10.14943/jjvr.19.4.87
Doc URL	http://hdl.handle.net/2115/1983
Type	bulletin (article)
File Information	KJ00002369925.pdf



[Instructions for use](#)

STUDY ON THE PIGS INFECTED WITH VIRULENT TESCHEN DISEASE VIRUS (KNM STRAIN) WITH SPECIAL REFERENCE TO IMMUNOFLOUORESCENCE*¹

Hiroshi WATANABE*²

Zdeněk POSPÍŠIL and Jarmír MENŠÍK

*Department of Infectious Disease,
Veterinary Research Institute,
Brno, Czechoslovakia*

(Received for publication, June 4, 1971)

Conventional pigs of 4-week-old were infected with KNM strain of virulent Teschen disease virus by intracerebral (IC), intranasal (IN) and contact (CT) routes.

The pigs of the IC group showed a very clear relation among clinical signs, virus multiplication and antibody production. Six days after infection (DAI), half the number of group pigs showed sudden neural disorders, the first multiplied viral antigens were seen in the brain by the fluorescent antibody (FA) technique and the virus was first isolated from the serum sample. Seven DAI, all pigs examined showed the most abundant fluorescence in the central nervous system (CNS). Rapid decrease of fluorescence in the CNS, except for the thalami, occurred on the days following immediately. The pigs of the IN and the CT groups did not show such clear phases of infection. No neural disorders occurred in the CT group in particular. The pigs showed no fluorescence in the spinal cords, though vacuolated neurons were usually seen in the cords as they were also in the other 2 groups.

After the middle stage of infection, all pigs showed fluorescence in the capillary endothelial cells of the brain. The most widespread appearance of fluorescence was commonly seen in the cerebellums. A number of Purkinje's cells of the cerebellums disappeared and the neurons in the spinal cords vacuolated in all pigs in the latter stage of infection. At this time, aggregated fluorescent neurons were often seen in the thalami. Appearance of fluorescence was usually less pronounced in the spinal cords. Abundant nonspecific fluorescent cells were found in the mesenteric lymph nodes and in the intestines.

The relation between occurrence of fluorescence and of lesions described by some workers was further discussed.

INTRODUCTION

TREFNY (1930) first described the outbreak of porcine polioencephalomyelitis

*¹ This work was supported by the Czechoslovakian Ministry of Agriculture and carried out in the Veterinary Research Institute, Brno, Czechoslovakia.

*² Present address: Department of Epizootiology, Faculty of Veterinary Medicine, Hokkaido University, Sapporo, Japan.

known as Teschen disease in Czechoslovakia in 1929. Subsequently, KLOBOUK (1931) showed the disease to be caused by a virus.

The characteristic histopathology of the CNS, especially of the spinal cords, of the pigs infected with Teschen disease virus consisted of the destruction of neurons, neuronophagy, cell nodules and perivascular infiltrations^{4,13,21,22}. Detailed epizootiology of the disease was described by HORSTMANN (1952). Outbreaks of porcine polioencephalomyelitis in the USA were reported and the spinal cords of the diseased pigs were observed with an electron microscope^{18,19}.

Some problems in isolation tests of enteroviruses from the feces of conventional pigs were suggested by some workers^{5,8,9,15} who detected naturally-contaminated viruses from fecal samples.

KOVACS et al. (1963) suggested by the FA technique that leucocytes acted not only as a vehicle carrying poliomyelitis viruses, but also as host cells for virus replication. The first fluorescence was observed in the neurons of the cerebrum of chicks 24 hours after IC inoculation with avian encephalomyelitis virus and strong fluorescence developed in Purkinje's cells of the cerebellum^{7,23}. Both fluorescence of avirulent Teschen disease virus (V 76 strain) and of a porcine enterovirus (Kr 69TC strain) appeared similarly in porcine kidney cultured cells. But the fluorescence of avirulent Teschen disease virus (Z strain) occurred in only the CNS and Kr 69TC strain in only the lungs of pigs (WATANABE, 1971 & the author's unpublished report).

Several workers^{10,11,25,27,32} described nonspecific fluorescence in granular, reticular and lymphoid cells. NAIRN (1968) proposed the necessity for control studies containing 3 conditions to eliminate nonspecific fluorescence.

The present report deals with findings of FA staining and virus multiplication in the pigs infected with virulent Teschen disease virus. At the same time, the authors tried to clarify the relation among obvious lesions in the spinal cord, the intestine excreting the virus for a long time and virus multiplication points.

MATERIALS AND METHODS

Virus

KNM strain which belongs to Konratice strain virus of Teschen disease virus group isolated in western Slovakia was supplied by V. MÁDR, Bioveta Laboratory, Czechoslovakia. After 9 passages in porcine brains, the infected brain possessed the titer of approximately 10,000 LD₅₀/g. The brain was emulsified and diluted 10 times in phosphate buffered saline (PBS) solution containing 200 U/ml of penicillin and 200 µg/ml of streptomycin. The infectious brain emulsion was stored at -20°C until used.

Cell culture

Primary monolayer cultures of porcine kidney were prepared in accordance with

another report³³).

Antiserum

KNM strain, $10^{4.5}$ TCID₅₀/0.1 ml, after 4 passages in porcine kidney cell culture, was used to produce antiserum. Adult rabbits were inoculated subcutaneously with the infectious cell culture fluid in accordance with another report³³).

Animals

Thirty-five conventional pigs, 4-week-old and of Large White stock, were isolated in 3 pens of one animal house prior to the inoculation. Each group of 14, 14 and 7 pigs respectively was infected by IC, IN and CT routes in turn.

Infection procedure

Intracerebral inoculation A lumbar puncture needle was quickly pushed through the left frontal bone. The needle was withdrawn and through the hole a fine hypodermic needle was inserted to a depth of 2 cm. One ml of the inoculum was injected with a syringe.

Intranasal inoculation The pigs were laid on their backs and 2 ml of the inoculum was dropped into the nostrils with a syringe.

Contact infection This group was placed on the opposite side of the IC group. The passage between the 2 groups was one and 1/2 meters wide.

Clinical signs

The pigs were observed daily and clinical signs of illness were recorded. Rectal temperatures were also recorded. On optional days, pigs were killed for postmortem examinations.

Tissue collection

Serum samples were collected from defibrinated blood of the pigs at slaughter and stored at -20°C . At necropsy, rectal feces were collected for virus isolation and an approximately 10% suspension of the feces was prepared in Earle's buffered salt solution (BSS) containing 1,000 U/ml of penicillin, 1,000 $\mu\text{g}/\text{ml}$ of streptomycin and 500 U/ml of mycostatin. This suspension was frozen, dissolved once, centrifuged at 4,000 rpm for 30 minutes and the supernatant was stored at $20 -^{\circ}\text{C}$.

The motor cortex of the cerebrum, the cerebellum, the thalamus, the cervical and the lumbar parts of the spinal cord, the mesenteric lymph node, 2 levels of the duodenum, the jejunum, the ileum and the rectum were removed from each pig. The pieces of the divided tissue were immediately frozen in alcohol immersed solid CO_2 and stored at -70°C until they were fixed in acetone for the FA staining.

Virus isolation

Four tubes of primary cell culture of porcine kidney were inoculated with 0.2 ml of the serum or the fecal suspension. After absorption at 37°C for one hour, the inoculum was removed and the maintenance medium was added. The cultures were further incubated at 37°C . One and 2 blind passages, respectively, of the serum and the fecal suspension were made before they were judged to be negative or positive for virus. At the second

and the third passages, the cultures were checked for virus every day for 9 days.

The cultures considered to be positive for virus were confirmed with the antiserum to KNM strain; a mixture of approximately 100 TCID₅₀ of each isolated virus and 20 unites of the neutralizing antibody to KNM strain were inoculated onto cell cultures.

Neutralization tests

The serums collected at slaughter were heated at 60°C for 15 minutes to inactivate the viruses possibly existing in them according to ŽUFFA (1962.)

Serial 4-fold dilution of the serum prepared in Earle's BSS and infective cell culture fluid of KNM strain containing approximately 100 TCID₅₀/0.1 ml were mixed in an equal volume. The mixture was maintained at 37°C for one hour and 0.2 ml of the mixture was inoculated into 4 tubes of cell culture. After the tubes were incubated at 37°C for one hour, 0.8 ml of maintenance medium was added and the cultures were incubated at 37°C. Cytopathic effect was examined daily till 7 DAI. The 50% end point of serum was expressed as reciprocal of the dilution of the serum which protected half the cultures inoculated with the virus-serum mixture. This dilution of the serum was arbitrarily defined to provide one unit of neutralizing antibody.

Fluorescent antibody technique

The frozen tissues were dissolved and fixed in acetone at 4°C over night. The tissues were embedded in paraffin according to the method described by SAINT-MARIE (1962). Embedded tissues were sectioned by a microtome and air dried.

The indirect FA technique was applied to stain the sections. They were initially overlaid with a 1:20 concentration of the unlabeled rabbit antiserum which was absorbed by porcine liver powder before use, in a moist chamber at room temperature for 30 minutes and washed with PBS solution 4 times in 30 minutes. The sections were secondarily overlaid with labeled anti-rabbit porcine globulin made in the Institute of Sera and Vaccines, Czechoslovakia, at room temperature for 30 minutes, washed with PBS solution 4 times in 30 minutes and mounted with 10% PBS solution in glycerin.

The specificity of fluorescent staining was confirmed by (1) the inhibition of fluorescence in the infected tissue section treated with unlabeled normal rabbit serum before staining with labeled globulin, (2) the blocking test and (3) the absorption test.

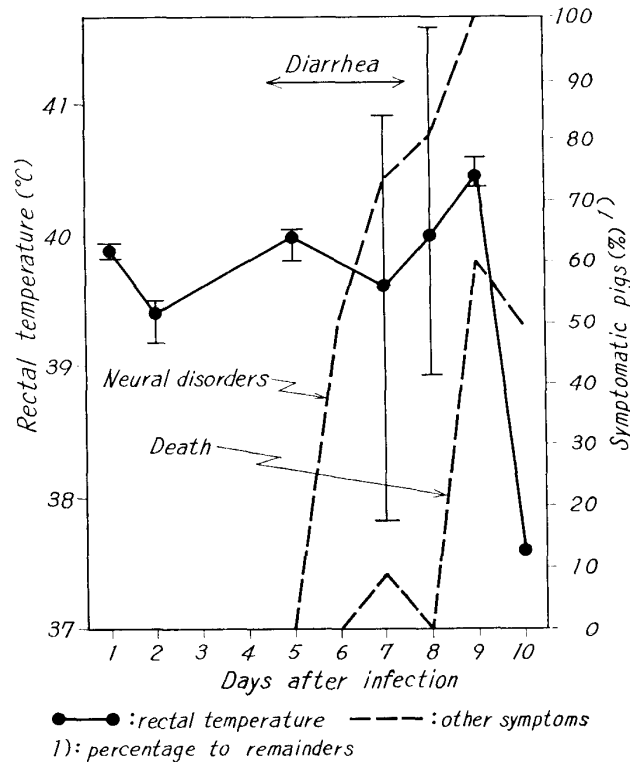
Samples prepared as stated above were examined under a fluorescent microscope, type ML-2 made in the USSR, equiped with a darkfield condenser.

RESULTS

Clinical signs

Intracerebral inoculation group: After the incubation period of 3 days, some pigs showed soft yellowish feces and a rise in rectal temperature. The feces then became grayish white, watery and profuse. The severest diarrhea occurred in the pigs 6 DAI when the first neural disorders suddenly developed in 6 of 12 pigs. Five pigs manifested severe paralysis by convulsions, dyspnea, slavering, screaming and lying down. All the paralyzed pigs remained in complete anorexia. One after another the pigs showed subsequent paralysis. Seven DAI, when the first death occurred, 2 of the 8 pigs showing paralysis

FIGURE 1 Disease produced after intracerebral infection with KNM strain



had a sharp fall in rectal temperature. Thereafter, the sharp fall was also noted in the remaining pigs.

No diarrhea was observed after 8 DAI. One pig without neural disorders showed a high temperature with a peak of 41.6°C during 7 to 9 DAI. All pigs of the group showed paralysis till the day and vigor of the pigs rapidly developed flaccid. Death followed on the first to the third day after the onset of paralysis (fig. 1).

Intranasal inoculation group: Soft feces and diarrhea appeared as in the IC group, the diarrhea was more severe in the IN group. On the 8th day, rectal temperature reached a peak of 41.1°C on the average. Neural disorders appeared 2 days later than those appearing in the IC group and paralysis also occurred later. A sharp fall in temperature was noticed after 10 DAI. The pigs which developed paralysis in the early stage tended to show higher temperature than the pigs developing paralysis in the later stage.

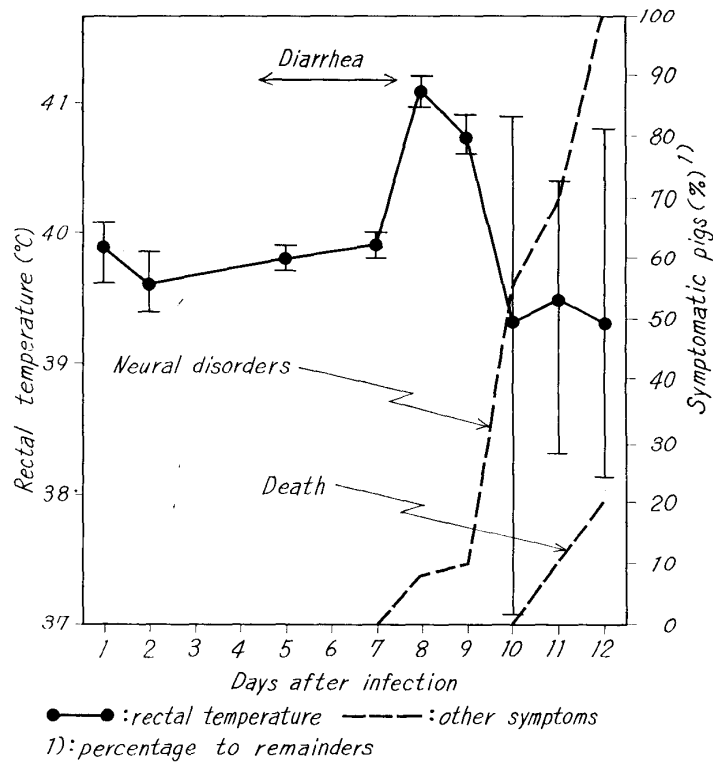
The first death in this group occurred 11 DAI and all pigs showed the same degree of paralysis as that observed in the IC group until 12 DAI (fig. 2).

Contact infection group: No obvious clinical signs were recognized except for temporary high rectal temperature, 9 to 10 DAI, and slight depression.

Recovery of virus

Following IC inoculation, the virus was recovered from all serum samples of the pigs examined 6 to 9 DAI. No virus was detected from the remaining serum samples of the

FIGURE 2 *Disease produced after intranasal infection with KNM strain*



pigs infected by all routes. Viruses were recovered from all fecal samples with the exception of one sample of a pig inoculated intracerebrally and examined 10 DAI (figs 3 & 4).

The viruses isolated from serum samples were identified with KNM strain, but the fecal viruses were not.

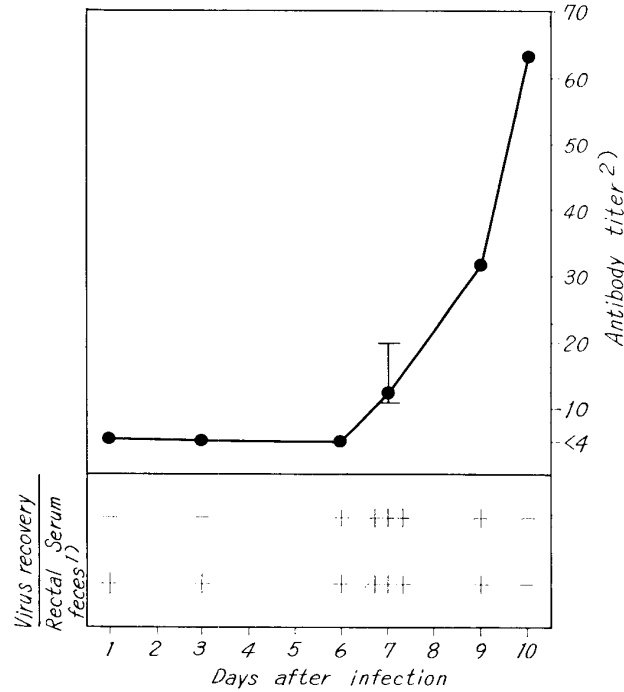
Development of antibody

Serum samples of the pigs inoculated intracerebrally had no detectable neutralizing antibody until 6 DAI. The titer of antibody rose from the 7th day and reached 1:64 ten DAI, the last experimental day. The titer of the IN group rose parallel with that of the IC group, but much more slowly (figs 3 & 4). Serums of only 2 of the 6 pigs in the CT group had a low neutralizing titer, 1:6, in the later stage.

Gross lesions in the organs

The most obvious gross lesion was intestinal congestion. From the third and the 4th days after IC and IN inoculations, respectively, the small intestines and the mesentery showed congestion in some degree. On the 4th day after IC inoculation, the whole intestines and a few parts of the mesenteric lymph nodes showed slight congestion. The stomachs were usually empty except for a large amount of mucus and all pigs showed congestion of the stomachs in the middle stage. Congestion in the large intestine, especially in the colon, and gas in the colon remained to the last experimental day of the IC group.

FIGURE 3 *Antibody production and virus excretion in pigs infected with KNM strain intracerebrally*



-:negative +:positive One mark shows one pig.
 1):judged after two blind passages.
 2):50% end point The virus used was a titer of $310 \text{ TCID}_{50} / 0.1 \text{ ml}$.

Congestion continued also in the colons and the mesenteric lymph nodes of some IN group pigs till the last experimental day. Gross lesions were very mild in the CT group.

No other obvious changes were observed except for a slight edema of the brains.

Fluorescence in the organs

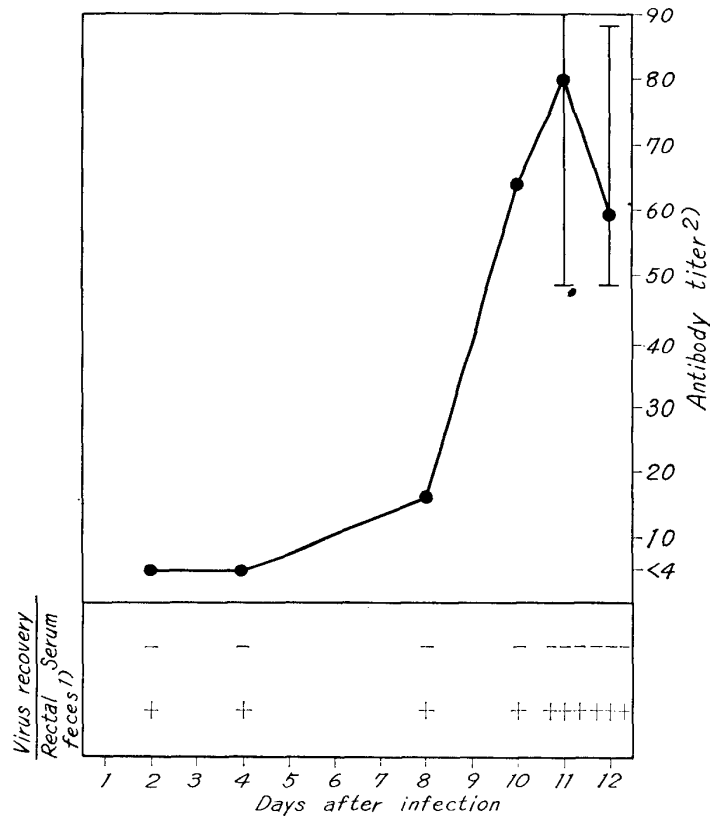
Intracerebral inoculation group: Specific fluorescence in the organs tended to appear in proportion to clinical signs. The characteristic features were especially seen in the brains and the appearance showed some distinct phases.

1) Brain Brilliant yellow-green fluorescence, presumably viral antigens injected, was sometimes found in the arteries and the veins of the brains in the earliest stage (fig. 8). The fluorescence was maintained in the cerebrums and the cerebellums to the 7th day.

Purkinje's cells of the cerebellum were the first neuron to appear fluorescence in the brain 6 DAI. The fluorescence was usually rather weak and a few Purkinje's cells showed vivid fluorescent granules in the cytoplasm.

Strong and dense fluorescence was suddenly found in all brain sections of 5 pigs examined 7 DAI. The most noticeable feature was shown by Purkinje's cells (figs 10 & 11). The fluorescent cells ranged 10~40% of all Purkinje's cells in every positive cerebellar section. The fluorescent cells tended to be one-sided only in a few flocculi. The features

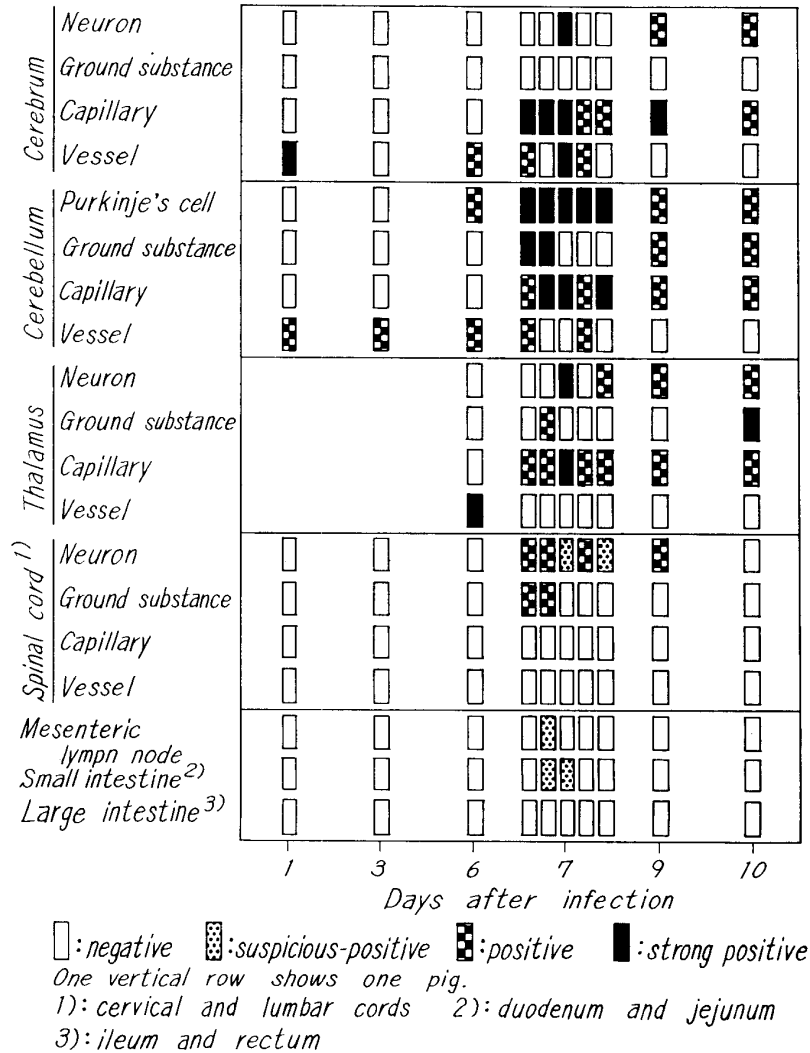
FIGURE 4 *Antibody production and virus excretion in pigs infected with KNM strain intranasally*



-:negative +:positive One mark shows one pig.
 1):judged after two blind passages.
 2):50% end point The virus used was a
 titer of 310 TCID₅₀ / 0.1 ml.

of fluorescence were varied; some Purkinje's cells showed fluorescent granules in both the cytoplasm and the dendrites, or dense fluorescence in the cytoplasm and fluorescent granules in the dendrites. Meanwhile, others showed only dense fluorescence in both the cytoplasm and the dendrites. No nuclei were observed in a number of fluorescent Purkinje's cells. In the ground substance of the cerebellum, fluorescence appeared also. The fluorescence was considered to consist of both fluorescence in the glial cells existing in Purkinje's, molecular layers and in the phagocytes of the whole gray and white matters. Dense fluorescence tended to be one-sided in a few flocculi where small fluorescent granules often gathered in circles (figs 19 & 20). Fluorescence further occurred in a few neurons of the cerebrum and the thalamus of a few pigs (fig. 9), although no fluorescence was seen in the ground substance of the cerebrum during the experimental period. It was an obvious and characteristic feature that fluorescence appeared consistently in the capillary endothelial cells of all samples of the brains from 7 DAI. Fluorescent capillaries in the cerebellum were characterized by the tendency to be concentrated in the cusps of some flocculi, often

FIGURE 5 Fluorescence in pigs infected with KNM strain intracerebrally



accompanied by dense fluorescent granules in the surrounding ground substance. In the cerebrums and the thalami, fluorescent capillaries also tended to exist in a few surrounding parts of the gray matters. Particularly, when the capillaries decreased in number, the phenomenon became clearer. Concentrated fluorescence was mainly seen in the cytoplasm of the endothelial cells of the capillaries (fig. 17).

Subsequent to 9 DAI, fluorescent neurons in the cerebellums and the cerebrums decreased rapidly in number and the fluorescence in intensity. On the other hand, vacuolated Purkinje's cells without fluorescence increased in number in the later stage and a number of Purkinje's cells in a large area often disappeared altogether. Fluorescent granules were scattered in the surrounding area of degenerated Purkinje's cells. Fluorescence also persisted in the rounded neurons of the cerebrums and in the thalami to the

last experimental day. In the later stage, a rare and interesting finding was obtained in that ten-odd fluorescent neurons were discovered to be localized in one part of the thalamus.

Two pigs of the IC group showed fluorescence in the neurons of all parts of the CNS 7 and 9 DAI (fig. 5).

2) **Spinal cord** Some fluorescent granules were found scattered in the ground substance of the gray and white matters, especially in the gray matters 7 DAI. From this day, a few fluorescent neurons were seen in the spinal cords (fig. 5). The neurons often revealed somewhat faint fluorescence. Almost fluorescent neurons were seen in the ventral horns (fig. 13) and a few fluorescent neurons were found in the dorsal nuclei also. Some fluorescent neurons tended to be shrunken and a number of neurons followed to be vacuolated. Appearance of fluorescence in the spinal cords was milder than that in the brains.

3) **Mesenteric lymph node** Abundant fluorescent granules which might contain nonspecific fluorescence were principally observed in the sinus stromas of the lymph nodes where large brilliant fluorescent granules appeared in the reticular cells and macrophages (fig. 21). So only the sections which satisfied the following conditions, were considered to be suspicious-positive. The conditions were: (1) more distinct fluorescent granules in the normally stained section than those in the section treated with normal rabbit serum before staining by the labeled globulin; (2) sharp reduction of fluorescence by the blocking test; and (3) absence of fluorescence by the absorption test. Only one sample examined 7 DAI satisfied all the conditions (fig. 5).

Fluorescent granules were most distinct 7 DAI. Subsequently, the lymphoid cells with cytoplasmic fluorescence increased in the whole stromas, especially in the periphery of the nodes. Fluorescence in lymphoid cells was considered to be nonspecific by the 3 conditions described above.

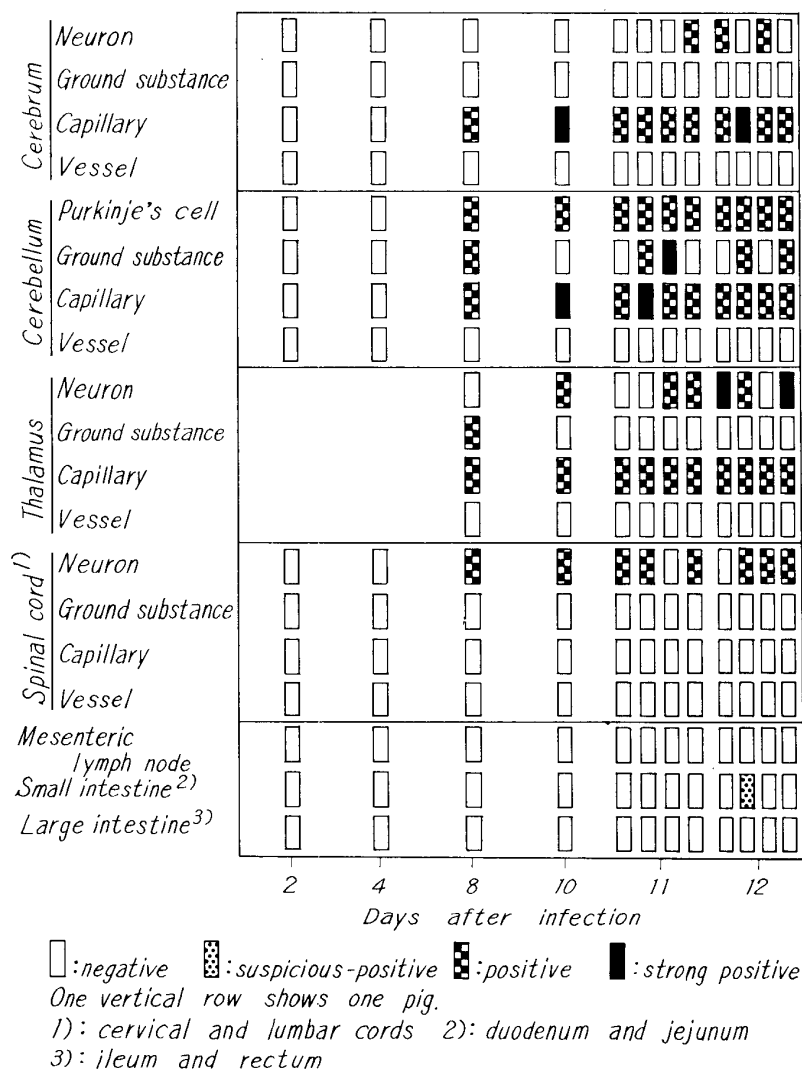
4) **Intestine** The mononuclear cells with cytoplasmic fluorescence were in a row under the basic membrane of the papillary epitheliums of the duodenum. The epitheliums were often stripped off entirely (fig. 23). The fluorescence was identified to be suspicious-positive (fig. 5).

Intranasal inoculation group 1) **Brain** The characteristic features of fluorescence were seen in the brains, but the appearance was not so apparent as that of the IC group. Phases of the appearance in the IN group were recognized one to 4 days later than that of the IC group.

First, some Purkinje's cells showed fluorescence 8 DAI. Although features of fluorescence were similar to that of the IC group, fluorescence of the IN group was usually rather weak. Fluorescence was also present in the ground substance of the cerebellum and the thalamus (fig. 18). The capillaries in all brain sections showed fluorescence after this day as in the IC group. The number of fluorescent capillaries was usually few and the intensity of their fluorescence faint (fig. 16).

Fluorescence in the neurons of the cerebrum and of the thalamus was granular and located in the cytoplasm. A few fluorescent neurons often tended to lump together, concentrating in the thalami and increasing in number on the last experimental day. Two

FIGURE 6 Fluorescence in pigs infected with KNM strain intranasally



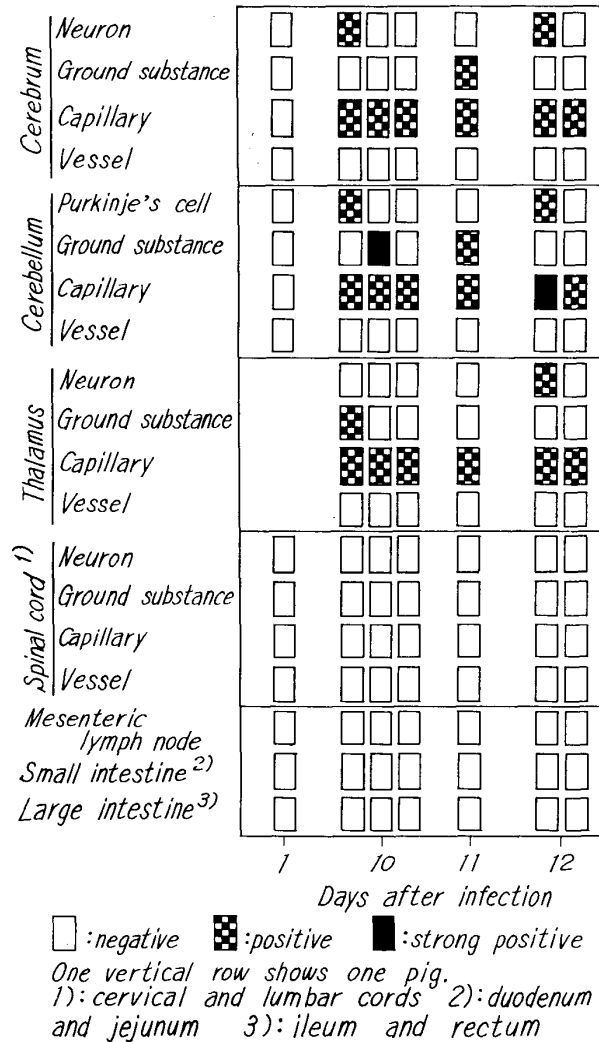
of 4 pigs in particular showed the ten-odd fluorescent neurons in one point of the thalami (fig. 12). On the other hand, the number of fluorescent Purkinje's cells were almost constant till the last experimental day. Vacuolation of Purkinje's cells, varying in number in individual cerebellar sections, with subsequent disappearance of the cells, followed in the latter stage of infection.

One pig of the IN group examined 11 DAI showed fluorescence in the neurons of all parts of the CNS (fig. 6).

2) Spinal cord Fluorescence was found in only a few neurons in the cords during the experimental period. A few vacuolated neurons also were usually present after 10 DAI (figs 6, 14, 15).

3) Mesenteric lymph node Nonspecific fluorescent granules gradually increased

FIGURE 7 *Fluorescence in pigs infected with KNM strain contactually*



in number within the first to the 10th day of infection, whereupon nonspecific fluorescent lymphoid cells followed and increased in the later stage (fig. 22). No specific fluorescence was identified in the nodes (fig. 6).

4) Intestine Nonspecific fluorescence was most evident in the macrophages, reticular cells and lymphoid cells 11 DAI and more obvious in the large intestine than in the small intestine. Suspicious-positive fluorescence was observed 12 DAI.

Contact infection group 1) Central nervous system Intensity of fluorescence was very weak. A few fluorescent neurons were found in the cerebellums, the cerebrums and the thalamus of a few pigs. Fluorescence was also observed occasionally in the ground substance of the brains. After 10 DAI, fluorescence was present in the capillaries in all sections of the brains. The fluorescent capillaries were characterized by weakness and localization.

2) Mesenteric lymph node No specific fluorescence was observed and nonspecific fluorescence was variable in the individual pig (fig. 7).

3) Intestine Only a few feeble nonspecific fluorescent cells occurred. No specific fluorescence was observed (fig. 7).

DISCUSSION

The first multiplied antigens appeared in the brain of the IC infection group pigs 6 DAI, when half of this group of pigs suddenly showed neural disorders. Though it was not certain just where in the brain the virus multiplied for the first time, the multiplication might concurrently have begun in the neurons and in the capillaries of the brain. The most distinct fluorescence appeared in every pig examined 7 DAI, followed by rapid decrease of the appearance. Results of the IC group indicated the very distinct relation among virus multiplication, virus excretion, clinical signs and antibody production. Responses of the pigs in the IN group developed one to 4 days later than that of the IC group and appearance of fluorescence in the IN group did not show such distinct phases. Responses of the animals in the CT group were more indistinct.

In the present experiment also, it was recognized that more than one viral agent existed in fecal samples as reported by some workers^{5,15}). Therefore, it was necessary to identify the isolated viruses in general, especially in fecal samples of conventional pigs. It was interesting that no viruses were isolated from the feces of one pig with clinical signs in the IC group.

The pigs infected by the IC route showed the severest clinical signs, followed by death. On the other hand, the pigs of the CT group developed no clinical signs except for temporary high rectal temperature and for slight depression. The close correlation between virus multiplication and the occurrence of neural disorders was supposed as follows: Appearance of fluorescence in the brains of the IC group pigs was much more distinct and appeared earlier than that of the IN and the CT groups. On the other hand, the biggest difference of fluorescent appearance in the organs of the CT group pigs to that of the other 2 groups was thought to be that no fluorescence was recognized in the spinal cords during the experimental period. These results suggest that in manifestation of neural disorders due to Teschen disease virus, the virus must cause the neurons of the brain to degenerate over any limit and/or directly invades and makes the neurons of the spinal cord degenerate. We found that avirulent Teschen disease virus did not multiply in the neurons of the CNS of colostrum-deprived and -received baby pigs (unpublished data). The findings also support the present supposition.

Concerning lesions in the CNS of the pigs infected with porcine polioencepha-

lomyelitis virus, it was reported^{4,21,26)} that the earliest changes were an enlarged perivascular space with marked congestion of the vessels, followed by perivascular cuffings. KOESTNER et al. (1966) described crystalline arrays of particles, possible porcine polioencephalomyelitis viruses, that were found in the capillary endothelial cells of the spinal cord 14 DAI by an electron microscope. In our present experiment, fluorescence in the capillary endothelial cells of the brain was first seen 7 to 10 DAI in all groups. The fluorescence remained in all pigs till the last experimental day. Further, we observed the same finding in the CNS of a baby pig infected with avirulent Teschen disease virus (unpublished data). From these results, it is certain that capillary endothelial cells are an important place for multiplication and survival of Teschen disease virus.

The most widespread involvement of the CNS was observed in the ventral horn of the spinal cord by MANUELIDIS et al. (1954), who described intense destruction of the nerve cells and the presence of many neuronophagic and cell nodules. BETTS & JENNINGS (1960) also stated that more than 50% of the large nerve cells were affected in some sections of the cord. Meanwhile, RICHARDS & SAVAN (1960) recognized the greatest affection in the brain stem and a little less severe affection in the spinal cord. On the contrary, we observed the least fluorescence in the spinal cord. In fact, no fluorescence was found in the spinal cords of the CT group pigs. The most abundant and distinct fluorescence appeared in the cerebellums. Actually, approximately 40% of Purkinje's cells in 2 pigs showed fluorescence. It is interesting that a very few masses of several fluorescent neurons were sometimes seen in the thalami in the later stage of infection. The results suggest that the thalamus is an important organ for virus multiplication in the later stage.

In comparison with a mild appearance of fluorescence in the spinal cords, it was noticed that there was vacuolation of many neurons there in the later stage. Even in the CT group pigs having no neural disorders, vacuolated neurons were usually observed in the spinal cords. It is supposed from these findings that degeneration of the neurons of the spinal cord mainly follows from degeneration of the superior neurons of the brain. More frequent occurrence of fluorescence in the gray matter than in the white matter coincided with the occurrence of lesions.

Macrophages, leucocytes, endothelial cells and lymphoid cells were discovered to act as vehicles carrying engulfed viruses or target tissues of some viruses in FA tests by some workers^{10,11,20,25,29,32)}, although nonspecific fluorescence was also recognized in those cells^{10,11,25,27,32)}. In our experiment, prominent nonspecific fluorescence was observed in the mesenteric lymph node and in the intestine. The nonspecific fluorescence seemed to depend on that of macrophages, lymphoid

and reticular cells. It was noteworthy that the nonspecific fluorescence usually ran parallel to the occurrence of specific fluorescence in the other organs. Meanwhile, suspicious-positive fluorescence was observed in some sections of the mesenteric lymph nodes and of the intestines. These results suggest that both the agents of specific and nonspecific fluorescent reactions co-existed in those cells and that the occurrence of the agents of nonspecific reaction was more or less related to the agents of specific fluorescent reaction.

Porcine enterovirus has been isolated from feces or intestinal tissues and multiplication of the virus in the intestine has been suggested by many workers^{1,2,3,6,14,16,30,34}. We have found in our current experiment, however, that it was extremely difficult to identify specific fluorescence in the intestine and in still other experiments, particularly, the authors could find no trace of fluorescence in the intestine at all. It is unknown, however, whether these indications are due to the limited ability of the FA tests to detect the virus, or whether for other reasons the tests read negative. At least, the authors are of opinion that the intestine is not so important organ for multiplication of Teschen disease virus as has been heretofore supposed.

ACKNOWLEDGEMENTS

The authors wish to thank Dr. J. ŠTĚPÁNEK of the Veterinary Research Institute for his help and advice during all the stages of research. Drs. V. MÁDR and B. MACURA of the Bioveta Laboratory, Opava, Czechoslovakia arranged this experiment and supplied KNM strain. The authors are glad to thank them.

The authors further wish to express their gratitude to Mmes. J. POŠTULKOVÁ and M. BRYMOVÁ for their skillful technical assistance in the FA tests. Appreciation is due also to other members of the Veterinary Research Institute for helping this study.

REFERENCES

- 1) ALEXANDER, T. J. L. & BETTS, A. O. (1967): *Res. vet. Sci.*, **8**, 321
- 2) BABA, S. P., BOHL, E. H. & MEYER, R. C. (1966): *Cornell Vet.*, **56**, 386
- 3) BERAN, G. W., WENNER, H. A., WERDER, A. A. & UNDERDAHL, N. R. (1960): *Am. J. vet. Res.*, **21**, 723
- 4) BETTS, A. O. & JENNINGS, A. R. (1960): *Res. vet. Sci.* **1**, 160
- 5) BOHL, E. H., SINGH, K. V., HANCOCK, B. B. & KASZA, L. (1960): *Am. J. vet. Res.*, **21**, 99
- 6) CARTWRIGHT, S. F. & HUCK, R. A. (1963): *J. comp. Path.*, **73**, 27
- 7) CHEVILLE, N. F. & MANLUX, W. S. (1966): *Am. J. vet. Res.*, **27**, 1413
- 8) DERBYSHIRE, J. B., CLARKE, M. C. & JESSETT, D. M. (1966): *Vet. Rec.*, **79**, 595
- 9) DERBYSHIRE, J. B., CLARKE, M. C. & JESSETT, D. M. (1969): *J. comp. Path.*, **79**, 97
- 10) GOLGROVE, G. S., HAELTERMAN, E. O. & COGGINS, L. (1969): *Am. J. vet. Res.*, **30**, 1343
- 11) HEUSCHELE, W. P., COGGINS, L. & STONE, S. S. (1966): *Ibid.*, **27**, 477
- 12) HORSTMANN, D. M. (1952): *J. Immun.*, **69**, 379

- 13) HORSTMANN, D. M., MANUELIDIS, E. & SPRINZ, H. (1951): *Proc. Soc. exp. Biol. Med.*, **77**, 8
- 14) IZAWA, H., HOWARTH, J. A. & BANKOWSKI, R. A. (1962): *Am. J. vet. Res.*, **23**, 1142
- 15) KASZA, L. (1965): *Ibid.*, **26**, 131
- 16) KELLY, D. F. (1964): *J. comp. Path.*, **74**, 381
- 17) KLOBOUK, A. (1931): *Zver. Obzor*, **24**, 436, 460 & 477
- 18) KOESTNER, A., KASZA, L. & HOLMAN, J. E. (1966): *Am. J. Path.*, **49**, 325
- 19) KOESTNER, A., LONG, J. F. & KASZA, L. (1962): *J. Am. vet. med. Ass.*, **140**, 811
- 20) KOVACS, E., BARATAWIDJAJA, R. K., WALMSLEY-HEWSON, A. & LABZOFFSKY, N. A. (1963): *Arch. ges. Virusforsch.*, **14**, 143
- 21) LONG, J. F., KOESTNER, A. & KASZA, L. (1966): *Am. J. vet. Res.*, **27**, 274
- 22) MANUELIDIS, E. E., SPRINZ, H. & HORSTMANN, D. M. (1954): *Am. J. Path.*, **30**, 567
- 23) MOHANTY, G. C. & WEST, J. L. (1968): *Am. J. vet. Res.*, **29**, 2387
- 24) NAIRN, R. C. (1968): *Clin. exp. Immun.*, **3**, 465
- 25) PETER, C. P., GRATZEK, J. B. & RAMSEY, F. K. (1966): *Am. J. vet. Res.*, **27**, 1583
- 26) RICHARDS, W. P. C. & SAVAN, M. (1960): *Cornell Vet.*, **50**, 132
- 27) ROWE, D. S., CRABBÉ, P. A. & TURNER, M. W. (1968): *Clin. exp. Immun.*, **3**, 477
- 28) SAINT-MARIE, G. (1926): *J. Histochem.*, **10**, 250
- 29) SALENSTEDT, C. R. (1963): *Acta vet. scand.*, **4**, 384
- 30) SINGH, K. V., BOHL, E. H. & SANGER, V. L. (1964): *Cornell Vet.*, **54**, 612
- 31) TREFNY, L. (1930): *Zver. Obzor*, **23**, 235
- 32) TUOMI, J. & KANGAS, J. (1963): *Arch. ges. Virusforsch.*, **13**, 430
- 33) WATANABE, H. (1971): *Jap. J. vet. Res.*, **19**, 1
- 34) WENNER, H. A., BERAN, G. W. & WERDER, A. A. (1960): *Am. J. vet. Res.*, **21**, 958
- 35) ŽUFFA, A. (1962): *Vet. Čas.*, **11**, 165

EXPLANATION OF PLATES

PLATE I

- Fig. 8 Specific fluorescence in the artery of the cerebral cortex. The fluorescence is thought to show existence of the viral antigens injected. Virchow-Robin space is expanded.
Six days after intracerebral infection × 160
- Fig. 9 Each fluorescent neuron is isolated in the cerebral cortex. Fluorescence is seen in the cytoplasm and the axones, but not in the nucleus of the neuron.
Seven days after intracerebral infection × 160
- Fig. 10 Fluorescence is seen in Purkinje's cells of the cerebellum. Fluorescent granules are apparent in the dendrites. No nuclei are recognized.
Seven days after intracerebral infection × 80
- Fig. 11 Two Purkinje's cells adjoined to one another show fluorescence. The nuclei are observed.
Seven days after intracerebral infection × 320

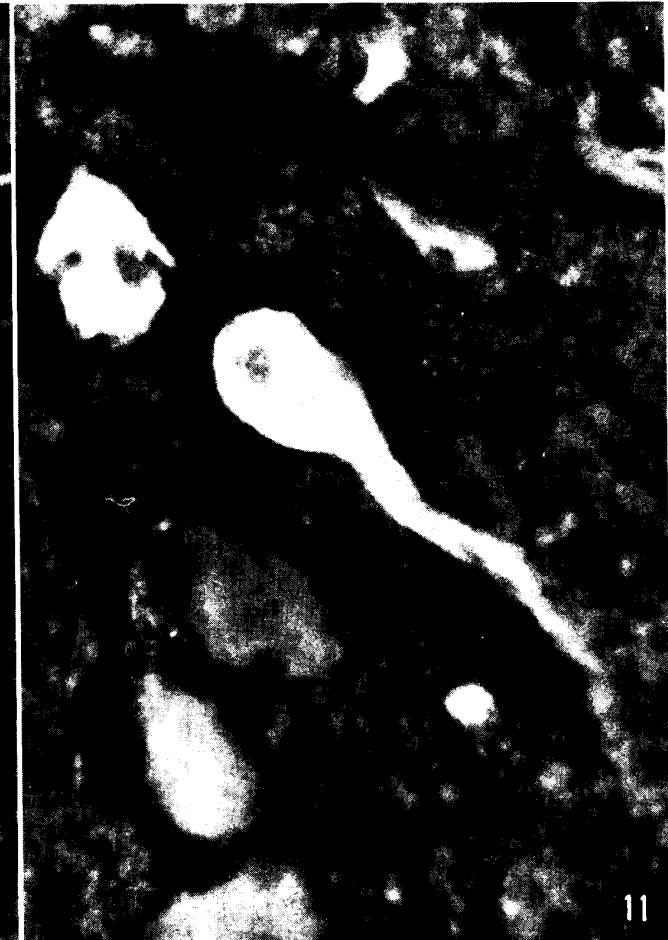
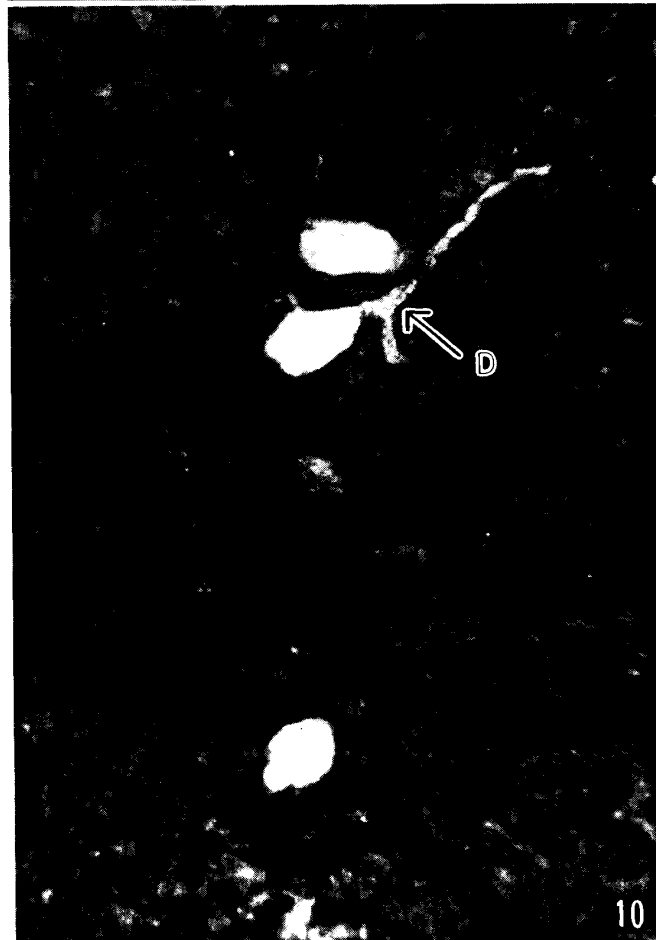
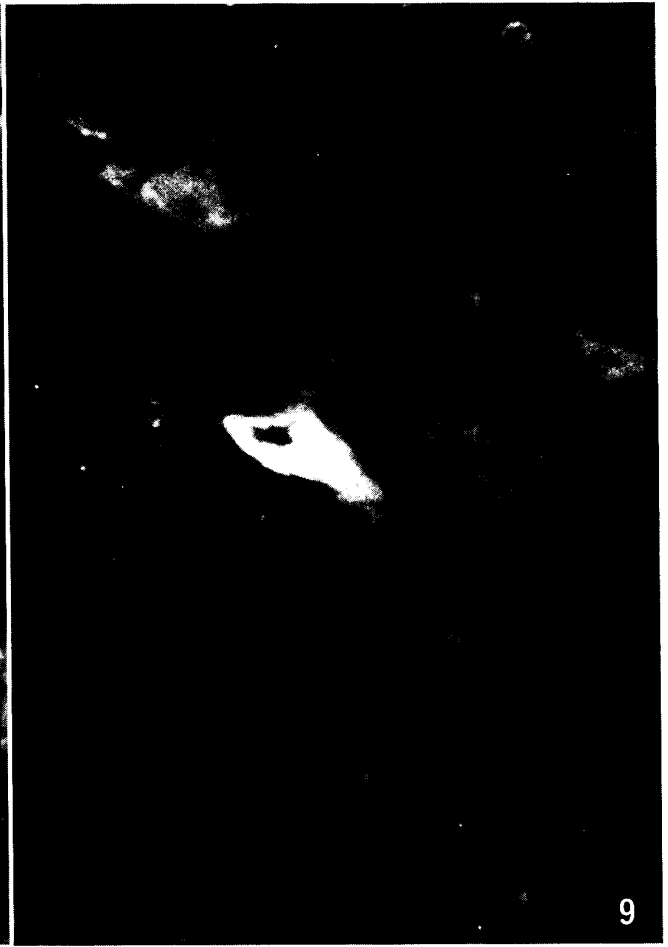PLATE II

- Fig. 12 Fluorescent neurons are gathered in one point of the thalamus. It is a characteristic feature of the thalamus in the later stage of infection.
Twelve days after intranasal infection $\times 80$
- Fig. 13 A large nerve cells in the ventral horn of the spinal cord shows weak fluorescence in the cytoplasm. Almost fluorescent neurons were seen in the ventral horn of the spinal cord.
Seven days after intracerebral infection $\times 160$
- Fig. 14 A fluorescent neuron in the dorsal horn of the spinal cord. The occurrence was rare in the dorsal horn.
Twelve days after intranasal infection $\times 80$
- Fig. 15 A fluorescent neuron in the dorsal nucleus of the spinal cord shows vacuolation.
Twelve days after intranasal infection $\times 160$

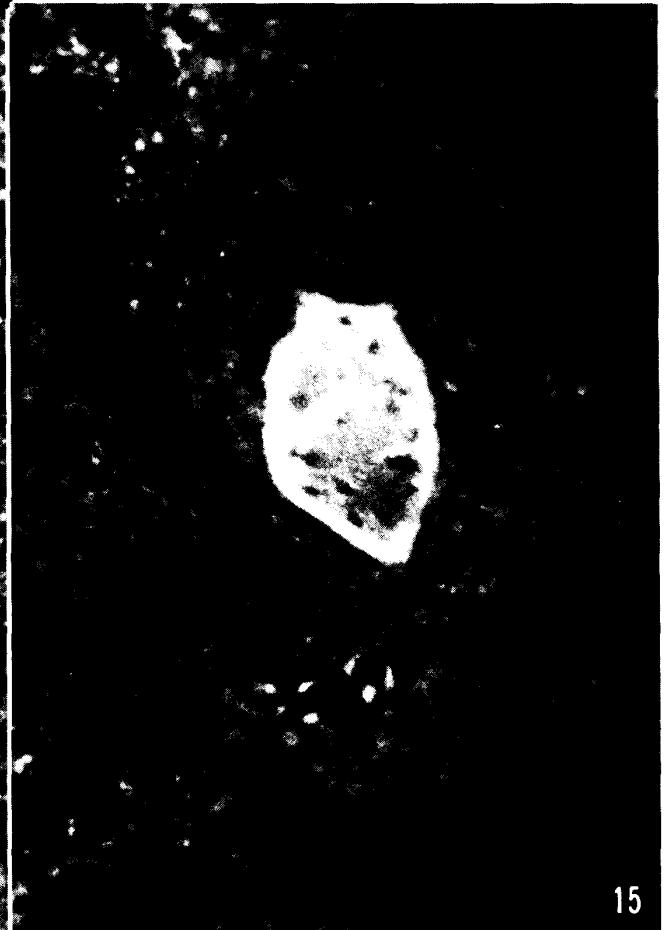
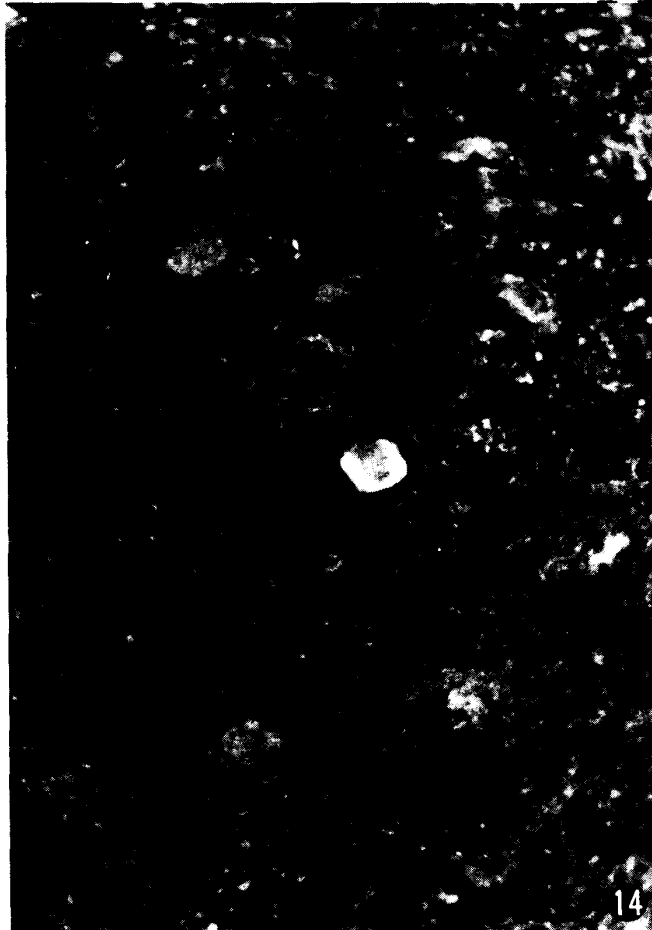
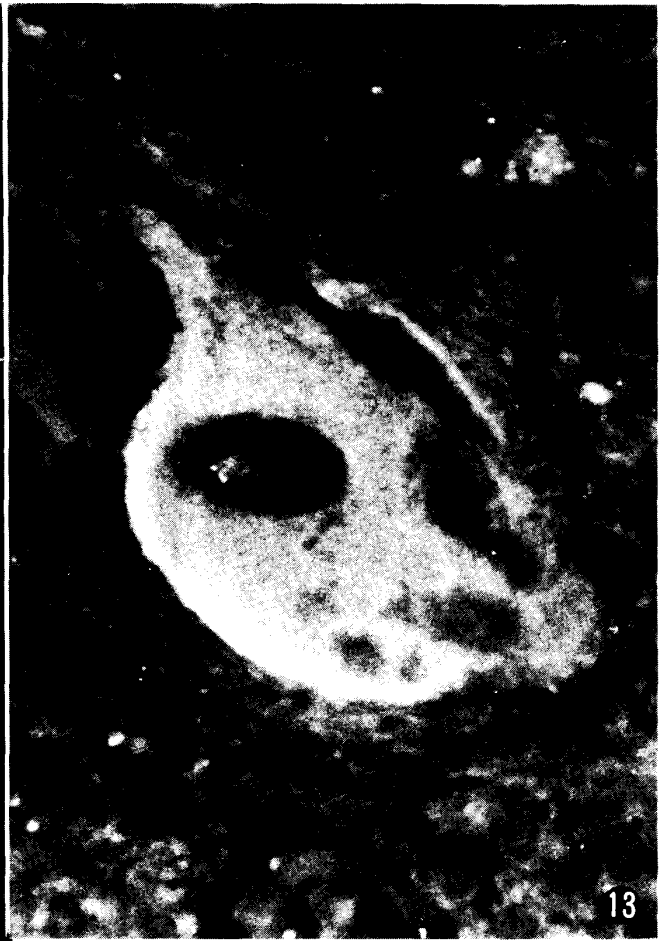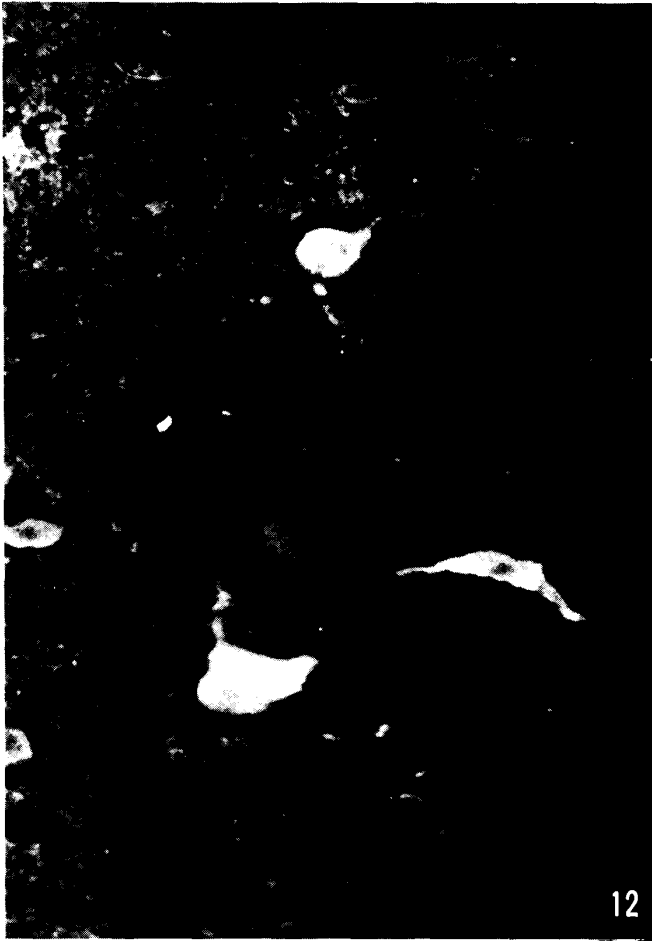PLATE III

Fig. 16 Capillary endothelial cells in the cerebellum showing fluorescence (F). This finding may be the first occurrence of fluorescence in the capillary.

Eight days after intranasal infection $\times 80$

Fig. 17 Capillary endothelial cells showing fluorescence. Fluorescence is seldom seen in the nuclei.

Ten days after intracerebral infection $\times 320$

Fig. 18 Lumps of fluorescent granules as seen in the ground substance of the white matter in the cerebellum.

Eight days after intranasal infection $\times 640$

Fig. 19 Lumps of fluorescent granules in the ground substance of the molecular layer in the cerebellum.

Ten days after intracerebral infection $\times 160$

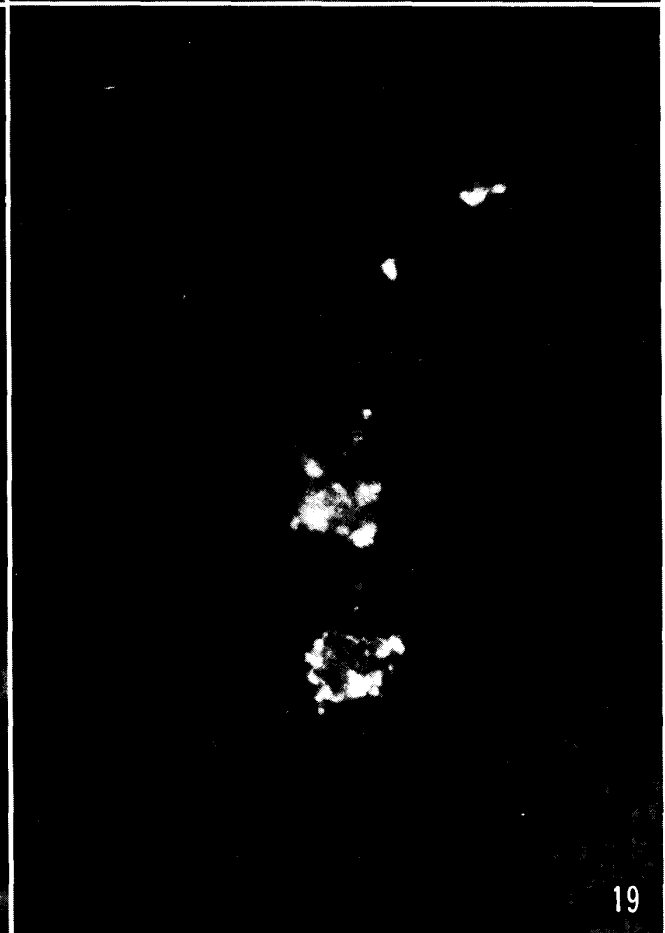
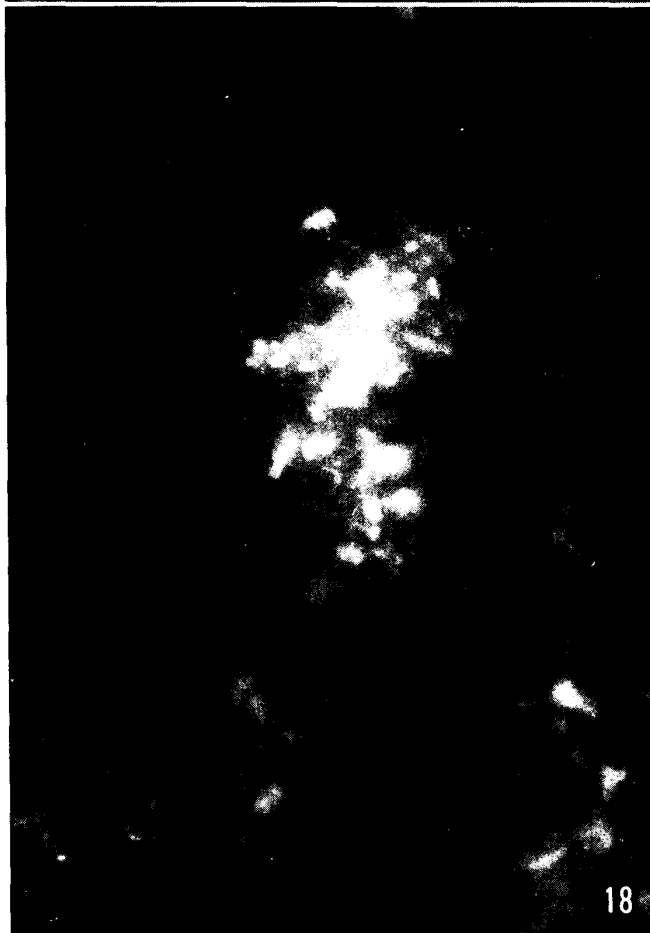
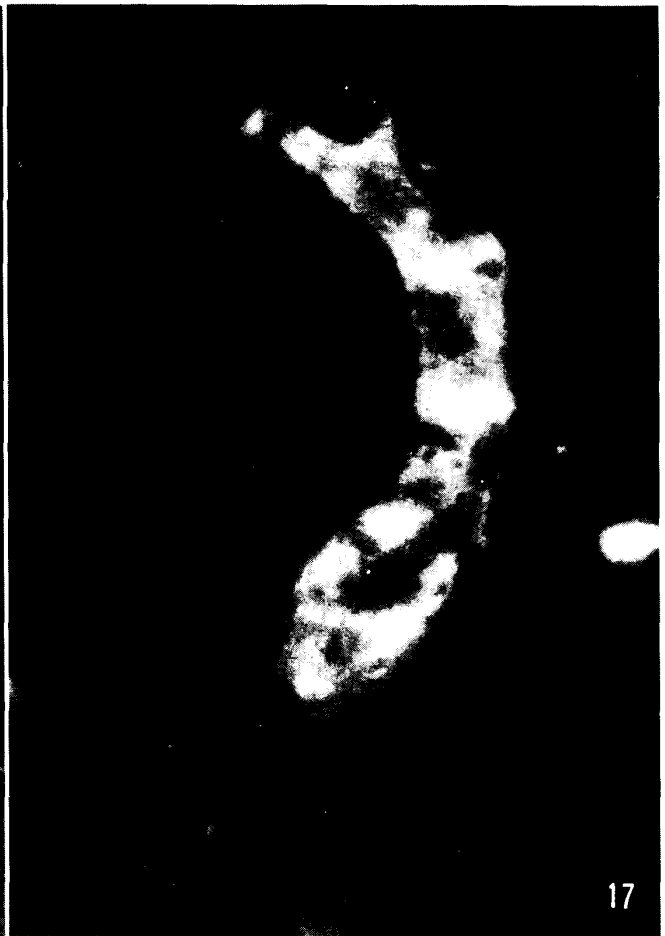
PLATE IV

- Fig. 20 Lumps of fluorescent granules are scattered in the ground substance of the granular cell layer in the cerebellum.
Ten days after intracerebral infection $\times 160$
- Fig. 21 Fluorescent granules determined to be suspicious-positive, as seen in the sinus stroma along the lymph cavity (LC) of the mesenteric lymph node.
Seven days after intracerebral infection $\times 320$
- Fig. 22 Lymphoid cells showing nonspecific fluorescence in the cytoplasm. Normally occurring throughout the stroma of the mesenteric lymph node in the later stage of infection.
Twelve days after intranasal infection $\times 80$
- Fig. 23 Mononuclear cells showing nonspecific fluorescence and existing under the basic membrane of the villus as found in the duodenum. The mucosa are stripped.
Seven days after intracerebral infection $\times 320$

