



Title	ONCOGENICITY OF INFECTIOUS CANINE HEPATITIS VIRUS IN HAMSTERS
Author(s)	KINJO, Toshio; YANAGAWA, Ryo; FUJIMOTO, Yutaka
Citation	Japanese Journal of Veterinary Research, 16(4), 145-158
Issue Date	1968-12
DOI	10.14943/jjvr.16.4.145
Doc URL	http://hdl.handle.net/2115/1916
Type	bulletin (article)
File Information	KJ00002369741.pdf



[Instructions for use](#)

ONCOGENICITY OF INFECTIOUS CANINE HEPATITIS VIRUS IN HAMSTERS*¹

Toshio KINJO, Ryo YANAGAWA
and Yutaka FUJIMOTO*²

*Department of Hygiene and Microbiology
Faculty of Veterinary Medicine
Hokkaido University, Sapporo, Japan*

(Received for publication, September 26, 1968)

INTRODUCTION

A number of adenoviruses have been proven oncogenic for newborn hamsters. These are human adenoviruses types 3 (HUEBNER et al., 1965), 7 (GIRARDI et al., 1964), 12 (TRENTIN et al., 1962), 18 (HUEBNER et al., 1962) and 31 (PEREIRA et al., 1965), avian adenovirus (CELO virus) (SARMA et al., 1965), several simian adenoviruses (HULL et al., 1965), and bovine adenovirus type 3 (DARBYSHIRE, 1966).

However, whether or not these adenoviruses can induce tumors in their natural hosts, especially in human beings, is completely obscure.

If the infectious canine hepatitis (ICH) virus, the so called "canine adenovirus" is proven to be oncogenic, we would have a rather suitable system to use, ICH virus and a dog as a recipient, for analysis of the virus-host interaction, in relation to oncogenesis.

From this point of view, prior to demonstrating the oncogenicity of the ICH virus for its natural host, our intension is to show the oncogenic activity of the virus for newborn hamsters. Newborn hamsters are normally used for viral oncology.

While the present experiment was being carried out the oncogenicity of the ICH virus, for the newborn hamster, was shown by SARMA et al. (1967).

The present authors have confirmed the observations of SARMA et al. (1967). In addition we found that the antigen preparations from tissue culture cells derived from tumor cells, as well as those antigens from primary or transplanted tumor cells, reacted with sera from the tumor-bearing hamsters.

This report describes the induction of tumors by strains of the ICH virus and the serial transplantations of the primary tumor in hamsters. It also describes

*¹ Supported in part by a grant from the Ministry of Education

*² Department of Comparative Pathology, Faculty of Veterinary Medicine, Hokkaido University, Sapporo, Japan

the results of immunological and histopathological observations of these tumors.

A study of *in vitro* cultivation of the tumor cells will be reported in the following paper (KINJO et al., 1968).

MATERIALS AND METHODS

Virus strains Four strains of ICH virus, strains FD, Woc-4, N-III and Winthrop, were used in the studies on oncogenicity.

Details relating to the sources and serological properties of the strains were described in the preceding paper (KINJO & YANAGAWA, 1968).

These viruses were grown in dog kidney cell cultures (DKC). The cultures were harvested when almost all cells showed a cytopathic effect (CPE) and after being frozen and thawed once, they were centrifuged at 3,000 rpm for 30 min to remove cellular debris. The supernates, about 10^7 TCID₅₀ per ml, were utilized as virus materials for inoculation.

Hamsters and inoculation procedures One hundred nineteen newborn golden hamsters (17 litters) less than 24 hr of age were inoculated, subcutaneously in the nuchal region, or intraperitoneally with 0.01~0.02 ml of undiluted virus. Control animals were similarly treated except that they were given extracts from non-infected cell cultures. Tumor transplantations were carried out by inoculating suckling, weanling or adult hamsters with finely minced or trypsinized tumor tissues. This material was deposited mainly subcutaneously at the nape of the neck.

Observation of tumor development The animals were observed, at least, twice a week for the onset and progress of the induced tumors. Upon autopsy, individual serum samples were collected and we recorded the tumors weight, dimensions and gross appearance.

Aliquots of the tumor specimens were washed in a phosphate buffered saline (PBS) and then used for transplantation experiments, tissue culture studies, infectivity assays, and in preparing complement-fixing antigens. Other aliquots were placed in a 10% formalin solution for histopathological studies.

Complement fixation (CF) test The CF test was carried out by the methods ordinarily used in this laboratory (KINJO & YANAGAWA, 1967) except that the volume of each reagent was reduced to 2/5 of the usual volume.

Preparation of tumor antigen About 20% (v/v) extracts of tumor tissues from hamsters were homogenized, in PBS, using the Teflon glass grinder, held in an ice bath. The homogenates were then sonicated in Kubota's oscillator (KMS-100) at 10 KC for 10 min, and clarified by centrifugation at 9,000 rpm for 30 min. The supernates were then stored at -20°C until used as the tumor antigens.

Preparation of tissue culture T antigen (neoantigen) (HUEBNER et al., 1965) Monolayers of DKC were inoculated with strain FD of the ICH virus. The inoculated cultures were incubated at 37°C until CPE appeared in about 50% cells (2 to 3 days). Then the cells were scraped from the glass into fluids and centrifuged at 3,000 rpm for 30 min. The sedimented cells were resuspended in the supernatant fluid at 1/10 of the original volume, sonicated and centrifuged by the manner described above.

Sera from tumor-bearing hamsters were inactivated by heating at 56°C for 30 min.

RESULTS

1 Tumor induction by strains of ICH virus

Table 1 summarized the results of ICH virus inoculations into newborn hamster. The period of the observation for tumor production was 1 year.

TABLE 1 *Oncogenicity of infectious canine hepatitis (ICH) virus in newborn hamsters*

STRAIN	ROUTE *1	TUMOR OCCURRENCE IN HAMSTERS					
		No. inoculated	No. weaned	No. with tumor	Percentage of tumor development	Day of tumor appearance	
Woc-4	IP	16	13	1	7.7	3.9	198
	SC	17	13	0	0		
FD	IP	3	3	0	0	12.5	153, 160, 174
	SC	24	21	3	14.3		
N-III	IP	13	5	0	0	0	
	SC	7	5	0	0		
Winthrop	IP	14	4	0	0	0	
	SC	9	5	0	0		
Control	IP	10	7	0	0	0	
	SC	6	4	0	0		
Total		119 (103)*2	80 (69)	4 (4)	5.0 (5.9)		153~198

*1 IP: Intraperitoneal, SC: Subcutaneous

*2 Number in parenthesis indicates number of animals inoculated with the virus, the control animals which received normal fluid of DKC were excluded.

The strain FD produced subcutaneous tumors at the site of inoculation in 3 out of 21 hamsters inoculated, after 153, 160 and 174 days (fig. 1). These subcutaneous tumors developed about to 1.5 cm in diameter. Then the tumors regressed gradually and disappeared completely within 2 weeks.

The strain Woc-4 produced an intraperitoneal tumor in 1 out of 13 hamsters after a 198-day latent period (fig. 2). This tumor developed rapidly, and became very large in size and weight. The hamster was sacrificed at 214 days.

The rate of tumor induction was not high, 12.5% for FD and 3.9% for Woc-4 and the latent period was long (150~198 days). No tumors were observed during the 1 year observation in the animals receiving the other 2 strains (N-III and Winthrop) or in the control animals.

2 Transplantation ability of the ICH virus induced tumor

The intraperitoneal tumor (designated as HT-7) induced by strain Woc-4 was serially transplanted 5 times into newborn, suckling or adult hamsters. These results were summarized in tables 2 and 3. In the first transplant passage (tab. 2), tumor appeared at the site of inoculation in 28 out of 33 (84.8%) hamsters within 37 days following transplantation.

TABLE 2 *The first transplant passage of the primary tumor (HT-7) in hamsters*

EXP. NO.	TUMOR MATERIAL INOC. *1	DOSE	ROUTE	AGE OF HAMSTER	NO. WITH TUMOR/NO. INOC.	PERCENTAGE OF TUMOR DEVELOPMENT	DAY OF TUMOR APPEARANCE
21	Minced	0.5 ml	IP	37 days	5/5	100	20 (4)* 2, 23
22	Trypsinized	4×10 ⁵ cells/0.2	SC	31	4/6	62.5	20, 24 (2), 27
"	Minced	0.2	IP	"	1/2		20
23	"	0.2	SC	37	4/5	80	20 (3), 27
25	Trypsinized	4×10 ⁵ cells/0.2	"	58	7/8	87.5	24, 27 (4), 35, 36
27	" *3	1×10 ⁵ cells/0.1	"	1	4/4	100	23, 26 (3)
"	Minced *3	0.1/ site	SC+IP	"	3/3	100	35, 37 (2)
Total				1~58	28/33	84.8	20~37

*1 For minced and trypsinized see Results in the text.

*2 20 (4) means 4 hamsters developed tumor at day 20.

*3 Minced and trypsinized tumor materials were kept at 4°C for 16 hr before inoculation.

TABLE 3 *Serial passage of ICH virus induced tumor in hamsters*

EXP. NO.	NO. OF TRANS-PLANT PASSAGE	HAMSTER NO. WITH TUMOR USED FOR INOCULUM	AGE OF HAMSTER RECIPIENTS	ROUTE OF INOCULATION	NO. WITH TUMOR/NO. INOCULATED	DAY OF TUMOR APPEARANCE
			days			
31	2nd	HT21-3	11	IP	3/3	15 (3)
32	"	HT23-1	4	SC	4/4	15 (3), 21
36	"	HT25-1	7	SC	4/4	10 (2) 13 (2)
38	3rd	HT36-1	20	SC	4/4	12 (3), 17
40	4th	HT38-1	24	SC	5/5	10 (2), 13 15 (2)
41	"	"	75	SC	4/4	14 (3), 16
45	5th	HT41-1	4	SC	3/3	10 (3)
Total			4~75		27/27	10~21

Note: Abbreviations are same with those of tables 1 and 2.

After the 2nd transplant passage, positive takes were found in all recipients within 21 days (tab. 3).

There was an apparent difference in the times of appearance of the primary and transplant tumors in hamsters following inoculation with virus or transplant tumor tissues.

3 Description of the tumors

(a) Macroscopical findings

ICH virus induced tumor A tumor mass, the size of a walnut was located in the abdominal cavity on the right side of the abdominal wall. The tumor was slightly adhered to the muscular tissue of the peritoneum (fig. 3). The removed solitary tumor mass was smooth on the surface and encapsulated with thin capsule. The tumor mass was nodular, lobulated and rubbery in consistency. The tumor mass was heart shaped. The size of the tumor mass was 6×6×4.5 cm and the weight was 77 g (total body weight of the hamster was 187 g). The cut surface of the tumor was flat, smooth, rubbery and grayish white in color. The tumor was divided into three parts with connective tissue septa connecting to the capsule. The central parts of the tumor parenchyma consisted of irregular shaped yellowish necrotic areas and the blood vessels in the connective tissue septa showed congestion (fig. 4). There were no metastasis.

Transplanted tumor The tumor mass produced by transplantation of the HT-7 tumor developed at the site of inoculation in the subcutaneous tissues and was sharply demarcated from the surrounding tissues. Occasionally several small tumor nodules were found around a large tumor mass (figs. 5 & 6).

The intraperitoneal tumor produced by transplantation of the primary tumor developed at various portions of the peritoneum of the abdominal wall, diaphragm, and the visceral organs (fig. 7).

The gross character of the both transplanted tumors, subcutaneous and peritoneal, was quite similar to those of the original virus induced tumor, but it seemed to increase somewhat in hardness.

Metastasis occurred in the lungs of some animals (fig. 8).

(b) Microscopical findings

ICH virus induced tumor The tumor developed an expansive tendency and some parts of the tumor showed infiltrative proliferation into the muscular tissue. There were widely distributed edematous necrotic areas and hemorrhages in the tumor parenchyma. A fibrin thrombus was found in the blood vessel of the necrotic area. The tumor cells and stromal net work showed tendency to arrange around the vascular lumina. The arrangement of the tumor tissue was similar to those of hemangiopericytoma (perithelioma) in most parts (figs. 9 & 10). Mitosis were frequently seen. There were scattered pycnotic and degenerated cells and many small necrotic foci. In some parts of the tumor tissue there were well developed irregular vascular channels, but in the other parts the vascular channels were poorly developed. The latter part of the tumor tissue was closely occupied with the tumor cells. The tumor cells in some areas were markedly pleomorphic. The tumor cells were large and polygonal. Large round irregular nuclei had a vesicular appearance and were frequently with clumped dark chromatin. Pinkish nuclear bodies resembling inclusions were frequently scattered in these areas. Nucleoli were enlarged. Basophilic, bizarre and syncytial giant cells were occasionally seen. Some of the giant cells had more than ten nucleoli. Mitosis were frequent. Cell arrangement was irregular in these areas. Their structure resembled that of the pleomorphic cell tumor (fig. 11). In the other parts of the tumor tissue, the tumor cells were spindle-shaped and the nuclei were ovoid or elongated containing one or more nucleoli. The tumor showed a fibrosarcoma structure (fig. 10).

Transplanted tumor The character of the initial transplanted tumor (HT-27-2) was quite similar to those of the original virus induced tumor, except for the pleomorphic cell tumor structure. The tumor cells were large and polygonal in outline and proliferated around the vascular lumina (peritheliomatous structure) (fig. 12). Mitosis were frequent. Occasionally macrophages were scattered in the tumor parenchyma with a starry sky appearance as in a malignant lymphoma. The tumor showed metastasis in the lungs and meningeal tissues.

From the above findings, we considered these tumors to be an undifferentiated mesenchymal tumor.

4 Serological studies of ICH virus induced hamster tumors

Box CF titration was carried out using individual serum samples from tumor-bearing hamsters against the corresponding tumor antigens. The purpose of this preliminary experiment was to obtain high titered serum and antigen. Sera from hamsters No. HT-25-1 and No. HT-35-1, the latter was received tissue cultured cells derived from the HT-7 tumor, were selected as the standard sera. Antigens from tumors of hamsters Nos. HT-35-1 and HT-38-1 were used as the standard antigens.

Using 4 units of the standard sera and antigens, the CF tests were conducted against individual tumor antigen and tumor-bearing hamster serum. The results were shown in table 4.

TABLE 4 *Level of complement-fixing tumor antibody in sera from hamsters with primary or transplanted tumors and level of tumor antigen in those tumor cells*

HAMSTER NO.	VIRUS OR TUMOR MATERIAL INOC.	ROUTE	DAY OBSERVED	TUMOR WEIGHT	TITER OF CF-	
					ANTIBODY	ANTIGEN
HT-7	ICH virus	IP	214	77 ^g	1 : 4	1 : 16
HT-21-3	HT-7 primary tumor, Minced	"	27	9	4	16
HT-21-4	"	"	"	6	4	16
HT-21-5	"	"	35	7	8	32
HT-22*	"	"	67	(2×2 cm)	32	—
HT-23-1	"	SC	27	13	4	16
HT-23-2	"	"	"	3	8	8
HT-23-3	"	"	50	26	—	32
HT-25-1*	HT-7 primary tumor Trypsinized	"	"	13	128	32
HT-25-2	"	"	"	10	16	16
HT-25-3	"	"	"	23	32	16
HT-27-1	"	"	39	17	32	64
HT-27-4	"	"	50	11	16	16
HT-27-5	"	"	"	16	16	32
HT-36-1*	HT-25-1 1st transplant tumor, Minced	"	21	3	< 4	32
HT-36-2	"	"	"	4	< 4	32
HT-38-1	HT-36-1 2nd transplant tumor, Minced	"	28	14	16	128

* Metastasis was observed by naked eye.

— Not examined

As can be seen in the table, complement fixing tumor antigens were readily demonstrated in suspensions of both the primary and transplanted ICH virus induced tumors. Sera from the tumor-bearing hamsters also reacted with the tumor antigens.

Despite the fact that the primary tumor was large, the tumor antigen titer and antibody titer of the tumor-bearing hamster was low. However, in the hamsters with transplanted tumors, generally speaking more tumor antigen and greater antibody titers were detected in the hamsters with large transplanted tumors than in those with small transplanted tumors.

No reactions occurred between tumor antigens and normal hamster sera, or between antigens prepared from normal hamster tissues and sera from tumor-bearing hamsters.

Box CF tests were also conducted between serum from primary and transplant tumored

TABLE 5 *Box complement-fixation tests of sera from hamsters with primary and transplanted tumors versus corresponding hamster tumor antigens and tissue culture T antigen (neoantigen) of ICH virus*

ANTIGENS	ANTIGEN DILUTION	HT-7 HAMSTER SERUM DILUTION					ANTIGENS	HT-25-1 HAMSTER SERUM DILUTION					
		4	8	16	32	AC*2		4	8	16	32	64	AC
HT-7 primary tumor antigen	4	2*1	1	0	0	0	HT-25-1 transplanted tumor antigen	4	4	4	4	4	0
	8	2	0	0	0	0		4	4	4	4	4	0
	16	0	0	0	0	0		4	4	4	4	3	0
	32	0	0	0	0	0		4	4	3	1	1	0
	SC*3	0	0	0	0	0		±	0	0	0	0	0
Tissue culuture T antigen	4	4	3	0	0	0	Tissue culture T antigen	4	4	4	±	0	0
	8	4	4	1	0	0		4	4	3	0	0	0
	16	4	3	1	0	0		3	1	0	0	0	0
	32	3	1	±	0	0		1	±	0	0	0	0

*1 Figures indicate the degree of hemolysis. 0: 100%, ±: intermediate between 0 and 1, 1: 75%, 2: 50%, 3: 25% and 4: no hemolysis

*2 AC: Antigen control *3 SC: Serum control

hamster and corresponding tumor antigen or ICH virus tissue culture T antigen (neoantigen).

As shown in table 5, only a slight reaction was observed between the HT-7 antigen and the homologous hamster serum, but the latter reacted moderately with the tissue culture T antigen.

The HT-25-1 hamster serum reacted with both HT-25-1 tumor antigen and tissue culture T antigen (neoantigen).

5 Attempts to recover virus from ICH virus induced tumors

Attempts were made to recover ICH virus from the ICH virus induced primary tumor and from some of the 1st and 2nd transplanted tumors. The following methods were applied for this purpose.

a) A 20% extracts of tumors were frozen and thawed 5 to 6 times, and then centrifuged at 9,000 rpm for 30 min. The supernates were then inoculated onto cell cultures susceptible to ICH virus, such as DKC, established cell line of DKC (MDCK), and Vero cells. CPE and the propagation of the virus were examined.

b) Ten days later, the inoculated cultures described above, which did not show any sign of virus propagation, were frozen and thawed twice. Then following centrifugation they were again inoculated onto DKC.

c) Tumors were trypsinized and the dispersed tumor cells were seeded onto cell cultures susceptible to the ICH virus. The cell cultures were served when the cell propagation was about 50%, so as to make mixed cultures.

d) Two to three weeks later aliquots of the mixed cultures were frozen and thawed twice, and inoculated onto DKC.

e) Other aliquots of mixed cultures were passaged, and inoculated with ICH virus to observe whether or not any interaction will occur to the challenged virus.

Despite our intensive search to detect the virus, we failed to find infectious ICH virus in the primary and transplanted hamster tumors. No effect of the superinfection was observed.

DISCUSSION

It has been well a known fact that a number of adenoviruses, which infect human beings and other animal species, can produce tumors in newborn hamsters. However, before the present experiments were started, several trials to show oncogenicity of ICH virus (canine adenovirus) have failed (HUEBNER et al., 1962; McLEOD & HAM, 1963).

If the ICH virus has oncogenic activity for newborn hamsters, the virus will be used for an analysis of whether the virus can be oncogenic in its natural host. The data from these experiments would contribute to the question of the oncogenicity of human adenoviruses to human beings. The present experiments were started from these viewpoints.

It has been proposed that at least 2 properties of human adenoviruses are closely associated with their oncogenic property. One is the base composition of the DNAs of the adenoviruses and the other is the property of the adenovirus hemagglutinin (HA).

The guanine-cytosin (G-C) contents of adenovirus DNAs described by PINA & GREEN (1965) contributed to the grouping of adenovirus and its relation to oncogenic activity. The adenovirus group of the lowest G-C content (47~49%), for example, corresponded to the highly oncogenic group.

With regard to the adenovirus hemagglutinins, the human adenovirus HA were classified into 4 groups by ROSEN (1960). The highly oncogenic group is entirely classified in group 4.

These findings suggest that it is necessary to clarify such properties prior to starting oncogenic studies of the ICH virus.

Taking the above results into consideration, we attempted to serologically classify 14 strains of ICH virus. However, as described in the preceding paper (KINJO & YANAGAWA, 1968), there were no significant strain differences of the serological characteristics examined by hemagglutination, complement-fixation and serum neutralization tests. The results thus agreed with the general concept that only one serological type is recognized for the ICH virus (PEREIRA et al., 1963).

In respect to the G-C content of the ICH virus, it seems difficult to obtain an exact value because of possible contamination of the virus stock with small

virus-like particles as has been suggested in this laboratory (KINJO & YANAGAWA, 1967; SUGIMURA & YANAGAWA, 1968). Therefore, this problem still remains to be clarified.

Since no serological differences were found among the strains of ICH virus, we have to turn our attention to other biological properties, for selecting ICH virus strains. Multiplication patterns of ICH virus, in HeLa cells (KINJO & YANAGAWA, 1967) was another suggestion of strain differences.

Thus, we selected 2 strains FD and Woc-4 from one group which could replicate in HeLa cells at about $10^{2.5}$ TCID₅₀ per ml accompanied with CPE, and 2 strains, N-III and Winthrop, from the other group which could not replicate in HeLa cells.

These 4 strains were standardized to 10^7 TCID₅₀ per ml and then inoculated into newborn hamsters.

The results to date, as described in the text, show that only 2 strains which could propagate in HeLa cells, induced tumors in hamsters, while other 2 strains which could not propagate in HeLa cells did not produce tumors, during a year observation period.

Because of the limitations in our studies—in the number of animals inoculated, number of strains used and periods of observation—oncogenicity of the latter 2 strains could not be excluded. However, some relationships seemed to exist between the behavior of multiplication in HeLa cells and oncogenic property of ICH virus strains. It will be an interesting future problem to clarify this relationship.

SARMA et al. (1967) also successfully induced tumors in newborn hamsters with the ICH virus. They used the Lederle strain 255 of ICH virus and produced tumors at the site of inoculation in 2 out of 14 hamsters. One was a subcutaneous tumor produced in 360 days and the other was an intraperitoneal tumor produced in 403 days. These latent periods were longer than those that we found. Thus the latent period may be depended upon the strains used.

However, in both experiments the percentage of tumor development was low and the latent period was long. This suggests that oncogenic potency of the ICH virus may be similar to the weakly oncogenic human adenovirus group, such as adenovirus types 3 and 7, rather than to the highly oncogenic types 12, 18 and 31.

Complete regression of the tumors was observed in all the 3 subcutaneous tumors, within 4 weeks after the first appearance of tumor development. Although the datum was not presented here, 2 of these 3 hamsters were challenged with tumor cells, and one took the tumor but another did not. Experiments relating to these problem are in progress.

On the other hand, the intraperitoneal tumor developed rapidly and at autopsy on day 214, it had reached 77 g ($6 \times 6 \times 4.5$ cm) in weight, which corresponded to about 2/5 of the total hamster weight of 187 g.

The histopathological figures of the primary ICH virus induced tumor were pleomorphic. The tumor cells were basically spindle-shaped cells and large polygonal anaplastic cells, and occasionally giant cells were seen. There seemed to be varying degrees of differentiation. We believe that these tumors are undifferentiated mesenchymal tumors with some characteristics of a low grade fibrosarcoma.

There were several reports with respect to the histopathology of adenovirus induced tumors. SARMA et al. (1967) described similar findings for the ICH virus induced primary tumors in hamster. BERMAN in the paper reported by HUEBNER et al. (1962) regarded the hamster tumors induced by adenovirus types 12 and 18 to be primitive undifferentiated mesenchymal neoplasms with some definite epitheloid characteristics. KAYANO & TSURUHARA (1965) regarded the hamster tumors induced by adenovirus type 12 as an undifferentiated mesenchymal tumor. TRENTIN et al. (1962) described the tumors as undifferentiated sarcomas. On the contrary, OGAWA et al. (1966) described that the hamster tumors induced by adenovirus type 12 would likely have originated from neuroectodermal supporting cells.

With respect to the origin of the tumor cells, there is a need for further study.

When transplant experiments were carried out using minced or trypsinized primary tumors, during the first transplantation, takes were observed, in 84.8%, within 20 to 37 days after inoculation. While 100% takes occurred after the 2nd transplantation, and their latent periods were shortened to 10~21 days.

The transplanted tumors grew rapidly and killed the tumored hamsters within about 1 month after palpable tumors were first detected. This occurred primarily with the intraperitoneal tumors which were more rapid growing and in some cases these tumors became so large that they equaled the size and weight of the hamster itself.

The transplanted subcutaneous tumors generally appeared only the site of inoculation, but in some cases metastasis were observed in other parts, primarily in the thoracic cavity. In one case which was submitted for histological examination, metastasis were observed in the lungs and meningeal tissues, although no metastasis were apparent upon examination with the naked eye. In the transplanted intraperitoneal tumors many small tumor masses were observed at the various parts of the peritoneum of the abdominal cavity. Both the subcutaneous and intraperitoneal tumors seemed to be highly malignant.

Attempts to demonstrate infective virus in the primary or transplanted tumors

by the various methods described in the text have been unsuccessful to date. Attempts to recover the infectious virus from human adenovirus-induced tumors have also failed. We are planning to recover the infectious virus from tumor cells using the technique of cell fusion or heterokaryon formation (GERBER, 1966; KOPROWSKI et al., 1967).

However, these virus free tumors usually carried viral information which codes for the production of a virus specific antigen, namely, tumor antigen (HUEBNER et al., 1963).

In our experiments we demonstrated the tumor antigen, showing common antigenicity with ICH virus-specific tissue culture T antigen (neoantigen), in the primary and transplanted tumors. In addition, we demonstrated a CF antibody which reacts with both of the tumor antigens in the sera of tumor-bearing hamsters.

Both the tumor antigen and antibody were continuously produced in the tumor-bearing hamsters regardless of the number of transplant passages. Therefore we concluded that the ICH viral genome which codes for the production of tumor antigen maybe incorporated somehow in the chromosome network of the tumor cells.

Since we have no available tumor antigens or antibodies induced by other adenoviruses, SV₄₀, or polyoma virus, we could not carry out cross-CF reactions with these tumor systems to confirm specificity of the ICH virus tumor. However, it was proved by cross-neutralization and other tests described previously (KINJO & YANAGAWA, 1967) that the virus used in the present experiments was not an oncogenic human adenoviruses. In addition, the specific reactivity of the tumor-bearing hamster sera to the T antigen (neoantigen) prepared from DKC infected with ICH virus is strong evidence that the hamster tumor was caused by the ICH virus.

It is obvious from the data of SARMA et al. (1967) and of the present work that the ICH virus has oncogenic activity for newborn hamsters similar to the oncogenic human adenoviruses.

We intend to do future research on the immunological relations between tumors of the ICH virus and of other adenoviruses primarily of the human adenoviruses and we also intend to demonstrate whether or not the ICH virus is oncogenic in dogs. The results of such experiments will also serve to enlighten the oncogenic studies of human adenoviruses in man.

SUMMARY

Two out of the four strains of infectious canine hepatitis (ICH) virus were proved to be oncogenic for newborn hamsters.

When newborn hamsters were inoculated subcutaneously, with strain FD of ICH virus, tumors developed at the site of inoculation in 3 of 21 hamsters, within 153 to 174 days of inoculation. But the subcutaneous tumors soon regressed and disappeared.

Strain Woc-4 produced an intraperitoneal tumor in 1 out of 13 hamsters 198 days following an intraperitoneal inoculation. This tumor developed rapidly and became very large in size ($6 \times 6 \times 4.5$ cm) and weight (77 g).

The intraperitoneal tumor was easily transplantable to hamsters. After the 2nd passage we got 100% positive takes and the latent period was shortened to less than a month. Both the primary and transplanted tumors were histologically diagnosed as an undifferentiated mesenchymal tumor.

Attempts to recover the ICH virus from both the primary and transplanted tumors failed, but a complement fixing antibody to the tumor antigen and to the tissue culture T antigen of the ICH virus could be demonstrated in the sera of all tumor-bearing hamsters, tested.

REFERENCES

- 1) DARBYSHIRE, J. H. (1966): *Nature, Lond.*, **211**, 102
- 2) GERBER, P. (1966): *Virology*, **28**, 501
- 3) GIRARDI, A. J., HILLEMANN, M. R. & ZWICKEY, R. E. (1964): *Proc. Soc. exp. Biol. & Med., N. Y.*, **115**, 1141
- 4) HUEBNER, R. J., CASEY, M. J., CHANOCK, R. M. & SCHELL, K. (1965): *Proc. natn. Acad. Sci., U. S.*, **54**, 381
- 5) HUEBNER, R. J., PEREIRA, H. G., ALLISON, A. C., HOLLINSHEAD, A. C. & TURNER, H. C. (1964): *Ibid.*, **51**, 432
- 6) HUEBNER, R. J., ROWE, W. P. & LANE, W. T. (1962): *Ibid.*, **48**, 2051
- 7) HUEBNER, R. J., ROWE, W. P., TURNER, H. C. & LANE, W. T. (1963): *Ibid.*, **50**, 379
- 8) HULL, R. W., JOHNSON, I. S., CULBERTSON, C. G., PEIMER, C. B. & WRIGHT, H. F. (1965): *Science*, **150**, 1044
- 9) KAYANO, F. & TSURUHARA, T. (1965): *Trans. Soc. path. jap.*, **54**, 216 (in Japanese)
- 10) KINJO, T. & YANAGAWA, R. (1967): *Jap. J. vet. Res.*, **15**, 141
- 11) KINJO, T. & YANAGAWA, R. (1968): *Ibid.*, **16**, 128
- 12) KINJO, T., YANAGAWA, R. & NISHI, T. (1968): *Ibid.*, **16**, 183
- 13) KOPROWSKI, H., JENSEN, F. C. & STEPLEWSKI, Z. (1967): *Proc. natn. Acad. Sci., U. S.*, **58**, 127
- 14) MCLEOD, D. L. & HAM, A. W. (1963): *Canad. med. Ass. J.*, **89**, 799
- 15) OGAWA, K., TSUTSUMI, K., IWATA, Y., FUJII, M., OHMORI, M., TAGUCHI, K. & YABE, Y. (1966): *Gann*, **57**, 43
- 16) PEREIRA, H. G., HUEBNER, R. J., GINSBERG, H. S. & VAN DER VEEN, J. (1963): *Virology*, **20**, 613
- 17) PEREIRA, M. S., PEREIRA, H. G. & CLERKE, S. K. R. (1965): *Lancet*, **I**, 21
- 18) PINA, M. & GREEN, M. (1965): *Proc. natn. Acad. Sci., U. S.*, **54**, 547

- 19) ROSEN, L. (1960): *Amer. J. Hyg.*, **71**, 120
 20) SARMA, P. S., HUEBNER, R. J. & LANE, W. T. (1965): *Science*, **149**, 1108
 21) SARMA, P. S., VASS, W., HUEBNER, R. J., IGEL, H., LANE, W. T. & TURNER, H. C. (1967): *Nature, Lond.*, **215**, 293
 22) SUGIMURA, T. & YANAGAWA, R. (1968): *Jap. J. vet. Res.*, **16**, 1
 23) TRENTIN, J. J., YABE, Y. & TAYLOR, G. (1962): *Science*, **137**, 835

EXPLANATION OF PLATES

PLATE I

- Fig. 1 Tumor-bearing hamster (HT-2) at 186 days after subcutaneous inoculation of ICH virus, strain FD
 The tumor developed at the site of inoculation (arrow).
 The photograph was taken at 12 days after the first appearance of the tumor which subsequently regressed and disappeared within 2 weeks.
- Fig. 2 Hamster (HT-7) with an intraperitoneal tumor which appeared at 198 days after intraperitoneal inoculation with strain Woc-4
 The photograph was taken just prior to sacrifice at 214 days.
- Fig. 3 Tumor development in the abdominal cavity of the HT-7 hamster
 A part of the tumor mass adhered to the muscular tissue of the peritoneum (arrow) but the main mass was located in the abdominal cavity separate from the abdominal organs.
- Fig. 4 Cut surface of the HT-7 hamster tumor
 The tumor mass was divided into 3 parts with connective tissue septa.
- Fig. 5 Hamster (HT-27-4) with subcutaneous tumor 40 days after subcutaneous transplantation of a trypsinized HT-7 tumor
- Fig. 6 The same hamster as fig. 5
 Several tumor nodules were found around a large nodular tumor mass.
- Fig. 7 Tumor (HT-21-4) in the abdominal cavity 27 days after intraperitoneal transplantation of minced HT-7 tumor
 Tumors were found on various portions of the peritoneum of the abdominal wall and the visceral organs.
- Fig. 8 Hamster with subcutaneous tumor (HT-25-1) 50 days after subcutaneous transplantation of trypsinized HT-7 tumor
 The photograph was taken following the removal of the subcutaneous tumor.
 Tumor metastasis in the thoracic cavity, especially in the lungs

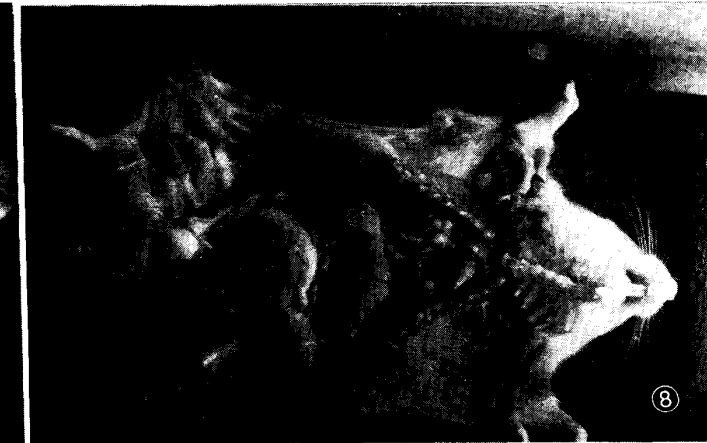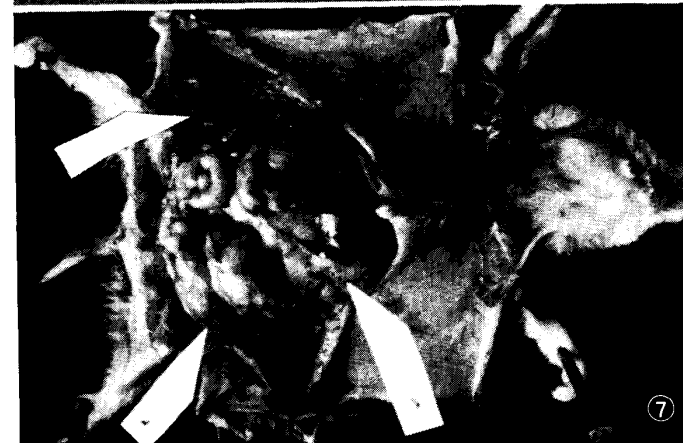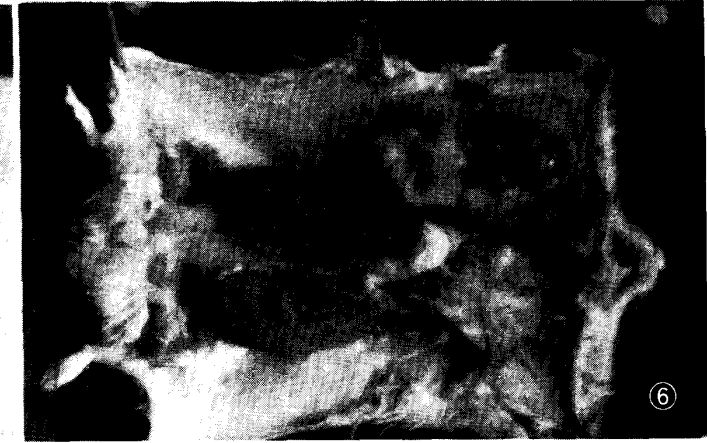
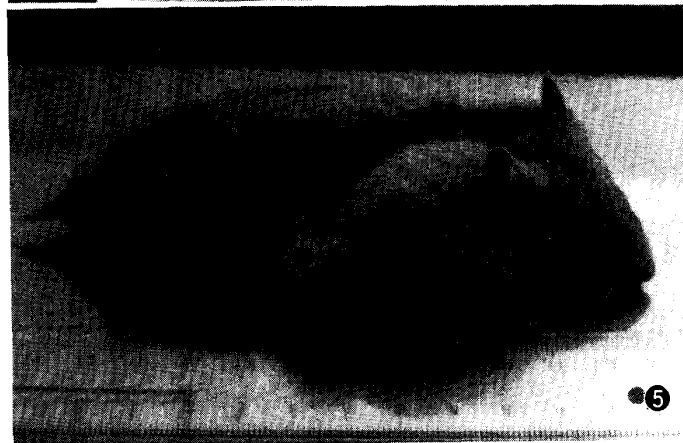


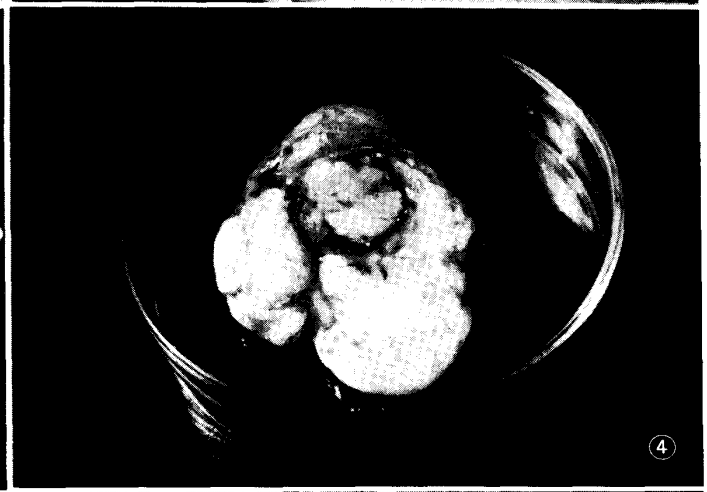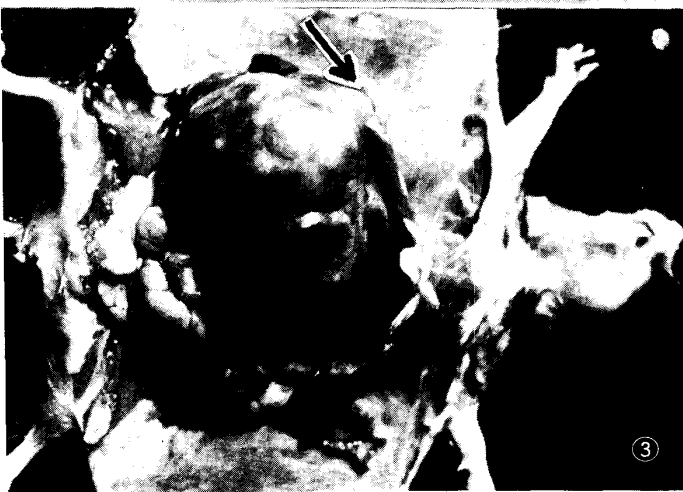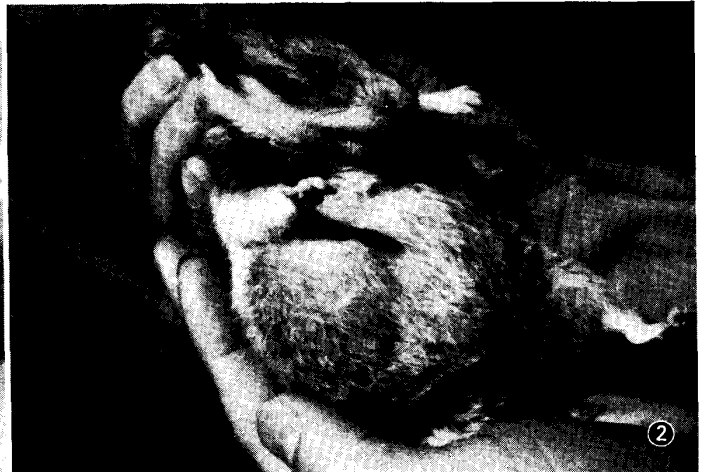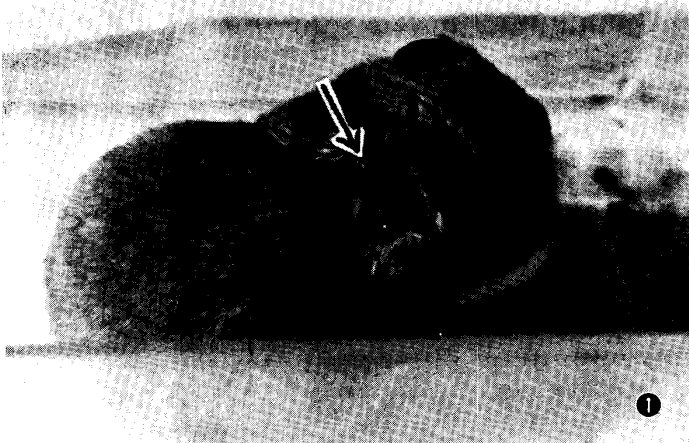PLATE II

- Fig. 9 Original virus induced tumor 214 days after inoculation
Undifferentiated large polygonal tumor cells were arranged around the vascular lumina. There were many scattered, pycnotic and degenerated cells, and a loose edematous area around the tumor cell foci.
Hematoxylin-eosin stain × 114
- Fig. 10 Same case as fig. 9
The small capillaries were open and lined by endothelium but they were closely encircled by spindle-shaped cells. There were necrotic and loose areas around the tumor cell foci.
H.-E. × 114
- Fig. 11 Same case as fig. 9
The tumor cells proliferated around the vascular channels. The tumor cells in the right lower part of the figure have a pleomorphic appearance. The tumor cells in the left upper part of the figure are spindle-shaped.
H.-E. × 180
- Fig. 12 Initial transplanted tumor 25 days after inoculation
Large polygonal anaplastic tumor cells were arranged around the vascular lumina. A macrophage (arrow) was found in the left upper corner of the figure.
H.-E. × 425

