



Title	HISTOPATHOLOGICAL STUDIES ON BOVINE MAMMARY GLAND III ON THE "ACTINOMYCOTIC" UDDER
Author(s)	YAMAGIWA, Saburo; ONO, Takeshi; NAKAMATSU, Masao; UEMURA, Tamio; IDA, Taiji
Citation	Japanese Journal of Veterinary Research, 11(1), 12-25
Issue Date	1963-03
DOI	10.14943/jjvr.11.1.12
Doc URL	http://hdl.handle.net/2115/1773
Type	bulletin (article)
File Information	KJ00002373369.pdf



[Instructions for use](#)

HISTOPATHOLOGICAL STUDIES ON BOVINE MAMMARY GLAND III ON THE "ACTINOMYCOTIC" UDDER

Saburo YAMAGIWA*, Takeshi ONO**, Masao NAKAMATSU*,
Tamio UEMURA*** and Taiji IDA***

(Received for publication, November 12, 1962)

INTRODUCTION

In regard to the characteristic actinomycotic lesion in the bovine mammary gland, it seems that from a good many years ago this lesion already has been watched with interest. For instance, KENDALL (1914)⁷⁾ reported on 636 cases which were slaughtered under supervision with "actinomycotic" udder as the result of mass inspections of dairy herds during a period of 5.5 years in Australia. Later, in literature, the authors encountered only with 2 cases reported by SMITH (1934)¹⁰⁾, 1 case by DAVIES (1935)⁵⁾ and 3 cases by MAGNUSSON (1928)⁸⁾, but according to DAVIES (1935)⁵⁾ 170 cases of record had been detected. Possibly the 170 cases may include PEHRRSON's cases (1886), HULPHERS' 8 cases (1920), GUNST's 20 cases (1927) and SCHLEGEL's 2 cases, together with the 26 cases (ALBISTON, 1930)¹⁾ and 115 cases (ALBISTON and PULLAR, 1934)²⁾ in Victoria (regrettably the authors were not available originals of the reports).

While the contents of the above mentioned reports will be considered later, first an attempt will be made to feel out the such recent basic thinkings on "actinomycotic" udder as seen in some text books. In this connection, these books are from England and America alone. According to GAIGER and DAVIES (1955): *Staphylococcus aureus* is also the cause of a chronic mammary gland infection which clinically resembles actinomycosis. Apparently all cases of so-called "actinomycosis" in the mammary gland of cows and about 15% of cases in sows are caused by this organism. Colonies develop in the form of granules as in equine botryomycosis, but they also develop clubs as in true actinomycotic granules. SMITH and JONES (1957) mentioned in their heading of granulomatous staphylococcal mastitis: This bovine disease occurs with moderate rarity, and is reported from Europe, America

This work was communicated at the 51st Meeting of the Japanese Society of Veterinary Science on April 10, 1961 in Tokyo.

* Department of Comparative Pathology, Faculty of Veterinary Medicine, Hokkaido University, Sapporo, Japan

** Laboratory of Veterinary Pathology, Obihiro Zootechnical College, Obihiro, Japan

*** Health Department of Hokkaido Prefectural Government, Sapporo, Japan

and Australia; hitherto, it has gone under the etiologically incorrect name of "actinomycotic mastitis." From its pathological and etiological characteristics it is a granulomatous disease known as "botryomycosis." Since earlier workers reported that botryomycosis may be seen in the mammary gland of mares, it may safely be said that mares are also subject to granulomatous staphylococcal mastitis [MAGROU's experimental work (1919)⁹ is available]. However, in actuality no recent reports are available. Furthermore, the causative cocci have been identified as *Staphylococcus aureus*. In addition, according to the discussion at a Joint Meeting of the Sections of Comparative Medicine and Surgery, the Royal Society of Medicine (*Vet. Rec.*, 1930, 10, 589—abstract by J. G. W.) BOSWORTH³) and COLEBROOK⁴) mentioned staphylococcal mastitis.

As may be clearly seen in the above, insofar as the bovine mammary gland is concerned, it appears that etiologically genuine actinomycosis caused by *Actinomyces bovis* is hardly ever seen. Moreover, it is known that there exist lesions of the mammary gland of which the character especially the histological figures closely resemble that of genuine actinomycotic lesions and in which staphylococci play an important etiological role. In these circumstances, the frequency which the authors encounter with such lesions in the bovine mammary gland and the pathogenetic view in having relation to it give rise to discussion. In regard to the frequency, with the exception of cases of KENDALL⁷) and ALBISTON¹), it attracts notice that number of cases which have been reported up to the present are a few. Naturally, in Japan there are no reports to be found on this problem. Next, as regards the pathogenetic view, considering the facts that staphylococci are constantly detected in the bovine mammary gland as a usual matter and moreover that it has been clearly demonstrated that they are the causal organism in acute mastitis, it is a matter of no small interest to the present workers. According to SMITH and JONES: While various theories have been proposed as to why this staphylococcus should produce a chronic granulomatous reaction so different from the acute sero-fibrinous-purulent form which is the rule, it is believed that a delicately close balance between the pathogenicity of the invader and the resistance of the host may well be the reason. Also according to RUNNELLS, R. A., W. S. MONLUX and A. W. MONLUX (1960) in their description on chronic mastitis in their text book: Microorganisms which caused chronic mastitis were mostly hemolytic staphylococci. As regards the reason why it should take the form of chronic mastitis, if the damage in severe acute mastitis is not as great as that just described, a state of equilibrium may develop between the etiological agent and tissue defenses with neither able to overcome the other.

Since the beginning of the present studies, the authors have investigated the mammary glands of 114 cases from Hokkaido and detected "actinomycotic" lesions

in 7 cases (6.14%) out of the 114 cases. In the present paper discussion will be offered on the "actinomycotic" udder with reference to the 7 cases. As regards the investigated materials and methods, since circumstances accord with those mentioned in report I, in the present paper particulars will be abridged. All the 114 cases are of meat packing plant cases indiscriminately collected, and out of them 17 were apparently diagnosed as mastitis clinically.

FINDINGS OF THE INVESTIGATED CASES

In the histological findings of the mammary gland, section preparation numbers such as Anterior 1, Posterior 2, etc. indicate the sites which were sampled from the ventral parts to dorsal parts of the udder.

Case 1. TM 91 Cross-bred Holstein-Friesian cow 4 years of age Slaughtered on 18/VI '56 at the Kimobetsu meat packing plant.

Clinical findings: Traumatic pericarditis was indicated with no noteworthy findings in the udder. Highest milking volume: ca 18 liters, last milking ca 10.8 liters.

Macroscopical findings of the mammary gland: No noteworthy findings were seen.

Histological findings of the mammary gland: Anterior 1: Inactive parenchyma was seen sporadically in the active parenchyma. Anterior 2: Inactive parenchyma was seen sporadically in the active parenchyma. Two groups of acini showed inflammatory changes. Also within the area of a single lobule a well defined focus formation was seen. In the focus ten odd granulomata were seen side by side; the center of each consisted of a faintly eosinophilic stained homogeneous substances, and one of the granulomata has club shaped structures in the periphery. Proliferation of epithelioid cells in the foci was slight and a small number of giant cells were present; Proliferation of fibrous tissue was not active. Anterior 3: The same as in Anterior 1. Posterior teat: Showed no noteworthy findings. Posterior 1: Inactive parenchyma was seen sporadically in the active parenchyma. In seven groups of acini inflammatory changes were seen. Posterior 2: The same as in Anterior 1. Posterior 3: Nine acinar groups showed inflammatory changes, the others same as just above. Supramammary lymph nodes: Showed no noteworthy changes.

Summary of findings: No abnormalities were seen in either clinical or macroscopical findings. In 3 section preparations of the mammary gland features of mastitis alveolaris were seen. In a single section preparation, granulomatous chronic lobular mastitis was seen.

Case 2. M 8 Cross-bred Holstein-Friesian cow 17 years of age Slaughtered on 9/IV '56 at the Kutchan meat packing plant.

Clinical findings: Left anterior quarter atrophied. Highest milking volume: ca 2.5 liters. Last milking ca 5.4 liters.

Histological findings of the mammary glands: Left anterior teat: In the region of mucous membrane near the teat canal opening, the submucosa was edematous and showed marked proliferation of fibrous tissue. In the lumen of the teat canal, there were granule-like small agglomerations faintly stained with eosin which were entrenched in cellular and

fibrinous exudates. By Gram-Weigert stain, it was developed that the agglomerations had in the center an accumulation of small spherical substances in various shades, and that the accumulation was surrounded by a slightly reddish massive structures. Anterior 2: The lactiferous sinus was filled with granulation tissue. Anterior 3: Granulation tissue showing embolus-like appearance was seen in the large milk collecting duct. Anterior 4: The wall of the lactiferous sinus showed thickening due to proliferation of granulation tissue. The parenchyma showed inactive features. Three granulomatous lesions as large as a lobule or groups of lobules were seen; in the central part of each granuloma there existed accumulations of spherical substances which were faintly stained with hematoxylin; in the circumference of the accumulations features of fringe club formation were seen; the granulation tissue was loosely fibrous. Anterior 5: In addition to 11 granulomatous lesions as large as a lobule or groups of lobules, one large focus of 1.3 cm in diameter was seen. An embolus-like formation of granulation tissue was seen in the large milk collecting duct and some granule-like lesions were embedded in the tissue. Individual granulomata to in the latter (one large focus) possessed numerous giant cells (Fig. 2). Anterior 6: The parenchyma showed inactive features. An embolus-like granulation tissue was seen in the lactiferous sinus. Anterior 7: Seven granulomatous tissue foci as large in extent as groups of lobules were seen and they had granule-like agglomerations. In the central part of the individual granule-like agglomerations there was an accumulation of small spherical substances which were faintly stained with hematoxylin (Figs. 3 and 4). The surrounding tissue of the accumulation was loose and no giant cells were seen. An embolus-like granulation tissue was present in the lactiferous duct. Anterior 8: The interstitial tissue showed subacute inflammatory changes. Independently of these changes, 7 groups of acini showed inflammatory changes. Anterior 9: Subacute inflammatory changes were seen in the various sized lactiferous ducts. Anterior 10: The parenchyma showed inactive features. Eight granulomatous lesions as large as a lobule were seen. All the milk ducts were inflammatory. Lymph nodes: No noteworthy changes were seen.

Summary of findings: During milking. One quarter was atrophied and in this quarter the presence of a granulomatous chronic lobular mastitis extending over area of a lobule or groups of lobules was demonstrated. At the same time granulomatous proliferation in the lactiferous sinus and duct was seen. Also, embedded in the granulation tissue, some granule-like agglomerations were seen. In addition, in one another section preparation a feature of mastitis alveolaris was seen.

Case 3. TM 64 Cross-bred Holstein-Friesian cow 2 years of age Slaughtered on 16/VII '56 at the Asahigawa meat packing plant.

Clinical findings: Disseminated indurations were palpated in the right anterior and posterior quarters of the udder. Former milking volume ca 18 liters, at time of slaughter no secretion.

Macroscopical findings of the mammary glands: Focal indurations were seen in places in the right anterior and posterior quarters.

Histological findings of the mammary glands: Teats: No noteworthy findings were observed in the anterior and posterior. Anterior 1: Twelve foci as large as a lobule or groups of lobules were seen. These were all aggregation of granulomata and each of the granuloma had an accumulation of spherical substances which were faintly stained with

hematoxylin in the central part. Marked proliferation of fibrous tissue containing a large number of lymphocytes and scanty epithelioid cells was seen in the surrounding tissue. Posterior 1: Sixteen foci of the size of a lobule or groups of lobules were seen. Each granuloma which occupied the foci had spherical substances which was faintly stained with hematoxylin in the center (granule-like agglomerations), while the surrounding tissue abounded in fibrous tissue. The feature of clubs in the periphery of the granule-like agglomerations was beautiful. Posterior 2: Nine foci as large as a lobule or groups of lobules were seen. The nature of these was the same as the above described.

Summary of findings: In non-lactation, clinically dissemination of indurative foci were seen by palpation in one quarter. Histologically, numerous foci of granulomatous chronic mastitis of the size of a lobule or groups of lobules were shown.

Case 4. TM 20 Cross-bred Holstein-Friesian cow Age unknown Slaughtered on 7/VI '56 at Sapporo meat packing plant.

Clinical findings: Udder atrophied.

Macroscopical findings of the mammary gland: Intensive atrophy of the right anterior quarter existed and the right quarters were almost displaced by the posterior quarter. In the cut surface of the right posterior quarter numerous yellowish-white moist round projections of the approximate size of small red beans were seen here and there. When observed in detail, it felt that the center of the projections showed whitish opaque character and the periphery showed transparent. The left anterior quarter was atrophied.

Histological findings of the mammary gland: Left anterior 1, 2 and 3, together with Right anterior 1, 2 and 3 showed inactive features of the parenchyma. Right posterior 1: Showed inactive features of the parenchyma. Twenty-one foci were seen as large as a lobule or groups of lobules. In the foci, some of the granulomatous tissue contained a large number of leukocytes while the others did not; existence of epithelioid cells was generally a few. Right posterior 2: Inactive features were seen in the parenchyma. Twenty-seven foci such as just above-described were seen. Right posterior 3: The parenchyma showed inactive features. Twenty-two foci such as just above-described were seen. The foci had granule-like agglomerations. With Gram-Weigert staining, accumulations of purple stained granular substances became visible amassed in the center of the agglomerations. The surrounding club-like substances showed a beautiful appearance in purple. Right posterior 4: Eighteen foci were seen as described just above. Right posterior 5: Twenty foci were seen as described just above. In a section preparation with silver impregnation the periphery of granule-like agglomerations appeared in a tone of dark brown, being surrounded by a beautiful club-like structures (Fig. 5). Right posterior 6: Twenty-two foci were seen as described just above. In an Azan-stained preparation the periphery of granules-like agglomerations showed a bright reddish hue. Right posterior 7: Thirteen foci were seen as described just above.

Summary of findings: The parenchyma showed an inactive mammary gland. In one quarter, numerous granulomatous chronic mastitis lesions as large as a lobule or groups of lobules were seen. These were palpable during in the lifetime of the animal.

Case 5. TM 37 Cross-bred Holstein-Friesian cow 10 years of age Slaughtered on 31/VII '56 at the Sapporo meat packing plant.

Clinical findings: Unknown.

Macroscopical findings of the mammary gland: The right anterior quarter secreted a large quantity of milk. Two or three hen's egg sized indurations were palpated in the left posterior quarter. In the lactiferous sinus and dorso-posterior part of the left posterior quarter, there existed scattering or multiple rice-grain sized projections. The individual projected portions were yellowish in color and hard to the touch. The portions with multiple projections increased the hardness and could be palpated as coarse indurated one. At the vicinity of such a changed area some of the small lactiferous ducts contained creamy pus. Lymph nodes: No swelling was seen.

Histological findings of the mammary gland: Right anterior 1: In the parenchyma features of inactivation and enlargement of acini were intermingled. Inflammatory changes were seen in a single acinar group. Right anterior 2 and 3: Features of inactivation of acini existed among enlarged acini. Left posterior 1: Two lobules were occupied by granulomata. The granulomata were abundant in epithelioid cells. There were a few granulomata with spherical substances in the center. The fade circumference of the center was wide. Left posterior 2: Inactive acini and enlarged ones were seen mixed together. Fourteen foci of groups of acini showed inflammatory changes. Four lobules contained granulomata. The granulomata abounded with fibrocytes. Left posterior 3: Seventeen lobules contained granulomata including granule-like agglomerations (Fig. 1). In a Gram-Weigert stained section preparation staining of the agglomerations showed positive (purple) in only the central part and the club-like substances (Fig. 6). Lymph nodes: No focal lesions were seen.

Summary of findings: While there were no clinical description, in the deeper part of a single quarter coarse indurated portions were palpable. From microscopical findings it was shown that the indurated portions were comprised of very closely existing or multiply occurring lobular granulomatous chronic mastitis lesions. In addition there were lesions of mastitis alveolaris.

Case 6. TM 50 Cross-bred Holstein-Friesian cow Age unknown Slaughtered on 31/VIII '56 at the Obihiro meat packing plant.

Clinical findings: Later stage of lactation.

Macroscopical findings of the mammary gland: In the deeper part of one posterior quarter small brownish nodules were seen scattered.

Histological findings of the mammary gland: Teats: No abnormalities could be seen. Posterior 1: In the parenchyma inactive features of acini among which intermingled enlarged pictures of acini were seen. Some of the acini contained a few leukocytes in the lumen. Posterior 2: The nature was as described just above. Two foci of the size of groups of lobules were seen. The foci were filled with numerous granulomata. The granulomata were abundant in fibrocytes. Posterior 3: The findings were as described just above.

Summary of findings: A figure was of granulomatous mastitis of the size of groups of lobules which also have been macroscopically mentioned as nodules.

Case 7. M 7 Cross-bred Holstein-Friesian cow 10 years of age Slaughtered on 6/IV '56 at the Kaributo meat packing plant.

Clinical findings: This case was affected with traumatic mastitis in October of the

previous year. In spite of treatment, the response was worse and the mastitis went on aggravating and milking became gradually difficult.

Macroscopical findings of the mammary gland: Traumatic indurated lesions were seen in the right posterior quarter. The lymph nodes were enlarged. No notes are available as to the mammary gland.

Histological findings of the mammary gland: A 1, 2: No remarkable changes were seen in the teats. A 3: Showed inactive features of the parenchyma. A 4: Likewise showed inactive features of the parenchyma. In 2 groups of acini inflammatory changes were seen. B 1: In a section preparation, a focus discernible to the naked eye (0.4 cm in diameter) was seen directly under the epithelium of the mucous membrane in the opening of the teat. Approximately 10 granulomata were seen embedded therein. Each of the granulomata contained small spherical substances in the central part surrounded by a leukocyte layer of which the right outer circumference showed a well developed epithelioid cell layer; in the outermost layer, fibrous tissue proliferation was seen. B 2: No noteworthy changes were seen. B 3: Three groups of acini showed inflammatory changes, the others showed inactive features of the parenchyma. C 1: In the lumen of the deeper portion of the ductus papillosus (the region of mucous membrane) a colony of coccus-like substances was seen. This was surrounded by leukocytes. No abnormalities were recognized in the epithelial tissue facing the colony. C 2: In the parenchyma adjacent to the lumen further inwards from the teat opening a lobular focus was seen, while another (0.6 cm in diameter) was seen in a portion being slightly apart from the lumen. There were 20 odd granulomata embedded in these lesions. The structure of each granuloma was loose and colonies of coccus-like substances and leukocytes were seen mingled therein. Infiltration of lymphocytes and plasma cells was seen among the granulomata. C 3: Subepidermic tissue of the teat was edematous and thromboses were seen in the small arteries. C 4: One lobular group focus (1.5 cm in diameter) and 2 lobular foci were seen. The nature of these was similar to that in C 2. D 1: No remarkable changes were seen in the teat. D 2: No focal lesions were seen in the parenchyma adjacent to the teat. D 3: Inactive features of the parenchyma were seen. Furthermore, in the traumatically indurated portion a lesion, 3 cm in diameter, consisting of aggregation of granulomata was seen. Lymph nodes 1, 2 and 3: Lymphoid tissues were hyperplastic.

Summary of findings: Although macroscopical findings and the site from which the section preparation were taken out cannot be clearly defined, it was shown that in the parenchyma of 3 quarters at least, features of granulomatous chronic mastitis either in the size of a lobule or groups of lobules were visible. Furthermore, granulomatous features were seen in the lumen of the teat canal and in sites immediately adjacent thereto. Still further, granulomatous foci were seen in the right posterior quarter.

DISCUSSION

Of the 7 cases investigated, clinically 1 cases (Case No. 3) had been revealed by palpation to have indurative lesions in the tissue of the mammary gland, while macroscopically 4 cases (Case Nos. 4, 5, 6 and 7) were conjectured to have similar lesions; the remaining 2 showed histologically figures of granulomatous

mastitis. The histological diagnosis of the lesions is undoubtedly "actinomycotic" mastitis. However, etiologically speaking, since culture tests and others have not been conducted, there might be such a one as assert their opinion that final conclusion should be reserved. However, in view of the facts that fungus pathogenes could not be found in the stained section preparations, that the presence of accumulations of Gram-positive small spherical substances has been proven and that absence of similar lesions in the regional lymph nodes was noted, would like to have led the authors tentatively to disregard the possibility of genuine actinomycosis. Thus, in agreement with the opinions of English and American workers present writers would like to diagnose all 7 cases of this report as "granulomatous staphylococcal mastitis."

Hereupon, it is found interesting that among the indiscriminately investigated mammary gland cases in Hokkaido 6.14% were shown to be granulomatous staphylococcal mastitis. Previously HIRATO et al.⁶⁾, in Hokkaido, conducted bacteriological examination on the milk of 668 quarters which included ones of cases which were diagnosed as mastitis (62 mastitis milk, 297 normal milk, 309 abnormal milk). At the result, staphylococcus was purely isolated from 332 samples (26 mastitis milk, 150 normal milk, 156 abnormal milk). They further reported that 336 out of 515 strains of staphylococci were *Staphylococcus aureus*. Thus it might be reasonable to conjecture that if bovine mammary glands are subjected to histological examination, regardless of clinical mastitis, a considerable number of granulomatous staphylococcal mastitis cases might be detected. These circumstances let the authors surmise the existence of the possibility that at least a part of the lesions in mastitis circumscripta (mastitis alveolaris and mastitis lobularis) which was particularly pointed out in the writers' report I might eventually develop into granulomatous staphylococcal mastitis. It might be said that this surmise is verified also by the fact that, also in the literature, as mentioned above in the introduction, in case of individual cows of which the mammary glands had indurations to be able to palpate were made of the object at the time of mass inspections of dairy herds, etc., the frequency of detection of this disease was rather high. In any event, in the tissue of the mammary gland it is a definite fact that staphylococci do not necessarily give rise to this disease, and as regards the reason the statements by SMITH and JONES and RUNNELLS et al. are of great interest in which they explained that this disease was the result of the disruption of equilibrium between located bacteria and tissue. Further with special regard to the present Case No. 7, it should be pointed out that the traumatic induration of the udder has similar character for histological changes of the mammary gland and that a close relationship between the two exists. In this case since there was the fact that the treatment of trauma was continued for half a year, it may be readily conjectured that the

lesions of the mammary gland tissue are metastatic (through the teats) in nature.

Formerly, the authors on the basis of histological findings decided hastily the 7 cases as true actinomycosis, and the fact was considered as an important issue in public health. However, as described hitherto, the authors corrected now decision and came to take a profound interest in the importance of the relationship between the bovine mammary gland and staphylococci. And the authors came to be rather surprised at the lack of recent publications on the subject of this kind in recent years. The reason for this is of that considering the concept of mastitis circumscripta as set forth by YAMAGIWA et al. at the same time, the authors believe that further profound attentions should be clinically paid to staphylococcus as well as to streptococcus.

SUMMARY

In recent years, in view of the fact that reports on granulomatous staphylococcal mastitis are rare, in the present paper as to the mammary glands of 7 cases indiscriminately collected from meat packing plant materials, report was performed on the disease from the viewpoint of histopathology.

REFERENCES

- 1) ALBISTON, H. E. (1930): *Aust. vet. J.*, **6**, 2 [DAVIES]⁵⁾
- 2) ALBISTON, H. E. & E. M. PULLAR (1934): *Ibid.*, **10**, 146 [DAVIES]⁵⁾
- 3) BOSWARTH, T. J. (1930): Actinomycosis common to man and animals. Discussion at a joint meeting of sections of comparative medicine and surgery, the Royal Society of Medicine, vide Proc. Royal Society of Medicine, April, 1930 [*Vet. Rec.*, **10**, 588 (1930)]
- 4) COLEBROOK, L. (1930): *Ibid.*
- 5) DAVIES, G. O. (1935): *Vet. Rec.*, **15**, 15
- 6) HIRATO, K., K. SHIMIZU, T. KUNISHIGE, Y. SHIMIZU, K. OSAMURA, M. NAKAGAWA, H. NAGAYA, T. FUKUDA, T. KANMA & Y. TONO (1956): *J. Jap. vet. med. Ass.*, **9**, 159 (in Japanese)
- 7) KENDALL, E. A. (1914): *Vet. J.*, **70**, 132
- 8) MAGNUSSON, H. (1928): *Acta path. microbiol. scand.*, **5**, 170 [SMITH]¹⁰⁾
- 9) MAGROU, J. (1919): *Ann. Inst. Pasteur.*, **33**, 344
- 10) SMITH, H. (1934): *J. Amer. vet. med. Ass.*, **84**, 635
- 11) YAMAGIWA, S., T. ONO, T. UEMURA & T. IDA (1957): *Jap. J. vet. Res.*, **5**, 141

EXPLANATION OF PLATES

Refer to the text

PLATE I

Fig. 1. Case No. 5 Hematoxylin-eosin (H.-E.) stained × 49

Fig. 2.	Case No. 2	H.-E.	× 122
PLATE II			
Fig. 3.	Case No. 2	H.-E.	× 122
Fig. 4.	Case No. 2	H.-E.	× 490
PLATE III			
Fig. 5.	Case No. 4	Bielschowsky	× 490
Fig. 6.	Case No. 5	Gram-Weigert stained	× 122

ADDITIONALLY: NON INFLAMMATORY HISTOLOGICAL CHANGES IN THE MAMMARY GLAND DUE TO CONVERSION OF ITS FUNCTION.

Since the beginning of the present studies the authors have investigated the mammary gland of 143 meat packing plant cows obtained in Hokkaido and Gifu Prefecture. In their first report the authors attempted summary description on the histological findings of mastitis. In the next report it is the intention to describe on the histological classification of mastitis, prior to this some correction will be offered on non-inflammatory histological changes in the mammary gland which are believed to be due to conversion of function of the mammary gland. Although there were 53 cases among those investigated which presented evidence for explaining such changes, in the present paper 10 cases are dealt with, which were related to description and figures in report I. Further, in regard to the 3 cases of mastitis alveolaris (TM 3, TM 22, TM 1) and 1 case of mastitis diffusa (TM 4), which will be the cases presented in the following report, mention will be performed as to only the figures appended in report I.

DESCRIPTION OF CASES AND FIGURES

TM 8 5 years of age Slaughtered on 14/V '56 at the Asahigawa meat packing plant. Clinical findings: Unknown.

Macroscopical findings: The parenchyma showed a pale color and atrophic state. The interstitium showed increase in hardness and width.

Microscopical findings: Inactive features of the parenchyma were seen in Left anterior 1, 2, 3 and 4 together with Right posterior 1, 2 and 3.

Discussion: In report I the present case was added to macroscopical mastitis case. This is due to the fact that we stucked to the macroscopical findings which showed increase in hardness and width of the interstitial tissue.

TM 14 7 years of age Slaughtered on 23/V '56 at the Sapporo meat packing plant. Clinical findings: Infertility for the present year.

Macroscopical findings: Both sides of the quarters were enlarged and increase in width of the interstitium was seen in the cut surface.

Microscopical findings: Left anterior 1: Inactive features of the parenchyma were

seen intermingled with active features of the parenchyma. Left anterior 2: Inactive features of the parenchyma lied among active features were seen. Left anterior 3 and 4: Inactive features of the parenchyma were seen. Left posterior 1: Showed the same findings as in Left anterior 1. Left posterior 2: Inactive features of the parenchyma and transitional features of the parenchyma were seen lied therein. Left posterior 3: Inactive features of the parenchyma were seen.

Discussion: In report I the present case was added to the microscopical mastitis case. As regards the appended figures in report I the authors explained that "In *figs. 18 and 19*, only lobules which have fallen into mastitis lobularis-lesion are observed adjacent to each other. This can be regarded as a partial magnified picture of figure 14." However, this was due to the fact that too much importance was attached to the increase of width of the interstitial tissue in the macroscopical findings.

TM 16 8 years of age Slaughtered on 28/V '56 at the Sapporo meat packing plant.
Clinical findings: Pregnancy.

Macroscopical findings: Although there were some differences in each quarter respectively, the interstitial tissue showed increase in its width in general.

Microscopical findings: Left anterior 1: The parenchyma showed inactive features and in the interstitium slight emigration of eosinophil leukocytes was seen. Left anterior 2 and 3: The parenchyma showed inactive features. Left posterior 1: The parenchyma likewise showed inactive features. Left posterior 2: Transitional features to inactive features of the parenchyma intermingled with inactive features were seen. Left posterior 3: Inactive features of the parenchyma were seen.

Discussion: In report I the present case was added to the macroscopical mastitis case. This was due to the fact that too much importance was attached to increase of width of the interstitial tissue in the macroscopical findings.

TM 32 10 years of age Slaughtered on 18/VII '56 at the Sapporo meat packing plant.

Clinical findings: Unknown.

Macroscopical findings: The interstitial tissue was prominent while the parenchyma showed atrophy.

Microscopical findings: Left anterior 1: Transition to active features of the parenchyma was seen. Left anterior 2: Transitional features to inactive features of the parenchyma intermingled with inactive features were seen. Left anterior 3: The same as just above. Left posterior 1: Active features of the parenchyma intermingled with inactive features of the parenchyma were seen. Left posterior 2: The same as just above. In the interstitial tissue there was emigration of eosinophil leukocytes. Left posterior 3: The same as just above.

Discussion: In report I this case was classified as macroscopical mastitis case. This was due to the fact that too much importance was attached to the macroscopical findings.

TM 5 12~13 years of age Slaughtered on 7/V '56 at the Sapporo meat packing plant.
Clinical findings: No abnormalities were found.

Macroscopical findings: Increased hardness was palpated. The parenchyma showed a tone of light orange-yellowish color and the interstitium showed increase in width.

Microscopical findings: Transitional features were seen in Left anterior 2, 3 and 4. Left posterior 2, 3 and 4: The same as just above.

Discussion: In report I this case was classified as microscopical mastitis case. Too much importance was attached to the macroscopical findings. In report I, *figs. 10, 11, 12* and *13* were presented and it was pointed out that within one and the same lobule there were seen differences in nature depending upon acinar groups. However, such changes should not have been treated under mastitis alveolaris as findings of inflammatory ones.

TM 7 13 years of age Slaughtered on 10/V '56 at the Sapporo meat packing plant.

Clinical findings: Unknown. Pregnancy in 6~7 months.

Macroscopical findings: In the left anterior quarter remarkable increase in the width of the interstitial tissue was noted.

Microscopical findings: Inactive features of the parenchyma in Left anterior 1, 2 and 3 were seen. Left posterior 1: Transitional features of the parenchyma were seen intermingled with inactive features. Left posterior 2 and 3 showed transitional features of the parenchyma.

Discussion: In report I the present case was added to the macroscopical mastitis case. This was due to an overrating of the increase in width of the interstitial tissue in one quarter. In regard to *fig. 15* the findings were described as follows, however they should have been rather considered as non-inflammatory histological changes of the mammary gland. In report I it was stated that "In *fig. 15*, one-third of the area of the picture also indicates pathological tissue. Lobules which are embedded in proliferated interacinar connective tissue are atrophic. A microscopical investigation enables recognition of intralobularly proliferated fibrous tissue accompanied by infiltrated cells which are comprised of lymphocytes, leukocytes and particularly of plasma cells in quantity...."

TM 13 13 years of age Slaughtered on 21/V '56 at the Sapporo meat packing plant.

Clinical findings: Unknown.

Macroscopical findings: The parenchyma showed orange-whitish in color with a clear picture of the interstitium.

Microscopical findings: Left posterior 1, 2 and 3: Transition from active features to inactive of the parenchyma was seen.

Discussion: In report I the present case was added to the microscopical mastitis case.

TM 25 14 years of age Slaughtered on 26/VI '56 at the Sapporo meat packing plant.

Clinical findings: Hernia.

Macroscopical findings: The parenchyma appeared light yellowish in color with a well defined interstitium.

Microscopical findings: Left anterior 1, 2 and 3: Transitional features to inactive of the parenchyma were seen. Left posterior 1, 2 and 3: The same as just above.

Discussion: In report I the present case was added to the microscopical mastitis case.

TM 21 15 years of age Slaughtered on 11/VI '56 at the Sapporo meat packing plant.

Clinical findings: Unknown.

Macroscopical findings: The parenchyma appeared light yellowish in color with a well defined interstitium.

Microscopical findings: Left anterior 1, 2 and 3: Inactive features of the parenchyma were seen. Left posterior 1 and 2: Transitional features were seen intermingled with inactive features of the parenchyma. Emigration of eosinophil leukocytes was found in the interstitial tissue. Left posterior 3: Transitional features were seen intermingled with inactive features of the parenchyma.

Discussion: In report I the present case was added to the microscopical mastitis case.

TM 19 Age unknown Slaughtered on 7/VI '56 at the Sapporo meat packing plant.

Clinical findings: Unknown.

Macroscopical findings: Increase in width of the interstitial tissue was seen.

Microscopical findings: Left anterior 1, 2 and 3 showed inactive features of the parenchyma and emigration of eosinophil leukocytes was found in the interstitium.

Discussion: In report I the present case was added to the macroscopical mastitis case.

Next, we wish to comment on the appended figures of 4 cases, presented in report I, which will be the cases further dealt with in the report.

Report I, Fig. 14 (TM 3) In report I (p. 151) the authors wrote as follows; "To cite an example, many atrophic acini are observed existing in between interlobular fibrous tissues as shown in figure 14. Among the lobules with lesions, secreting lobules also exist."

The above was stated in having relation to mastitis lobularis. However, insofar as the figure is concerned the findings should be categorized as non-inflammatory changes coming from conversion of the function in the mammary gland.

Report I, Fig. 23 (TM 22) In report I (p. 154) the following statement was made: "The authors are of opinion that it may be reasonable to diagnose the change in figure 23 as mastitis lobularis cysticus."

This, too, was stated in having relation to the conditions of mastitis lobularis. However, at least the findings in the figure, should be categorized as non-inflammatory histological changes due to conversion of the function of the mammary gland.

Report I, Fig. 22 (TM 1) In report I (p. 154) the authors mentioned as follows: "As for figure 22, a few lobules and ducts shown in the picture are those existing among the lobules which manifest changes similar to that in the lower half of lobule shown in figure 10. In the lobule presented in figure 23, small ducts are dilated cystically, acini have either become atrophied or have disappeared. The increase of fibrocytic element shows a strong tendency and phagocytes and plasma cells are sporadically observed. There is no leukocytic infiltration. The argyrophile fibers show a conspicuous increase."

This was stated in having relation to the conditions of mastitis lobularis, however the findings in the figure should be considered to belong to non-inflammatory histological changes of the mammary gland.

Report I, Fig. 24 (TM 4) In report I, (p. 154) the authors reported as follows: "If it is permitted to confer the name of subacute to these changes in the six pictures

mentioned above, it is also allowable to give an interpretation to the following three pictures (figs. 22~24) as they show chronic changes.”

This, also, was stated in having relation to the conditions of mastitis lobularis, but the findings in the *fig. 24* should be categorized just like the *figs. 22* and *23*, as non-inflammatory histological changes of the mammary gland.

In the above, the writers believe that they have been able to give an outline of non-inflammatory histological changes based on conversion of mammary gland function. Thus, the writers have to take aware of that they have made erroneous statements in regard to the findings or figures in the 14 cases in their report I. As for why the misunderstanding was brought on, there are enumerated roughly divided two causes which may already be apparent in the above. The first—too much importance was assigned to the increase of width of the interstitium in macroscopical findings. The second—the cell infiltration in the interstitial areas in microscopical findings was mis-interpreted as chronically developed events of mastitis circumscripta especially mastitis lobularis. Thus, it comes to this, that in report I the following statements have been made in the discussion (p. 163): “There are some cases which showed similar wide distribution to that of the multilobular type among those which are classified as mastitis circumscripta; these cases may give an impression to someone that the difference from mastitis diffusa is obscure. In this regard, the authors particularly would like to point out that important discrepancies of the characteristics of pathological changes between the two types still can be stressed as they do exist. At this time, they have no intention to adhere to the titles of classification. In short, the authors are of opinion that the differentiation is good enough if the cases only prove to have the following characteristics. 1. Microscopical minute foci develop multilocally in mastitis circumscripta. 2. The minute foci, secondary, terminate their pathological changes with interstitial inflammatory reactions in lobule or groups of lobule following the fairly mild progression of the disease. 3. Furthermore, the duct system does not provide a location for the lesion”.

Summing up, the authors published an additional report upon which some parts of the description and the concerned appended figures which were described having relation to the diagnosis of mastitis circumscripta especially mastitis lobularis in report I should be understood as non-inflammatory changes based on conversion of unction of the mammary gland tissue.

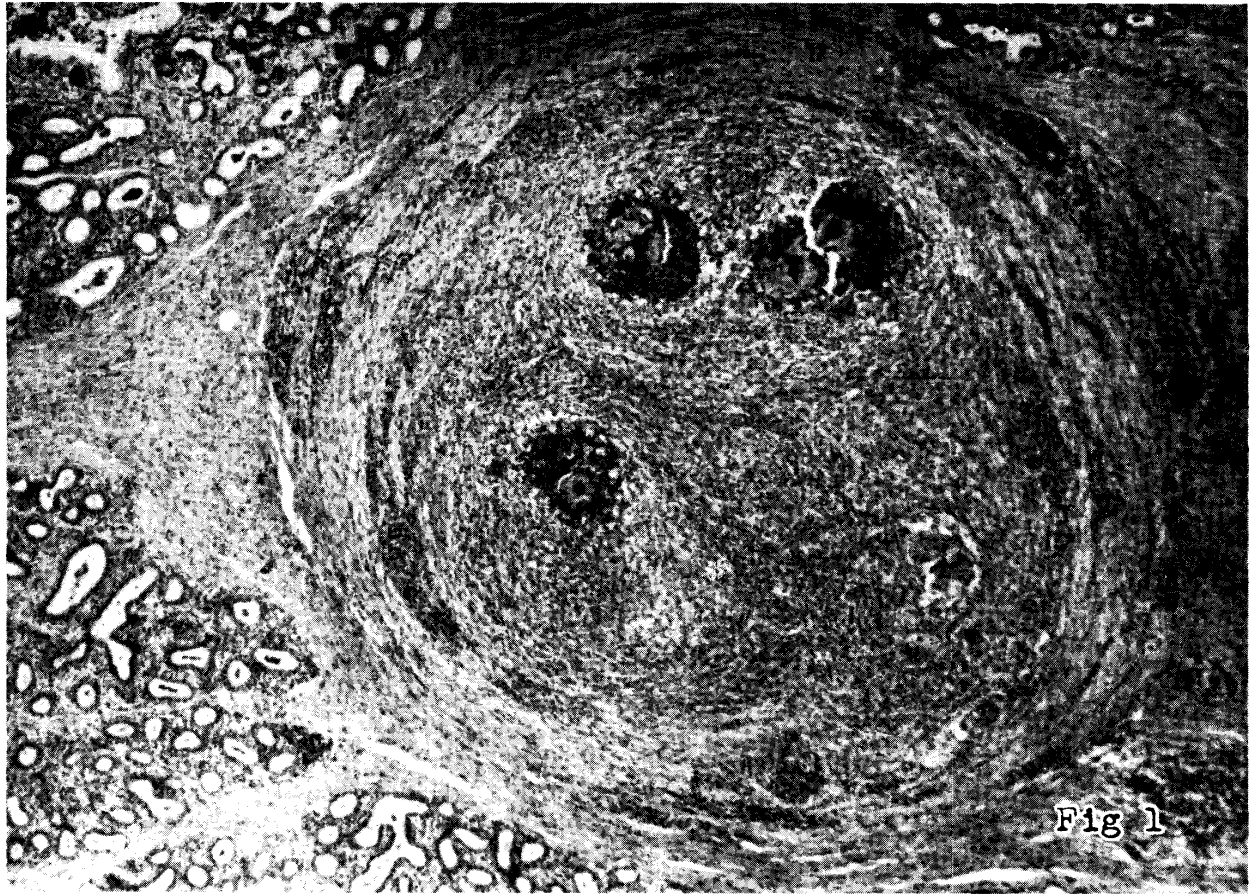

Fig 1

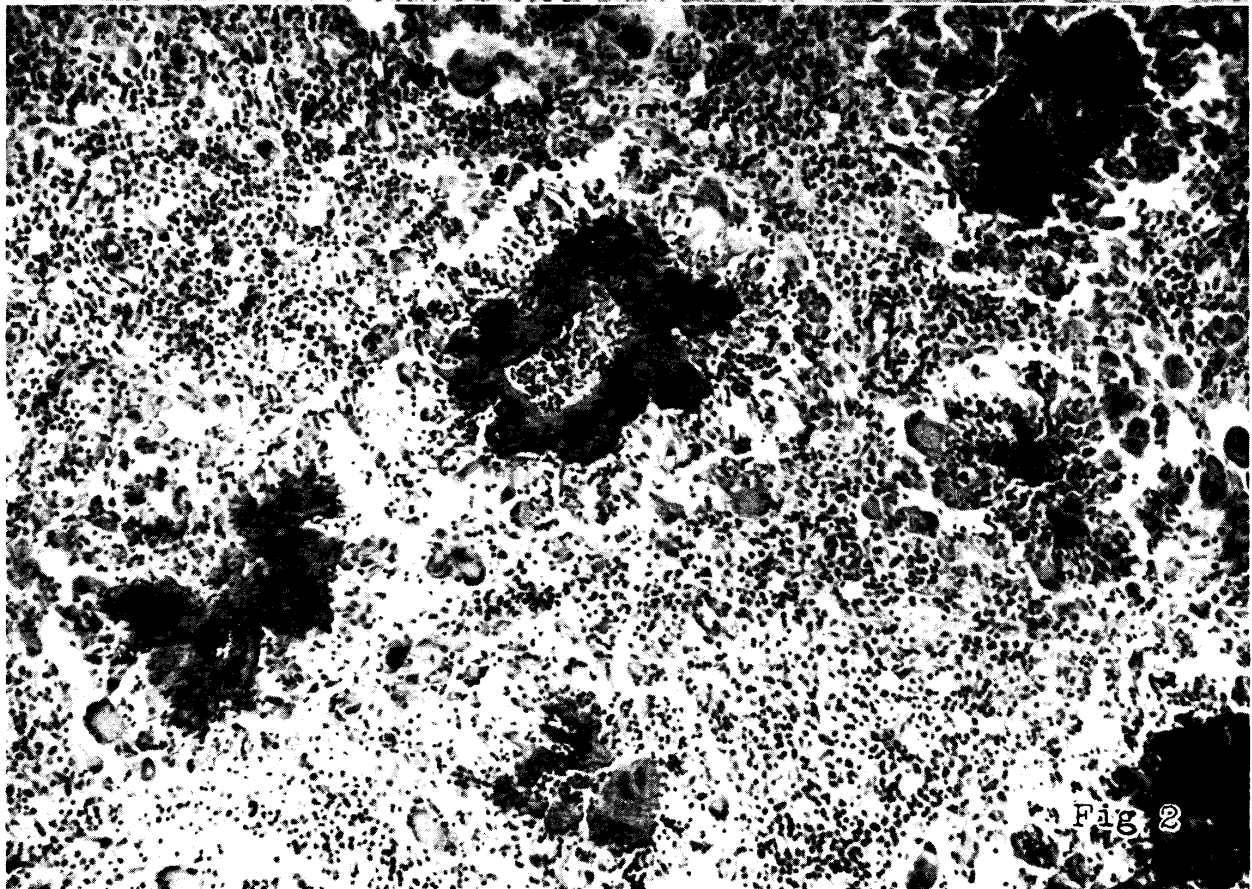


Fig 2

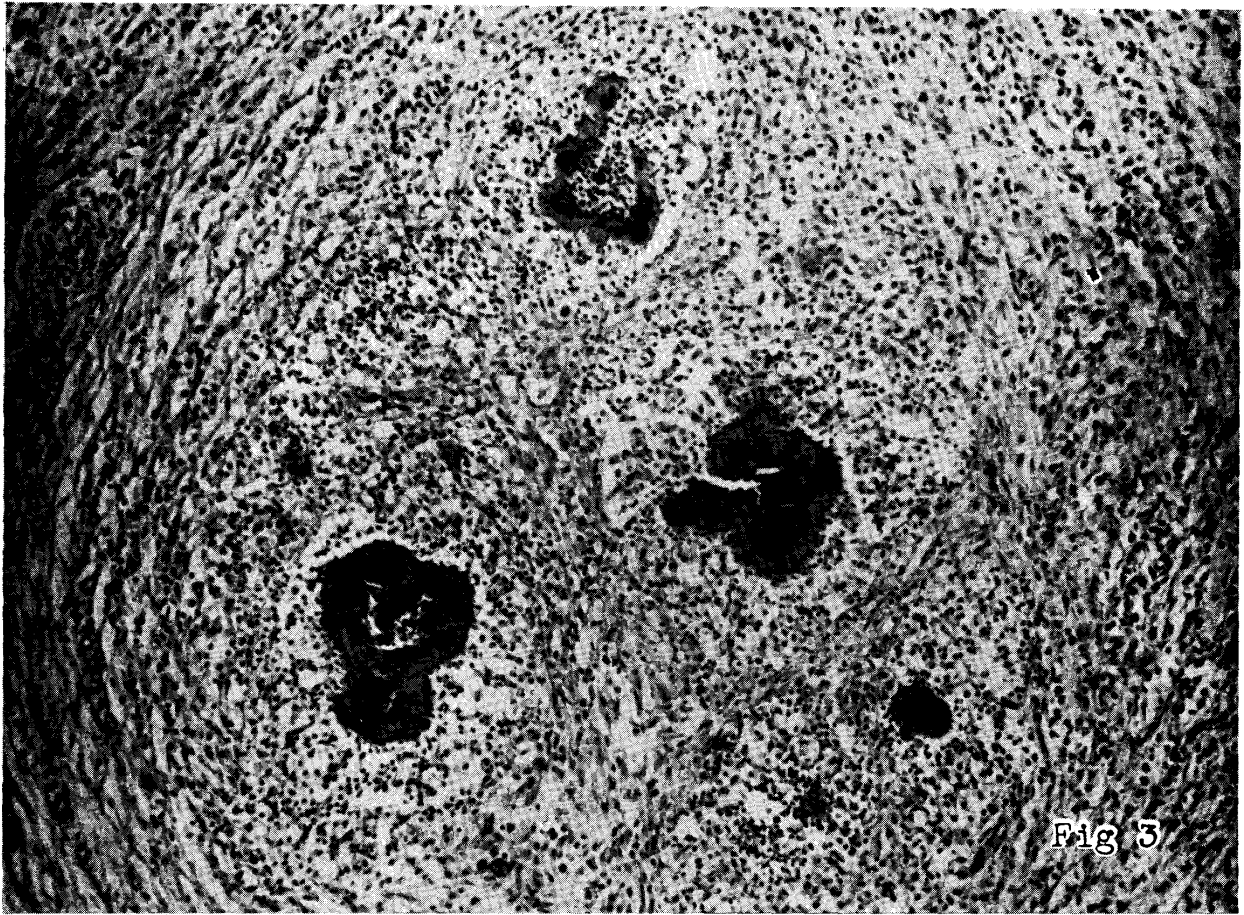


Fig 3

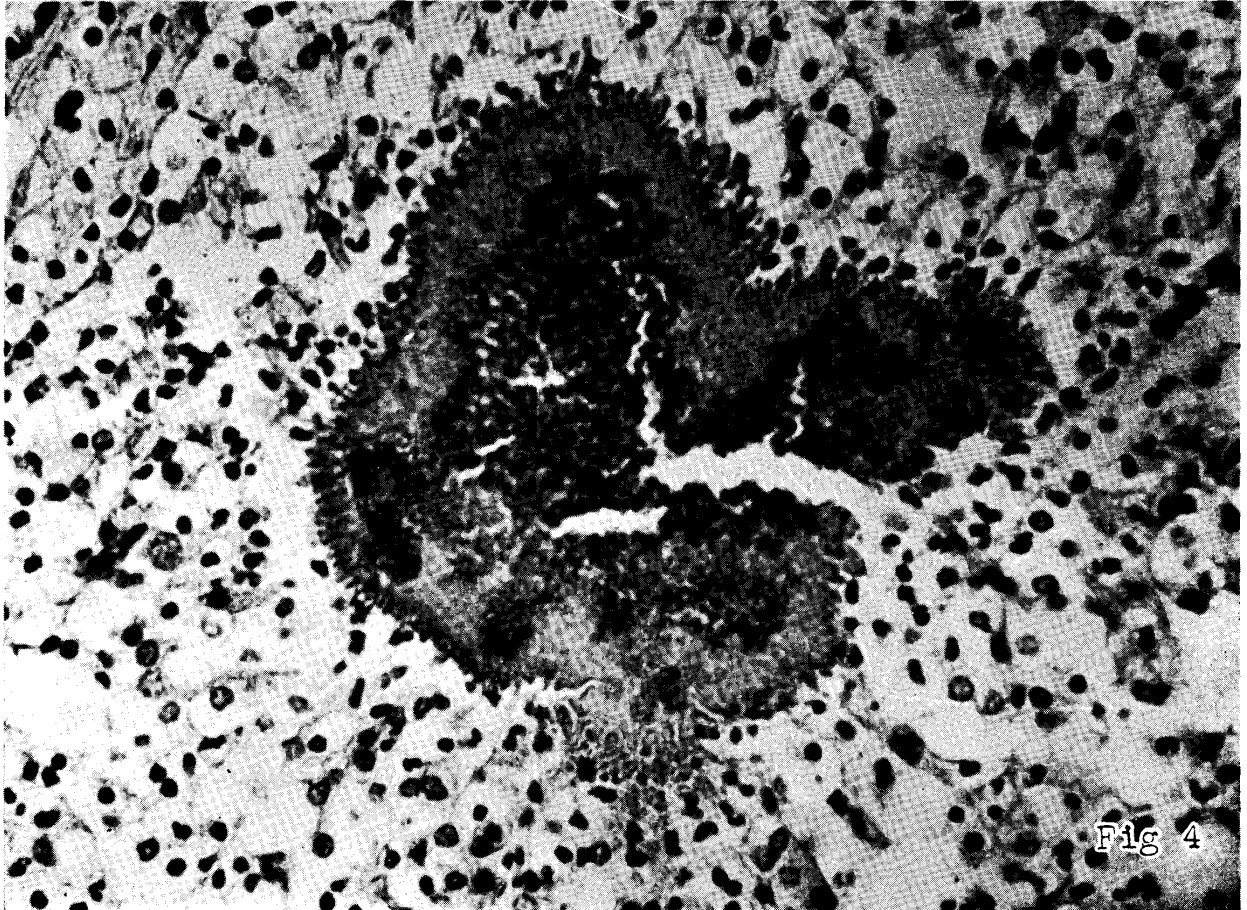


Fig 4

