



Title	HISTOPATHOLOGICAL STUDIES ON BOVINE MAMMARY GLAND II. : TISSUE REACTION TO MICROSCOPICAL PSEUDOCONCREMENT
Author(s)	YAMAGIWA, Saburo; ONO, Takeshi; UEMURA, Tamio; IDA, Taiji
Citation	Japanese Journal of Veterinary Research, 6(1), 51-61
Issue Date	1958-03-25
DOI	10.14943/jjvr.6.1.51
Doc URL	http://hdl.handle.net/2115/1727
Type	bulletin (article)
Note	<p>Neither the nature of microscopical pseudoconcrements nor their genesis were intended for detailed discussion in this paper. If findings pertaining to such problems are required based on microscopical investigation, differences of incidence depending on location need to be clearly describe in a larger number of cases. Authors' direct purpose lay in discussing the various responses of mammary gland tissue to the pseudoconcrement. Therefore, it should not be expected that their discussion would be of assistance in solving the opposite opinions held by E. JOEST and W. STECK, and MCFADYEAN. The present author would like to point out that the cause of different opinions might be traced to neglect in taking into consideration the differences in the materials investigated. While MCFADYEAN selected fairly normal mammary gland as the material for his investigation, JOEST and STECK used the pseudoconcrements in pathological mammary gland for their investigation at least judging from their figures. It is obvious that the results of the present authors' research make it possible for them to say a pseudoconcrement is an endogenous foreign body which normally is proved to be located in the lumen of acinus. In this connection, a problem lies in JOEST and STECK'S research in that the material is limited to the pseudoconcrement which predominates in epithelial layer or stands on the wall of acinus and duct. On the contrary, MCFADYEAN did not seem to pay much attention to the appearance of pseudoconcrement in the tissue regardless of parenchyma and interstitium. It can be interpreted that the opposition in reports of the early authors has resulted from the materials used. The materials of the present investigation are the cases of mastitis circumscripta and mastitis diffusa reported in the first paper. The results of this investigation can be summarized as follows. 1. It can be said without doubt that the pseudoconcrement is produced in the lumen of acinus. 2. Importance should be attached to the histological features of the epithelium which envelops the pseudoconcrement which is proved to be attaching to the wall of acinus and duct, particularly in the lumen of the latter. 3. The pseudoconcrements which occurred in ductal epithelium and were embedded in interstitium show passive tissue reaction. 4. The authors wonder why not they can say that such histological findings can be resulted from the nature of acinar and ductal epithelia, particularly of the latter. The authors are of opinion that the tendency of the characteristics of the epithelial layer in inflammatory mammary gland tissue to envelop and absorb foreign body should be emphasized.</p>
File Information	KJ00002373149.pdf



Instructions for use

HISTOPATHOLOGICAL STUDIES ON BOVINE
MAMMARY GLAND II.
TISSUE REACTION TO MICROSCOPICAL
PSEUDOCONCREMENT

Saburo YAMAGIWA*, Takeshi ONO**, Tamio UEMURA***
and Taiji IDA****

(Received for publication, January 10, 1958)

Among the points which attract the attention of those who conduct microscopical examination on mammary gland tissue, there is an appearance of so-called amyloid bodies (*Corpora amylacea*; microscopical pseudoconcrements****). The present authors are of opinion that the matter of whether or no these pseudoconcrements are pathological products has often been discussed may be traced to the frequent appearance of the pseudoconcrements. The authors conducted investigation in this regard centering around morphological findings, particularly on the response of mammary gland tissue to these pseudoconcrements.

Two reports completed by leading investigators—E. JOEST and W. STECK, and J. MCFADYEAN—can be cited as recapitulated ones which are based upon the same view point as the present authors'. Such contradictory interpretations, however, still remain as they were some 20 years ago. With regard to the origin of the pseudoconcrements, while JOEST and STECK sought their formation only in acinar epithelium, MCFADYEAN did not agree stressing that the pseudoconcrements freely exist in the lumen of the acinus and that epithelial and other type of cells have no relation to the development of the pseudoconcrements judging from the aspect of their free existence.

Present authors' research materials were 54 and 19 quarters of mammary gland which were diagnosed as *mastitis circumscripta* and *mastitis diffusa* respectively just like those used in preparing the first report.³⁾ The following are explanations of the photographs which illustrate their findings.

* Department of Veterinary Pathology, Faculty of Veterinary Medicine, Hokkaido University, Sapporo.

** Laboratory of Veterinary Pathology, Obihiro Zootechnical College, Obihiro.

*** Health Department of Hokkaido Prefectural Government.

**** Adopting E. JOEST's nomenclature; the present authors hereafter will call them by that name (Mikroskopische Pseudokonkremente).

EXPERIMENTAL RESULTS

1. Pseudoconcrement Freely Existed in the Lumen of Acinus and Duct

This can easily be pointed out from the photographs contained in the first report (Figs. 3, 8, 9 & 28).

Fig. 1.* Pseudoconcrements are observed in the lumina of secreting acini and intralobular ducts. Each of them is fairly stained with hematoxylin with its accompanying cloud-like structure, and has no tissue reaction.

FIG. 1. TM 18, L, P. H.-E. $\times 120$

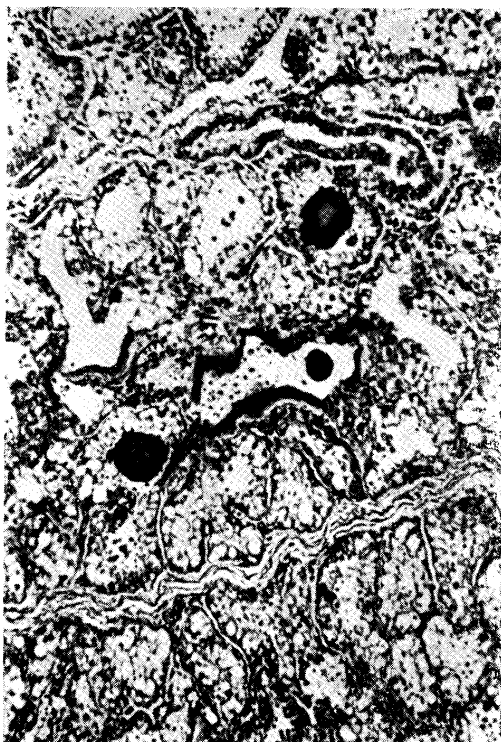
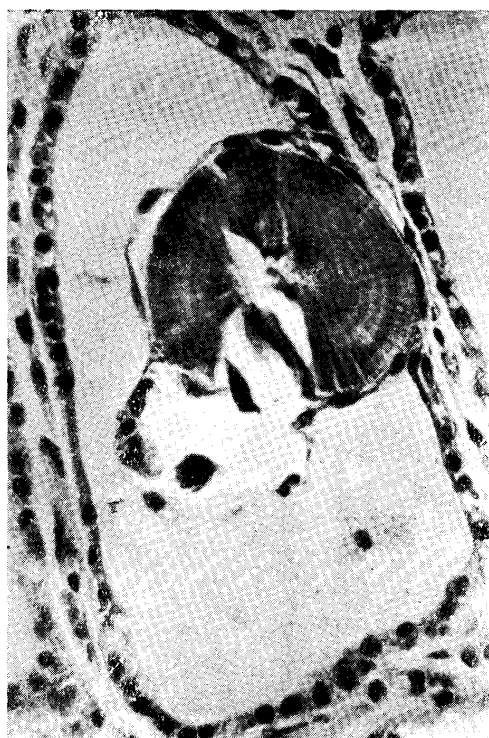
FIG. 2. TM 9, L, P. H.-E. $\times 400$



2. Pseudoconcrement Attached to the Wall of Acinus

Fig. 2. The pseudoconcrements are observed sporadically in the lumina of acini, but the majority exist freely. Photographed acinus is the intact portion and epithelial cell layer seems to envelop the pseudoconcrements in the lumen. There must have been 2 pseudoconcrements, but one of them is remaining vacant focus artificially. The other contains beautifully laminated and radial structure.

* With each figure is printed: case No., the portion from where the section preparation was obtained, staining method and magnification in order. L indicates left side, R right side, A anterior quarter of mammary gland and P posterior.

Fig. 3. In this case, pseudoconcrements are embedded in the interstitium also sporadically as well as in the lumen of acinus. Those in the intraacinar part normally exist independently, but the one in the photograph is obviously enveloped by the epithelial cell layer.

3. Pseudoconcrement Attached to the Wall of Duct

Fig. 4. *Mastitis circumscripta* The course of the disease indicated slight chronic symptoms. The left part of the photograph presents a straight section of the intra-lobular duct. Several pseudoconcrements are observed in the lumina. Each of them is enveloped by mono-layered epithelium (cf. Figs. 2 & 3). There is a pseudoconcrement occurring in the epithelial cell layer of duct. Free existence of pseudoconcrements in the intact lumina of acini is observed in various portions as well as in the right of the photograph, but none indicates tissue reaction.

Fig. 5. *Mastitis circumscripta* indicating the expansion of acinus or group of acini. The pseudoconcrements occur in disorder, but those may be noted which take occupancy of epithelial layer of duct, of which similar occurrences are observed in two places in the photograph. The pseudoconcrements are located on the basement membrane. Epithelial cells seem to be oppressing the surface of the pseudoconcrement at the contact area. Nuclei of these cells are observed to have become slender and as if they are endothelial cells at the covered portions.

Fig. 6. *Mastitis diffusa* of which duct offers the location of inflammation. The number of pseudoconcrements is extremely small. The photograph presents a part of duct. The structure of epithelial cell layer become irregular and it contains an infiltration of emigrated cells. Pseudoconcrement appearing in the center of the photograph contains in its core an aggregation of granular substances; its circumference is enveloped by a cylindrical epithelial layer.

Fig. 7. Lesion indicating the expansion of acinus and group of acini, of which interstitium became fibrous containing a few pseudoconcrements. The photographed pseudoconcrement, as well as that in the previous photographs, projects into the lumen of duct and is enveloped by epithelial cells. The most outstanding characteristics of this case are that the pseudoconcrement changes into an aggregation of fibrous substances and that the eosin-stained substance contains a few nuclei of fibrocytes.

FIG. 3. TM 9, L, A. H.-E. $\times 400$

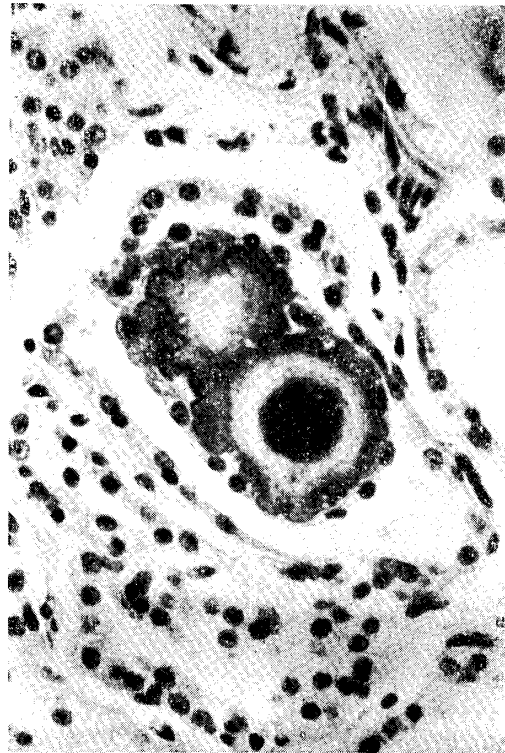

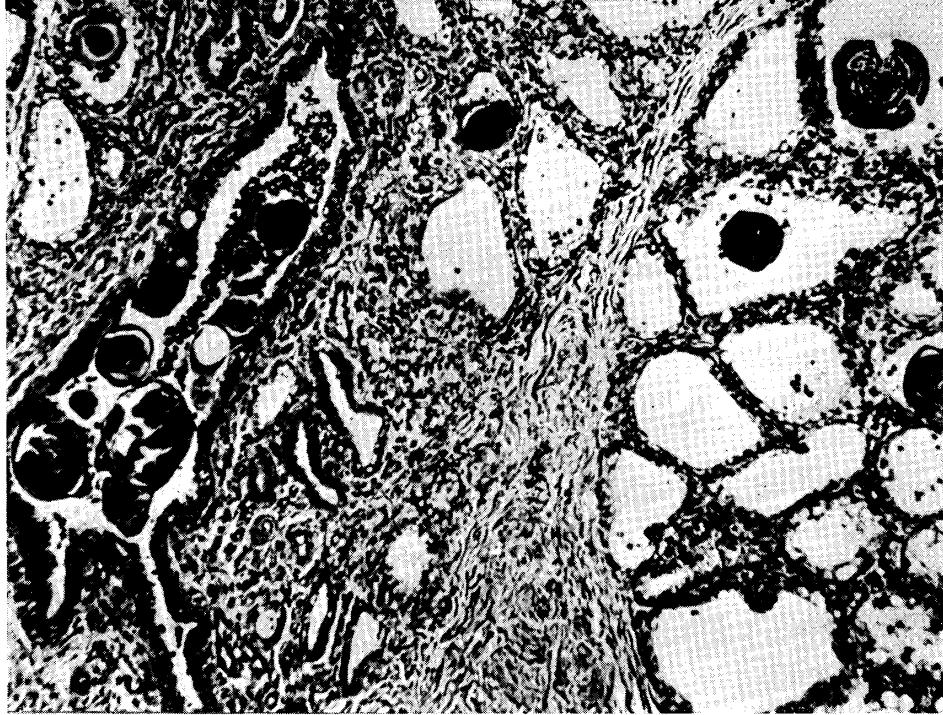
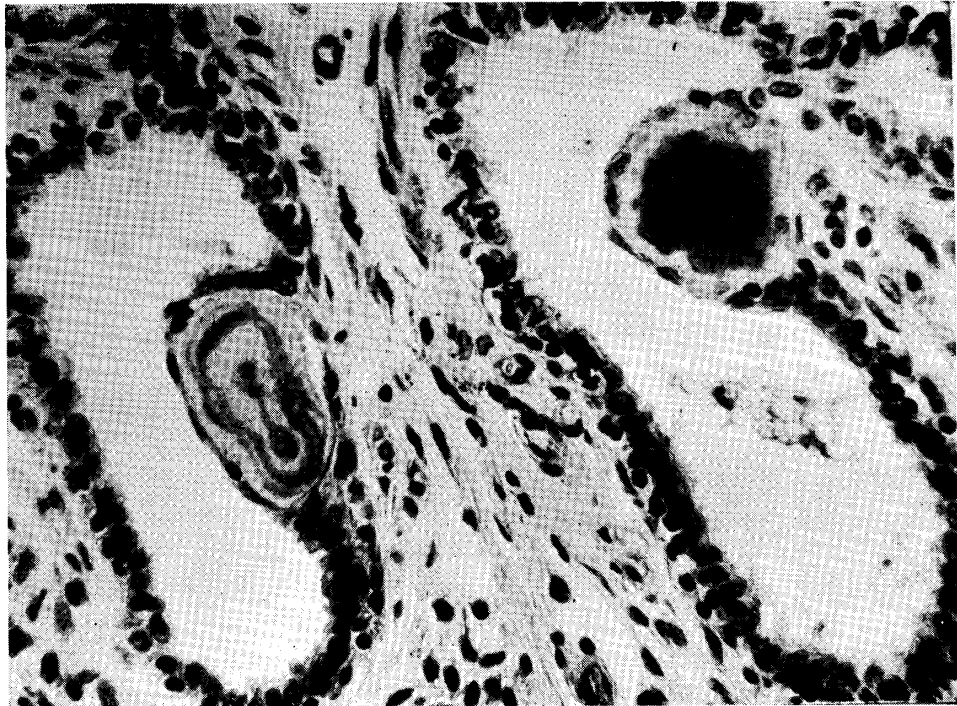
FIG. 4. *TM, 6, L, P. H.-E. ×120*FIG. 5. *TM 21, L, A. H.-E. ×400*

FIG. 6. *TM 27, L, P. H.-E. ×400*

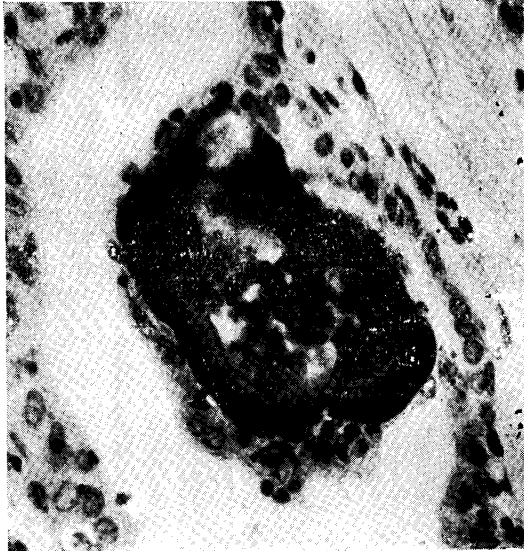


FIG. 7. *TM 4, L, A. H.-E. ×400*

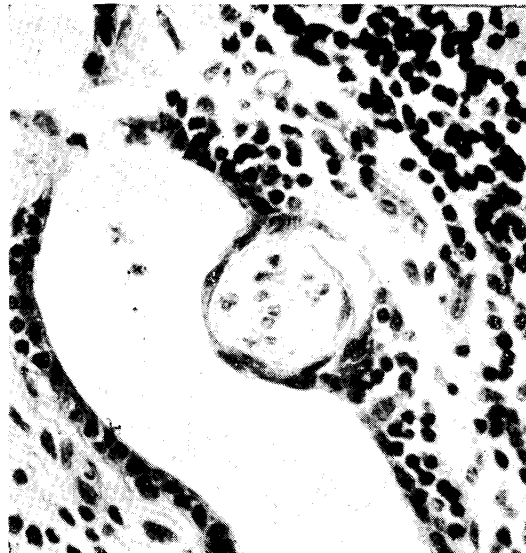
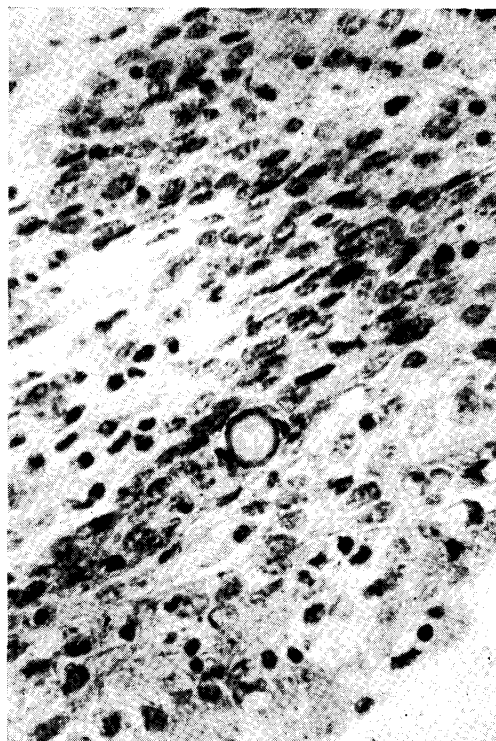


FIG. 8. *TM 15, L, P. H.-E. ×120*



FIG. 9. *TM 28, L, A. H.-E. ×400*



4. Pseudoconcrement Located in Epithelium of Duct

Fig. 8. Diagnosed as chronic interstitial lobular mastitis (*Mastitis circumscripta*) histologically. The photograph presents a few small pseudoconcrements (c indicates the pseudoconcrement). They are all located in the epithelia of the duct and all slightly protrude into the lumina. The pseudoconcrement itself is either faintly stained with hematoxylin, amorphous and homogeneous or is accompanied by cloud-like structure.

Fig. 9. *Mastitis diffusa* of an early stage; specimen contains intact parenchymal portions. The right part of the photograph shows the lumen of large-sized duct containing exudates. Epithelial layer seems to be thickened, for the epithelial cells present proliferation which is accompanied at the same time by degeneration and desquamation. There is an infiltration of emigrated cells. S-shaped surrounding epithelial layer indicates the existence of a small pseudoconcrement, which is faintly stained with hematoxylin showing formation of centripetal laminated structure obscurely. There is no particular reaction in its surrounding parts.

The findings noted above are also observed in portions other than the photographed. The existence of pseudoconcrements in the lumina of ducts and acini can scarcely be identified.

Fig. 10. *Mastitis diffusa* with conspicuous interstitial changes. The center of the photograph presents a pseudoconcrement located in ductal epithelium. The existence of the pseudoconcrement on the side of the lumen of basement membrane is obvious; it is enveloped by epithelial cells. The inflammatory change of duct system is slight.

FIG. 10. TM 15, L, A. H.-E. $\times 400$

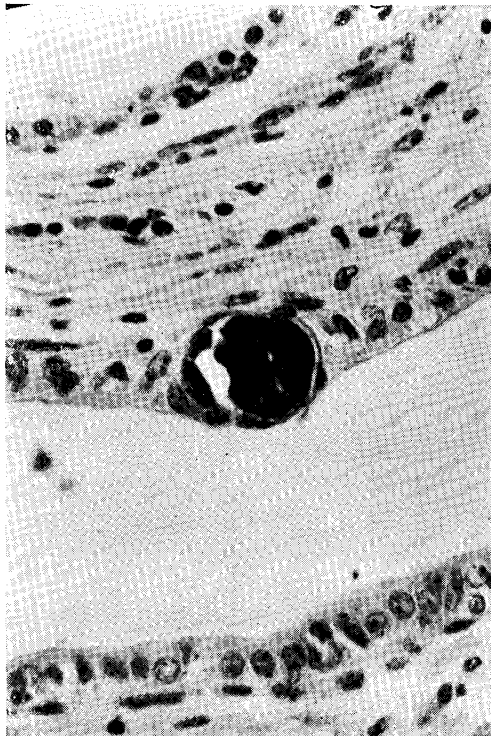
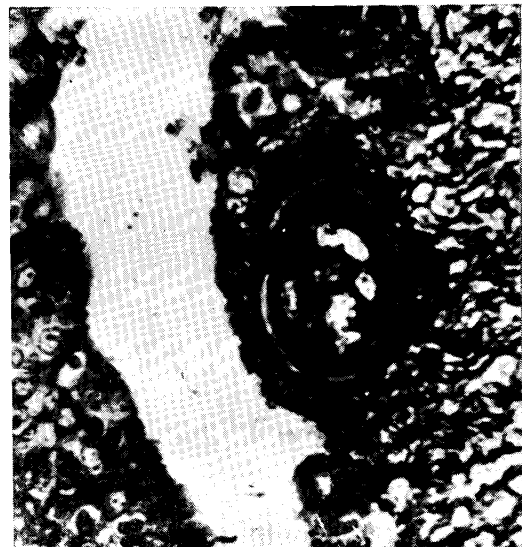
Fig. 11. Pseudoconcrement which takes

FIG. 11. TM 23, L, A. BIELSCROWSKY.

$\times 400$



occupancy of poly-layered ductal epithelium. Argyrophile fibers form a capsule surrounding the pseudoconcrement. The fibers of subepithelial layer are invading the epithelium through the basement membrane.

5. Pseudoconcrement Located in Interstitium

Fig. 12. *Mastitis diffusa*, observe the concrement in the center of the photograph. It is surrounded by argyrophile fibers separated from epithelial cells by basement membrane and seems to push the basement membrane toward the lumen.

Fig. 13. *Mastitis circumscripta*. Pseudoconcrements are few in number; they are observed only in proliferated fibrous tissue excepting one or two. Four pseudoconcrements can be found in the photograph. The arrangement of surrounding tissue varies as the pseudoconcrements are surrounded by dense fibrous tissue in the lower right of the photograph and embedded in cell-poor tissue in the upper left.

Fig. 14. Same case as figure 1, shows lobular mastitis and contains a pseudoconcrement nearly in the center of the photograph. No particular cell reaction, but strong tendency of eosinophile infiltration generally presented.

Fig. 15. *Mastitis diffusa*. An irregular-shaped pseudoconcrement contacting intralobular connective tissue is embedded. The surrounding area looks coarse, but includes fibrocytes rich in protoplasm.

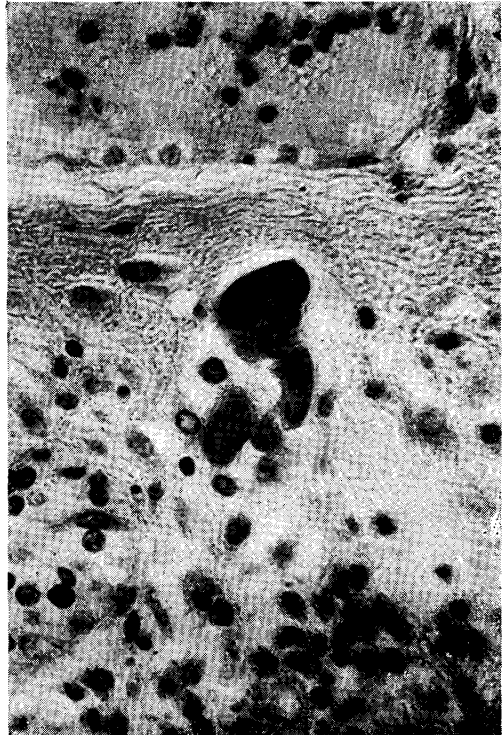
Fig. 16. The center of photograph presents a pseudoconcrement embedded in fibrous interstitium of chronic diffuse mastitis. There is a proliferation of argyrophile fibers in its surrounding area,

FIG. 13. *TM 14, L, A. H.-E. ×120*

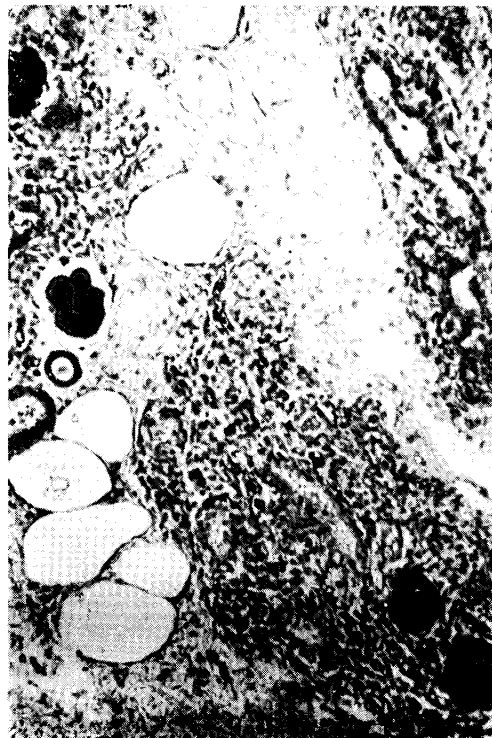

FIG. 12. *TM 28, L, P. BIELSCHEWSKY. ×400*

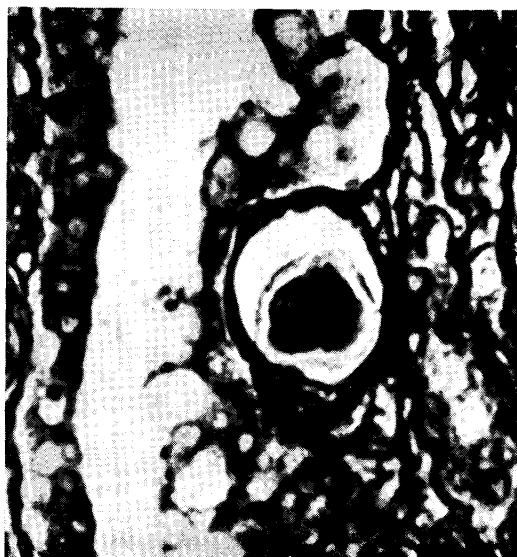
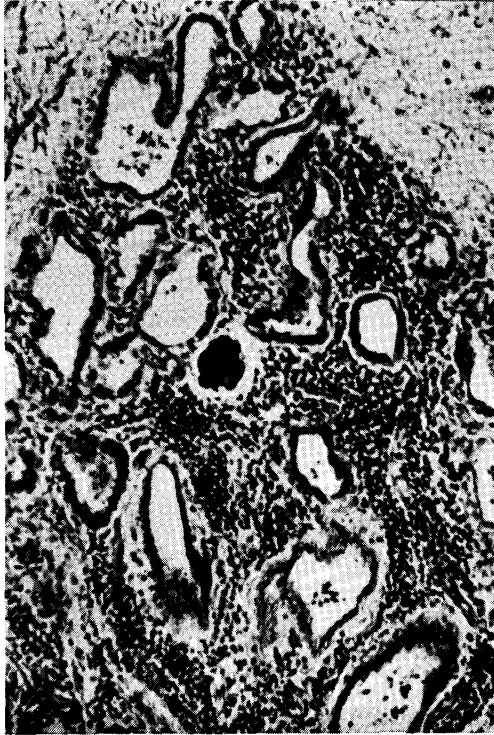
FIG. 14. *TM 18, L, P. H.-E. ×120*FIG. 15. *TM 28, L, A. H.-E. ×400*

which is dense, particularly in the portion contacting the pseudoconcrement.

Fig. 17. *Mastitis circumscripta* with a considerable number of pseudoconcrements which are all predominant in the interstitium. The photographed is intended to represent them. Surrounding tissue shows no difference from other general inflammatory interstitial tissue.

Fig. 18. *Mastitis circumscripta* with a small number of pseudoconcrements. The photographed pseudoconcrement is located in the perilobular interstitial tissue accompanying a foreign body giant cell on the right.

Fig. 19. *Mastitis circumscripta* with a small number of pseudoconcrements in the lumina of intact acini. A small number of pseudoconcrements are also observed in interstitial tissue as appears in the photograph. Such a pseudoconcrement takes irregular shape and its surrounding is faintly eosin-stained homogeneous hyalinous substance. It is interpreted as a part of homogeneous hyalinous substance which wedges into the pseudoconcrement. In addition, a foreign body giant cell can be recognized in the lower part of the hyalinous substance.

FIG. 16. *TM 15, R, P. BIELSCHOWSKY.*
×400

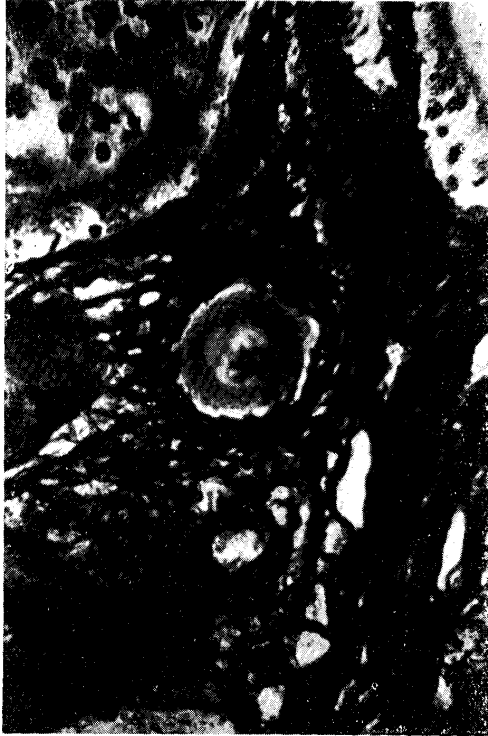

FIG. 17. *TM 15, R, P. H.-E. ×400*

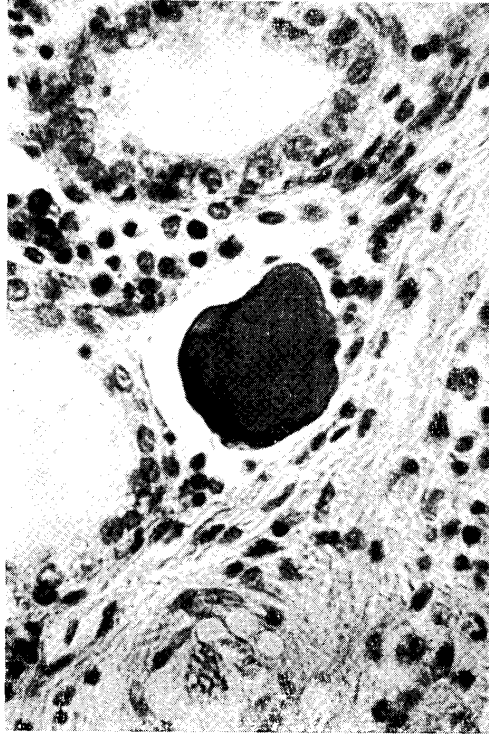


FIG. 18. *TM 14, L, P. H.-E. ×400*

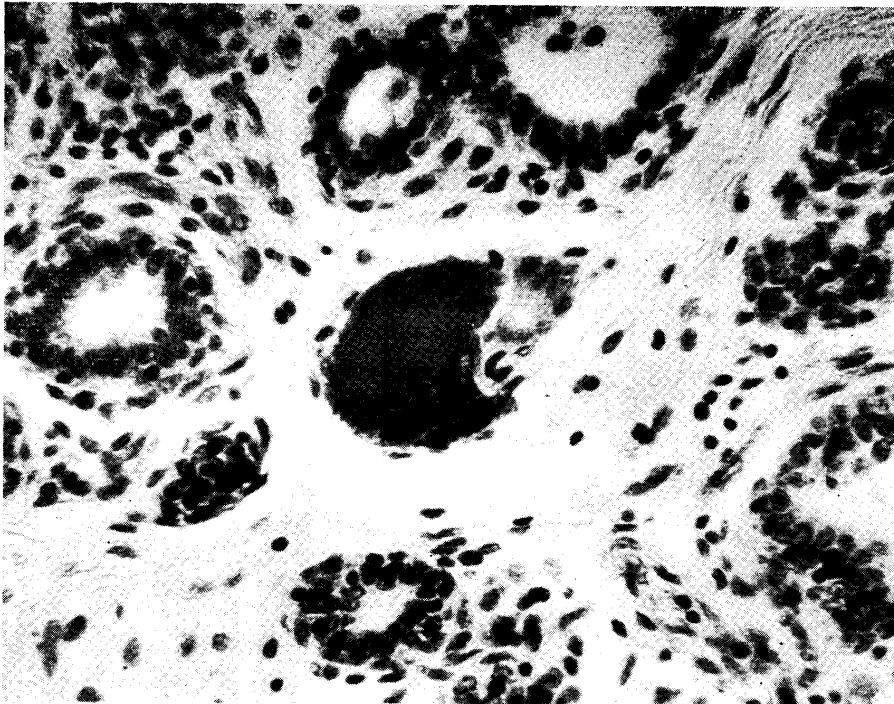
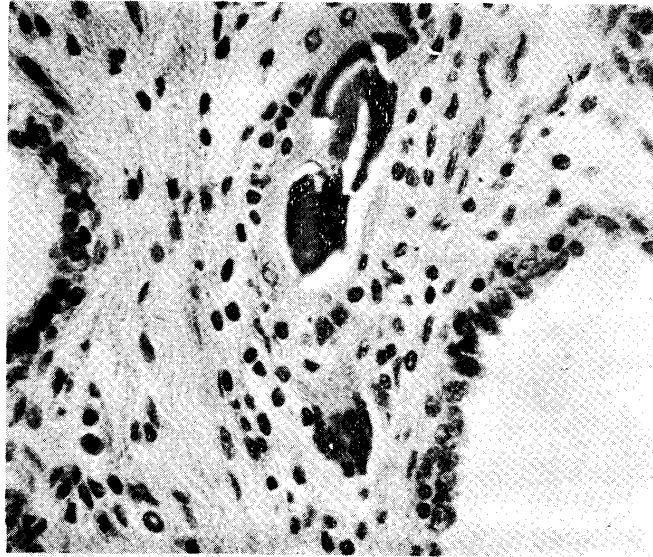


FIG. 19. *TM 24, L, P. H.-E. ×400*

DISCUSSION AND SUMMARY

Neither the nature of microscopical pseudoconcrements nor their genesis were intended for detailed discussion in this paper. If findings pertaining to such problems are required based on microscopical investigation, differences of incidence depending on location need to be clearly describe in a larger number of cases. Authors' direct purpose lay in discussing the various responses of mammary gland tissue to the pseudoconcrement. Therefore, it should not be expected that their discussion would be of assistance in solving the opposite opinions held by E. JOEST and W. STECK, and MCFADYEAN. The present author would like to point out that the cause of different opinions might be traced to neglect in taking into consideration the differences in the materials investigated. While MCFADYEAN selected fairly normal mammary gland as the material for his investigation, JOEST and STECK used the pseudoconcrements in pathological mammary gland for their investigation at least judging from their figures.

It is obvious that the results of the present authors' research make it possible for them to say a pseudoconcrement is an endogenous foreign body which normally is proved to be located in the lumen of acinus. In this connection, a problem lies in JOEST and STECK's research in that the material is limited to the pseudoconcrement which predominates in epithelial layer or stands on the wall of acinus and duct. On the contrary, MCFADYEAN did not seem to pay much attention to the appearance of pseudoconcrement in the tissue regardless

of parenchyma and interstitium. It can be interpreted that the opposition in reports of the early authors has resulted from the materials used.

The materials of the present investigation are the cases of *mastitis circumscripta* and *mastitis diffusa* reported in the first paper. The results of this investigation can be summarized as follows.

1. It can be said without doubt that the pseudoconcrement is produced in the lumen of acinus.

2. Importance should be attached to the histological features of the epithelium which envelops the pseudoconcrement which is proved to be attaching to the wall of acinus and duct, particularly in the lumen of the latter.

3. The pseudoconcrements which occurred in ductal epithelium and were embedded in interstitium show passive tissue reaction.

4. The authors wonder why not they can say that such histological findings can be resulted from the nature of acinar and ductal epithelia, particularly of the latter. The authors are of opinion that the tendency of the characteristics of the epithelial layer in inflammatory mammary gland tissue to envelop and absorb foreign body should be emphasized.

REFERENCES

- 1) JOEST, E. & W. STECK (1924): *Z. InfektKr. Haustiere*, **26**, 21.
- 2) MCFADYEAN, J. (1929): *J. comp. Path.*, **43**, 1.
- 3) YAMAGIWA, S., T. ONO, T. UEMURA & T. IDA (1957): *Jap. J. vet. Res.*, **5**, 141.