

CLINICAL—ALIMENTARY TRACT

Abdominothoracic Mechanisms of Functional Abdominal Distension and Correction by Biofeedback



Elizabeth Barba,^{1,2,3,*} Emanuel Burri,^{1,2,3,*} Anna Accarino,^{1,2,3} Daniel Cisternas,^{1,2,3} Sergi Quiroga,⁴ Eva Monclus,⁵ Isabel Navazo,⁵ Juan-R. Malagelada,^{1,2,3} and Fernando Azpiroz^{1,2,3}

¹Digestive System Research Unit, University Hospital Vall d'Hebron, Barcelona, Spain; ²Centro de Investigación Biomédica en Red de Enfermedades Hepáticas y Digestivas (Ciberehd), Barcelona, Spain; ³Departament de Medicina, Universitat Autònoma de Barcelona, Bellaterra (Cerdanyola del Vallès), Spain; ⁴Radiology Department, University Hospital Vall d'Hebron, Barcelona, Spain; and ⁵Departamento de Lenguajes y Sistemas Informáticos, Universidad Politécnica de Catalunya, Spain

BACKGROUND & AIMS: In patients with functional gut disorders, abdominal distension has been associated with descent of the diaphragm and protrusion of the anterior abdominal wall. We investigated mechanisms of abdominal distension in these patients. **METHODS:** We performed a prospective study of 45 patients (42 women, 24–71 years old) with functional intestinal disorders (27 with irritable bowel syndrome with constipation, 15 with functional bloating, and 3 with irritable bowel syndrome with alternating bowel habits) and discrete episodes of visible abdominal distension. Subjects were assessed by abdominothoracic computed tomography (n = 39) and electromyography (EMG) of the abdominothoracic wall (n = 32) during basal conditions (without abdominal distension) and during episodes of severe abdominal distension. Fifteen patients received a median of 2 sessions (range, 1–3 sessions) of EMG-guided, respiratory-targeted biofeedback treatment; 11 received 1 control session before treatment. **RESULTS:** Episodes of abdominal distension were associated with diaphragm contraction (19% ± 3% increase in EMG score and 12 ± 2 mm descent; $P < .001$ vs basal values) and intercostal contraction (14% ± 3% increase in EMG scores and 6 ± 1 mm increase in thoracic antero-posterior diameter; $P < .001$ vs basal values). They were also associated with increases in lung volume (501 ± 93 mL; $P < .001$ vs basal value) and anterior abdominal wall protrusion (32 ± 3 mm increase in girth; $P < .001$ vs basal). Biofeedback treatment, but not control sessions, reduced the activity of the intercostal muscles (by 19% ± 2%) and the diaphragm (by 18% ± 4%), activated the internal oblique muscles (by 52% ± 13%), and reduced girth (by 25 ± 3 mm) ($P \leq .009$ vs pretreatment for all). **CONCLUSIONS:** In patients with functional gut disorders, abdominal distension is a behavioral response that involves activity of the abdominothoracic wall. This distension can be reduced with EMG-guided, respiratory-targeted biofeedback therapy.

chiefly functional bloating, irritable bowel syndrome, and functional dyspepsia.^{1,2} Although abdominal bloating has been defined as a subjective sensation of increased intra-abdominal pressure, visible abdominal distension is a distinctively recognizable objective observation because it usually develops in discrete episodes.^{1–3} However, the mechanism of abdominal distension, the focus of the current study, is not fully understood.

In an initial study comparing computed tomography (CT) images obtained in the same patients during basal conditions and during an episode of abdominal distension, abdominal distension was shown to be associated with a caudoventral redistribution of abdominal content, featuring diaphragmatic descent and prominent anterior wall protrusion.⁴

Following up on these previous observations, the aim of the current work was to clarify the muscular activity behind the morphologic changes involved in abdominal distention; the role of the thorax in abdominal distention, particularly considering the diaphragmatic descent involved in abdominal distension; and the underlying mechanism of abdominal distention, either reflex or behavioral, and specifically whether it is under volitional control.

To this end, we recruited a relatively large cohort of patients who primarily reported episodes of visible abdominal distension. Paired studies were conducted during episodes of severe distension and in-between episodes (basal conditions) with minimal or no distension; morphovolumetric differences in abdominothoracic CT scans were correlated with the functional differences in electromyography (EMG) activity of the walls. A test was then performed to determine whether patients could learn to control abdominothoracic muscular activity, and thereby correct distension, using an original EMG-guided biofeedback technique.

Keywords: Abdominal Bloating; Intestinal Gas; Diaphragmatic Activity; Respiratory Function.

*Authors share co-first authorship.

Abbreviations used in this paper: CT, computed tomography; EMG, electromyography; IBS, irritable bowel syndrome.

The sensation of abdominal bloating and visible abdominal distension often, but not invariably, coincide with various categories of functional gut disorders,

Materials and Methods

Participants

Nine healthy individuals with no gastrointestinal symptoms (6 women, 3 men; age range, 22–29 years) and 45 patients who predominantly reported episodes of visible abdominal distension (42 women, 3 men; age range, 24–71 years) participated in the study; of note, only patients with manifest fluctuations in their abdominal distension, that is, experiencing episodes of severe distension in contrast with basal periods with mild or no distension, were included in the study. All patients had a functional disorder diagnosis based on Rome III criteria⁵: 15 functional bloating (10.2 ± 1.0 bowel movements per week; 3.6 ± 0.1 score on the Bristol Stool Form Scale) and 30 irritable bowel syndrome (IBS). In the IBS group, 3 patients had alternating bowel habits and 27 constipation-predominant IBS (2.1 ± 0.3 bowel movements per week, 1.2 ± 0.2 Bristol score); of note, no patient qualified as having diarrhea-predominant IBS. Symptom duration was similar in the 3 groups (7 ± 2 years, 6 ± 1 years, and 8 ± 2 years, respectively). The study protocol had been previously approved by the Institutional Review Board of the University Hospital Vall d'Hebron and all subjects gave their written informed consent to participate in the study.

Computed Tomography Scanning

Abdominothoracic CT scans were obtained with a helical multislice CT scanner, exposure 120 kV and 50 mA, using the available dose-reduction options (tube current modulation). Section thickness and image reconstruction depended on the scanner model (2.5-mm thickness, 1.6-mm interval reconstruction with Mx8000; Philips Medical Systems, Best, The Netherlands; 2-mm thickness, 1.5-mm interval reconstruction with Somatom Sensation 16 or Somatom Definition AS; Siemens Medical Solutions, Forchheim, Germany). Images were obtained in the supine position during a single breath-hold. No oral or intravenous contrast medium was administered.

Electromyography of the Abdominothoracic Walls

Activity of the diaphragm, anterior abdominal wall and intercostal muscles was recorded by electromyography (Electromyographic System ASE 16; PRIMA Biomedical & Sport, Mareno di Piave, Italy) at 1024 Hz, amplified 20,000 times, and filtered with a high-pass filter at 30 Hz and a low-pass filter at 500 Hz.⁶ The technique had been previously validated and described in detail.⁷ A brief description is provided here.

Abdominothoracic wall activity was recorded via surface electrodes (Kendall Arbo Kiddy H207PG/F; Tyco Healthcare, Barcelona, Spain): activity of the upper rectus, external oblique, lower rectus, and internal oblique at the right side of the abdomen was recorded via bipolar leads^{8,9}; intercostal muscle activity was recorded via a monopolar electrode at the second intercostal space in the right midclavicular line and a ground electrode over the center of the sternum.^{10,11} The appropriate location of abdominothoracic electrodes was checked by recording EMG responses to a Valsalva maneuver (abdominal wall contraction) and deep inspiration (intercostal muscle contraction). The location of the electrodes was marked on the skin for subsequent recordings (see Experimental Design).

Diaphragmatic EMG activity was measured via intra-esophageal electrodes mounted over a probe. The probe consisted of a polyvinyl tube (5-mm outside diameter, 3-mm inside diameter) with 6-ring electrodes, 5-mm wide at 15-mm intervals. The electrodes were made of a silver mixture (Conductive Pen; Chemotronics, Leeds, UK) and were connected to external plugs by insulated copper wires (200 μ m in diameter) running through the lumen of the tube. After nasal intubation, the electrodes were positioned across the diaphragmatic hiatus under fluoroscopic control. Bipolar EMG activity was recorded from contiguous electrodes. To suppress electrocardiographic interferences, 0.2-second intervals were removed from the diaphragmatic EMG signal around every QRS peak using a specifically developed digital filter. In each study, the bipolar leads that best detected diaphragmatic activity were determined by recording the EMG response to a Valsalva maneuver and were selected for later analysis (see Data Analysis).

EMG recordings were conducted in a quiet isolated room with patients sitting on an ergonomic chair with the trunk erect; the back of the chair was adjusted to the lumbar area to fix the curvature of the spine.^{12,13} After a 3-minute equilibration period, EMG activity was recorded for 6 minutes.

Determination of the Diaphragmatic Position by Ultrasonography

In previous studies, we showed that displacement of the diaphragm can be equally evaluated by monitoring the position of either the right liver dome by CT scan or the right lower margin imaged by ultrasonography.⁷ As described previously, the position of the lower margin of the right liver lobe at the right anterior axillary line was identified by ultrasonography (Acuson Cypress/ Siemens Medical Solutions Inc., Mountain View, CA) using a 2.4-MHz curved array transducer held over the costal wall in a coronal plane with the shaft held in a horizontal position and the head in an axial direction. Participants were instructed to breathe normally, and the mid-point between the end-inspiratory and end-expiratory position of the liver margin, assessed during a period of 6 respiratory cycles, was marked on the overlying skin of the costal wall, and the difference between 2 determinations (baseline vs distension episode, beginning and end of each treatment session) was measured.⁷

Subjective Sensation of Abdominal Distension

The patient's subjective sensation of abdominal distension was measured on a 6-score graphic rating scale graded from 0 (no distension) to 6 (extremely severe distension). Measurements were taken immediately before each test (CT scan or EMG) and before and after each treatment session (biofeedback or control).

Girth Measurement

The method has been previously described and validated in detail.^{9,14–17} Briefly, a nonstretch belt (48-mm wide) with a metric tape measure fixed over it was placed over the umbilicus. The overlapping ends of the belt were adjusted carefully by 2 elastic bands to maintain the belt constantly adapted to the abdominal wall. Girth measurements were taken with the subjects breathing quietly as the mean of inspiratory and expiratory determinations during 3 consecutive respiratory

cycles without manipulation of the belt-tape assembly by the investigator. Girth was measured at the beginning of each EMG recording session and before and after each biofeedback session. In the first recording session (basal conditions or distension episode), the location of the belt was marked on the skin for subsequent measurements. During each treatment session (biofeedback or control), the belt was kept in place and the effect of treatment (before vs after) was measured.

Biofeedback Training

Patients were instructed to come to the hospital during an episode of visible abdominal distension (subjective sensation score of abdominal distension ≥ 2) and EMG of the abdominothoracic walls was recorded. Under visual control of EMG recordings displayed on a monitor, patients were trained to coordinate the activity of their abdominothoracic muscles. Specifically, they were informed that abdominal distension could be related to their abdominothoracic muscular activity and were instructed to voluntarily reduce the activity of intercostal muscles and the diaphragm, while increasing the activity of the anterior abdominal muscles, particularly during expiration. Each session lasted 40 minutes. The technique had been developed through a series of preliminary feasibility studies.¹⁸ In the first 10 patients, abdominothoracic activity (via surface electrodes) and diaphragmatic activity (via intraesophageal electrodes) were recorded, and visual control of the different muscular activity recordings was provided; because learning was not determined by diaphragmatic guidance, the intraesophageal recording probe was no longer used to reduce discomfort. During control sessions, abdominothoracic surface EMG activity was recorded (without intraesophageal probe), but not shown to the patients. Patients were informed that abdominal distension could be related to their abdominothoracic muscular activity and that a confirmatory test would be performed.

Experimental Design

Main studies. Two series of studies were sequentially performed in patients. To elucidate the pathogenetic factors involved in abdominal distension, patients first underwent abdominothoracic CT scans ($n = 39$) and EMG recording sessions ($n = 32$) at both baseline and during abdominal distension (paired studies); patients were instructed to come to the laboratory in 2 different conditions: when they felt minimal or no abdominal distension and during episodes of severe distension. CT scanning, but not EMG recordings, were performed blindly, with the operator unaware of the condition (basal or distension) of the patient.

Of the 32 patients in whom EMG recordings were performed, diaphragmatic activity valid for analysis was obtained in 10 (because of patient intolerance or refusal of intubation on one of the study days). Just before the EMG recording, the position of the diaphragm was determined by ultrasonography in the last 15 patients both during basal conditions and during an episode of abdominal distension (9 also had diaphragmatic EMG recordings in both conditions).

Biofeedback Treatment

After the initial series of studies on the mechanism of distension, 26 patients received 1–3 sessions of biofeedback

training on separate days within a 2-week period; the last 11 patients in this group received a separate control session before biofeedback. The position of the diaphragm was determined by ultrasonography at the beginning and end of each biofeedback (in all but 2 patients; $n = 24$) and control session (in all 11 patients).

Ancillary reproducibility study. EMG recordings were performed on 2 separate days in 9 healthy subjects to test EMG recording reproducibility.

Data Analysis

Analysis of CT images and EMG recordings were performed blindly. Morphovolumetric analysis of CT images was performed using an original software program specifically developed in our laboratory and described in detail previously.^{4,19} To measure the volume of gas within the gut, images were filtered with a user-defined threshold to separate gas from tissues. Total abdominal volume (gas plus liquids and solids) was measured as the body volume between 2 planes: a cranial plane (perpendicular to the vertebral spine and tangential to the diaphragmatic domes) and a caudal plane (defined by bony structures in the pelvis), subtracting the volume of the lungs and the heart below the cranial plane. Body perimeter was measured by averaging the perimeter of the trunk surface measured in 10 axial slices 4 mm apart; at each site, the perimeter was measured as the length of a polyline (series of connected segments) following the body contour. Chest perimeter was measured just below T₁₀ and girth above the iliac crest. Antero-posterior abdominal diameter was measured as the distance (in the antero-posterior axis) between the anterior aspect of the vertebral bodies and the midline surface of the anterior abdominal wall; the mean of the values measured at 6 levels (L₁ to S₁) was calculated in each subject. Position of the diaphragm was measured as the distance (in the vertical axis) between the left diaphragmatic dome and the cranial end plate of the 12th vertebra (T₁₂). Lung height was measured as the distance (in the vertical axis) between the uppermost point and the base of the right lung. The antero-posterior diameter of the thorax at T₄ and T₇ levels was measured as the maximum distance within the interior surface of the ribcage in the antero-posterior axis. Thoracic lateral diameter at T₄ was measured as the maximum distance within the interior surface of the ribcage in the lateral axis. Lung volume was measured using a seed in the range of –500 to –1000 Hounsfield units, and pulmonary cross section as the area in the horizontal planes at the levels of T₄ and T₇. The software developed in this work was built on 2 open-source toolkits: the Insight Segmentation and Registration toolkit²⁰ and the Visualization toolkit, both used for 3D computer graphics, image processing, and visualization.²¹

EMG activity was measured as the root mean square voltage^{9,22} averaged during 1-minute periods. Diaphragmatic activity was measured by averaging the activity of the 2 selected leads (those that best detected the change induced by a Valsalva maneuver; see Materials and Methods).

Statistical Analysis

Sample size was calculated based on previous data in healthy subjects.²³ Anticipating a 5% EMG activity change (SD 10%), 34 patients were required to detect a difference with a

power of 80% and a significance level of 5% (2-sided); acknowledging the uncertainties of our assumptions in patients, and considering potential dropouts or incomplete studies, 45 patients were actually enrolled.

Mean values or grand means for repeated observations, ie, treatment sessions, of the parameters measured (\pm SE) were calculated in each group of subjects. Normality was tested by the Kolmogorov-Smirnov test. Comparisons of parametric, normally distributed data were made by the paired Student *t* test; otherwise, the Wilcoxon signed rank test was used. Correlations of paired data were examined using linear regression analysis.

Results

Morphovolumetric Changes Associated With Abdominal Distension (Computed Tomography Scanning)

During distension episodes, a marked increase was observed in abdominal girth (32 ± 3 mm greater than in basal scans; $P < .001$) and antero-posterior abdominal diameter (Table 1, Figure 1). The subjective sensation of abdominal distension was concordant with the objective findings; sensation at the time of the basal scan was 2.0 ± 0.1 score and 5.0 ± 0.1 score during distension ($P < .001$). Volumetric analysis of the abdominal cavity showed the protrusion of the anterior wall to be associated with a relatively modest but statistically significant increase in intestinal gas volume, as well as total abdominal content (Table 1). The increase in intestinal gas volume during abdominal distension correlated well with the increase in total abdominal content ($R = 0.729$; $P < .001$).

Abdominal distension was associated with a caudal displacement of the diaphragm, measured as a decrease in the distance from the diaphragmatic dome to T₁₂. Diaphragmatic descent involved an increase in the vertical axis of the lung (Table 1, Figure 1). Simultaneously, the costal wall expanded, increasing the pulmonary cross section; the

combined increase in lung height and cross section resulted in a net expansion of lung volume (Table 1, Figure 1). No differences were observed in the parameters measured in patients who underwent the first CT scan during basal conditions ($n = 31$) and those who underwent the first scan during a distension episode ($n = 8$).

Muscular Activity During Abdominal Distension (Electromyographic Recording)

The changes in abdominothoracic muscular activity associated with abdominal distension detected by EMG and reported here were consistent with the morphologic differences detected by abdominal imaging described in the previous section (Figure 1).

During distension episodes, abdominal girth measured by tape measure was 30 ± 2 mm larger than the basal measurements ($P < .001$); thus, the difference was of the same magnitude as that measured by CT. Abdominal distension was associated with reduced EMG activity of the internal and external obliques (consistent with girth increment and protrusion of the anterior wall), increased EMG activity of the diaphragm (consistent with a diaphragmatic descent), and increased EMG activity of intercostal muscles (consistent with costal wall expansion) (Figure 1 and Table 2).

Projection of the lower margin of the right liver lobe over the skin, measured by ultrasonography before each EMG recording session, was 22 ± 4 mm lower during abdominal distension than during basal conditions ($P < .001$), thereby reflecting a diaphragmatic descent. This diaphragmatic descent showed good correlation with that measured by CT during another episode of distension in the same patients ($R = 0.882$; $P = .005$). Simultaneous functional/morphologic evaluation of the diaphragm (by EMG and ultrasonography in the same recording session) showed a good correlation between the increase in EMG activity (contraction) and diaphragmatic descent ($R = 0.863$; $P = .006$ excluding one outlier).

Table 1. Morphovolumetric Analysis of the Abdominothoracic Cavity in Patients During Episodes of Abdominal Distension and During Basal Conditions

	Basal conditions	Abdominal distension	P value
Total abdominal volume, mL ^a	10,917 \pm 559	11,615 \pm 546	<.001
Abdominal gas, mL ^a	106 \pm 16	205 \pm 35	<.001
Abdominal AP diameter, mm ^a	207 \pm 3.7	218 \pm 5	<.001
Distance diaphragm to T ₁₂ , mm ^a	55 \pm 3.1	42 \pm 3.2	<.001
Lung height, mm ^b	165 \pm 4	182 \pm 5	<.001
Thoracic AP diameter at T ₄ , mm ^b	83 \pm 3	93 \pm 3	<.001
Lung cross section at T ₄ , cm ^{2b}	87 \pm 4	101 \pm 5	<.001
Thoracic LD diameter at T ₄ , mm ^b	172 \pm 3	178 \pm 3	<.005
Thoracic AP diameter at T ₇ , mm ^b	143 \pm 3	148 \pm 2	<.005
Lung cross section at T ₇ , cm ^{2-b}	168 \pm 5	184 \pm 5	<.001
Lung volume, mL ^b	2329 \pm 97	2830 \pm 123	<.001

NOTE. Values are mean \pm SE.

AP, antero-posterior; LD, lateral diameter.

^an = 39.

^bn = 38.

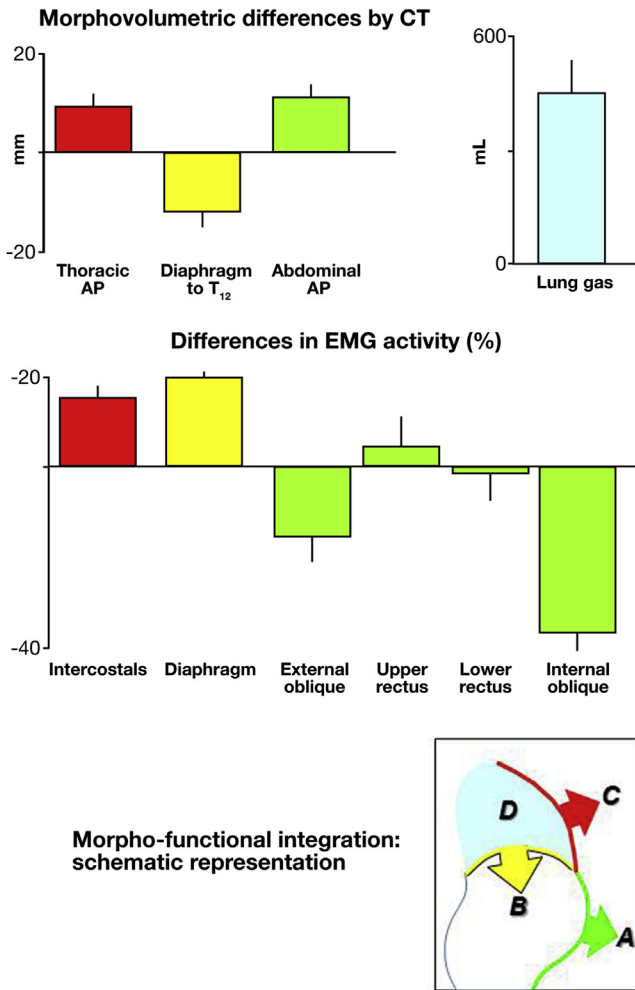


Figure 1. Abdominothoracic differences (mean \pm SE) measured in the same patients during abdominal distension vs basal conditions. (A) Anterior wall protrusion (increased antero-posterior diameter) and relaxation (decreased EMG activity in external and internal obliques). (B) Diaphragmatic descent (referenced to T₁₂) and contraction (increased EMG activity). (C) Costal expansion (increased antero-posterior diameter) and intercostal contraction (increased EMG activity). (D) Increased lung volume.

Subjective sensations of abdominal distension measured at the time of each EMG recording session (4.5 ± 0.8 score during episodes of abdominal distension and 1.6 ± 0.6 score during basal conditions; $P < .001$) were similar to those measured at the time of CT under analogous conditions.

No differences were observed in the parameters measured in patients that underwent the first EMG recording during basal conditions ($n = 18$) and in those who underwent the first EMG recording during a distension episode ($n = 8$).

Reproducibility Study

EMG activity measured in healthy subjects on 2 different days showed good overall reproducibility (Figure 2).

Table 2. Electromyographic Activity of Abdominothoracic Muscles in Patients During Episodes of Abdominal Distension and During Basal Conditions

	Basal conditions	Abdominal distension	P value
Intercostals, μV^a	12.4 ± 0.6	14.2 ± 0.5	$<.001$
Diaphragm, μV^b	7.8 ± 0.3	9.4 ± 0.6	$.001$
External oblique, μV^a	6.5 ± 0.5	5.3 ± 0.4	$.011$
Upper rectus, μV^a	4.4 ± 0.4	4.4 ± 0.5	$.586$
Lower rectus, μV^a	5.7 ± 0.5	5.4 ± 0.5	$.303$
Internal oblique, μV^a	9.9 ± 0.8	5.7 ± 0.4	$<.001$

NOTE. Values are mean \pm SE.

^a $n = 32$.

^b $n = 10$.

Responses to Biofeedback Treatment

Under the visual guidance provided by the EMG signal, all patients were able to effectively control muscular activity. After the initial biofeedback sessions, some patients responded and no longer developed abdominal distension (a subjective sensation of distension score ≥ 2 was required for performing biofeedback sessions); 3 patients received only 1 session, 14 patients 2 sessions, and 9 patients 3 sessions. As illustrated by Figure 3, EMG activity of the intercostals and diaphragm significantly decreased after biofeedback, while activity of the abdominal muscles, particularly the internal oblique, significantly increased. These changes in muscular activity were associated with a significant ascent of the diaphragm (12 ± 2 mm ascent of liver margin by ultrasonography; $P < .001$; $n = 24$), decrease in girth (by 25 ± 3 mm; $P < .001$) and improvement in the subjective sensation of abdominal distension (from 4.3 ± 1.0 score to 2.6 ± 0.3 score; $43\% \pm 5\%$ reduction; $P < .001$). After the control session, no changes were detected in muscular activity (Figure 3),

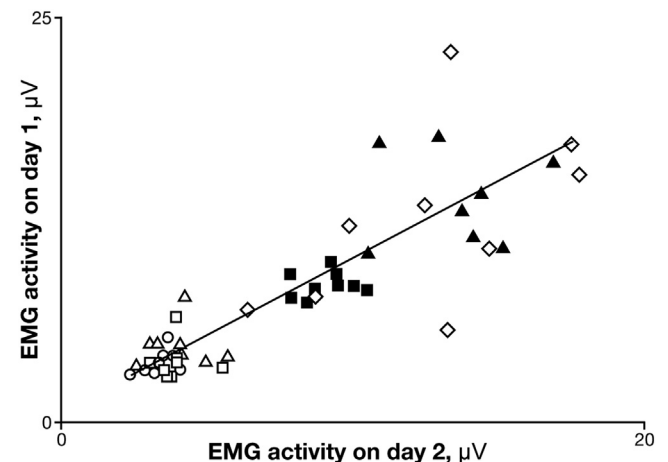


Figure 2. Reproducibility studies. EMG activity of intercostals (\blacktriangle), diaphragm (\blacksquare), external oblique (\triangle), upper rectus (\circ), lower rectus (\square), and internal oblique (\diamond). Data are individual values in healthy subjects ($n = 9$) measured on 2 separate days.

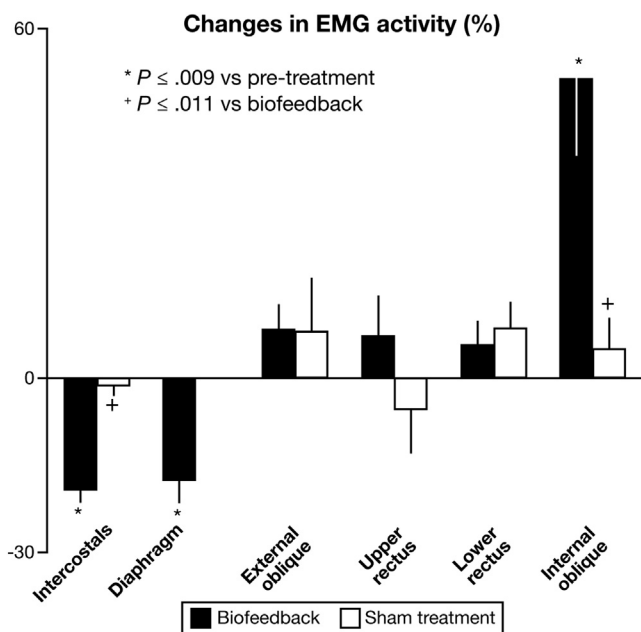


Figure 3. Effect of biofeedback on abdominothoracic muscular activity. Changes in EMG activity (mean ± SE) during biofeedback and control sessions. Biofeedback significantly reduced intercostal and diaphragmatic activity, and increased anterior abdominal activity, particularly the internal oblique (n = 26, except for diaphragm, n = 10); no changes were detected during control sessions (n = 11, no diaphragmatic EMG).

diaphragmatic position (1.0 ± 0.4 mm change; P < .001 vs biofeedback), girth (-0.2 ± 0.5 mm change; P = .027 vs biofeedback), and the subjective sensation of abdominal distension (from 4.6 ± 0.2 to 4.6 ± 0.3; 1% ± 5 % change; P = .004 vs biofeedback). The response to biofeedback did not differ in patients with and without diaphragmatic recording, and in patients who received a prior control session compared with those who did not (Table 3).

Influence of Clinical Presentation and Age

No consistent differences in the parameters measured, specifically morphologic (CT) and functional (EMG) changes associated with distension and in response to treatment,

were detected when comparing patients with functional bloating vs those with constipation-predominant IBS and when comparing the younger half of patients vs the older half.

Discussion

Our study correlating morphologic and muscular activity measurements under real-life clinical conditions suggests that abdominal distention is a behavioral response of the abdominothoracic walls that is correctable by behavioral techniques.

Physiologically, the walls of the abdomen actively adapt to its content by tight control of their muscular tone, a phenomenon termed *abdominal accommodation*.²⁴ In healthy subjects, an increase in intra-abdominal content induces relaxation and ascent of the diaphragm, which permits cephalic expansion of the abdominal cavity with minor protrusion of the anterior wall.^{23,24} The diaphragmatic ascent produces a decrease in lung height, which is compensated by intercostal muscle contraction, elevation of the costal wall, and an increase in pulmonary cross section, to prevent a reduction in lung volume; hence, the accommodation of intra-abdominal content involves a well-coordinated response of the abdominothoracic walls as a whole.⁷ The results obtained in acute animal experiments support the existence of viscerosomatic reflexes that modulate the abdominal wall contraction²⁵ and, conceivably, this type of reflex governs abdominal accommodation.

In the current study and a previous study,⁴ discrete episodes of real-life abdominal distension in patients with functional bloating were associated with a significant, but relatively modest, increase in net intra-abdominal volume. In healthy subjects, comparable volume loads, modeled by colonic gas infusion, were accommodated by a normal diaphragmatic relaxation/ascent with minimal protrusion of the anterior abdominal wall.^{7,24} However, in patients reporting episodic abdominal distension, during basal conditions, that is, distension-free intervals, the same intra-colonic gas loads triggered an aberrant somatic response leading to abdominal distension,^{3,9} specifically, a paradoxical contraction of the diaphragm, that pushed abdominal contents downward, and relaxation of the anterior abdominal wall, resulting in redistribution of the contents with

Table 3. Abdominothoracic Muscular Activity in Patients During Biofeedback and Control Sessions

	Biofeedback (n = 26)			Control (n = 11)		
	Before	After	P value	Before	After	P value
Intercostals, μV	13.4 ± 0.7	10.8 ± 0.6	<.001	13.4 ± 1.4	13.7 ± 1.4	.528
Diaphragm, μV ^a	10.6 ± 1.1	8.5 ± 0.6	.009	—	—	—
External oblique, μV	4.9 ± 0.4	5.2 ± 0.4	.305	5.0 ± 0.5	5.4 ± 0.6	.260
Upper rectus, μV	4.4 ± 0.4	4.5 ± 0.4	.817	6.3 ± 0.7	7.0 ± 0.6	.166
Lower rectus, μV	5.1 ± 0.4	5.2 ± 0.4	.338	6.7 ± 0.6	7.0 ± 0.5	.165
Internal oblique, μV	5.7 ± 0.5	8.4 ± 0.8	<.001	7.2 ± 0.6	7.7 ± 1.1	.338

NOTE. Values are mean ± SE.

^aDiaphragmatic activity was recorded in 10 patients during biofeedback and in none during control sessions.

ventral expansion of the abdominal cavity. This experimental condition mimicked the findings of the current study in patients during spontaneous episodes of abnormal distension. Both increased intra-abdominal volume and the abnormal somatic response contribute to visible abdominal distension. The relative contribution of these 2 sources is at variance; while the somatic response seems important in functional patients, those with intestinal neuropathy, a rare condition, exhibit massive intestinal retention that, even with a normal abdominothoracic accommodation response, results in prominent abdominal distension.²⁶

An original contribution of the current study relates to the paradoxical activity of the chest during abdominal distension. In contrast to healthy subjects, in whom the costal wall follows the diaphragm to compensate lung function, the diaphragmatic descent during episodes of abdominal distension in patients was associated with elevation of the costal wall and chest hyperinflation. The fact that other individuals with increased lung volumes, such as patients with chronic obstructive pulmonary disease or even healthy subjects during exercise, do not report significant abdominal distension suggests that the mechanism of abdominal distension may involve both thoracic and abdominal contributions. Although not specifically evaluated in this study, we speculate that the breathlessness reported by some patients during episodes of abdominal distension might be related to hyperinflation of the chest rather than thoracic compression by a distended abdomen.

The effect of biofeedback provides persuasive evidence that the aberrant somatic activity associated with abdominal distension is under voluntary control. Patients with abdominal distension were trained to control abdominothoracic activity and thereby correct distension.¹⁸ These data also suggest that abnormal abdominothoracic activity associated with distension may represent a conditioned response. Other frequent somatic manifestations of functional gut disorders, such as rumination and aerophagia, may have a similar conditioning-related origin.^{27,28} However, what determines the acquisition of the conditioned response and what the conditioning stimuli are, that is, why patients learned to produce it in the first place and in response to what, remains unknown. Previous studies support the concept that patients with functional gut disorders and bloating have increased intestinal sensitivity and perceive stimuli that are normally well tolerated.^{1,2} Therefore, we speculate that, in such patients, even minor increases in intestinal content may induce a bloating sensation and, in conditioned patients, this sensation triggers the abnormal abdominothoracic response that produces abdominal distension, which can further reinforce the bloating sensation.

Of note, the intra-abdominal volume increment required to experimentally induce distension in patients during distension-free intervals^{3,9,17} was generally larger than the volume increment observed in the current and previous studies during real-life distension,⁴ suggesting that, in real life, other facilitatory or triggering factors (such as stress and fatigue) may also be involved.

We acknowledge that we did not include patients with diarrhea-predominant IBS, in whom abdominal distension may have a different mechanism.²⁹ In addition, we included only patients with fluctuating abdominal distension, in whom CT and EMG clearly revealed differences when they manifested visible abdominal distension compared with basal conditions, as well as the effect of conductal treatment. Previous studies have shown that, in the majority of patients, abdominal distension presents diurnal variations and that distension episodes are associated with any type of oral intake (less frequently with certain types of food), stress, or anxiety.^{29–31}

Based on our data, the indication of specific testing in these patients (by CT or EMG) may be restricted to rare cases in which intestinal dysmotility and luminal pooling are suspected.²⁶ The initial line of treatment in patients with abdominal distension would target potential triggers, such as increased intestinal load, either in relation to diet or constipation.^{30,32,33} Because perception of symptoms is a key factor in our pathophysiologic model and is frequently associated with distension,³⁰ treatment of abdominal symptoms by conventional IBS therapy would seem reasonable. If identifiable, other triggers, such as emotional factors or anxiety, could also be targeted. In the current proof-of-concept study, we applied a complex biofeedback technique that still needs to be validated in a proper randomized controlled trial. The indication of this treatment is restricted by its complexity and cost. Conceivably, a simpler and cheaper conductal technique could be developed and, if proven really effective, might become the standard second-line treatment of abdominal distension for patients unresponsive to standard dietary or pharmacologic modalities.

References

1. Azpiroz F, Malagelada J-R. Abdominal bloating. *Gastroenterology* 2005;129:1060–1078.
2. Agrawal A, Whorwell PJ. Review article: abdominal bloating and distension in functional gastrointestinal disorders—epidemiology and exploration of possible mechanisms. *Aliment Pharmacol Ther* 2008;27:2–10.
3. Villoria A, Azpiroz F, Burri E, et al. Abdomino-phrenic dyssynergia in patients with abdominal bloating and distension. *Am J Gastroenterol* 2011;106:815–819.
4. Accarino A, Perez F, Azpiroz F, et al. Abdominal distension results from caudo-ventral redistribution of contents. *Gastroenterology* 2009;136:1544–1551.
5. Thompson WG, Longstreth G, Drossman DA, et al. Functional bowel disorders and Functional abdominal pain. In: Drossman DA, Corazziari E, Talley NJ, et al., eds. *The functional gastrointestinal disorders*. 2nd ed. McLean, VA: Degnon Associates, 2000:351–432.
6. Merletti R, Hermens HJ. Detection and conditioning of the surface EMG signal. In: Merletti R, Parker P, eds. *Electromyography, physiology, engineering, and noninvasive applications*. Hoboken, NJ: John Wiley & Sons, 2004:107–131.
7. Burri E, Cisternas D, Villoria A, et al. Accommodation of the abdomen to its content: integrated

- abdomino-thoracic response. *Neurogastroenterol Mot* 2012;24:312–e162.
8. Ng JK, Kippers V, Richardson CA. Muscle fibre orientation of abdominal muscles and suggested surface EMG electrode positions. *Electromyogr Clin Neurophysiol* 1998;38:51–58.
 9. Tremolaterra F, Villoria A, Azpiroz F, et al. Impaired viscerosomatic reflexes and abdominal wall dystonia associated with bloating. *Gastroenterology* 2006;130:1062–1068.
 10. Demoule A, Verin E, Locher C, et al. Validation of surface recordings of the diaphragm response to transcranial magnetic stimulation in humans. *J Appl Physiol* 2003;94:453–461.
 11. Maarsingh EJ, van Eykern LA, Sprikkelman AB, et al. Respiratory muscle activity measured with a noninvasive EMG technique: technical aspects and reproducibility. *J Appl Physiol* 2000;88:1955–1961.
 12. Caldarella M, Azpiroz F, Malagelada J-R. Antro-fundic dysfunctions in functional dyspepsia. *Gastroenterology* 2003;124:1220–1229.
 13. Distrutti E, Azpiroz F, Soldevilla A, et al. Gastric wall tension determines perception of gastric distension. *Gastroenterology* 1999;116:1035–1042.
 14. Passos MC, Tremolaterra F, Serra J, et al. Impaired reflex control of intestinal gas transit in patients with abdominal bloating. *Gut* 2005;54:344–348.
 15. Salvioli B, Serra J, Azpiroz F, et al. Origin of gas retention and symptoms in patients with bloating. *Gastroenterology* 2005;128:574–579.
 16. Caldarella MP, Serra J, Azpiroz F, et al. Prokinetic effects in patients with intestinal gas retention. *Gastroenterology* 2002;122:1748–1755.
 17. Burri E, Barba E, Huaman JW, et al. Mechanisms of postprandial abdominal bloating and distension in functional dyspepsia. *Gut* 2014;63:395–400.
 18. Burri E, Azpiroz F, Hernandez C, et al. Biofeedback treatment of abdominal distention: a proof-of-concept (Abstract). *Gut* 2010;59:A137.
 19. Perez F, Accarino A, Azpiroz F, et al. Gas distribution within the human gut: effect of meals. *Am J Gastroenterol* 2007;102:842–849.
 20. Ibañez L, Schroeder W, Ng L, et al. *The ITK software guide*. Clifton Park, NY: Kitware Inc, 2003.
 21. Schroeder W, Martin K, Lorensen B. *The visualization toolkit, an object oriented approach to 3D graphics*. 3rd ed. Clifton Park, NY: Kitware Inc, 2002.
 22. Beck J, Sinderby C, Lindstrom L, et al. Effects of lung volume on diaphragm EMG signal strength during voluntary contractions. *J Appl Physiol* 1998;85:1123–1134.
 23. Burri E, Cisternas D, Villoria A, et al. Abdominal accommodation induced by meal ingestion: differential responses to gastric and colonic volume loads. *Neurogastroenterol Mot* 2013;25:339–e253.
 24. Villoria A, Azpiroz F, Soldevilla A, et al. Abdominal accommodation: a coordinated adaptation of the abdominal walls to its content. *Am J Gastroenterol* 2008;103:2807–2815.
 25. Martinez V, Thakur S, Mogil J. Differential effects of chemical and mechanical colonic irritation on behavioral pain response to intraperitoneal acetic acid in mice. *Pain* 1999;81:179–186.
 26. Barba E, Quiroga S, Accarino A, et al. Mechanisms of abdominal distension in severe intestinal dysmotility: abdomino-thoracic response to gut retention. *Neurogastroenterol Motil* 2013;25:e389–e394.
 27. Barba E, Burri E, Accarino A, et al. Biofeedback-guided control of abdominothoracic muscular activity reduces regurgitation episodes in patients with rumination. *Clin Gastroenterol Hepatol* 2015;13:100–106.e1.
 28. Bredenoord AJ, Smout AJ. Physiologic and pathologic belching. *Clin Gastroenterol Hepatol* 2007;5:772–775.
 29. Houghton LA, Lea R, Agrawal A, et al. Relationship of abdominal bloating to distension in irritable bowel syndrome and effect of bowel habit. *Gastroenterology* 2006;131:1003–1010.
 30. Chang L, Lee OY, Naliboff B, et al. Sensation of bloating and visible abdominal distension in patients with irritable bowel syndrome. *Am J Gastroenterol* 2001;96:3341–3347.
 31. Sullivan SN. A prospective study of unexplained visible abdominal bloating. *N Z Med J* 1994;1:428–430.
 32. Manichanh C, Eck A, Varela E, et al. Anal gas evacuation and colonic microbiota in patients with flatulence: effect of diet. *Gut* 2014;63:401–408.
 33. Azpiroz F, Hernandez C, Guyonnet D, et al. Effect of a low-flatulogenic diet in patients with flatulence and functional digestive symptoms. *Neurogastroenterol Motil* 2014;26:779–785.

Received July 3, 2014. Accepted December 9, 2014.

Reprint requests

Address requests for reprints to: Fernando Azpiroz, MD, Digestive System Research Unit, Hospital General Vall d'Hebron, 08035 Barcelona, Spain. e-mail: azpiroz.fernando@gmail.com; fax: (34) 93 489 44 56.

Acknowledgments

The authors thank Anna Aparici and Purificación Rodríguez for technical support and Gloria Santaliestra for secretarial assistance.

Daniel Cisternas's current affiliation is Departamento de Gastroenterología, Facultad de Medicina, Pontificia Universidad Católica de Chile, Santiago, Chile.

Conflicts of interest

The authors disclose no conflicts.

Funding

Supported in part by the Spanish Ministry of Economy and Competitiveness (Dirección General de Investigación Científica y Técnica, SAF 2013-43677-R); Ciberehd is funded by the Instituto de Salud Carlos III. Dr Burri was supported by grants from the Freiwillige Akademische Gesellschaft (Basel, Switzerland) and the Gottfried und Julia Bangerter-Rhyner-Stiftung (Bern, Switzerland). Writing assistance: English editing of the manuscript by Christine O'Hara and funded by SAF 2013-43677-R.