

Case Report

Primary Fibrosarcoma of the Testicle with Puzzling Post-surgery Presentation: Mimicking Recurrence

Sami Mahjoub Taha¹, Yassin Mohammed Osman², Dafalla Abuldris³, Mohammed El Imam Mohammed Ahmed¹, Mohamed Daffalla Awadalla⁴, and Nadia M. Mokhtar⁵

¹Department of Urology, Faculty of Medicine, University of Gezira, Sudan

²Department of Urology, Gezira Hospital for Renal Disease and Surgery, Sudan

³Department of Oncology, National Cancer Institute, University of Gezira, Sudan

⁴Faculty of Medicine, University of Gezira, Sudan

⁵Department of Pathology, National Cancer Institute, Cairo University, Egypt

Abstract

Sarcomas of the testis are extremely rare tumors, their incidence being difficult to assess accurately. The authors report a case of a 21-year-old male, presented with painless scrotal swelling that increased in size insidiously within three months. The examination revealed a 10 cm right testicular swelling—hard, not tender and oval in shape. Testicular ultrasound revealed right heterogenous testicular mass. Tumor markers (Human chorionic gonadotrophin (HCG) and alpha fetoprotein) were normal. CT chest and abdomen were normal. Radical orchidectomy was done through an inguinal approach. Histopathology showed testicular fibrosarcoma with spindle cells. After one month, the patient noticed reappearance of a swelling in the right hemiscrotum. Right inguinal exploration with massive resection of the recurrent scrotal mass was done. Histopathology revealed inflammatory process dominated by stitch granuloma. In conclusion, the recurrence rate of testicular sarcomas is high following radical orchidectomy, but still there was a place of non-malignant mass that looks like recurrence; it might occur like nonspecific inflammatory mass and stitch granuloma.

Keywords: testicular tumor, testicular fibrosarcoma, spindle cells, recurrent testicular sarcoma

1. Introduction

Testicular cancer represents about 1.5% of male neoplasms and 5% genitourinary tumors. Most testicular tumors are diagnosed in 20th and 30th years of life. The histological type varies, although there is a clear predominance (90–95%) of germ cell

Corresponding Author: Sami Mahjoub Taha; email: samimahj@gmail.com

Received 26 March 2018

Accepted 15 June 2018

Published 28 June 2018

Production and Hosting by Knowledge E

© Sami Mahjoub Taha et al. This article is distributed under the terms of the Creative Commons

Attribution License, which permits unrestricted use and redistribution provided that the original author and source are credited.

Editor-in-Chief:
Prof. Mohammad A. M. Ibnouf

 OPEN ACCESS

tumors [1]. Testicular sarcomas are extremely rare tumors, their incidence being difficult to assess accurately. Although uncommon, these tumors have been recorded as the main urogenital site of sarcomas in the elderly, whereas primary testicular sarcoma is rare neoplasm, in which the diagnosis is made after exclusion of the more common type of sarcomas like paratesticular sarcomas [2, 3]. Furthermore, the rarity of primary fibrosarcoma in the testis further justifies the following report.

2. Case Report

A 21-year-old male, presented to the urology department with painless right testicular swelling that increased in size insidiously within three months. No fever and no urinary symptoms were reported. Left scrotum was free. On examination, about 10 cm right testicular swelling was found—hard, not tender and oval in shape. Scrotal skin and another testis were normal. Testicular ultrasound showed right heterogenous testicular mass. Tumor markers like HCG and alpha fetoprotein were normal. CT chest and abdomen were normal. Radical orchidectomy was done through inguinal approach, and the spermatic cord was chopped at the internal inguinal ring.

Histopathology revealed fibrosarcoma of the testis, the microscopic appearance was malignant hypercellular sarcomatous tumor composed of long fascicle of fusiform spindle-shaped cells arranged in herringbone pattern. Tumors have spindle-shaped nuclei and the tumor cells are separated by interwoven collagen fibers arranged in parallel fashion. There was mild to moderate anaplasia with scattered mitotic activity, Figures 1–6, evident by immunohistochemistry (SMA, S100, Desmin were negative and Ki67 was positive in 10% denoting low proliferation index). After one month, he noticed swelling in the same side of previous surgery, which was painless and increased in size. Testicular ultrasound showed right testicular tumor and right inguinal lymph node enlargement.

Right inguinal exploration with massive resection of the recurrent scrotal mass was done. Histopathology revealed inflammatory process dominated by stitch granuloma.

3. Discussion

Sarcomas of the testis are extremely rare. When you review the literature of published series of sarcomas they were distributed as follows: leiomyosarcoma (32%), rhabdomyosarcoma (RMS, 24%) and liposarcoma (20%) are the commonest subtypes [4, 5].

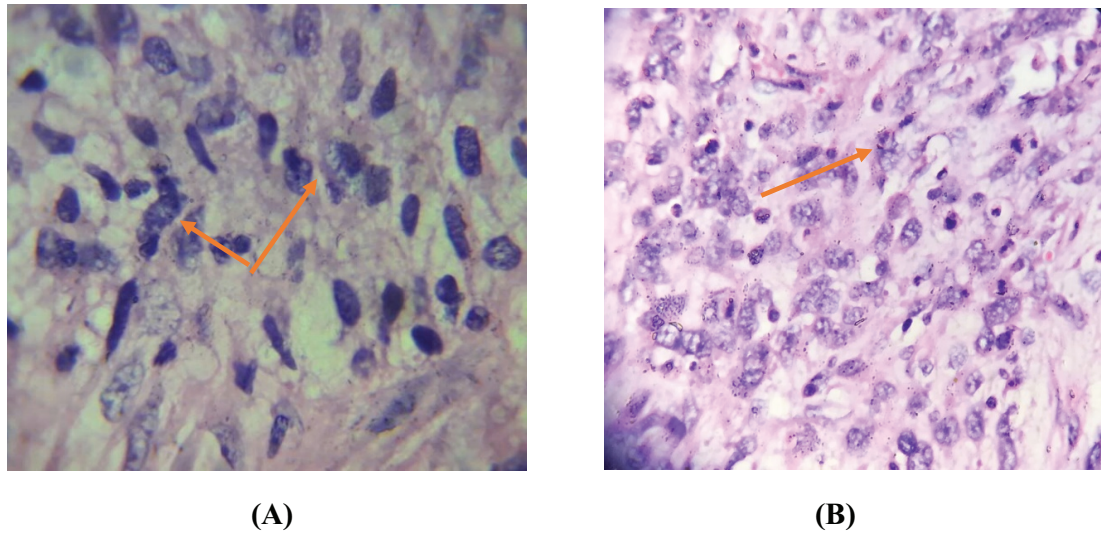


Figure 1: Malignant hypercellular sarcomatous tumor formed with long fascicle of fusiform spindle-shaped cells arranged in herringbone pattern—spindle-shaped nuclei with scanty cytoplasm and indistinct borders (orange arrows)—Hematoxylin-eosin stain; magnification x 40 (A), magnification x 100 (B). The copyright of the image is kept for the authors.

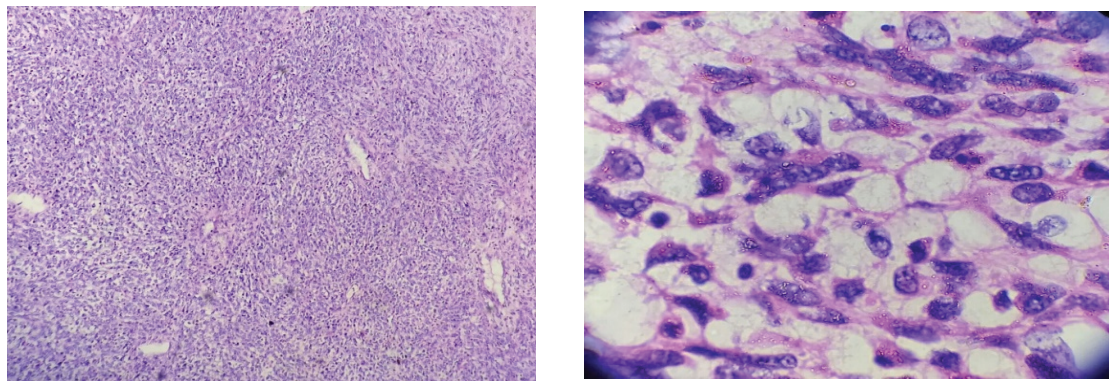


Figure 2: Collagen fibers arranged in parallel fashion : Hematoxylin-eosin stain; magnification x 10 (left) and x 40 (right).

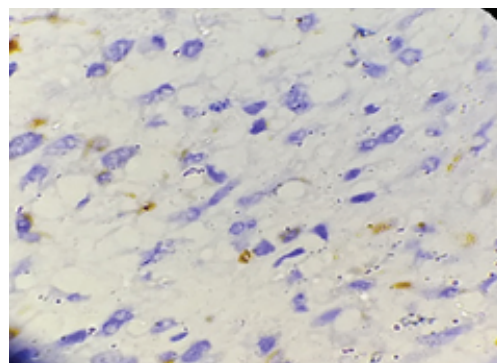


Figure 3: Ki67 immunohistochemistry is positive—in about 10% of tumor cells (magnification x 40).

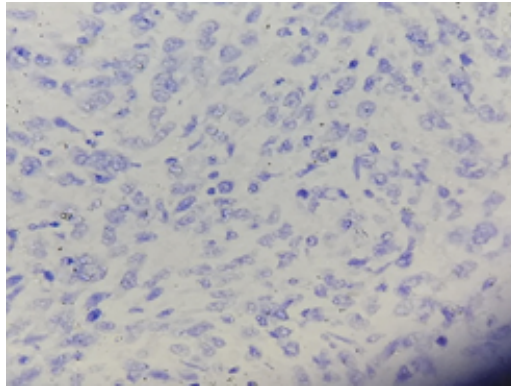


Figure 4: S100 is negative—immunochemistry (magnification x 40).

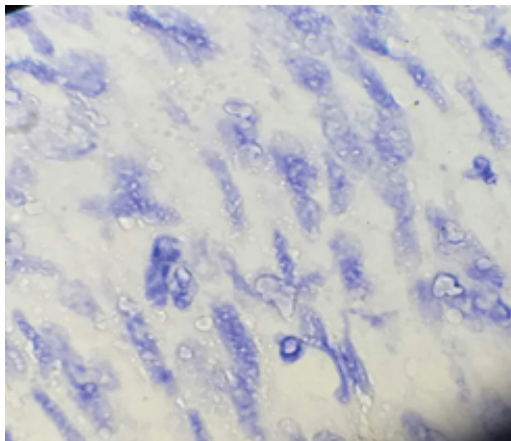


Figure 5: Desmin is negative—immunochemistry (magnification x 40).

Gowing and Morgan studied all mesenchymal tumors arising in testicular tissues, and their relative rarity is apparent; the study consists of 22 sarcomas enrolled in a survey of around 1000 patients with testicular neoplasm. The majority of the sarcomas in this study were mesenchymal, that is, fibrosarcoma, liposarcoma, myosarcoma, rhabdomyosarcoma and leiomyosarcoma, or combinations [6]. The sarcomas may present with a unilateral, painless scrotal swelling with short duration as seen in this case.

The commonest way of metastasis is via lymphatics to internal iliac and para-aortic lymph nodes. Distant metastasis to liver, lungs and bone by hematogenous spread accounts for 20% of patients in initial presentation [14]. Management of testicular fibrosarcoma has shifted with multispecialty approaches that improves the survival chances up to 80% by incorporating chemotherapeutic medications, radiotherapy or surgical intervention [14, 15].

In the current reported case, the radiological staging was NoMo, and accordingly the oncologist preferred follow-up after radical orchidectomy. Inguinal approach orchidectomy with ligation of spermatic cord at the internal ring is the standard surgical intervention as seen in the case. The site of tumor origin (testicular-paratesticular), lymph node involvement, distant metastasis, presence or absence of residual disease after surgical resection will help in staging of testicular and the plan of management of fibrosarcoma of the testis.

The reported local relapse rate in the scrotum and groin after orchidectomy is 25–37% [8, 10, 11]. Adjuvant locoregional (ipsilateral pelvic and groin nodes and scrotum) radiation and/or surgery apparently reduces rate of recurrence [7, 9, 11, 12]. Fagundes et al. [10] reported no local recurrence in patients receiving adjuvant radiation, compared with 37% local recurrence in those managed with the removal of the testis alone.

Catton et al. [13] mentioned 14% local recurrence in patients who underwent wide local excision and/or radiotherapy after original excision of the testicular or paratesticular sarcomas. They also suggested that orchidectomy alone is inadequate for testicular sarcomas and recommended adjuvant wide hemiscrotum excision, which may include inguinal lymph nodes for those managed with orchidectomy or local excision. They found that there was microscopic disease present in 27%, following wide excision in patients with apparently completely excised tumors.

In the current case, there was an appearance of swelling in the right testicle within one month following radical orchidectomy, which made us to think of local recurrence, and therefore the decision of re-exploration was made with wide local excision of the swelling and the hemiscrotum. The patient was followed-up for six months and there was no local recurrence or distant metastasis.

The role of retroperitoneal lymph node dissection (RPLND) in testicular sarcomas remains controversial [5, 10, 16, 17]. Catton et al. [10] recommended RPLND in their earlier series of 21 patients, but in their subsequent report they noted that the patients with a high risk of nodal metastasis are also at highest risk of concurrent or subsequent systemic disease; accordingly, they felt that those patients would benefit from systemic rather than regional treatment [13]. Others suggest that RPLND should be limited to patients with suspicion of LN metastasis in the image [19]. In this case, we advocate that the last suggestions is to do RPLND when there is radiological suspicion of LN residual after adjuvant chemotherapy.

Adjuvant chemotherapy in testicular sarcomas is not fully established. In pediatrics, with testicular sarcomas—especially rhabdomyosarcoma (RMS)—adjuvant chemotherapy had good outcome on the overall survival [20, 21]. Its use in adult testicular sarcomas has not been yet specifically addressed in a controlled study [22].

The use of post-intervention chemotherapy for adult high-grade testicular fibrosarcoma is controversial. A meta-analysis of randomized trials of testicular sarcomas at different centers showed that doxorubicin-based adjuvant chemotherapy significantly improved the time to local and distant failure [23].

In conclusion, testicular fibrosarcoma is extremely rare testicular tumor. Although recurrence rate is high following radical orchidectomy, but there was still a place of non-malignant mass that looks like recurrence that might occur like a nonspecific inflammatory mass and stich granuloma.

References

- [1] Albers, P., Albrecht, W., Algaba, F., et al. (2014). Guidelines on Testicular Cancer. European Association of Urology Guidelines on Testicular Cancer: Update.
- [2] Purdue, M. P., Devesa, S. S., Sigurdson, A. J., et al. (2005). International patterns and trends in testis cancer incidence. *International Journal of Cancer*, vol. 115, pp. 822-827.
- [3] Lioe, T. F. and Biggart, J. D. (1993). Tumors of the spermatic cord and paratesticular tissue: A clinicopathological study. *British Journal of Urology*, vol. 71, pp. 600-606.
- [4] Soosay, G. N., Parkinson, M. C., Paradinas, J., et al. (1996). Paratesticular sarcomas revisited: A review of cases in the British Testicular Tumour Panel and Registry. *British Journal of Urology*, vol. 77, pp. 143-146.
- [5] Fagundes, M. A., Zietman, A. L., Althausen, A. F., et al. (1996). The management of spermatic cord sarcoma. *Cancer*, vol. 77, pp. 1873-1876.
- [6] Dowling, K. J. and Lieb, H. E. (September 1, 1985). Fibrosarcoma of epididymis. *Urology*, vol. 26, no. 3, pp. 307-308.
- [7] Russo, P., Brady, M. S., Conlon, K., et al. (1992). Adult urological sarcoma. *Journal of Urology*, vol. 147, pp. 1032-1036.
- [8] Blitzer, P. H., Dosoretz, D. E., Proppe, K. H., et al. (1981). Treatment of malignant tumors of the spermatic cord: A study of 10 cases and a review of literature. *Journal of Urology*, vol. 126, pp. 611-614.
- [9] Rao, C. R., Srinivasulu, M., Naresh, K. N., et al. (1994). Adult paratesticular sarcomas: A report of eight cases. *Journal of Surgical Oncology*, vol. 56, pp. 89-93.

- [10] Catton, C. N., Cummings, V., Fornasier, B., et al. (1991). Adult paratesticular sarcomas: A review of 21 cases. *Journal of Urology*, vol. 146, pp. 342-345.
- [11] Fagundes, M. A., Zietman, A. L., Althausen, A. F., et al. (1996). The management of spermatic cord sarcoma. *Cancer*, vol. 77, pp. 1873-1876.
- [12] Rabbani, F., Wright, J., and McLoughlin, M. (1997). Sarcomas of the spermatic cord: Significance of wide local excision. *The Canadian Journal of Urology*, vol. 4, pp. 366-368.
- [13] Catton, C. N., Jewett, M., O'Sullivan, I., et al. (1999). Paratesticular sarcoma: Failure pattern after definitive local therapy. *Journal of Urology*, vol. 161, pp. 1844-1847.
- [14] Resim, S., Okur, N., Bakar's, S., et al. (2009). Paratesticular embryonal rhabdomyosarcoma: Report of a case. *Iranian Journal of Pediatrics*, vol. 19, no. 4, pp. 430-434.
- [15] Kumar, R., Bharti, S., Khosla, D., et al. (Jan 1, 2012). Long-term survival in paratesticular rhabdomyosarcoma. *Clinical Cancer Investigation Journal*, vol. 1, no. 1, p. 31.
- [16] Merimsky, O., Terrier, P., Bonvalot, S., et al. (1999). Spermatic cord sarcoma in adults. *Acta Oncologica*, vol. 38, pp. 635-638.
- [17] Hermans, B. P., Foster, R. S., Bihrlé, R., et al. (1998). Is retroperitoneal lymph node dissection necessary for adult paratesticular rhabdomyosarcoma? *Journal of Urology*, vol. 160, pp. 2074-2077.
- [18] Donohue, J. P. (1991). Editorial comment. *Journal of Urology*, vol. 146, p. 345.
- [19] Goldfarb, B., Khoury, A. E., Greenberg, M. L., et al. (1994). The role of retroperitoneal lymphadenectomy in localized paratesticular rhabdomyosarcoma. *Journal of Urology*, vol. 152, pp. 785-787.
- [20] Raney, R. B., Jr., Tefft, M., Lawrence, W., Jr., et al. (1987). Paratesticular sarcoma in childhood and adolescence: A report from the Intergroup Rhabdomyosarcoma Studies I and II, 1973-83. *Cancer*, vol. 60, pp. 2337-2343.
- [21] De Vries, J. D. (1997). Paratesticular rhabdomyosarcoma. *World Journal of Urology*, vol. 13, pp. 219-225.
- [22] Anonymous. (1997). Adjuvant chemotherapy for localized resectable soft-tissue sarcoma of adults: Meta-analysis of individual data. *Sarcoma Meta-analysis Collaboration. Lancet*, vol. 350, pp. 1647-1654.
- [23] Khoubehi, B., Mishra, V., Ali, M., et al. (Nov 1, 2002). Adult paratesticular tumours. *BJU International*, vol. 90, no. 7, pp. 707-715.
- [24] Fernando, J., Azcarretazabal, T., Torio, B. et al. (1999). Primary pure intratesticular fibrosarcoma. *Pathology International*, vol. 49, pp. 185-189.

- [25] Zukerberg, L. R. and Young, R. H. (1990). Primary testicular fibrosarcoma: A report of two cases. *Human Pathology*, vol. 21, pp. 932-935.