



Research Article

Prevalence of Endo-Parasites of Common Tree Frog *Rana Saharica* from Misurata, Libya

Elmajdoub O. Layla¹ , Shabash H. Elhamali², Omar A. Mosaab¹ ,
and Aborawis M. Afaf¹

¹Department of Zoology, Misurata University, Misurata, Libya

²Department of Parasitology, Faculty of Veterinary Medicine, South Valley University, Qena 83523, Egypt

Abstract

The current study was conducted to detect the prevalence of parasitic infection among (62) common tree frogs (*Rana Saharica*), of different ages, with weights ranged between 1 and 25g. **Results:** The results revealed that 61 (98%) out of 62 examined common frogs were infected with endo-parasites. The prevalence of infection with protozoal was (86.4%) and (80%) for helminthes, while the mixed infection with both was 65%.

Furthermore, the nematodes (75.5%) were the most prevalent helminthes, also helminthes mixed infection in a single host was reported. *Rhabditis* spp., *Ophiotaenia ranae*, *Glythelmins quieta*, *Corynosoma* spp. were Recovered from the digestive tract of common tree frogs, whereas, the *Oplina ranarum* and *Copromonas subitillis* the most prevalent protozoan species were detected from the common frogs.

From the parasitic fauna seen in this study and from the statistical analysis, there were significant differences ($P=0.05$) between the weight of hosts and the density of infection.

Corresponding Author:

Elmajdoub O. Layla; email:
elmajdoubayla@yahoo.com

Received 23 December 2017

Accepted 7 March 2018

Published 14 March 2018

Production and Hosting by
Knowledge E

© Elmajdoub O. Layla et al. This article is distributed under the terms of the

Creative Commons

Attribution License, which permits unrestricted use and redistribution provided that the original author and source are credited.

Editor-in-Chief:

Prof. Mohammad A. M. Ibnouf

Keywords: *Rana Saharica*, endo-parasites of frogs, nematodes, helminthes, prevalence

1. Background

The amphibians are the most threatened taxa that 40% of the approximately amphibian species worldwide in decline, [16], usually the infectious disease, including those caused by viruses, parasites and fungi are major contributors to the decline of many species of amphibians especially frogs.

The common tree frog, *Rana Saharica*, 1827, is found in south-central Hadhramut in Saudi Arabia, northern Yemen, extreme northeastern Sinai, Israel, Syria, southern Turkey, northern and western Iran, Armenia, southern Georgia [5].

OPEN ACCESS

The previous studies consider that amphibian populations provide excellent systems to study ecological concepts related to helminth communities. [2, 11, 12].

There are no studies of Frog parasites in Libyan anurans, thus the aim of this study was to determine the prevalence rates of endo- parasites in common tree frog, *Rana Saharica* from the Misurata city in the north of Libya.

2. Material and Methods

2.1. Study area

A study was carried out in different parts of the Misurata region in the western north of Libya during April to end of October 2015 by hands. The samples were taken from 62 common tree frogs, and this study was approved by research unit of zoology Ethics Committee of Misurata University, Misurata, Libya. From Misurata, this region in the western north of Libya is geographically located at latitude 32°22'39.12"N and longitude 15°05'31.26"E based on the map of the world.

2.2. Sample collection

The frogs were humanely killed, dissected and necropsied, the digestive system was removed intact and the various sections (oesophagus, proventriculus, gizzard, duodenum, jejunum, ileum, caeca and rectum) separated and placed in petri dishes containing 0.9% physiological saline.

2.3. Sample examination

Each section was cut longitudinally to expose its content and examined under a dissecting microscope to recover the parasitic worms [4]. The macroscopic worms were isolated after being washed by showering them several times to remove the stuck materials of the host alimentary canal. Moreover, the cestodes were put in warm water (45°C) for 12-24 hours to get good mount, and putting them in pure Glycerin for a few hours, after fixation, a process of dehydration was applied gradually by treating them with graded alcohol as 30%, 50% and 70% then dyed with semichons acid carmine according to the way explained by [3]. Furthermore, again dehydrated through acid alcohol (1% HCL in 70% ethyl alcohol), 70%, 90% and absolute ethyl alcohol, cleared by xylol and mounted in DPX [15]. Whereas the nematodes were killed extended by using

hot 70% ethyl alcohol and preserved in 70% ethyl alcohol containing 5% glycerine, Lactophenol was used as a clearing agent [7].

2.4. Histological examination

After dissection of frogs, the internal organs (liver and lung) were quickly removed, thus were taken the internal organs from five frogs and the small pieces were fixed in 10% formalin and further processed to paraffin wax embedding using routine protocols. Sequential 5 μm thick sections were cut using a microtome and a series of sections were stained with haematoxylin and eosin for histopathological examination. (Juncueira *et al.*, 1979)

2.5. Statistical analysis

One way ANOVA was employed to determine the possible association between density of parasite infection and host weights. This test was performed using the SPSS computer software.

The manuscript is the authors' original work and it has not received prior publication and is not under consideration for publication elsewhere.

3. Results

3.1. Prevalence of helminth parasites in common tree frog (*Rana Saharica*)

Of naturally infected frogs, 98% (61/62) were positive for one or more species of endoparasites. 53 (86%) were found infected with protozoa, 49 (80%) were found infected with helminths and Multiple infections with both protozoan and helminths were observed in 40 (65%).

These species were identified as 4 species of Protozoa: *Oplina ranarum*, *Copromonas subtilis*, *Nyctotheus condiformis*, *Cepeda lanceolata*. Trematodes included the intestinal fluke *Glypthelmins quieta*, the nematodes were found *Rhabditis* spp. And one species of cestoda and achentocephala as *Ophiotaenia ranae*, *Corynosoma* spp. respectively.

Table (1) illustrated the 36 (73.5%) single infection and 13 (26.5%) multi infections with two or more species of helminths in the same frog. Moreover, the *Rhabditis* spp recorded the 75.5% and was higher than those of *Ophiotaenia ranae* 45%, *Glypthelmins*

	<i>Rhabditis</i> spp	<i>Ophiotaenia ranae</i>	<i>Glypthelmins quieta</i>	<i>Corynosoma</i> spp.	A single infection	Multi infections
Number of infected frogs	37	22	4	1	36	13
Prevalence rate	75.5%	45%	8.2%	2.04%	73.5%	26.5%

TABLE 1: Illustrated the prevalence rates of helminthic parasites in common frog.

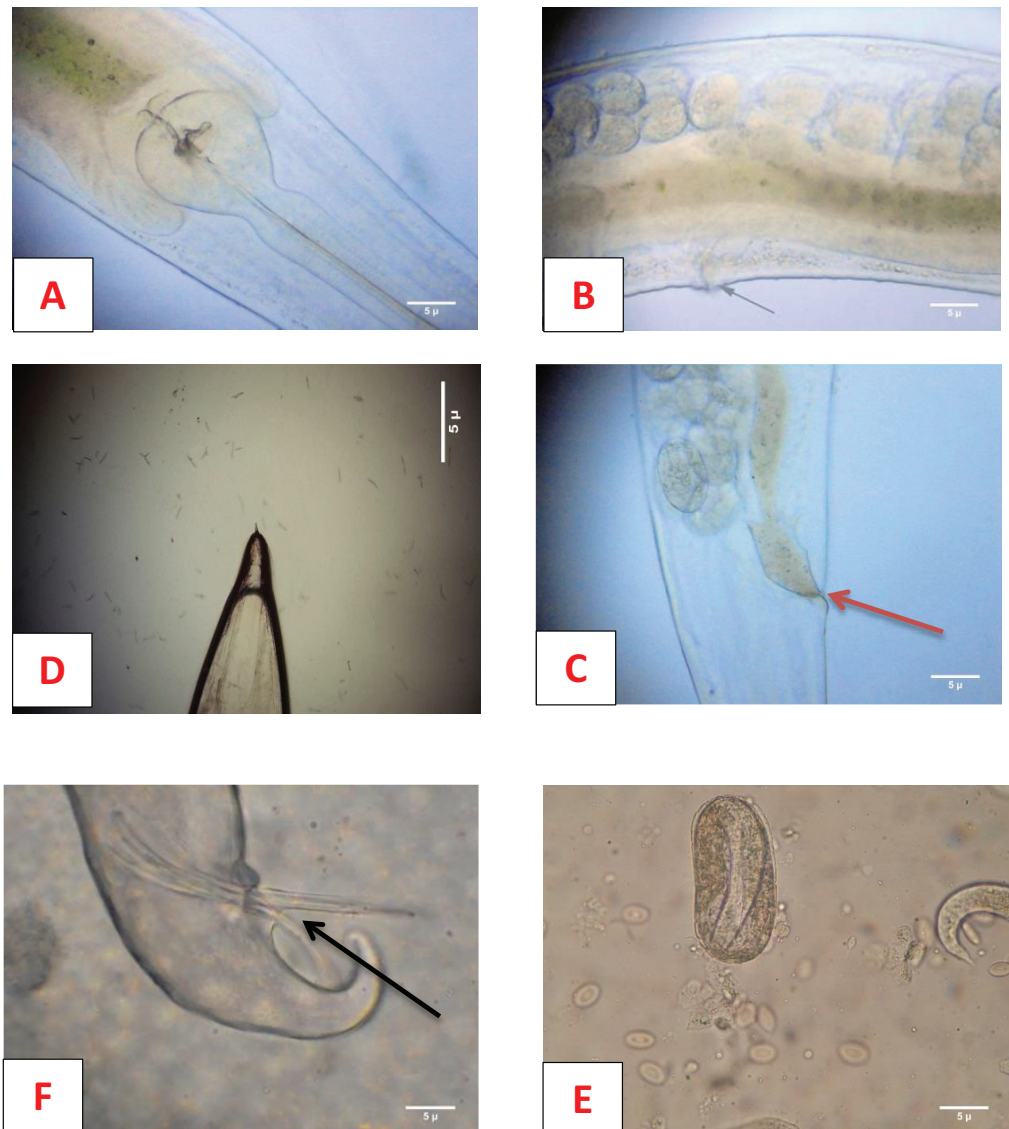


Figure 1: the general morphology of *Rhabditis* spp. From the intestine of common frog. A: oesophagus form of *Rhabditis* spp. B: uterus filled with eggs, arrow indicated to the genital pore. C: anus pore. D: the posterior end of female adult. E: the egg to larvae. F: the posterior end of male adult with two spines.

quieta 8.2% and *Corynosoma* spp. 2.04%. Fig (1), (2) and (3) shown the morphological features of *Rhabditis* spp., *Ophiotaenia ranae* and *Corynosoma* spp. Respectively.

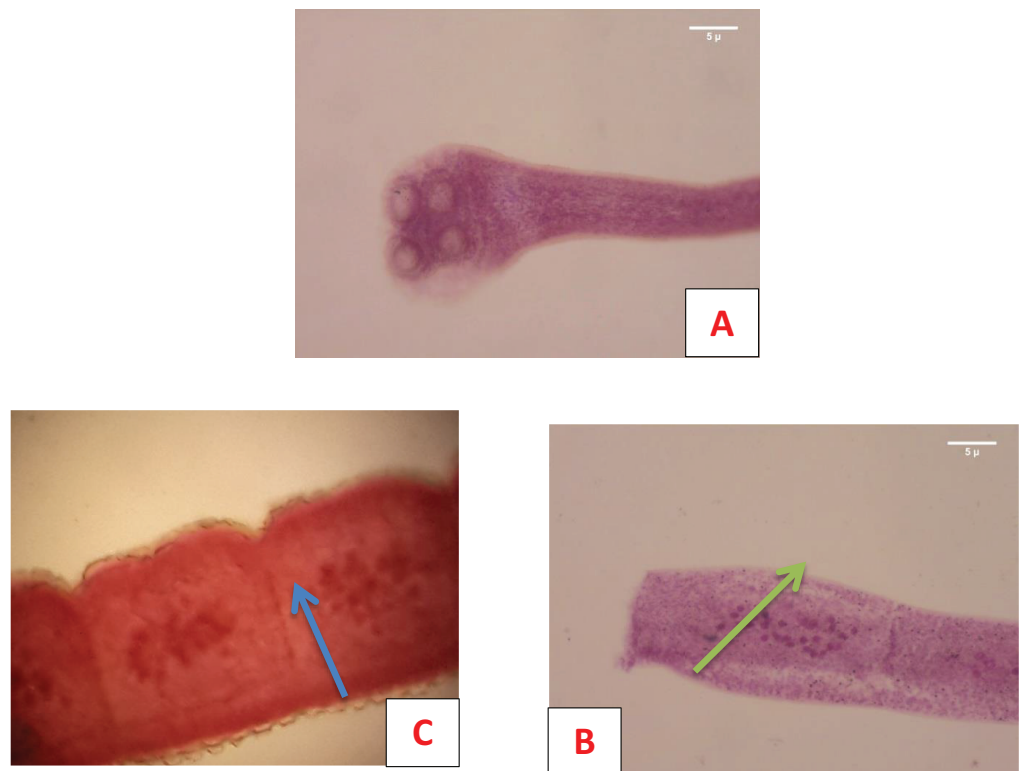


Figure 2: The general morphology of *Ophiotaenia ranae* From the intestine of common frog. A: the scolex of the adult worm showing four suckers. B: the mature segment showing testes (arrow). C: the gravid segment showing eggs (arrow).

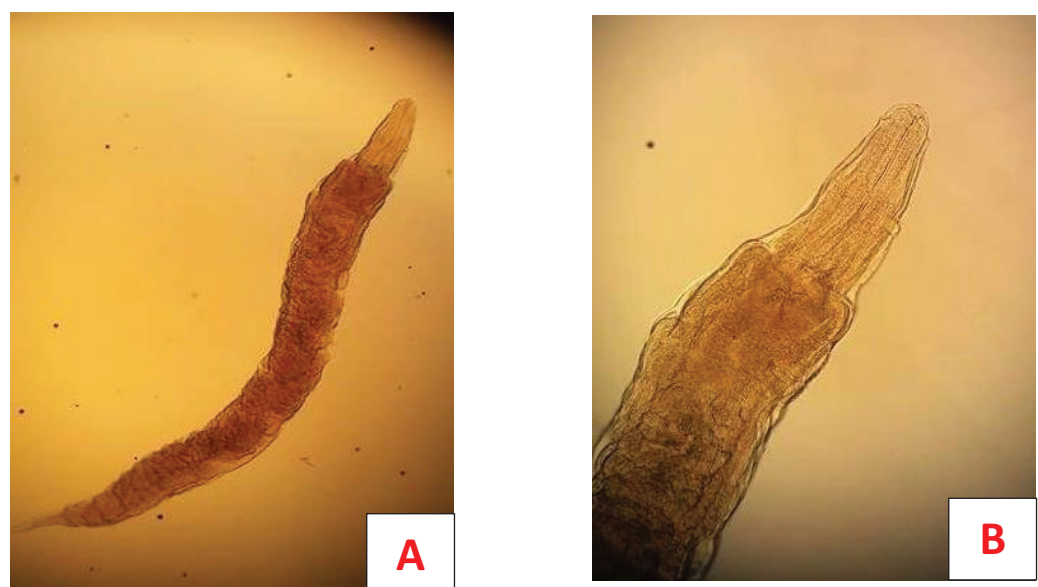

Figure 3: the general morphology of *Corynosoma* spp. From the intestine of common frog. A: the general morphology of adult worm. B: the scolex of the adult worm showing tiny spines.

	<i>Nyctotheus condiformis</i>	<i>Coccidian oocyst</i>	<i>Copromonas subtillis</i>	<i>Oplina ranarum</i>	<i>Cepeda lanceolata</i>	A single infection	Multi infections
Number of infected frogs	7	2	11	11	1	33	20
Prevalence rate	13.2%	3.8%	20.7%	20.7%	1.9%	62.3%	37.7%

TABLE 2: The prevalence rates of protozoa parasites in common frog.

3.2. Prevalence of protozoa parasites in common tree frog *Rana Saharica* at Misurata

Based on Table (2) illustrated *Oplina ranarum* and *Copromonas subtillis* prevalence were close to the average rate (20.7%) and higher than those of *Nyctotheus condiformis*, *Coccidian oocysts* and *Cepeda lanceolata* were (13.2%, 3.8% and 1.8%) respectively.

Furthermore, from this Table was showed the single infection with one species of protozoan was higher than those of multi infection with two or more species of protozoa, also the most species were found together as *Oplina ranarum* & *Nyctotheus condiformis* (18.8%) following by *Oplina ranarum* & *Copromonas subtillis* (15.6%) and *Copromonas subtillis* & *Nyctotheus condiformis* (12.6%), while 12.5% was found infected with three species of protozoa.

3.3. Prevalence of parasites in internal organs in common tree frog (*Rana Saharica*)

Regarding the intestinal infection, all the examined internal organs were infected with parasites, in case of severe infection with intestinal protozoa, the infections moved to the liver and lungs. Fig 5 illustrated the liver that has shown 50% infection rate with *Oplina ranarum*, 25% with *Copromonas subtillis* and 25% with the cyst of *Mesocostoides* spp. Followed by lung 50% in each of *Copromonas subtillis*, and *Oplina ranarum*. Fig 6 was shown the internal infections of liver and lung tissues.

Regarding the statistical findings that shows the relationship between the weight of frogs and the density of parasites with the significant difference based on the one-way ANOVA ($P=0.05$), Fig 7 illustrated the relationship between density of parasite and weight of examining frogs. Both of the prevalence and intensity of infections significantly increases with the weight of the frog.

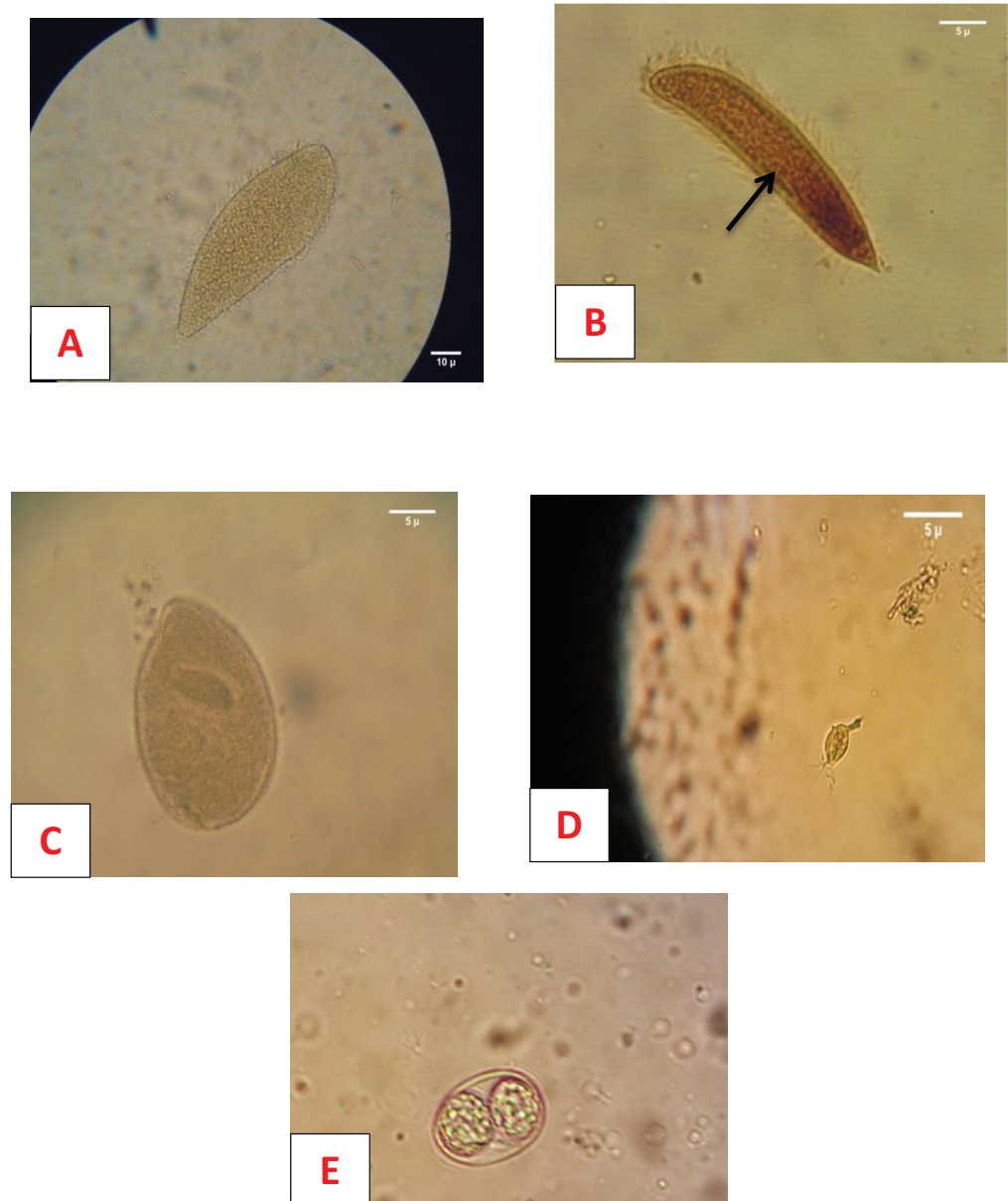


Figure 4: The general morphology of some protozoa were shown in gastrointestinal of common tree frog, A: *Oplina ranarum*; B: *Cepeda lanceolata*, are indicated to the small spine; C: *Nyctotheus condiformis*; D: *Copromonas subtilis*; E: Spoulated *Coccidian* oocyst.

4. Discussion

This is the first study regarding the parasitic fauna in the common tree frog (*Rana Saharica*), in Misurata city, Libya from April to end of October 2015, belonging to the Protozoa, Nematode, Cestoda, Trematoda and Acanthocephla, 98% of examining frogs were infected with parasites which agrees with a study by [9] that reported all examined frogs were infected by parasites. Moreover, the previous studies reported

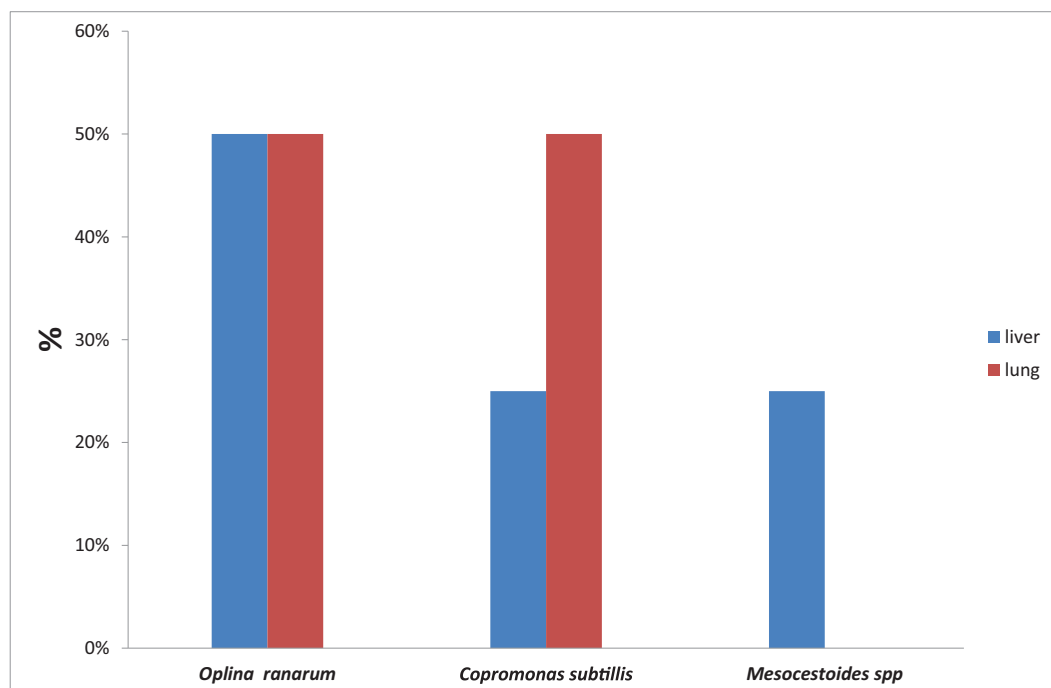


Figure 5: The prevalence rate of infected liver and lung from common tree frog.

higher prevalence rate of parasitic infection by Tyler, 2009 (76%) and Randall and Coggins (1996) around 80%. Protozoa were found in 86% of the common frogs, 80% of helminths, this result was corresponding with study in Saudi Arabia by ALAttar, 2010. And Mcallister *et al.* (1995) reported the Protozoan infection were higher than those of helminths, while the mixed infection (protozoa and helminths) was found 65% in current study and higher than that study by [9] (26%).

Regarding to the prevalence rate of nematodes (75.5%) were higher than those of Cestoda, Trematoda and Acanthocephala (45%, 8.2% and 2.04%) respectively, in contrast [13] from Malaysia recorded the prevalence rates of Trematoda 36.8% and Acanthocephalans 19.5% were higher than those in this study while the Nematodes prevalence was lower (43.7%) comparing with this result, thus it suggested that might belonged to the variation in the environment and geographical location. Otherwise, [8] reported that the high prevalence in nematode infection is mostly in terrestrial frogs. 26.5% of frogs seemed to be infected by two or more species of helminths and this current result was corresponding with [13]; Yildirimhan *et al.* (2012) in Turkey. They observe significant differences between frogs and density of parasites, also this finding was agreed with [13] in their study.

The most common parasite species were described as *Oplina ranarum*, *Copromonas subtilis*, *Nyctotheus condiformis*, *Cepeda lanceolata*, *Glypthelmins quieta*, *Rhabditis spp.*, *Ophiotaenia ranae*, *Mesocestoides spp.* and *Corynosoma spp.*

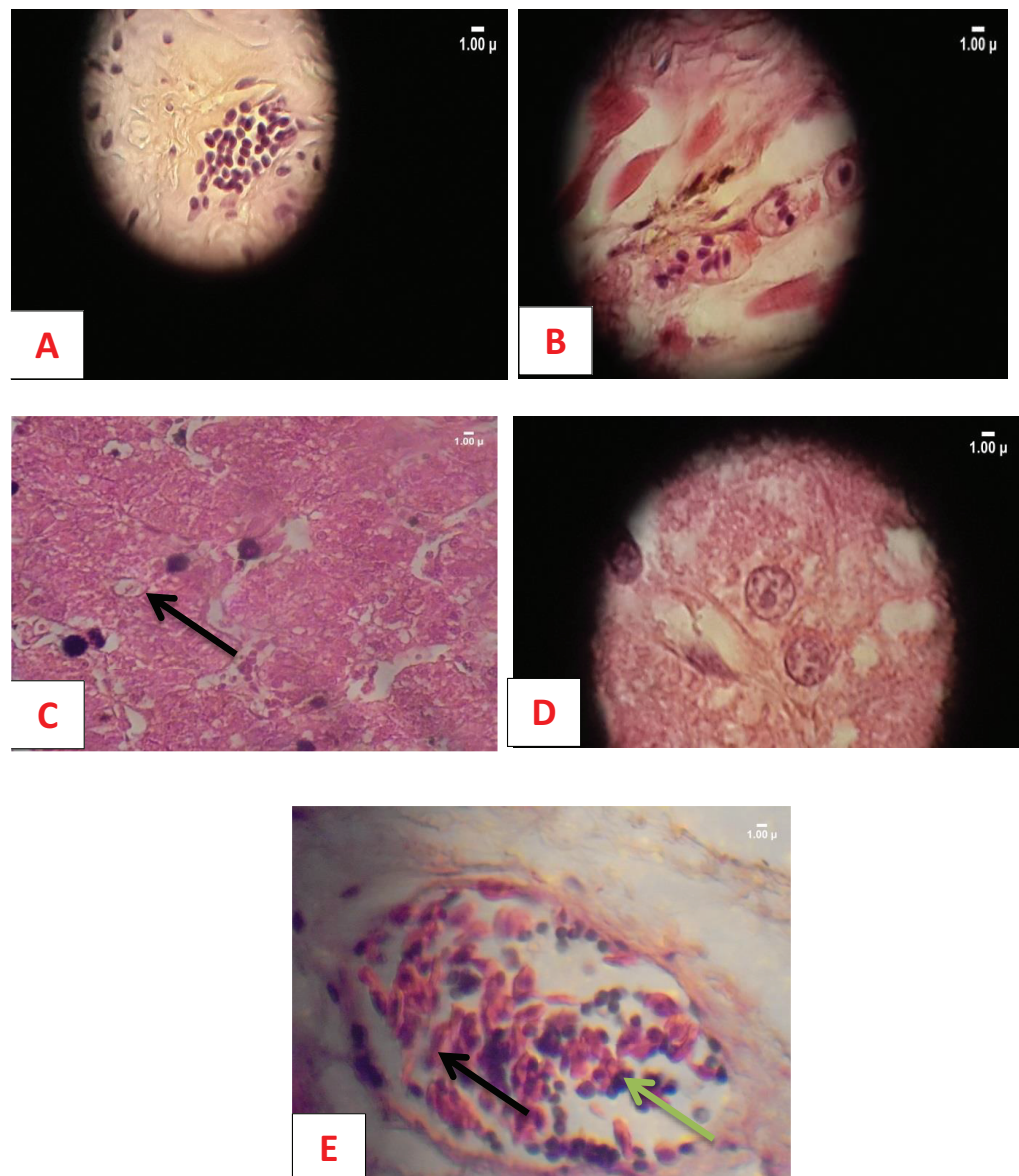


Figure 6: Histopathology findings of the liver and lung tissues of frogs infected with parasites, A: *Copromonas subtilis* in the lung tissue; B: *Copromonas subtilis* in liver tissue; C, D: cyst of *Mesocestoides* spp. In liver tissue, have indicated it by arrow; E: Mixed infections with *Copromonas subtilis* and *Oplina ranarum* in lung tissue.

Moreover, the previous study discovered the *Rhabditis* spp. and *Glypthelmins quieta* from different species of frogs and corresponding with this study [13] Yildirimhan *et al.* (2012) in Turkey and Rahman *et al.* (2008). Whereas, the infection by Trematodes and acanthocephalan spp. In terrestrial frogs were limited compared with other species of frogs because they required two hosts in their life cycles as insects or molluscan first intermediate hosts.

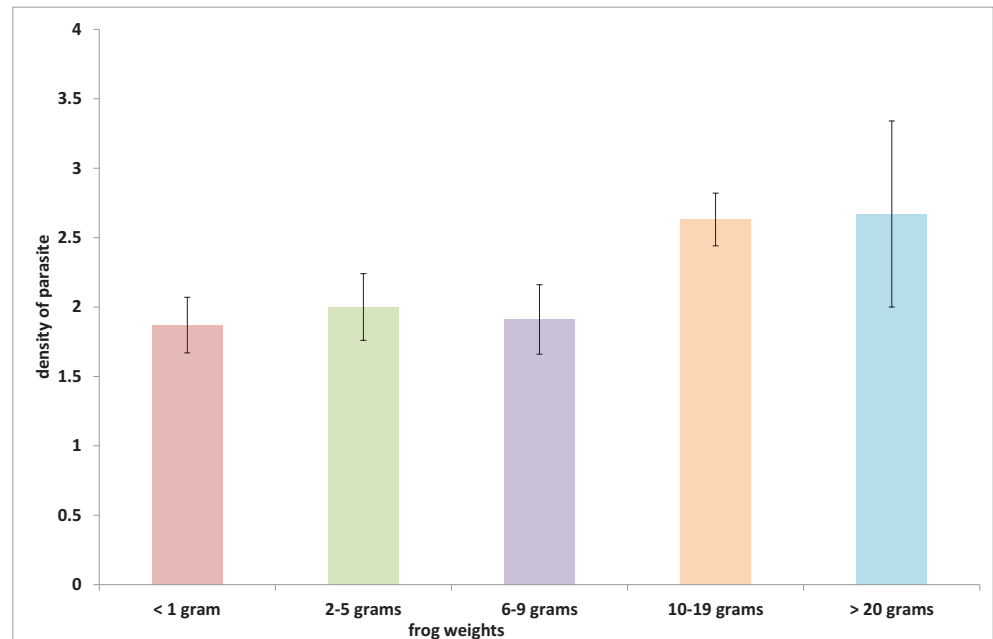


Figure 7: The relationship between density of parasitic infections and frog weights.

Furthermore, the prevalence rate of *Oplina ranarum* in current frogs was the most common protozoa and estimated 20.7%, followed by 13% of *Nyctotheus condiformis*, these findings agreed to study in the USA by [9, 14] in Malaysia.

In this study, the *Mesocestoides* spp. isolated from liver with single invaginated scolex in the deep invagination canal, also [10] described them in their study.

Currently, it was suggested that most amphibians harbour a depauperate non-interactive helminth community. In conclusion, mainly the frogs examined were parasitized by protozoans, nematodes and cestodes followed by trematodes.

5. Acknowledgments

The authors are grateful to the Dean of Zoology department, Misurata University for providing the facilities for carrying out the research.

References

- [1] AlAttar, A.M. (2010): Hematological, Biochemical and Histopathological Studies on Marsh Frog, *Rana ridibunda*, Naturally Infected with *Waltonella duboisi*. International Journal of Zoological Research, 6: 199-213

- [2] Bolek, M.G. and Coggins, J.R. (2003): Helminth community structure of sympatric eastern American toad, *Bufo americanus americanus*, northern leopard frog, *Rana pipiens*, and bluespotted salamander, *Ambystoma laterale*, from southeastern Wisconsin. *Journal of Parasitology*, 89, 673-680.
- [3] Cable, R. M. (1985) An Illustrated laboratory manual of Parasitology 5th Ed. Surjeat publications, Dehli, 255-269.
- [4] Fatihu M., Ogboya, V.C., Njoku C.V. and Sanor D.I. (1991) Comparative studies of gastrointestinal helminths of poultry in Zaria, Rev. Elev. Med. Vet. Pays. Trop., 44 (2): 175-177.
- [5] Frost, D.R. (2010): Amphibian Species of the World: An Online Reference. Version 5.4 (8 April 2010). Am. Mus. Nat. Hist., New York. Available at <http://research.amnh.org/vz/herpetology/amphibia/>.
- [6] Juncueira, L.C.U., Bignolas, G., Brentani, R.R., (1979): Picrosirius staining plus polarization microscopy, a specific method for collagen detection in tissue section. *Histochemical Journal*, 11: 447-455.
- [7] Kruse O.W. Pritchard M.N. (1982): Collection and preservation of animal parasites Technical bull.1 Univ. Nebraska lincoln and London, 141.
- [8] Kusriani, M. D., Suzanna, E. and Satrija, F. (2003): Endoparasites of two species of edible frogs, *Limnonectes macrodon*, Boie and *Fejervarya cancrivora*, Gravenhorst, from Bogor, Indonesia. Prosiding Seminar Hasil Penelitian Departemen Konservasi Sumberdaya Hutan, 53-64.
- [9] McAllister, C.T., Bursey, C.R., Connior, M.B. and Trauth, S.E. (2013): Symbiotic Protozoa and Helminth Parasites of the Cajun Chorus Frog, *Pseudacris fouquettei* (Anura: Hylidae), from Southern Arkansas and Northeastern Texas, U.S.A. *Comparative Parasitology*, 80(1):96-104.
- [10] McAllister, C.T., Connior, M.B. Bursey, C.R., Trauth, S.E., Robison, H.W. and Conn, D. B. (2014): Six New Host Records for *Mesocestoides* sp. Tetrathyridia (Cestoidea: Cyclophyllidae) from Amphibians and Reptiles of Arkansas, U.S.A *Comparative Parasitology*, 81(2):278-283.
- [11] McAlpine, D.F. (1997): Helminth communities in bullfrogs (*Rana catesbeiana*), green frogs (*Rana clamitans*) and leopard frogs (*Rana pipiens*) from New Brunswick, Canada. *Canadian Journal of Zoology*, 75, 1883-1890.
- [12] Muzzall, P.M. (1991): Helminth infracommunities of the frogs *Rana catesbeiana* and *Rana clamitans* from Turkey Marsh, Michigan. *Journal of Parasitology*, 77, 366 -371.

- [13] Rahman, W.A. and Shakinah, Z. (2014): Endoparasitic Helminths of various Species of Frogs in Penang island, Peninsular Malaysia. *International Journal of current Microbiology and Applied Science* 3 (9): 933-939.
- [14] Rahman, W.A., Tan, A. and Sufina, I. (2008): On the parasitic fauna of two species of anurans collected from Sungai Pinang, Penang Island, Malaysia. *Tropical Biomedicine* 25(2): 160-165.
- [15] Tasawar Z., Aziz. and Akhtar M. (1999): Prevalence of cestode parasites of domestic fowl. *Pakistan. Vet.* 19 (3): 142-144.
- [16] Vie, J.C., Hilton-Taylor, C., Stuart, S.N., (2009): *Wildlife in a Changing World-an Analysis of the 2008 IUCN Red List of Threatened Species*. International Union for Conservation of Nature, Gland, Switzerland.