

Conference paper

Surgical Correction of Child Planovalgus Deformity by Porous TiNi-based Implants

G.B. Slizovskiy¹, V.E. Gunther^{2,3}, I.I. Kuzhelivskiy¹, L.A. Sitko⁴, M.A. Fedorov¹

*Corresponding author:

G.B. Slizovskiy, email:

sgv5858@mail.ru

¹FSBEI HE Siberian State Medical University (Pediatric Surgical Pathology), Tomsk, Russia²Tomsk State University, Tomsk, Russia³Research Institute of Medical Materials and Implants with Shape Memory, Tomsk, Russia⁴GBEI HPE Omsk State Medical University (Pediatric Surgery), Omsk, Russia

Received: 23 March 2017

Accepted: 9 April 2017

Published: 16 July 2017

Publishing services
provided by Knowledge E

Copyright © 2017 G.B. Slizovskiy et al. This article is distributed under the terms of the [Creative Commons Attribution License](#), which permits unrestricted use and redistribution provided that the original author and source are credited.

Selection and Peer-review under the responsibility of the SMBIM Conference Committee.

Abstract

The question of child degenerative-dystrophic diseases is predominate in orthopedic pathology, where the problem of its treatment is very acute. Excluding the modern treatment methods, the number of children suffering planovalgus deformity is comparably more to total orthopedic patients. This article describes a surgical treatment method of child planovalgus deformity by applying porous biocomposite materials from TiNi alloy. The method involves inserting porous frustoconical composite TiNi implant into subtalar joint, which, in its turn, could correct the deformation and shape the arch of foot eliminating planovalgus deformity.

1 Introduction

Nowadays, there are numerous operative treatment methods for axial deformities of foot and shin bone (tibia), which eliminate different pathological components [1, 3]. Such a number of methods could be explained by the ambiguous opinions of researchers on the pathogenesis of deformation. All existing surgical methods applied in treating axial deformities of foot and shin bone (tibia) could be classified as:

 OPEN ACCESS

How to cite this article: G.B. Slizovskiy et al. (2017), "Surgical Correction of Child Planovalgus Deformity by Porous TiNi-based Implants," in *Shape Memory Biomaterials and Implants in Medicine*, KnE Materials Science, page 486–492. DOI 10.18502/kms.v2i1.842

1. operations on tendon-ligamentous and capsular -ligamentous apparatus;
2. operations on bones and combined operations.

The first operation type on capsular-ligamentous apparatus to remove planovalgus deformity is performed on the soft tissues with further plaster bandage fixation.

The second operation type for 12+ children involves arthrodesis. Joint fusion in functional-reliable position to relieve impactable pain and recover from severe foot deformity. Such interferences remove foot deformity, but anatomic foot length is decreased as articular cartilage is resected, which, in its turn, reduces the functional treatment result. According to Jross data (1986) poor results of such interferences are about 47%. Today researchers are in constant range-finding study in up-dated treatment methods of above-mentioned pathology due to biotechnical foot function disorders as amortization, support and tension [5, 6,7].

Recently, the gold standard is the operation in subtalar sinus. This operative treatment includes correcting talocalcaneal joint configuration by inserting implant, shaping anatomically correct arch of foot in appropriate position and its reliable fixation in over-correction position by plaster bandage.

Colleagues from Nizhny Novgorod R&D Institute of traumatology and orthopedics, headed by M.V. Vlasov proposed subtalar implant with frustoconical body, externally screw-threaded and axially orifice connection. There are three longitudinal grooves on the body, spaced at identical intervals and dividing the body into equal sections. Grooves in the direction of screwing out have beds at the height of screw threads, while the threads of opposite side have rounded radius. This device improves the fixation reliability, excluding its migration from subtalar sinus and provides stable correction of talocalcaneal joint in appropriate position [3].

Colleagues from Turner Scientific Research Institute for Children's Orthopedics (V.V,Umnov and N.V. Dolzhenko) proposed the following implant to shape the arch of foot: autogenous bone from fibula and further fixation by twist drill needle (Kirshner wire) which prevents subtalar joint and anterointernal displaced talus, being the basic component of this deformity without significant anatomic changes [2].

Analogous operation including supplementary interference into the soft tissue component was proposed by V.A. Tupikov and his colleagues. This operation embraces not only autotransplant but also achille plastic operation, i.e. subcutaneous recession of long peroneus to talar neck and long peroneous tendon through foremen being formed on the talar neck and tension attached by a loop. Then inserting Z-shaped shortened plasty into tibialis posterior muscle. This method provides reliable talar bone fixation in correct position, restoration of

supporting foot function, reduction of surgical injury and after-operation complications [4].

A “simpler option” of above-described operation was proposed by Prof. G.P. Kotelnikov from Samar Medical University. This method included Z-shaped dissection of heel tendon, long and short peroneal muscles and externally inserting transplant into subtalar joint and dissection of talonavicular joint capsule[1]. In modern orthopedics surgical correction of planovalgus deformity is performed by means of subtalar sinus fusion through fusing infraarticular[5].

Unfortunately, the medical product market offers only foreign implants. In most cases this is Kalix2 implant, Integra Co. (France). Scientists from People's Friendship University of Russia have presented a rather complete documentation of clinical experience trials under the supervision of Prof. S.K. Tamoev. Proposed surgical treatment method involves 2 cm curved incision directly anterior and distally to lateral malleolus. Further talus bone sinus is exposed. A retractor is introduced into the subtalar sinus and reducing it towards plantar, thus removing valgus deformity and reducing the talus itself. A probe is introduced into the tarsal sinus to estimate the suitable implant size and after selected implant is installed (screwed in). The incision is closed by plastering the foot for 3-4 weeks. After the growth of a child the implant should be removed [7].

However, it should be mentioned that this applied implantation has some disadvantages. The implant is produced from polymer material, whereas its structure excludes possible ingrowth. In this case, the main problem involves its migration due to poor fixation in the subtalar sinus. In some cases, implant destruction which could be the result of the growth of a child and increasing body weight. Acknowledging these disadvantages in applying such technology and investigating more effective and universal method is challenging. Thus, the development of a more optimal method for subtalararthroereisis is the most urgent task in today's foot orthopedics.

It should be noted that the initial disadvantage of the prototype is the fact that the implant should be removed by a second operation at the age of 16-18. Due to the high prices of such implants the medical insurance (CHI) can not cover all expenses, and only by quota. Considering the state policy related to import substitutes it is necessary to develop domestic materials and treatment methods being highly competitive with foreign ones.

2 Experimental

Critical analysis of literature justify the fact that this problem is becoming ever more relevant. In this case, the investigations and development of up-dated

methods allege the experimental and clinical studies in surgery correction of valgus deformity preventing further progression and recurrence.

In the last years in Russian medicine new alloys such as TiNi have been introduced. It is possible to develop various TiNi implants which would enhance the surgery treatment efficiency of orthopedic pathology. The most non-conventional material in implantology could be structures of TiNi-based alloy [3]. New technical result – decreasing surgery injury and complications due to one-time use of installed implant-correctors.

Mesoporous titanium nickelide implants with porosity of 81%, pore size 420 micron (permeability) have been used. These physico-technical properties are quite closely related to those of spongy bone tissue, which, in its turn, optimizes the osteo-integration of the biocomposite metal-bone. When installing the implant immobility is fixed by the material surface roughness, while its geometrical shape as frustoconical body excludes the migration of the implant into the subtalar space.

To achieve new technical results in surgery correction of children paralytic valgus deformity by applying implants which involve 2 cm curved incision directly anterior and distally to lateral malleolus, further exposing talus bone sinus, removing valgus deformity and reducing the talus itself. After estimating and selecting the suitable implant size the porous composite TiNi-based implant is inserted with the medical instrument “clamp” at an angle of 10-15° relative to frontal plane; the incision is closed by plastering the foot for 8-12 weeks.

In the R&D Institute of Medical Materials and Smart Implants conic porous composite TiNi-based implants in experimental diameter from 10 mm to 18 mm (Fig. 1).



Fig. 1. Set of subtalar porous TiNi-based implants

3 Results and discussion

General appearance of foot and X-ray examination of the patient before treatment are presented in Fig. 2.

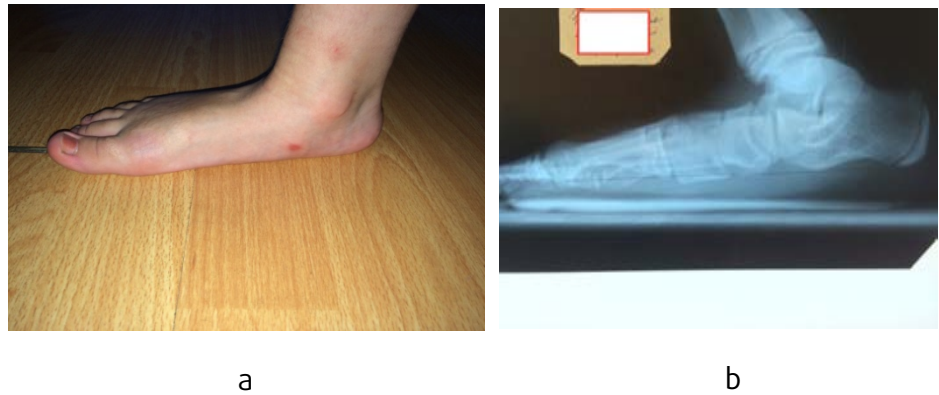

Fig. 2. General appearance of foot (a) and patient X-ray examination (b) before treatment

The operation is performed under spinal anesthesia. Patient-supine position. Pneumatic tourniquet is applied on middle third hip area. Preliminarily wrapping the operating lower limb with elastic bandage, then pumping pneumatic tourniquet, so as to minimize the blood loss. The lower limb is antiseptically treated three times. First, 4 cm oblique skin incision slightly anterior and distally to lateral malleolus; layer-to-layer exposure to subtalar joint; with Luer forceps strip scar tissue and ligament-filled subtalar joint from out of sinus.

Joint surface talar bone and mid- and- frontal heel bone facet is cleaned from cartilage tissue with Volkmann small spoon, whereas cartilage tissue is extracted to pinpoint bleeding. The foot is placed in normal correction position. In subtalar joint region with a special instrument the implant size from 10 mm to 18 mm is selected. After selecting the optimal sized implant of maximum correction degree, porous TiNi-based conical -shaped implant is single-stepped inserted into the subtalar joint space in base turned outwardly to heel at an angle of 10-15° relative to frontal plane; further, with Kocher forcep implant is additionally fixed to the joint by nail punch (Fig. 3).

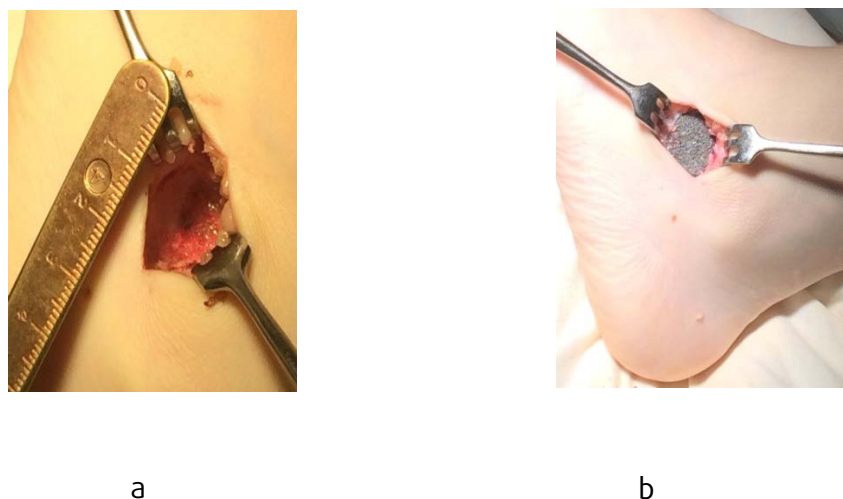


Figure 3. Bed for implant (a) and installed implant (b)

Test trials of foot movement is performed to check if the implant is firmly fixed in the joint and excluding migration (Fig. 4).

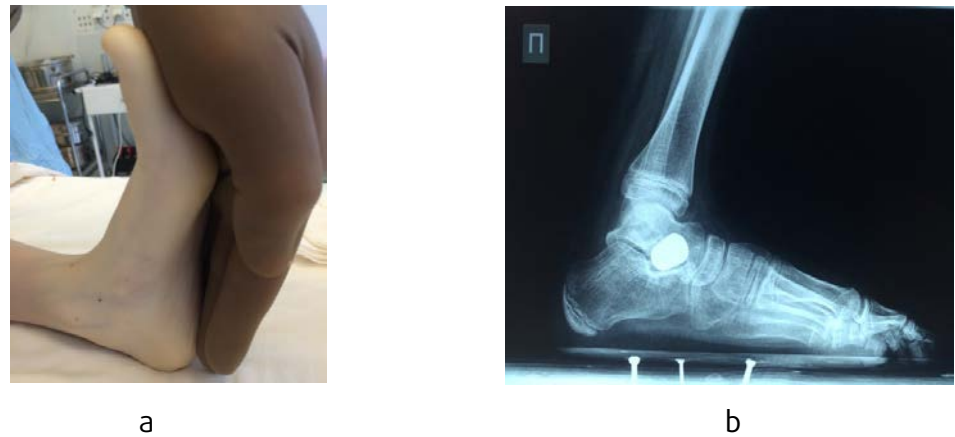

Fig. 4 General appearance of foot after operation (a), X-ray examination with implant (b)

Layer-by-layer the incision is closed with vicryl and without drainage. The skin is stitched with separate vicryl. Aseptic dressing is placed on the post-operation stitch. The lower limb is put in a support under plaster, then circular plaster fiber glass bandage is put on the lower limb, from upper third tibia to toe ends at a right angle. Pneumatic tourniquet is loosened.

Check-up X-ray in frontal and lateral projections is performed in 3-5 days after the operation in plaster bandage.

Time in plaster fiber glass bandage is 8-12 weeks after operation; check-up X-ray in 6th and 8th week after operation; plaster bandage is removed if bone block has been formed around TiNi-based implant and no sensation of pain or discomfort in projection of foot subtalar joint. After removing plaster bandage orthopedic shoes with fixed heel, high firm bootleg and insole with uplifted edges are prescribed. These shoes provide maximum relief on midfoot. These shoes should be worn for 6 months after operation. After six months check-up X-ray of foot in frontal and lateral projections. Further, check-up X-ray once in 12 months and consultations of children orthopedist.

Based on Order №1027 dated 05.08.1986 of Ministry of Health Care TiNi-based implants were permitted in clinical practice.

Conic porous composite TiNi-based implants in experimental diameter from 10 mm to 18 mm developed by R&D Institute of Medical Materials and Smart Implants are applied in the above-described surgery method.

4 Summary

The proposed surgery treatment comparable to prototypes excludes supplementary operations, such as open or integumental elongation of achillo-tendon, correcting open or closed heel bone osteotomy, correcting 1 instep bone osteotomy. In the case of combined paralytic valgus and heel deformity and achillo-tendon hyperextension, operation of detruncating plasty of achillo tendon is performed parallel to arthrodesis.

This method prevents implant displacement, as bone tissue adheres to implant pores, making its structure much more harder, which, in its turn, excludes possible breakage. In this case, it is not necessary to remove the implant during the adolescent period. This is due to the fact that this implant is a supplement to the deficient bone structure and provides the maximum contact with the surrounding tissues, as well. Another important factor is the impossibility of vascular disorders (these disorders could result in the remodeling of the bone tissue and / or recurrence of the deformity).

References

- [1] G.P. Kotelnikov, E.V. Kovalev, P.V. Ryzhov, N.V. Pirogova, Analysis of the results of treatment of patients with flat-valgus foot deformities from the standpoint of evidence-based medicine, 14th Congress of Pediatricians of Russia [in Russian], 2010.
- [2] V.E. Gunter, Biomaterials and New Medicine Technologies [in Russian], NPP MIC, Tomsk, 2014.
- [3] G.V. Slizovskiy, I.I. Kuzhelivskiy, Surgical treathment method of children dysplastic coxarthrosis, Mother and Child in Kuzbass [in Russian]. 3 (2013) 28-32.
- [4] V.M. Maslikov, N.V. Slizovsky, O.I. Ivanov, I.I. Kuzhelivsky, Russian patent "Method of treatment of long bone fractures in children" [in Russian] №2328241 from 10.07.2008.
- [5] M.B. Dobbs, P.L. Schoenecker, J.E. Gordon, Autosomal dominant transmission of isolated congenital vertical talus, Iowa Orthop. J. 22 (2002) 25-27.
- [6] J.M. Labovitz, The algorithmic approach to pediatric flexible pes planovalgus, Clin. Podiatr. Med. Surg., 23 (2006) 57-76.
- [7] J.R. Maxwell, A. Carro, C. Sun, Use of Maxwell-Brancheas arthroeresis implant for the correction of posterior tibial tendon dysfunction, Clin. Podiatr. Med. Surg. 6 (2007) 479-489.