

Conference paper

## Replantation of the Condylar Shoot of Fractured Temporomandibular Joint of the Articular Head by TiNi-based Materials

A.T. Karnaukhov<sup>1\*</sup>, I.G. Alyoshkin<sup>1</sup>, V.A. Karnaukhov<sup>1</sup>

\*Corresponding author:  
A.T. Karnaukhov, email:  
karnauhov41@mail.ru

<sup>1</sup>Irkutsk State Medical University, Irkutsk, Russia

Received: 23 March 2017

Accepted: 9 April 2017

Published: 16 July 2017

Publishing services  
provided by Knowledge E

Copyright © 2017 A.T. Karnaukhov et al. This article is distributed under the terms of the [Creative Commons Attribution License](#), which permits unrestricted use and redistribution provided that the original author and source are credited.

Selection and Peer-review under the responsibility of the SMBIM Conference Committee.

 OPEN ACCESS

### Abstract

The offered way of restoration of anatomic integrity of the articular head and of the condylar shoot of the temporomandibular joint by the way of modeling of replant at using materials of nickelid titanium alloy (TiNi) with the shape memory allows to conclude about the favorable results of rehabilitation of patients with fragmentary fractures of the articular head of the temporomandibular joint in the remote terms of observation of 8 years.

### 1 Introduction

One of important and complex problems of modern maxillofacial surgery is the modeling of injuries of the temporomandibular joint.

The frequency of injuries of the facial skull has increased by 2-3 times for the last decade. According to the authors [1, 6] the fractures of the lower jaw make about 80% of injuries of jaws, among which the fractures of the condylar shoot make 6,4 – 44,7% [2] of total number of changes, including the fractures with dislocation of the articular head, with the injuries of the temporomandibular joint.

8-19% fall to the share of fractures of the head of the lower jaw, i.e. so-called intra articulate damages [1, 3].

Such fractures, especially bilateral, are followed by the expressed anatomy-functional changes and quite often lead to the violation of the bite at the

conservative treatment, to the development of the contracture or ankylosis of the temporomandibular joint and are also followed by the damages of the articular disc, ligaments and capsules and by the hemarthrosis.

All this testifies to expediency of development of surgical methods of treatment of such damages [2, 4].

The diagnostics of damages of the temporomandibular joint causes the certain difficulties caused by a set of varieties of fractures of the condylar shoot, by the fragmentary fracture of the articular head and its dislocation, by the peculiarities of the structure of the joint, and it represents a special problem in the maxillofacial surgery [3, 5, 6]

Hi-tech methods of a research of the three-dimensional image [3D] have considerably changed possibilities of the radiodiagnostics of the temporomandibular joint pathology.

Using of the multislice computed tomography (multislice CT), of the magnetic resonance imaging (MRI) and volume digital dental tomographs allow to reveal fractures of jaws, of facial bones, an articular disk, intra articular ligaments, of the bilaminar zone in the temporomandibular joint [3, 5, 6.]

## 2 Experimental

To improve the results of the surgical treatment of the patients with intra articular fragmentary damages the temporomandibular joint head by using the materials from the nickelid titanium alloy with the shape memory (TiNi) of thermomechanical processing. To give the nearest and remote (8 years) results of the treatment.

The clinical material of the work is based on the experience of the examination and the treatment of 27 patients with high damages of the condylar shoot, with the fragmentary fracture of the articular head of the temporomandibular joint and its dislocation, the patients who were treated in the children's hospital of maxillofacial surgery and in the faculty clinics of the Irkutsk State Medical University from 2005 for 2016.

The analysis of the age observations has revealed the need of distribution of the patients to some groups. The first group (4-7 years) – four patients, the second group (8-15 years) – seven patients and the third one (16-45 years)-16 patients.

The reconstruction of the image on the roentgenograms was carried out in sagittal, coronary and axial projections (three-dimensional 3D). The both joints of all the patients were investigated, including the cases of unilateral damage of the condylar shoot Fig.1.

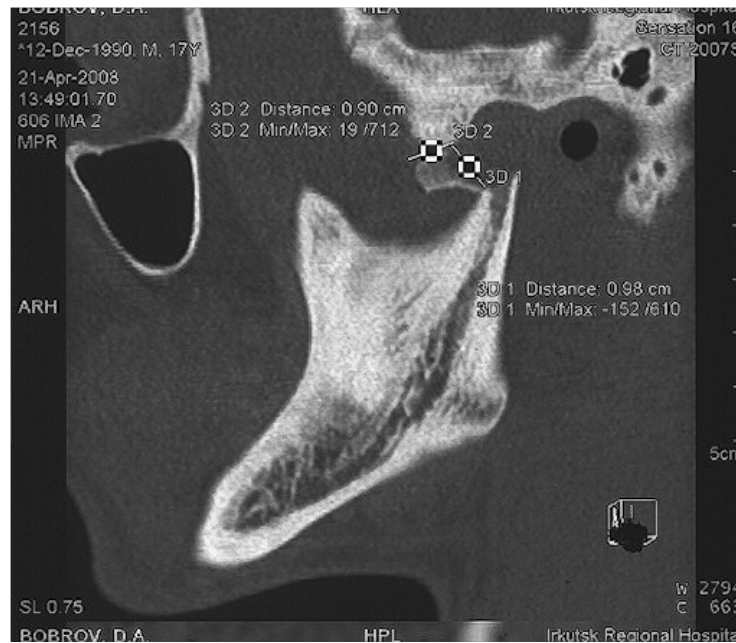


Fig.1. The patient B, 17 years. Fragmentary fracture of the head of the temporomandibular joint.

After the reconstructive surgical interventions on the joints in the early postoperative period and in dynamics the control radiological grants, and if it was necessary orthopedic and orthodontic treatment were annually carried out.

The technique of modeling of the replantatof hecandylar shoot of the temporomandibular joint was carried out with the brackets of 4-5mm made from the nickelid titanium alloy with the shape memory (TiNi) of thermomechanical processing, we fixed the articular head to the condyle fragment in three planes to the line of the fracture of the condyle perpendicularly.

The formation and the fixing of the replantat of the condyle to the branch of the jaw it was carried out with the brackets at an angle 90°, as replantats are fixed in a proper correlation with the branch of the jaw and the head of the joint puts into the articular pole on the disk. The osteosynthesis of the replantat was carried out with omega and S figurative brackets (2-3) with the shape memory bicortically and strictly perpendicularly to the line of the osteotomy of the branch.

As a result of the treatment of the temporomandibular joint fracture with the offered technique the anatomic integrity of the condyle and the function of the temporomandibular joint have reached the complete recovery in 25 (90,2%) cases. The patients ate liquid food, the mouth opened freely, without intermaxillary immobilization in two days after the surgery. The sparing diet for 3-5 days.

### 3 Results and discussion

We offer a way of using metals of thermomechanical processing with the shape memory made from the TiNi alloy having biomechanical and biochemical compatibility in Tomsk Research Institute of medical materials and implants with the shape memory.

The external access to the temporomandibular joint was got by cutting the skin from the earlobe fringing a jaw corner taking into account a marginal branch of a facial nerve (with the length of 4-5mm) in the cases of high fractures of the condyle shoot, of the neck and intracapsular fragmentary damages (fracture - dislocation) of the temporomandibular joint.

From 27 observations with such a pathology, 25 were carried out the modeling of the replantat of the condyle with the articular head according to the offered technique and in 2 cases the operation was done without the replantation of the condyle shoot. In the cases of high fractures of the neck of the condyle shoot with full bilateral 25 (90,2%) had the dislocation of articular heads and 2 (29.8%) of them had intracapsular fragmentary fractures of the heads. (Fig.1)

*Clinical example.* The patient B. of 17 years, (clinical record No. 937), has come to maxillofacial department of Ivano-Matryoninskaya children's clinical hospital of Irkutsk 21. 04. 2008 with complaints to pains when opening the mouth, the limited movements of the lower jaw. He got a blow in the chin at a "karate" competition two days ago. The restriction of opening of the mouth is revealed during the examination (1,0 - 1,5sm), the sagittal and lateral movements are sharply limited and painful, lateral deviation of the chin to the left. The violation of the bite of teeth is revealed in the oral cavity .

### 4 Diagnosis

Intraarticular fragmentary fracture-dislocation of the articular head of the temporomandibular joint on the left.

Left-side intraarticular fragmentary fracture-dislocation of the articular head is defined on the multislice computed tomography (multislice CT) of the frontal reformats, of the sagittal and coronary cuts. The modeling of a replantat was carried out according to the developed technique. Extra oral access at the left by the offered technique has made a resection of disteal department of a branch of a jaw with a condyle fragment at an angle 90° keeping a neurovascular bunch - is removed in a wound. The resection of distal department of the branch of the jaw with a condyle fragment at angle 90 degrees was made by extra oral access on the left. The fragments (three) of the articular heads located at the skull basis are found and removed in the wound with technical difficulties. The modeling of the

replantat of the articular head from three fragments by means of mini-brackets from TiNi 4-5mm of thermomechanical processing with shape memory (Fig. 2), the articular head of the modeled replantat is put into the articular fossa (the articular disk is kept and is in the fossa), the tendon of the external wing-shaped muscle, with the immobilization of the replantat to a jaw branch with omega-shaped brackets of TiNi is taken in. (Fig. 3)

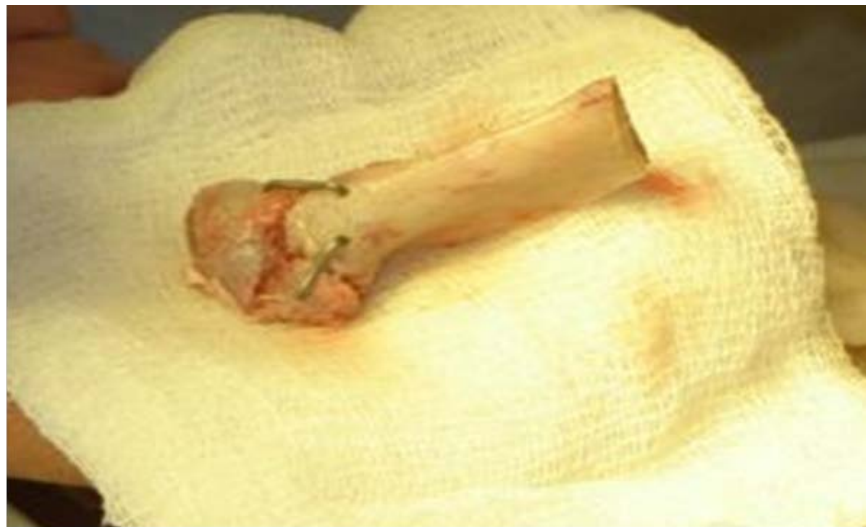

Fig. 2. The patient B, 17 years. The modeling of the replantat of the articular head of the condylar shoot of the temporomandibular joint by brackets made from TiNi alloy

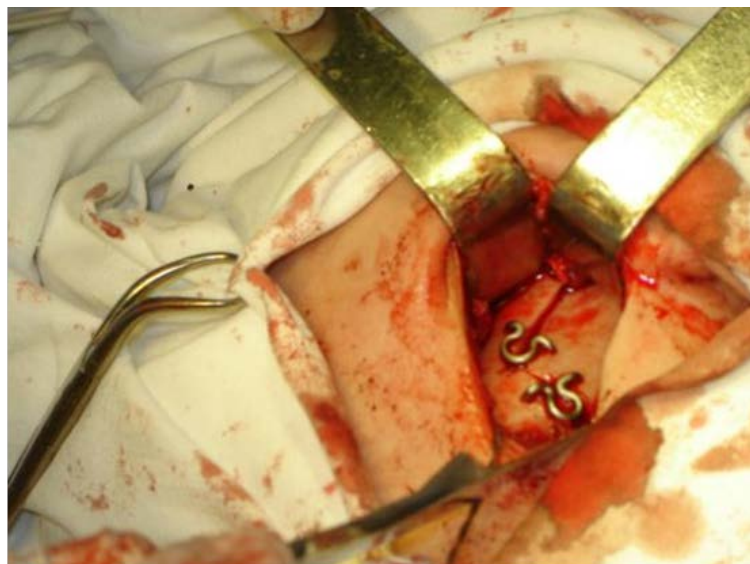


Fig.3. The patient B, 17 of years. The immobilization of a replantat to the branch.

The patient is discharged with the complete recovery of the function of the temporomandibular joint. The patient is examined after a year of observation (Fig. 4)



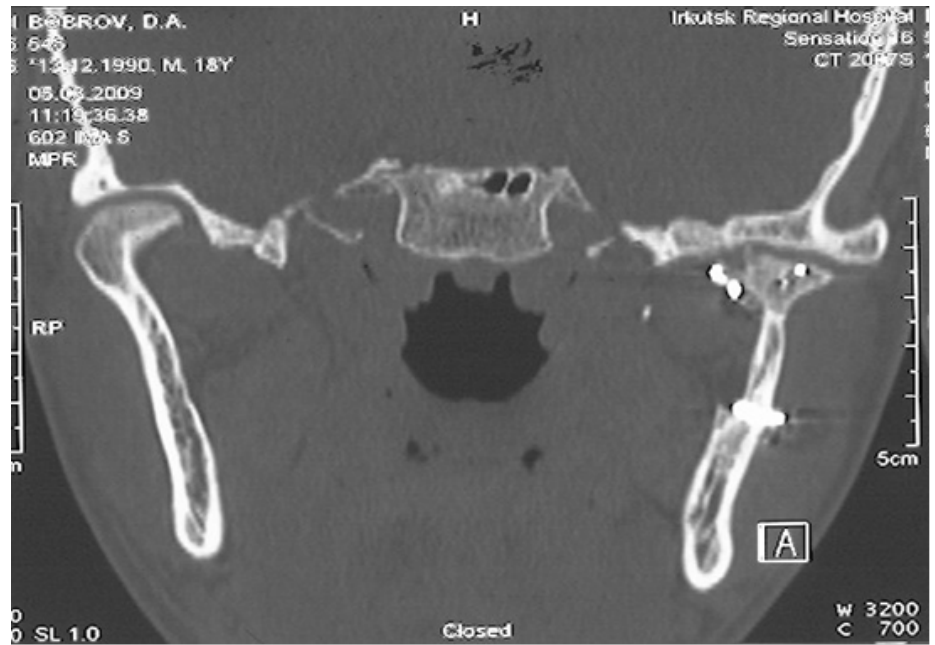

Fig. 4. The patient B, 18 of years. The multislice CT. The result after one year of observation of the replantation of the condyle shoot of the temporomandibular joint with the materials of TiNi alloy

The complete recovery of the function of the temporomandibular joint. The period of observation is 8 years. The multislice computed tomography (multislice CT) 2016 year. The structure of the replantat of the temporomandibular joint is without violations, the brackets are integrated with the bone (Fig. 5). The function of the movement of the lower jaw in the temporomandibular joint in three the planes and in full volume. There are no complaints. The observation of the surgeon.

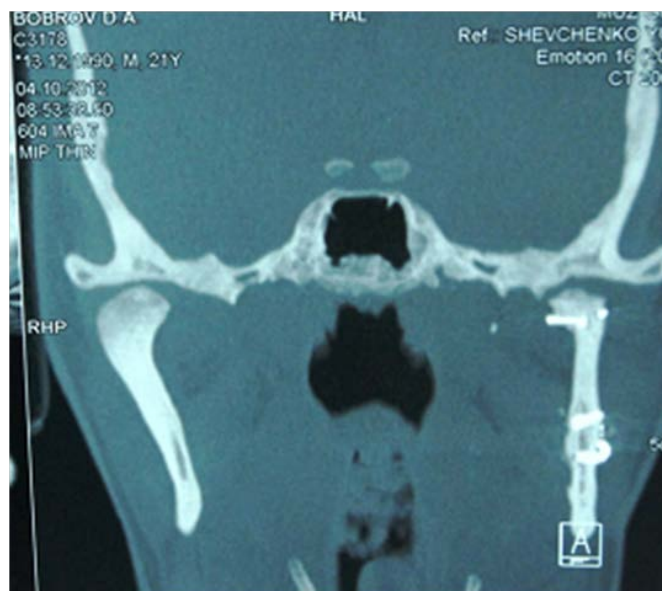

Fig. 5. The patient B, 25 years. The multislice CT. The result of 8 years of observation after the replantation of the condyle shoot of the temporomandibular joint with the materials of TiNi alloy

## 5 Conclusion

The using of computer technologies (multislice CT, MRI, and volume digital dental tomographs) with the three-dimensional image (3D) have considerably changed the possibilities of radiodiagnostics in obtaining significant diagnostic information of a radiological benefits. These technologies are the leading methods of identification of pathological changes at a maxillofacial trauma, at the trauma of the articular disk, of the intra articulate ligaments, of the bilaminar zone in the temporomandibular joint and these methods are important for the further planning of treatment of pathology of the temporomandibular joint.

The using of submersible clamps from the nickelid titanium alloy (TiNi) with the shape memory for the osteosynthesis at fractures in the area of the neck and the basis of the candyle shoot, which are followed by dislocation of the articular head, her fragmentary fractures, according to the offered technique of the replantation of candyle shoot allow to keep the function of the temporomandibular joint at rather stable immobilization of the fragments of the jaws and with the moderate compression effect.

## 6 Acknowledgments

TiNi-based medical materials and implants (solid clamps) were developed and manufactured at the Research Institute of Medical Materials and Implants with shape memory (Tomsk).

## References

- [1] I. A. Arsenova, Injuries of the temporomandibular joint and their treatment, Thesis abstract of candidate of medical sciences [in Russian], Omsk, 1997.
- [2] N.G. Bobyliv, P.G. Sysolyatin, S. P. Sysolyatin, About new way of surgical treatment of the condyle shoot fractures of the lower jaw which are followed by dislocation of the articular head, Maxillofacial surgery. 1-2 (2005) 63-67.
- [3] A.P. Dergilev, Arthrotomography, computer arthrotomography and magnetic resonance image of the temporomandibular joint, Thesis abstract of candidate of medical sciences [in Russian], Moscow, 2001.
- [4] M.A. Dudin, Transarticular osteosynthesis in surgery of the temporomandibular joint, Thesis abstract of candidate of medical sciences [in Russian], Novosibirsk, 1999.
- [5] A.P. Dergilev, Ya.L. Manakova, The radiodiagnostics of damages of temporomandibular joint, Maxillofacial surgery. 1-2 (2005) 77-83.

- [6] P. G. Sysolyatin, A.A. Ilyin, A.P. Dergilev, The classification of diseases and injuries of the temporomandibular joint, Medical book, Publishing house NSMA, N. Novgorod, 2001.