

Conference paper

3-D Incubator Principle in Nikelid-Titanium Porous Plates Hemostasis

E.M. Parfirieva¹, A.O. Ivchenko², O.A. Ivchenko², E.V. Gavrilin², A.I. Chirev², S.V. Bystrov^{2*}, I.O. Savell'ev³, V.E. Gunther^{4,5}

*Corresponding author:

S.V. Bystrov, email:
bystrov@vtomske.ru

¹Tomsk Regional Oncology Center, Tomsk, Russia

²Siberian State Medical University, Department of General Surgery, Tomsk, Russia

³Regional Clinical Hospital, Department of Vascular Surgery, Tomsk, Russia

⁴Tomsk State University, Tomsk, Russia

⁵Research Institute of Medical Materials and Implants with Shape Memory, Tomsk, Russia

Received: 23 March 2017

Accepted: 9 April 2017

Published: 16 July 2017

**Publishing services
provided by Knowledge E**

Copyright © 2017 E.M. Parfirieva et al. This article is distributed under the terms of the [Creative Commons Attribution License](#), which permits unrestricted use and redistribution provided that the original author and source are credited.

Selection and Peer-review under the responsibility of the SMBIM Conference Committee.

Abstract

Biological liquids (blood particularly) imbibe 3-D construction of nikelid-titan porous plates easily. Clot formation takes place in large porous volume, its retraction by fibrin fibers forming and then maturation of connective tissue all together additionally fix the implant in bleeding zone.

1 Introduction

3-D volume porous elements are the most perspective bioconstructions. They have optimal physical and chemical surface characteristics providing initial cell adhesion, large porous volume, adequate pore size and necessary size distribution of pores to stimulate cell proliferation and to improve their viability. Besides, open interrelated porous system for metabolite supply and release required.

3-D incubator principle is the basis of our hemostasis method; it based on unique features of porous and permeable nikelid titanium alloy: cell adhesion in bleeding zone, capillarity, wettability (protein adsorption and platelets activation), clot maturation and its retraction in plate pores with additional implant fixation, bioinertia and durability.

Bleeding is formidable complication; in some cases bleeding is fatal during surgery, in somatic pathology, after injuries and mechanical traumas.

Lack of effective hemostasis methods frequently limits capabilities of surgical treatment and can cause patient's death after massive bleeding during perioperative period.

 OPEN ACCESS

In despite of good compensation and low reaction of human organism after small amount of venous blood loss, bleedings from major veins and venous plexus are more dangerous than arterial bleedings because they lead to venous system hypotension and low heart force. Blood loss profusion depends on such factors as muscular weakness of vein wall, plural anastomoses between veins, blood flow regurgitation, complexity of palpation for damaged vessels identification and possible absence of vessel wall valve system (e.g. in presacral venous plexus).

Features of vessel location in presacral space and lack of functional vein valves determine bleeding profusion and complexity of hemostasis in this zone. Mechanical, biological methods or their combinations are usually used to stop bleeding from presacral venous plexus. However, these methods have disadvantages: low reliability, massive blood loss and long duration of procedure. [1,4-11]. Porous nikelid titanium plates usage provide effective hemostasis, simple technique and short procedure duration.

In this study the idea of hemostatic mechanism during porous nikelid titanium plates usage is revealed and described.

2 Experimental

TiNi-based alloy was made by self-propagating high-temperature synthesis method and was used for porous plate creating. Material selection bases on unique features: it has biological and biochemical tissue compatibility; it is a porous system and easily wetted by fluids that contributes to infiltration of interstitial fluid and erythrocytes. Velocity-ripple effect arises under alternating deformation, that is to say porous-alloy effect similar to pump-effect develops. The fluid is retracted and is pushed. The alloy deforming according to tissue elastic reaction regularity that is important on concave and crooked sacral surface.

The experiment was made on 200-250 g mixed-breed viripotent white rats. Laparotomy was performed under general anesthesia, pelvic peritoneum was dissected below common iliac vessels bifurcation and parallel to rectum on the left side. Tail vein branches were traumatized artificially. 0.8 – 1.2 cm² porous nikelid-titan plate was implanted in new-made bleeding zone after drainage. The plate was pressed to sacral vertebrae for 2-3 min until bleeding stoppage. Rats were eliminated from experiment after 1 day and 1 week that is important for late complication risk estimation.

We made electron microscopy to examine surface of plate; plate section was examined for tissue filling of pores. We also examine tissue near plate by optical microscopy after its extraction and Harris hematoxylin/eosin coloration. We additionally painted it by Mallory method of coloration to reveal collagen fibers and to evaluate their maturation.

Loose fibrin fibers, agglutinated weak-contoured erythrocytes and fresh erythrocyte mass (because of elimination from rat body) are founded on plate surface and especially in plate pores during electron microscopy to the end of 1 day experiment (Fig. 1).




Fig. 1. Plate surface electron microscopy after 1-day experiment. Fibrin fibers and agglutinated

A small slit-shaped space loosely filled by fibrin, leukocyte and erythrocyte takes a place behind colon between striated muscles (Fig. 2).

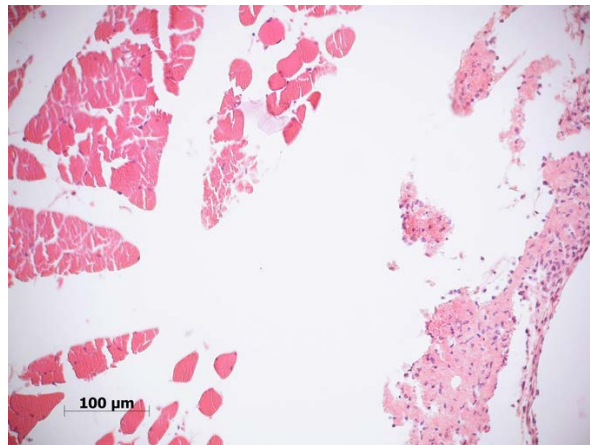


Fig. 2. Pelvic muscles of rat after nikelid-titan porous implant elimination in 1-day experiment. Severe endomysium edema; skeletal muscle dystrophia; the clot is formed on plate surface. Hematoxylin/eosin coloration

Fibrin include pale lilac fine-grained masses and light blue thin weaving fibers in the clot colored by Mallory method (Fig. 3).

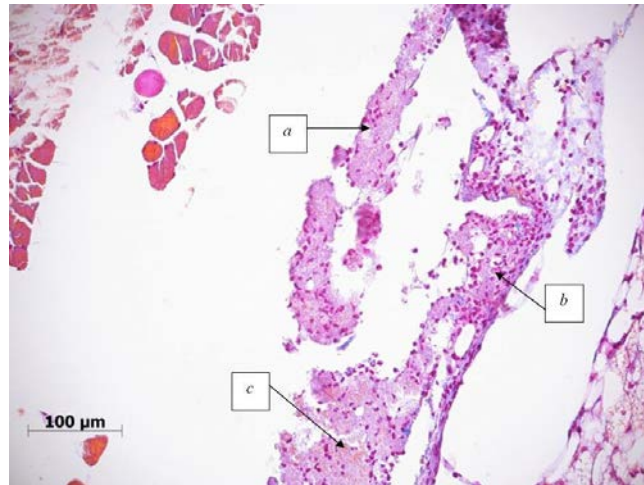


Fig. 3. Pelvic muscles of rat after nikelid-titan porous implant elimination in 1-day experiment. The clot is formed on plate surface. The clot includes fibrin (a), leukocytes (b) and small amount of erythrocytes (c)

There are many polymorphonuclear leukocytes in connective tissue along vessels. (Fig. 4). Their number greater near the clot then in another zones.

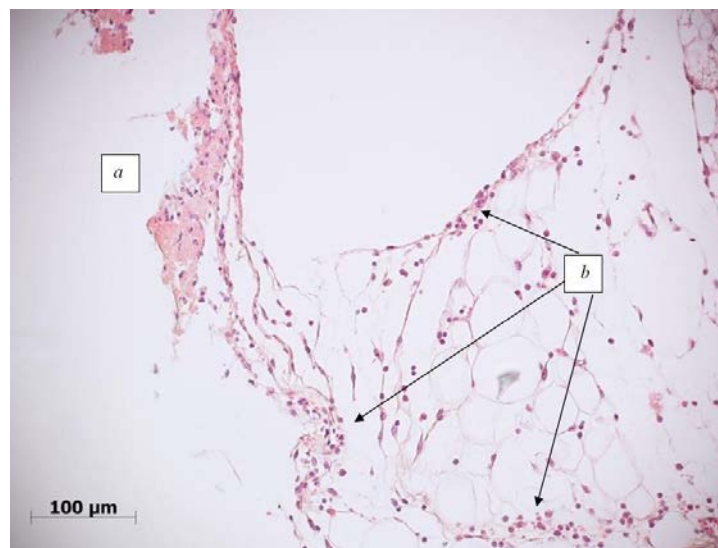


Fig. 4. Pelvic muscles of rat after nikelid-titan porous implant elimination in 1-day experiment. The clot is formed on plate surface (a). Leukocyte infiltrate in loose connective tissue and fat (b). Hematoxylin coloration

Thus, mixed blood clots form in 1 day after procedure in place of implantation. Some inflammation signs like venous stasis (hyperemia) and inflammation infiltrate are observed.

Clot matures to the end of 1 week during severe exudative reaction. Fibrin fibers are thicker and more framed with formless erythrocytes in plate pores (Fig. 5).

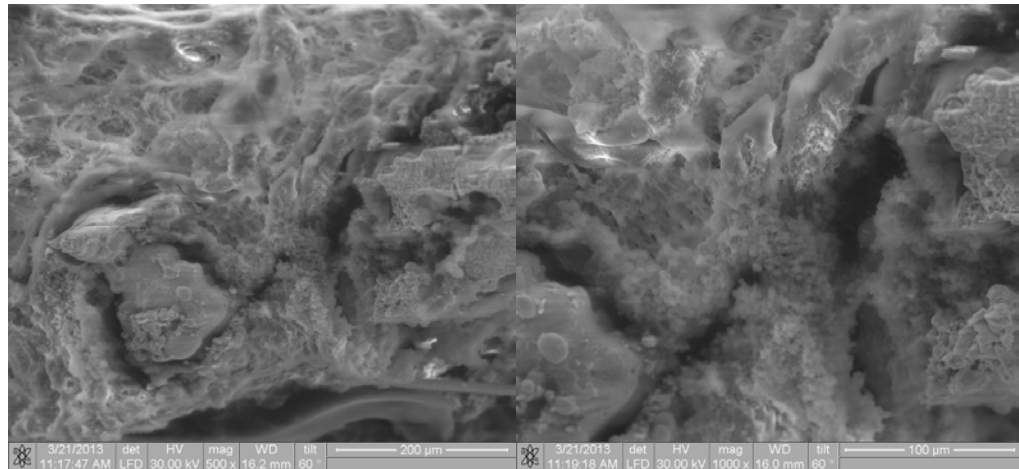


Fig. 5. Plate section electron microscopy in x500 and x1000 zoom after 1-week experiment. Fibrin fibers are more expressed

Changes in clot are also observed; it becomes looser and includes less leukocytes than previously. Fibrin consists from formed weaving fibers. Collagen fibers are observed during Mallory method coloration. (Fig. 6-7).

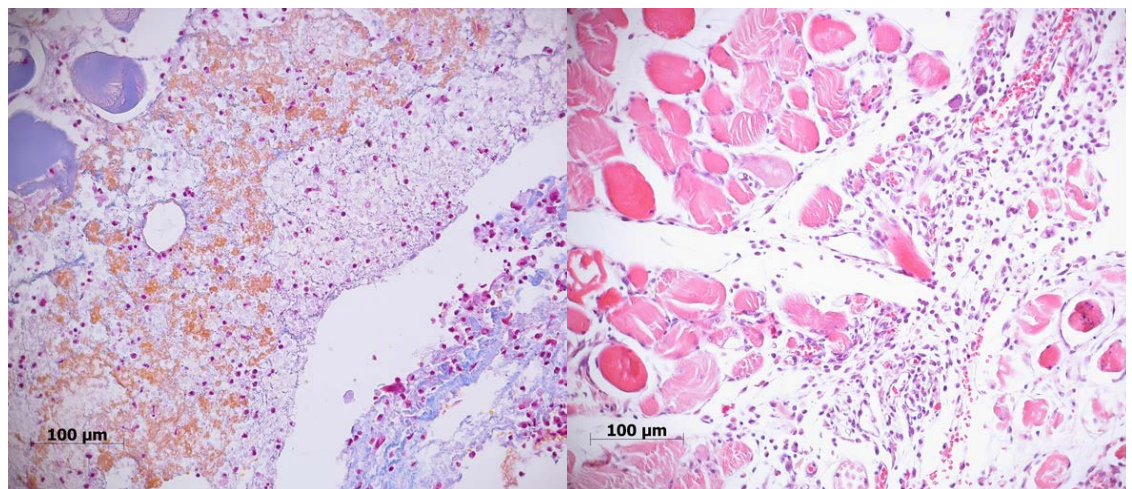


Fig. 6. Pelvic muscles of rat after nikelid-titan porous implant elimination in 7-days experiment. Myofibril lysis, tinctorial features of skeletal muscle sarcoplasm are changed (a), clot retraction (b), collagen fibers in clot (c). Mallory coloration method

Fig. 7. Pelvic muscles of rat after nikelid-titan porous implant elimination in 7-days experiment. New connective tissue grows at implant side from endomysium. Severe leukocyte infiltrate and vessel hyperemia in loose connective tissue. Hematoxylin/eosin coloration

Thus, signs of clot maturation during severe exudative inflammation reaction are observed to the end of 1 week.

3 Summary

Thus, signs of clot maturation during severe exudative inflammation reaction are observed to the end of 1 week.

Considering physical and technical features of material and obtained morphological data after plate implantation in presacral venous plexus bleeding zone, there are some results:

- 1) Nikelid-titan porous material has its own adhesion features.
- 2) The plate is wetted by organism fluids well and allow interstitial fluid and erythrocytes infiltrate fast thanks to controllable size distribution of pores.
- 3) Blood clots form directly in implant porous structure.

Blood clots formed in nikelid-titan implant pores mature in loose fibrin fibers to the end of 1 week after implantation. Because of that, the plate is additionally fixed in bleeding zone and provides reliable hemostasis, decrease late bleeding risk in this zone. Formation of more mature fibrin fibers is observed to the end of 1 week after implantation.

References

- [1] I.A. Tulina, Surgical approach to local colorectal cancer, Author. dis. cand. med. sci. [in Russian], Moscow, 2010, 23.
- [2] O.V. Kokorev, V.N. Hodorenko, Cell integration features depending on volume of nikelid-titanium porous incubators, Shape memory implants [in Russian]. MIC, 1-2 (2012) 50-56.
- [3] V.N. Hodorenko, Yu.F. Yasenchuk., V.E. Gunther, Biocompatible porous permeable materials, Bio-compatible materials and shape memory implants [in Russian], SST, Northampton, Tomsk, 2001.
- [4] A.I. Abelevich, G.A. Seropjan, E.N. Pacenker, Intraoperative profuse bleeding from sacral veins stoppage during rectal extirpation [in Russian]. StateMedicalAcademy Publ., Nizhny Novgorod, 1999.
- [5] JP Barras, T. Fellmann, Massive hemorrhage from presacral veins during resection of the rectum, *Helv Chir Acta.* 59 (1992) 335-339.
- [6] AD Hill, N. Menzies-Gov, A. Darzi, Methods of controlling presacral bleeding, *J Am Col Surgery.* 178 (1994)183-184.
- [7] George M. Filippakis, Manolis Leandros, Kostas Albanopoulos, Michael Genetzakis, et al., Use of Spray Electrocautery to Control Presacral Bleeding: A Report of Four Cases, *The American Surgeon.* 73 (2007) 410-413.
- [8] P. Baque, B. Karimdjee, A. Iannelli, E. Benizri, A. Rahili, D. Benchimol, Anatomy of the presacral venous plexus: implications for rectal surgery, *Surg Radiol Anal,* 26 (2004) 355-358.
- [9] M. Flynn, A. Romero ,C. Amundsen ,A. Weidner, Vascular anatomy of the presacral space: a fresh tissue cadaver dissection, *J Obstetry&Gynecology,* 15 (2005) 1150-1155.

- [10] J.L. Harrison, V.H. Hooks, R.K. Pearl, Muscle fragment welding for control of massive presacral bleeding during rectal mobilization, *Journal Diseases of the Colon&Rectum*, 46 (2003) 1115-1117.
- [11] V.M. Stolfi, J.W. Milsom, I.C. Lavery, J.R. Oakley, J.M. Church, V.W. Fazio, Newly designed occluder pin for presacral hemorrhage, *Journal Diseases of the Colon&Rectum*, 35(1992) 166-169.