

Conference paper

A New Method for Non-Invasive Surgery in Ophthalmology

A.N. Steblyuk^{1*}, V.E. Gunther^{2,3}, V.N. Bodnia⁴, R.A. Avakimyan¹, A.A. Tserkovnaya⁵

*Corresponding author:

A.N. Steblyuk email:
office@okocentr.ru

Received: 23 March 2017

Accepted: 9 April 2017

Published: 16 July 2017

Publishing services
provided by Knowledge E

Copyright © 2017 A.N. Steblyuk et al. This article is distributed under the terms of the [Creative Commons Attribution License](#), which permits unrestricted use and redistribution provided that the original author and source are credited.

Selection and Peer-review under the responsibility of the SMBIM Conference Committee.

 OPEN ACCESS

¹Krasnodar Branch of Federal State Independent Institution "Interbranch Scientific and Technical Complex "Eye Microsurgery" named after Academician S. N. Fedorov, Krasnodar, Russia

²Tomsk State University, Tomsk, Russia

³Research Institute of Medical Materials and Implants with Shape Memory, Tomsk, Russia

⁴State-Financed Educational Institution of the Higher Professional Education "Kuban State Medical University", Krasnodar, Russia

⁵State-Financed Health Institution "Clinical Oncologic Dispensary No.1", Tomsk, Russia

1 Introduction

Eyelid skin neoplasms make more than 80% of vision organ tumors. Patients were aged from 1 to 80 years and older. Tumors of epithelial genesis prevail up to 67%. The annual disease incidence of vision organ tumors by the total number of admitted patients makes 100-120 per 1 million of population [4]. Malignant skin neoplasm is one of the most common oncological diseases. In Russia, the incidence growth is 2-8% per year, and there are annually from 40.5 to 53 thousand new cases of the disease. Skin cancer mainly affects the head area (facial part), therefore, while selecting the treatment tactics, not just a medical but a cosmetic outcome shall be considered. Surgery, radiation therapy and combined treatment used for skin cancer are not always successful. The partial effect may be caused both by insufficient radicalism of intervention due to the risk of injury to surrounding healthy organs and tissues, and by location of the malignant tumor on an uneven surface where the uniform distribution of radiation doses is difficult to be achieved, in particular, in eye appendages (eyeball, eye angle, eyelids). The urgency of the issue of malignant skin tumors in eye adnexa is determined by a

high proportion (up to 70-80%) in the structure of malignant eye neoplasms. The most commonly diagnosed cases are basal cell, metatypical, squamous cell carcinoma, meibomian gland adenocarcinoma and skin melanoma. The traditional surgical and radiation treatment often eliminates the possibility of preserving the lacrimal and protective eyelid functions, and the frequency of relapse after the above methods ranges from 3% to 40%. Cryosurgery based on the destructive effect of low temperatures on biological tissue [1, 2] is the treatment of choice in head skin cancer treatment, including the eyelids.

Therefore, the study objective was examination of cryodestruction use possibilities for pathological eyelid and conjunctiva formations, including treatment of patients with primary malignant tumors of eye adnexa T₁NoMo – T₂NoMo (Stages I-II) with an autonomous cryoprobe from porous and permeable nickelid titanium (TiNi) as an alternative to radiation and surgical treatments.

2 Experimental

For cryotherapy the tool was used with the cryonidal operating component executed as a porous TiNi rod with the tip diameter 2-3 mm with the preset through porosity and the appropriate pore structure. The probes are manufactured in various shapes and sizes, with various configurations of its operating component. They are suitable for use in high-sensitivity area of eye appendages, without impairing the eyeball functions. It is also contributed by probe's low weight and small size. The operational contact surface is smoothly honed with preservation of fine pores for nitrogen direct contact with the biological substrate exposed to cryotherapy. The porous TiNi instrument being filled with liquid nitrogen keeps the temperature close to the nitrogen boiling point (up to -200°C) for 1-1.5 minutes, and during this period, the effect of cryosurgical procedures is the highest. The tool has been developed in the Scientific Research Institute (SRI) of Medical Materials and Shape Memory Implants at Siberian Physical-Technical Institute at TomskStateUniversity (Tomsk).

The objects of the clinical study were 78 patients with pathological eyelid and conjunctiva tumors (papilloma, granuloma, atheroma, xanthelasmachalazion, contagiosumepitheliale, retentional cyst, nevus), including malignant eye appendages neoplasms: basal cell and squamous cell carcinomas, meibomian gland adenocarcinoma subjected to local hypothermia with an autonomous porous-permeable TiNi probe after histological cancer confirmation. 35 men and 43 women

aged from 19 to 73 years were observed. The anamnesis was collected from all patients detailing the circumstances of disease occurrence, previous treatments, including surgical, their complications and underlying eye diseases. All patients underwent a comprehensive ophthalmic examination. Cryotherapy was performed on the Carl Zeiss slit lamp (Germany) on an outpatient basis. The micro tools comprised a sterile anatomical tweezers, an autonomous porous-permeable TiNi cryoprobe adapted to work on eye appendages and the Dewar camera filled with liquid nitrogen. Cryoinstrument sterilization was performed on the day of surgery in STERRAD® NX system (USA) and subsequent liquid nitrogen application. The postoperative visual examination was performed the next day and after 2-3 weeks after surgery. Photodynamic observation was conducted on a Topcon photo-slit lamp (Japan) facilitated with a computer system unit and specialized software.

3 Results and discussion

The main task in preventing the growth of pathological local eyelid and conjunctiva formations, including malignant tumors, is the active detection and treatment of patients at early disease stages with small amounts of pathologically changed tissues. The most successful treatment method under such conditions is a non-invasive cryogenic intervention with an autonomous porous-permeable TiNi probe, despite the high level of microsurgical equipment facilitation in ophthalmology. Pathophysiological mechanisms of extremely low temperatures effect on tissues have been examined quite thoroughly. Certain effects have been revealed: anesthesia, adhesion, destruction, temporary or final arrest of bleeding, stimulation, and repair. However, clinical use of local freezing in ophthalmology still leaves something to be desired. So far, the main development directions of cryogenic method for eye diseases are of great current interest. It assumed development of innovative cryo equipment, development of cryotherapy methods and eye disease cryosurgery, identification of indications and contraindications for this treatment. Liquid nitrogen is regarded as the best liquid cryo agent in modern cryology. It is a transparent, colorless and odorless liquid, non-toxic, and non-flammable, non-reactive to biological tissues. It is remarkable for easy storage: it can be stored in Dewar's vessel. Liquid nitrogen is sterile, it fully meets the requirements for medical purpose refrigerants. Besides, both high (30°C – 60°C) and low temperatures (196°C – 200°C) can be obtained making it universal for use

in combination with cryo-instruments in various medicine areas. The principles in devices cooled with liquid nitrogen are different, and there are several groups of cryogenic equipment. Some are cold-accumulating due to their cooling in the refrigerant (passive cryoprobes), some devices make a single unit with Dewar's vessel in which the refrigerant liquid is supplied to the tip by gravity or by pumping out the vapors. Besides, there are devices with refrigerant supply from an exterior container under an excess pressure. The main cryology achievement over the last decade was new-generation cryogenic system developed in the SRI) of Medical Materials and Shape Memory Implants (Russia). These systems comprise the refrigerant directly inside the porous-permeable operational part, and do not require any additional flow of liquid nitrogen, they have substantial benefits and they are better adapted for work in eye appendages. The TiNi material is inert to tissues, rust or corrosion. The alloy of which the probe has been manufactured has a controlled porosity of 30-70%, with 60-100 microns pore size and a high permeability percentage enabling refrigerant absorption and subsequent evaporation with maintaining of its cryogenic properties throughout the evaporation period. The cryotherapy result while using a porous-permeable TiNicyroprobe is made up of effect of operating with chilled metal and with directly evaporating liquid nitrogen comprised in its pores resulting in obtaining a very low "nitrogen" temperature on the object surface with 3 mm freezing depth. Thus, TiNi probes do not stick to tissues, and there is no an additional mechanical tissue injury and the mechanism of reparative processes in cryo destruction area is characterized by an accelerated regeneration [3, 5].

After impact with cryo probe on tissues, there are changes occurring in them: an edema and swelling are formed after a few minutes and enlarge within 1-2 days. Pathological formations grow in size; bulgings with transparent, yellowish or rosy liquid can be formed. Vesicles should not be opened up. Hygienic activities need to be performed not making any harm to progressing of the local aseptic inflammatory reaction. The cryosurgical impact procedure is performed under a local anesthesia with 1-2 instillations with 0.4% incoaine solution. The period of cryotherapeutic impact on the tumor is about 38-45 seconds. After thawing the frozen area after 2 minutes, the cryothermic procedure is repeated with the same mode of exposure. If necessary, cryoapplication is repeated after 3 weeks. The recovery is identified after 1.5 months (Fig.1, 2).

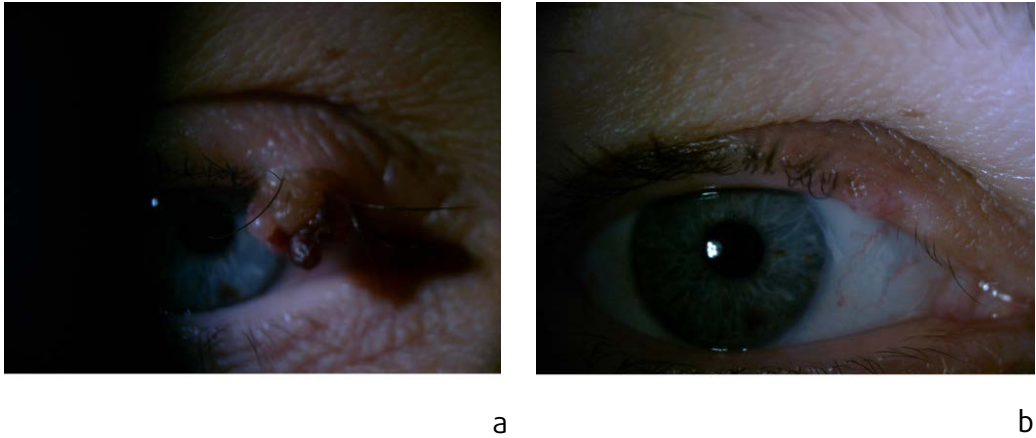


Fig.1. Patient G., aged 56: a – epithelial formation in eyelid margin on Day 5 after cryodestruction; b – eyelid margin condition 1.5 month since cryodestruction

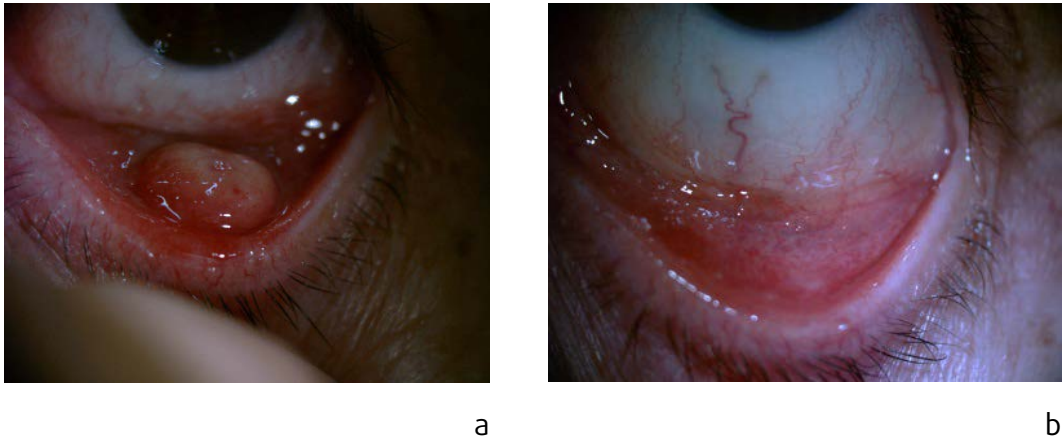


Fig.2. Patient P., aged 63:a – adenocarcinoma of meibomean gland; b – lower lid surface 2 months after cryosurgical treatment

4 Summary

Thus, the possibility of bloodless intervention in sensitive skin areas and the sparing properties of cryotherapy have been confirmed in treatment of eyelid and conjunctiva pathological formations in patients, including malignant eye appendage tumors at early disease stages with use of an autonomous porous-permeable TiNicyroprobe adapted for ophthalmology.

References



- [1] A.F. Brovkina, Ophthalmology [in Russian], Medicina, Moscow, 2002.
- [2] A.S. Buyko, V.A. Elagina, I.A. Safronenkova et al., Medical Cryology [in Russian]. 4 (2003) 51-54.
- [3] I.V. Zapuskalov, V.E. Gyunther, A.N. Steblyuk et al., Medical materials and implants with shape memor. Implants with shape memory in ophthalmology [in Russian], Publ. House "NPP MITS", Tomsk, 2012.
- [4] V.G. Kopaeva, Eye diseases [in Russian], Medicina, Moscow, 2002.
- [5] D.D. Miller, V.E. Gyunther, G.Ts. Dambaev et al., Medical materials and implants with shape memory. Porous-permeable nickelid titanium cryoprobes in medicine [in Russian], Publ. House "NPP MITS", Tomsk, 2010.