



Conference Paper

Design & Manufacturing of Implant for reconstructive surgery: A Case Study

A Manmadhachary^{1*}, Malyala Santosh Kumar², Y Ravi Kumar²,
M Haranadha Reddy³, and Alwala Adityamohan³

¹Department of Mechanical Engineering, Faculty of Science and Technology, ICFAI University, Hyderabad, Telangana, India

²Department of Mechanical Engineering, National Institute of Technology, Warangal, Telangana, India

³Department of oral & maxillofacial surgery, Panineeya Institute of Dental Science & Research Centre, Hyderabad, Telangana, India

Abstract

Additive Manufacturing (AM), also known as 3D printing is an emerging technology in oral & maxillofacial surgery with respect to reconstructive bone surgery. Such treatment protocols often require customized implants to fulfill the functional and aesthetic requirements. Currently, such customized implants are being manufactured using AM technology. This paper describes a mandible defect of oral & maxillofacial surgery. The fracture and defect of the mandible inferior border is one of the serious complications during alignment and fixing of the implant. Reconstruction of such defects is daunting tasks. The case report describes a method based on Computer Aided Design (CAD) and AM for individual design, fabrication and implantation of a mandible inferior border. A 40-year old male meet an accident with rash drive. The patient specific customized implant is designed with patient Computed Tomography (CT) data. The CT images in Digital Imaging and Communication in Medicine (DICOM) file format is used to develop a 3D CAD model of customized implant. The implant is designed to maintain the symmetry of mandible from right to left. The designed implant model is manufactured by Fused Deposition Modelling (FDM) techniques with a biocompatible material. The patient mandible prototype model was manufactured by AM process, which is helpful for pre-planning of surgical procedures. For these pre-planning surgical procedures, a perfect fit obtained during surgery. The patient ultimately regained reasonable mandible contour and appearance of the face.

Keywords: Additive Manufacturing, 3D printing, Oral & maxillofacial surgery, Reconstructive surgery, Patient specific implants

Corresponding Author: A
Manmadhachary; email:
manmadhachary@gmail.com

Academic Editor: Paul K.
Collins

Received: 28 November 2016
Accepted: 4 December 2016
Published: 9 February 2017

Publishing services provided
by Knowledge E

© 2017 A Manmadhachary et
al. This article is distributed
under the terms of the
[Creative Commons Attribution
License](#), which permits
unrestricted use and
redistribution provided that
the original author and source
are credited.

Selection and Peer-review
under the responsibility of the
DesTech Conference
Committee.

OPEN ACCESS

1 Introduction

Additive Manufacturing (AM), also known as 3D printing is a process of joining materials to create physical models from virtual 3-Dimensional (3D) Computer Aided Design (CAD) data [1]. The AM medical applications range from non-custom, off-the-shelf

implants to custom models for surgical planning, custom implants, prosthetics, personalized instruments for surgical procedures and scaffolds for Bioengineering [2]. AM medical models are applicable in the various medical fields such as dental surgery, reconstructive surgery and orthopedic surgery [3]. Especially in oral and maxillofacial surgery the bone reconstruction is done with the help of AM medical models [4].

In oral & maxillofacial surgery involving the treatment of facial asymmetry, accurate positioning of the bone fragments can be a technical challenge. In maxilla and mandibular asymmetric correction is a big challenging task for surgeons. This is not possible in the mid to visual comparison between the asymmetric bone and normal side with traditional pre surgical models. Design and manufacturing of patient specific reconstructive surgical implants is a big task for engineers to get symmetric and correction of the maxilla and mandible. The ability to transform CT data into three-dimensional models using AM models and more recently the use of simulation software, have enabled surgeons to plan osteotomies and distraction osteogenesis in three dimensions and to adapt osteosynthesis plates prior to surgery [5,6].

It is now also possible to create and manufacture a physical model and patient specific implant from a CT scan with AM techniques. An alternative approach to the problem of accurate positioning of osteotomised bony segments has been the application of intraoperative navigation techniques. This paper describes a simple and reliable technique for positioning the mandible inferior border bone in the treatment of reconstructive surgery using computer assisted surgical simulation and AM technology.

2 Methodology

A 40-year old male (Ramalingam) meet an accident with rash drive. During the accident, his mandible was divided into two pieces from left to right. Also right side of the patient's mandible inferior border was crushed. Due to this reason his face was undergone mandible angle reduction reported with deviated mouth, collapse the aesthetic view of his right side face, it is shown in Fig. 1. These problems were solved by adding of the inferior border with implantation procedure. This patient was treated in the Department of oral & maxillofacial Surgery, Panineeya Institute of Dental Science & Research Centre, Hyderabad, India, from March 2016 to September 2016. Surgical reductions were performed less than 3 months after injury.

2.1 Data collection and processing

The patient, transverse, coronal, and sagittal CT data of the maxilla and mandible region were obtained by 64 slice spiral CT scanner (Light Speed VCT, GE Medical Systems). The patient anatomy was scanned with tube voltage 80 kV, tube current 500 mA and pitch 1.34. The scanning was configured as 64 detectors, each detector has 0.625 mm

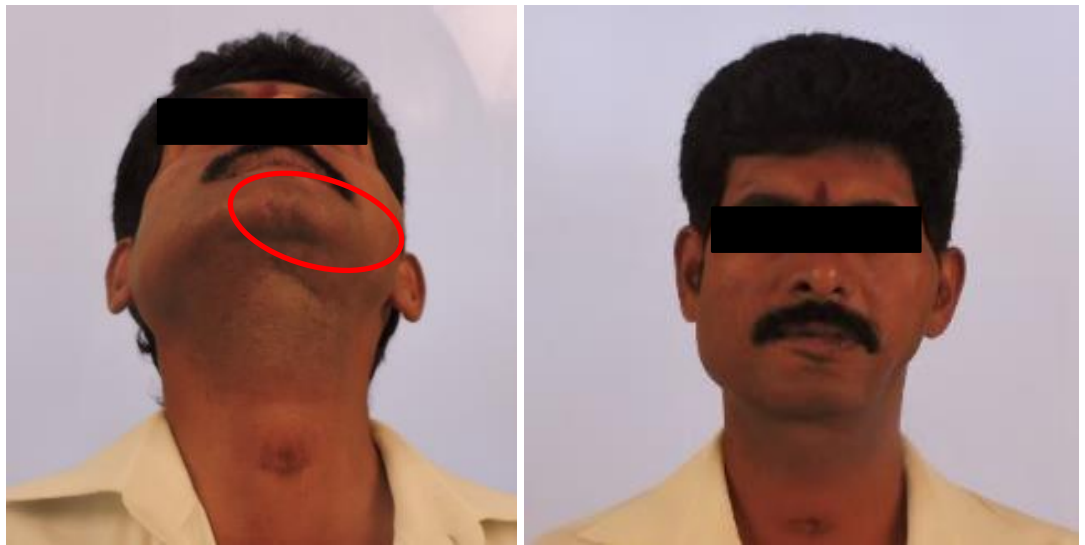

Figure 1: A PREOPERATIVE AESTHETIC VIEW OF THE PATIENT. NOTE THE FACIAL ASYMMETRY.

collimation width and the rotation time of the gantry has been set as 0.4 sec. This CT images were reconstructed with slice thickness 0.625 mm, slice increment 0.3 mm and FOV 250 mm. CT data were then transferred into Digital Imaging and Communications in Medicine (DICOM) images. These DICOM images are used to develop the 3D CAD models.

2.2 Design an Implant

The CT image in the DICOM file format is used to develop a 3D CAD modelling by Materialize Interactive Medical Image Control System (MIMICS) software. Once loaded DICOM images into the MIMICS software, all images were properly registered and aligned for its orientations. Next, the Region of Interest (ROI) was identified and a 3D voxel model of the patient anatomy was made. Using this threshold value, all pixels within this range were collected to a colour mask within the given segmentation level. A region growing technique was applied to form a patient's anatomy of a 3D CAD model, it is shown in Fig. 2 (A).

The mask editing tool allows editing the 3D CAD model in the 2D view. This tool can select and deselect pixels in the 2D view by clicking on applying, these selected pixels are removed from the mask. This tool is helpful when removing scatters. Here the maxilla and scatters at teeth were removed by using 2D mask editing tool. Finally, the 3D CAD mandible model was obtained. This 3D CAD mandible model was separated with symmetric axis by editing tool, it is shown in Fig. 2 (B).

This separated (right side) mandible is used to design an implant by mirror tool. To mirror the part another side of the 3D, here required a mirror plane. The Mimics simulation module generates a default sagittal plane, but adjusts this plane a bit to make

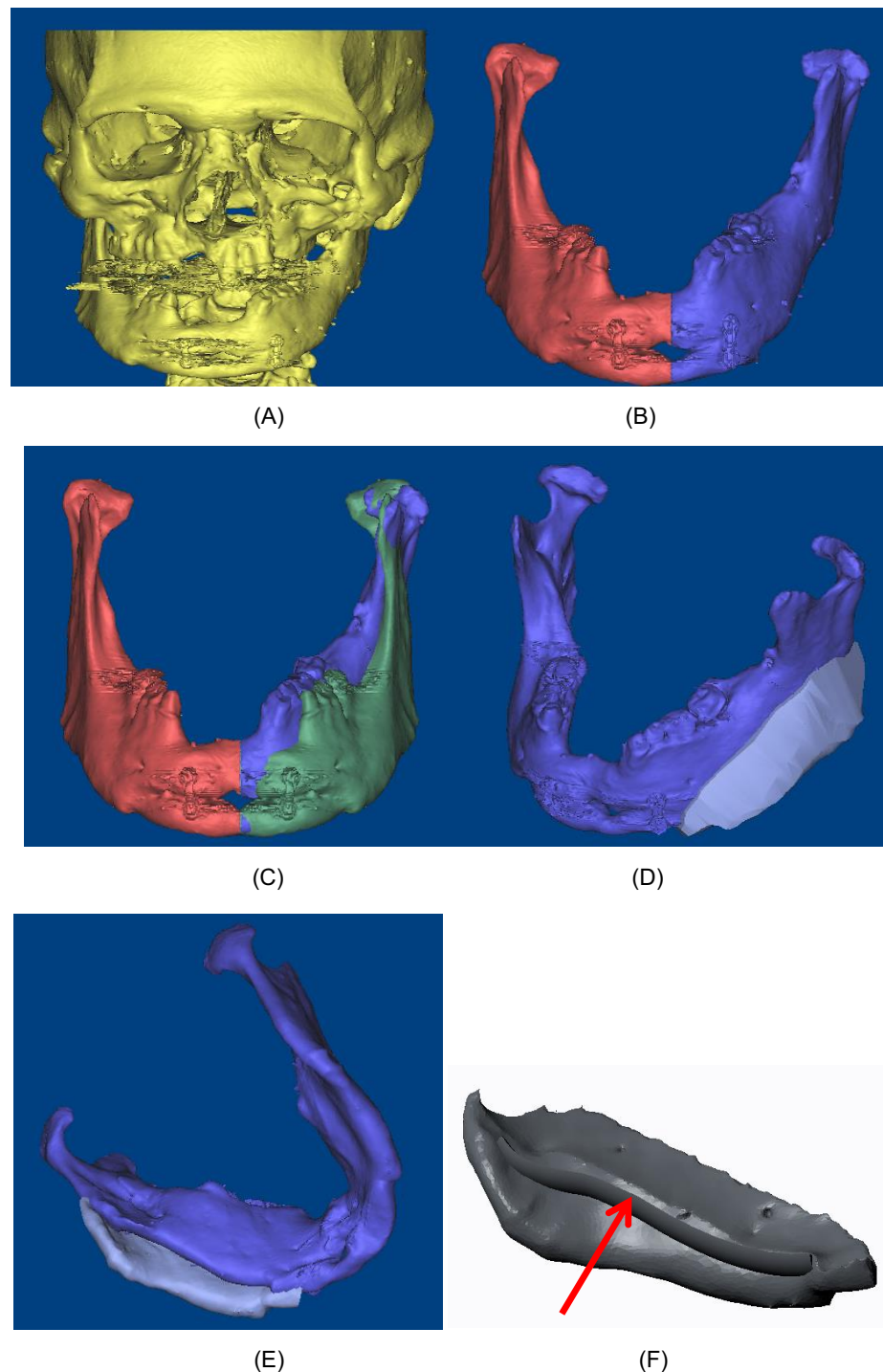


Figure 2: (A) PATIENT ANATOMY 3D CAD MODEL (B) RIGHT SIDE MANDIBLE WAS SEPARATED WITH SYMMETRIC AXIS (C) PATIENT RIGHT SIDE MANDIBLE WAS MIRRORED (GREEN COLOUR) WITH SYMMETRIC AXIS (D) MIRRORED MANDIBLE IS USED FOR IMPLANT DESIGN (E) IMPLANT WAS ALIGNED ON THE MANDIBLE SURFACE (F) THE CURVED PORTION WAS FIXED TO THE IMPLANT

sure it's suitable for this dataset. Using the mirror tool, 3D CT data of the unaffected side were mirrored through the midsagittal plane to build a symmetric counterpart. In

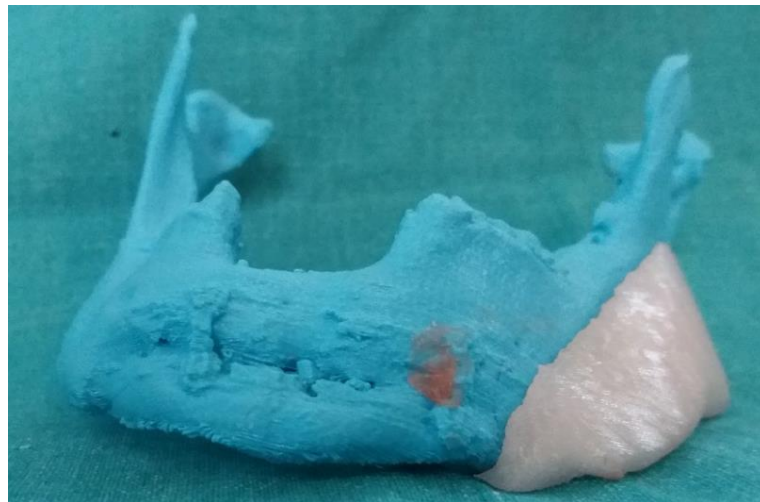


Figure 3: MODEL SURGERY ON AM MEDICAL MODELS.

this way, a bilaterally symmetric 3D mandible model was reconstructed. The mirrored part (green colour) is shown in Fig. 2 (C).

The mirrored green colour mandible was subtracted from original blue colour mandible. Now the subtracted mandible inner surface was exactly aligned on the top surface of the original mandible so the implant will be fixed exactly on the patient mandible surface. Further the subtracted portion of thickness was reduced from bottom to top for providing curve linear shape and uniform surface on a mandible body area, it is shown in Fig. 2 (D). After the accident, patient right side mandible inferior border was pushed towards the inner side, so the patient right side inferior border of the mandible was less compared to the left side. The designed implant CAD model was improved the fracture and defect of the mandible inferior border, it is shown in Fig. 2 (E). Further a smoothed curve was fixed (Fig, 2 (F)) on designing an implant 3D CAD model to easily fixation of the implant with mandible inferior border. Finally the designed implant is maintained the symmetry and improved the inferior border of mandible from right to left.

The 3D CAD models of mandible and designed implant were converted into an STL file for manufacturing of AM medical models. STL represents a 3D solid model as boundary model, constructed by triangular facets. It is a neutral file format for all AM manufacturing process.

2.3 Manufacture of the AM models

In this case study, manufactured a patient mandible with FDM Dimension SST 768 machine with Acrylonitrile butadiene styrene (ABS) plastic, It is shown in Fig. 3 with green colour. The designed implant model is manufactured with FDM Fortus 900mc machine by a bio-compatible PC-ISO material, It is shown in Fig. 3 with white colour. FDM printers

take the form of filaments, which are unwound from a coil and fed through an extrusion nozzle. The nozzle melts the filaments and extrudes them onto a base. Both the nozzle and the base are controlled by a computer that translates the dimensions of an object into X, Y and Z coordinates for the nozzle and base to follow during printing. The controlled extrusion head deposits very thin layer of material onto the base to form the first layer with slicing information. After the base lowers by the lead screw mechanism, the extrusion head deposits a second layer upon the first. This process continues till the end of the AM medical model.

2.4 Model surgery:-

Model surgery was performed on the original mandible AM model (Fig. 3) before the operation. The osteotomy, reduction and fixation, displacement of the fractured segment, and reconstruction of the facial contour were all simulated to ensure a better surgical outcome. In this patient's mandible and implants were placed across the mandible inferior border. Rigid fixation can be achieved using this AM technique. The implant was placed across the inferior border and shaped carefully according to the contour of the fractured ends.

2.5 Operation method:-

The AM manufactured implant was immersed in povidone iodine solution for 8 hours for sterilization. After fully exposing the mandible bony segments, the implant was placed near the surgical area, it is shown in Fig. 4 (A). The surgeons could observe the reduction of the bony segments and the positioning of the implant by the shape and position of the reduced bony segments. The AM manufactured implant was well with the mandible inferior border, then fixing the implant with Titanium screws, it is shown in Fig. 4 (B).

3 Results and Conclusions

The operation was straightforward and quick, with no intraoperative complications. AM medical models are helpful for preplanning of surgical procedures. For these preplanning surgical procedures a perfect fit obtained during surgery. The outcome of surgical reduction of mandible fractures can be objectively evaluated by comparing pre- and postoperative fracture displacement. Surgeons can more clearly observe bony structures before the operation and shape of the implant. Mandible reconstruction was facilitated using the CAD and AM technique with satisfactory aesthetic results. The patient specific models were used in patient intra operatively without the need for any further bone grafting, so reduces the operating time and increase the safety of surgery.

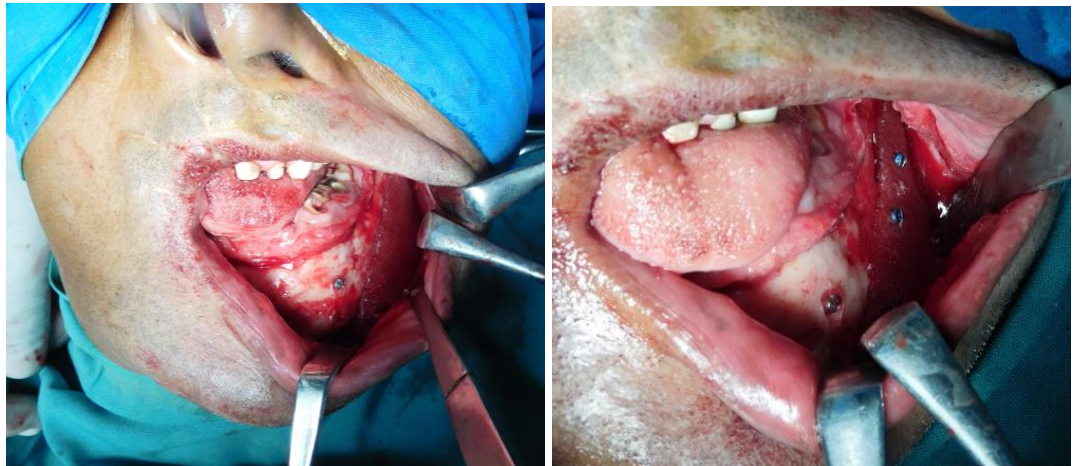


Figure 4: FIXING OF IMPLANT ON MANDIBLE SURFACE.

In this case study, the patient ultimately regained reasonable mandible contour and appearance of the face.

References

- [1] ASTM F2792-12a, Standard Terminology for Additive Manufacturing Technologies, ASTM International, West Conshohocken, PA, 2012.
- [2] T. T. Wohler, Additive Manufacturing and 3D Printing State of the Industry, Annual Worldwide Progress Report, Wohlers Associates, Colorado, USA, 2103.
- [3] M. J. C. Mamoru, B. Paulo, F. Dirk, J. S. Albert, R. Kamlakar, and S. Naohiko, Bio-manufacturing, *CIRP Annals - Manufacturing Technology*, **62**, 585–606, (2013), 10.1016/j.cirp.2013.05.001.
- [4] F. G. Elisabet, W. Jan, and K. N. Jenneke, Application of Additive Manufacturing in Oral and Maxillofacial Surgery, *Journal of Oral and Maxillofacial Surgery*, 1–11, (2015).
- [5] Z. Li-bin, S. Hong-tao, H. Li-sheng, B. Bin, L. Gui-cai, L. Yan-pu, and Z. Li-bin, Accurate Reconstruction of Discontinuous Mandible Using a Reverse Engineering/Computer-Aided Design/Rapid Prototyping Technique: A Preliminary Clinical Study, *Journal of Oral and Maxillofacial Surgery*, **68**, 2115–2121, (2010), 10.1016/j.joms.2009.09.033.
- [6] H. Jin-Song Hou, M. Chen, P. Chao-Bin, T. Qian, W. Jian-Guang, and W. Cheng Wang, Immediate Reconstruction of Bilateral Mandible Defects: Management Based on Computer-Aided Design/Computer-Aided Manufacturing Rapid Prototyping Technology in Combination with Vascularized Fibular Osteomyocutaneous Flap, *Journal of Oral and Maxillofacial Surgery*, **69**, 1792–1797, (2011), 10.1016/j.joms.2010.07.047.