

Conference Paper

Acute Toxicity Tests of Alkaloid Pare (*Momordica Charanthia*) Fruit on The Histopathology of Liver

Wurlina¹, Dewa Ketut Meles², Sunarni Zakaria³, Imam Mustofa⁴, Suherni Susilowati⁵, and I Dewa Putu Anom Adnyana⁶

^{1,2,4,5}Veterinary Medicine Faculty of Universitas Airlangga

³Medicine Faculty of Universitas Airlangga

⁶Veterinary Medicine Faculty of Universitas Brawijaya

Abstract

Pare fruit (*Momordica charanthia*) potential as an antidiabetic. In preliminary research has proven that alkaloid of the Pare fruit (*Momordica charanthia*) can lower blood sugar levels of mice suffering from diabetes mellitus. Alkaloid Pare can improve pancreatic β -cell function by improving the preparation phase for the cell dividing (interphase) and repair the mitotic stages and increase the CDK expression in mice with diabetes mellitus. The purpose of this research was to determine the dose that causes the death of 50% (LD₅₀) and to determine the toxicity effect of alkaloid Pare (*Momordica charanthia*) against damage in the form of congestion, degeneration, and necrosis of liver cells. Acute toxicity test with a 24-hour long treatment using 60 female mice, divided into six groups, each group consisted of 10 animals. The group is as follows: Po only given distilled water, the group P1, P2, P3, P4 and P5 respectively treated 0.3 g/kg bw, 1 g/kg bw, 3 g/kg bw, 10 g/kg bw and 15 g/kg bw. Furthermore, all the mice were necropsied to take the liver for histopathology preparations to observe the occurrence of congestion, degeneration, and necrosis. The parameters observed through histopathological examination of the liver include congestion, degeneration, and necrosis. The results of the research tested by Kruskal-Wallis test with data obtained based on the value of scoring was not significantly different ($\alpha < 0.05$) in the liver histopathological changes in the form of congestion, degeneration, and necrosis between control and treatment groups orally in time 24 hours. The dose can cause 50% of deaths more than 15 g in mice are included in the category of medicinal substances which are not harmful.

Keywords: Alkaloid Pare fruit, LD₅₀, congestion, degeneration, necrosis, liver.

Corresponding Author:

Wurlina

wurlina@fkh.unair.ac.id

Received: 03 October 2017

Accepted: 10 October 2017

Published: 29 November 2017

Publishing services provided
by Knowledge E

© Wurlina et al. This article is distributed under the terms of the [Creative Commons Attribution License](#), which permits unrestricted use and redistribution provided that the original author and source are credited.

Selection and Peer-review under the responsibility of the VMIC Conference Committee.

OPEN ACCESS

1. Introduction

Pare fruit contains ribosome-inactivating proteins, rosmarinic acid, rubixanthin, spinasterol, steroidal glycosides, stigmata-diols, stigmasterol, taraxerol, trehalose, trypsin inhibitors, uracil, vaccine, v-insulin, verbascoside, vicine, zeatin, zeatin riboside, zeaxanthin, and zeinoxanthin. Pare fruit contains carbohydrates, momordicin, protein, vitamins A, B and C, saponins, flavonoids, steroids triterpenoids, folic acid and a number of alkaloids [1]. The content of amino acids in these plants can cause cells undergo mitosis.

Anti-diabetogenic activity may be caused by the content of serine proteases in plants that are mitogenic, which causes cells undergo mitosis. Amino acids and plant enzymes can stimulate protein synthesis by stimulating the polymerization of DNA and transcription of DNA [2]. Plant materials that are mitogenic (stimulate the process of cell mitosis), generally have the ability to unti.e tubulin which is a protein that makes up microtubules by stimulating the polymerization of protein, so that the microtubules can play a role in forming the mitotic threads and processes for cell movement, phagocytosis and transport of food and the metabolism into and out of cells [3, 4].

Acute toxicity tests are mostly designed to determine the median lethal dose (LD₅₀) of a toxicant. Acute toxicity tests may indicate the target organs that may be damaged and the specific toxic effects [5]. Selection of the liver as the target organ may be damaged from the toxic effects of drugs, and this is because the liver has an important role in the metabolism of the body because it has enzymes that can transform harmful substances into substances that are physiologically inactive. The liver is the largest organ of the body's metabolism and functioning in the detoxification process of toxic and non-toxic materials. Acute toxicity tests were done by providing a chemical or a compound that is being tested in a single dose or repeated within a period of not more than 24 hours. This study was designed to determine the median lethal dose (LD₅₀). Certain substances such as herbal medicine ingredients that have low toxicity do not require a determination of the LD₅₀ value appropriately. This test can also indicate the target organs that may be damaged by the toxic effect [5].

2. Materials and Methods

Acute toxicity test to determine the dose that causes the death of 50% (LD₅₀) and to get a safe dose of Pare fruit used for a maximum of 24 hours demonstrated in vivo in 60

TABLE 1: Average changes in the histology of liver cells in mice for 24 hours.

| Treatment | Congestion | Degeneration | Necrosis |
|-----------|---------------------------|---------------------------|---------------------------|
| P0 | 0,05 ^a ± 0,085 | 0,30 ^a ± 0,264 | 0,14 ^a ± 0,189 |
| P1 | 0,04 ^a ± 0,084 | 0,32 ^a ± 0,252 | 0,12 ^a ± 0,252 |
| P2 | 0,05 ^a ± 0,093 | 0,33 ^a ± 0,242 | 0,13 ^a ± 0,250 |
| P3 | 0,04 ^a ± 0,084 | 0,32 ^a ± 0,252 | 0,12 ^a ± 0,252 |
| P4 | 0,05 ^a ± 0,086 | 0,33 ^a ± 0,242 | 0,13 ^a ± 0,233 |
| P5 | 0,04 ^a ± 0,084 | 0,32 ^a ± 0,250 | 0,14 ^a ± 0,242 |

Different superscript in the same column refers to significant difference ($\alpha > 0,05$)

female mice (*Mus musculus*) were divided into six groups, with each group consisting of 10 mice. the groups were as follows:

Control group (P0): The group of mice given only 1 ml bottled water within 24 hours.

Group 1 (P1): The group of mice given alkaloids pares 0.3 g/kg bw within 24 hours.

Group 2 (P2): The group of mice given alkaloids pares 1 g/kg bw within 24 hours

Group 3 (P3): The group of mice given alkaloids pares 3 g/kg bw within 24 hours

Group 4 (P4): The group of mice given alkaloids pares 10 g/kg bw within 24 hours

Group 5 (P5): The group of mice given alkaloids pares 15 g/kg bw within 24 hours.

Observations were made on the occurrence of deaths in each treatment group, and the group of mice that have not shown signs of death, followed by the development of physiological functions of the body such as changes in weight, appetite and the early signs of toxicity such as the presence of diarrhea, nausea, convulsions, asphyxiate within 14 days. After 14 days, all deaths are calculated and determined its LD50 and made the histopathological preparations of the liver as a metabolic organ to determine the degree of cell damage or cell death.

Data histopathological changes of the liver of mice were analyzed using non-parametric statistical tests using Kruskal-Wallis test because the data is obtained based on the value of scoring. When there is a significant difference followed by multiple comparison tests (Z-Test) 5%.

3. Results

The examination results of liver cells histopathology in mice after administration alkaloid Pare fruit (*Momordica charantia*) for 24 hours can be seen in Table 1.

In Table 1, microscopic observation through five fields of view that is different in each liver preparations of mice shows ($\alpha < 0.05$), so there was no significant difference in the histopathological features of liver cells experiencing congestion, degeneration and mild necrosis in the control group and the treatment group. This means that mice given alkaloids Pare with dose of 0.3 g/kg, 1 g/kg, 3 g/kg, 10 g/g and 15 g/kg bw orally within 24 hours of observation, indicating liver cells in normal circumstances, although there is some liver that indicates a change in the form of congestion, degeneration, and mild necrosis.

4. Discussion

Microscopical changes of liver in the form of congestion between control and treatment group given orally within 24 hours was not significantly different ($\alpha > 0.05$). Similarly, the microscopic changes in the form of degeneration and necrosis in the control group with the treatment given orally there was no significant difference ($\alpha > 0.05$). This suggests that the alkaloid Pare in the acute toxicity test does not cause toxic effects on the liver. This is consistent with the statement of Koeman [6] that the liver is the organ that is resistant to the effects of toxic substances. This is because, in addition to having the function of detoxification, the liver also has a large enough regeneration power if there occurs the process of liver cell damage in the form of congestion and degeneration that are reversible. Once absorbed by the liver, toxic substances and ingredients will go into the bloodstream, then detoxified in the liver to form non-toxic and more polar making it easy for excreted.

Damage in the form of congestion in the liver may be caused by a non-material drug such as ether used as an anesthetic before necropsy of mice, so a damming of blood can occur, in the presence of concentrated blood into a blood vessel. According to Price and Wilson [7]. Congestion is a damming of blood or increased volume of blood in the veins dilated due to parasympathetic nerve impulses that cause vasodilatation or the sympathetic nervous obstacles that cause vasoconstriction mechanism constraints on certain body parts. Congestion is a passive process resulting from damage to the vein tissue. Congestion can be systemic such as heart failure or can be local due to venous obstruction so that tissue bluish red color (cyanosis) due to lack of oxygen [8].

Liver damage in the form of degeneration characterized by an empty space in the cytoplasm rounded like a fat droplet formation. According to Maretnowati [9], these changes indicate that when fluid accumulate in the cytoplasm, causing cell organelles in the cytoplasm also absorb the fluid, leading to swelling throughout the cytoplasm.

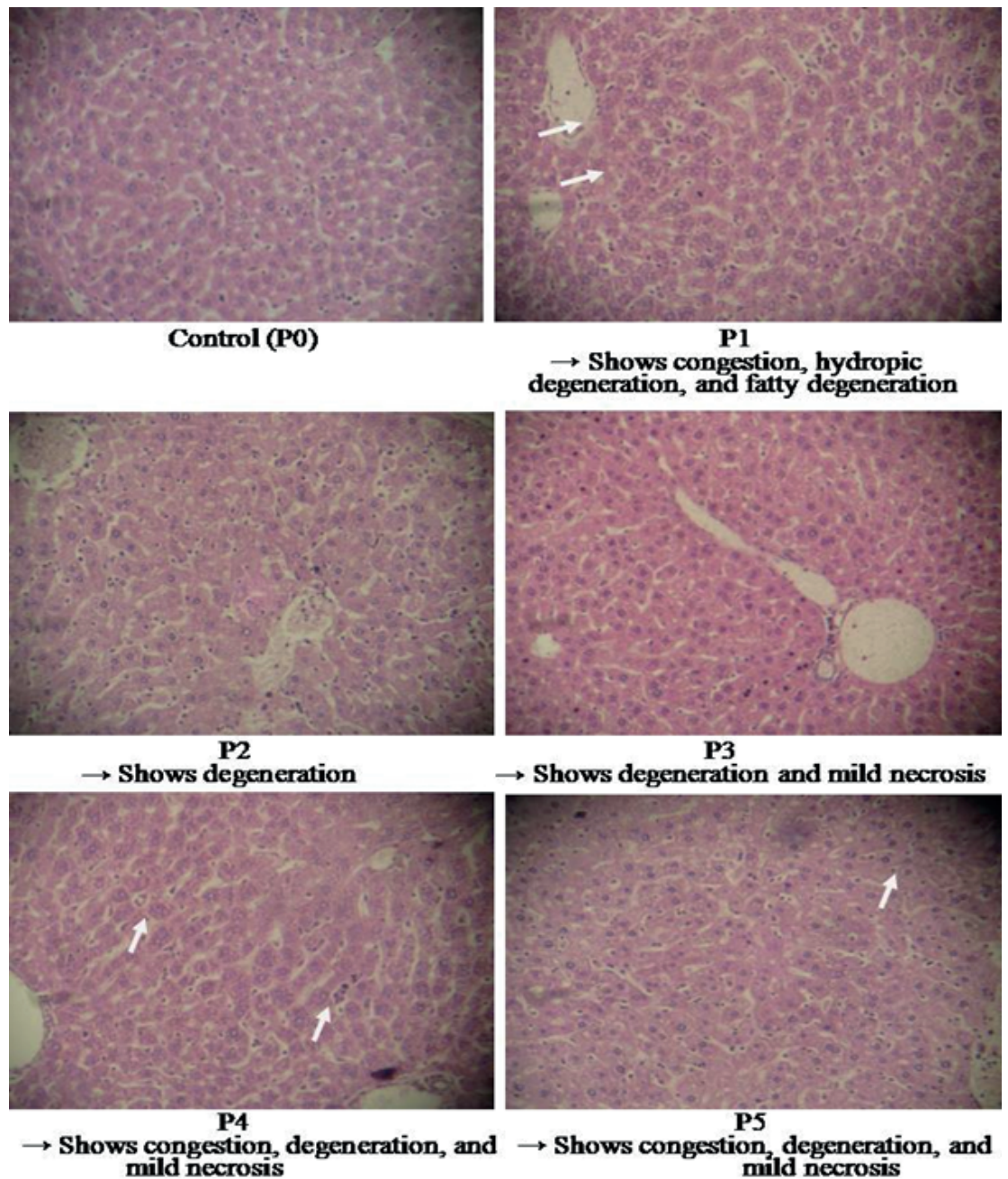


Figure 1: Microscopical appearance of mice liver after the administration of alkaloid Pare fruit within 24 hours.

There are also fat droplets that cover the cell nucleus. This kind of liver damage including fatty degeneration. Cell degeneration is damage that occurs in the cytoplasm but not even damages the cell nucleus so that it can be restored to normal if the cause is removed [7]. Degeneration is generally caused by damage to the mitochondria, and mitochondria have a function as a producer of energy in the cells produced in the form of ATP. If the mitochondria are disrupted, the ATP will be disrupted, so that the cell transfer process impaired as well. One of the most important cells transfer process is

the sodium pump mechanism that is useful to maintain osmotic pressure within the cell. If the mechanism is disturbed, would result in cells incapable of pumping sodium ions out so as to increase the concentration of sodium ions in the cell, causing fluid enter into the cells. Changes in cell swelling microscopically less real and only cause slight enlargement of cells and little change in the composition [8, 10, 14] state that the kind of degeneration according to severity, i.e degeneration turbid (Cloudy swelling) that is a cell swelling by the accumulation of water and metabolites in the cytoplasm that looks cloudy, degeneration hydrophilic that is a cell swelling by accumulation of more water and metabolites which looked vacuoles are formed in the cytoplasm, and fatty degeneration that is a swelling of cells with accumulation of fat in the cytoplasm. Liver damage in the form of necrosis of this research is still in the mild category and is still considered to be within reasonable limits because the liver has the high ability to regenerate cells. Rippey [11] stated that the necrosis of the liver is a dangerous toxic manifestation, but not always critical because the liver has the capacity growth or mechanisms of cell division (mitosis) are very good. The presence of the accumulation of toxic substances interferes the mitochondrial function. Mitochondria functioning to transform nutrients which enter the body either in the form of carbohydrates, proteins or fats into ATP (adenosine triphosphate, carbon dioxide, and water. As a result of disturbances in the function of mitochondria will cause interference with the production of adenosine triphosphate, as well as oxidative phosphorylation so many Na^+ ions that enter the liver cells due to the pH in cells decreased and acidic. Due to the low pH, the activity of the lysosomal and proteolytic enzyme is higher in cells, causing the lysosomal rupture, leading to hydrolytic enzymes out and dissolve the cell. The invisibility of liver cell death depending on the length and type of necrosis. Stages of necrosis include pyknotic, karyorrhexis, and karyolysis. Pycnotic characterized by clotting of chromatin and no longer recognized the nucleolus, the nucleus looks more dense and dark black. Karyorrhexis characterized by damage to the nucleus which it is broken so that the color becomes darker after staining. Karyolysis characterized by a nucleus which began to disappear until unrecognizable microscopically, the cells more elongated shape and color becomes apparent after staining.

From the results of this study can be said that the use of alkaloids Pare (*Momordica charantia*) with large doses is relatively safe. Due to the large doses of 15 g/kg bw proved not to cause death in experimental animals, so included into the class of substances that are not harmful. The changes in the microscopic appearance, i.e congestion, degeneration, and necrosis are still at the stage of mild and reversible if the cause is removed, otherwise, the ren has a high power cell regeneration.

LD₅₀ test of alkaloid Pare (*Momordica charantia*) using a high dose of 15 g/kg is relatively harmless because it does not occur death. [5] states that if large doses did not cause death can be considered that the acute toxicity of the material is low, and the LD₅₀ value do not need to be determined precisely, an approximate figure is already able to benefit. The dose that causes the death of 50% of the experimental animals (LD₅₀) was more than 15 g/kg bw Pare alkaloid. It can be concluded that the alkaloid substance of Pare including drug substance is practically non-toxic, and when used in the form of alkaloids, according to [12] alkaloids Pare included in the harmless drug substance.

5. Conclusion

In the acute toxicity test of alkaloids Pare in mice was not cause significant damage in the form of congestion, degeneration, and necrosis of the liver and ren. Based on the test of LD₅₀ (dose that causes the death of 50% in mice), alkaloids Pare including drug ingredients that are not harmful.

References

- [1] Battelli, M. G., 1996. Toxicity of ribosome-inactivating proteins-containing immunotoxins to a human bladder carcinoma cell line. *Int. J. Cancer*. Feb; 65(4):485-90. *ellimmunol*. Apr; 126(2):278-89.
- [2] Bolognesi, A., 1996. Induction of apoptosis by ribosome-inactivating proteins and related immunotoxins. *Int. J. Cancer*. Nov; 68(3): 349-55.
- [3] Chabner, BA, DP.rian, Las-Ares, R.G. carbonero and P. Calabresi. 2001. Antineoplastic Agents. In Good & Gilman's The Pharmacological Basis of Therapeutics. 10th. Edition. McGraw-Hill. Medical Publishing Division. p.1417-1421.
- [4] Kumar. V., S.R. Cotran., and L.S. Robbins. 2002. Basic Pathology. 7th edition. Independence Square West. Philadelphia USA.
- [5] Loomis, T., 1978. Essential of Toxicology, 3rd edition, Lea & Febringer, Philadelphia, p 195-235.
- [6] Lu, F.C. 1995. Asas, Organ Sasaran, dan Penilaian Resiko (Terjemahan). Edisi II. VI. Press. Jakarta, hal 85-100.
- [7] Maretnowati, N. 2005. Acute Toxicity Test and Sub Acute Ethanol Extract and Water Extract Skin Stem Artocarpus champion Spreng with Liver Histopathology Mice Parameters. Essay. Faculty of Pharmacy. Airlangga University. Surabaya.

- [8] Meles, D.K., Wurlina dan Nian (2009). Kadar gula darah setelah pemberian aloxan pada mencit putih (*Rattus norvegicus*). *Veterinary journal*. Vol.5,no.4 p. 34.
- [9] Price, A.S., and L.M. Wilson. 1995. *Concept Clinical Pathophysiology Disease Processes*. Issue 4. Book Medical Publishers EGC. Jakarta.
- [10] Rippey, J.J. 1994. *General Pathology*. Witwatersrand University Press. Perth Western Australia.
- [11] Adnyana. I.D.P.A. 2006. Anti effect alkaloids Telomerase Fraction Of Cleavage And Mitosis Myeloma Cells of Mice. Faculty of Veterinary Medicine, University of Airlangga. Surabaya.
- [12] Ravi K, B.Ramachandran, and S.Subramanian. 2004. Hypoglycemic Activity of Inorganic Constituents in Eugenia Seed Kernel on Streptozotocin-Induced Diabetes in Rats. *Biol Trace Elem Res*. Summer;99(1-3): 145-155.
- [13] Robbins L.S., Kumar V., S. Ruiz, 2007. *Textbook of Pathology Robbins*, Ed.7, Vol. 2. Interpretation: do. Bram U.P. Book Medical Publishers EGC. Jakarta.
- [14] Thomson, A.D. and R.E. Cotton. 1997. *Pathology Lecture Notes*. Issue 3. Book Medical Publishers EGC. Jakarta.