

Acta Veterinaria (Beograd), Vol. 59, No. 1, 53-68, 2009.

DOI: 10.2298/AVB0901053P

UDK 619:616.348:636.7

**IDIOPATHIC AND SECONDARY ACQUIRED MEGACOLON IN DOGS IS ASSOCIATED WITH DIMINISHED VASOACTIVE INTESTINAL POLYPEPTIDE INNERVATION OF THE AFFECTED COLON**

PROKIĆ B\*, TODOROVIĆ VERA\*\*, DRNDAREVIĆ NEDA\*\*, VIGNJEVIĆ SANJA\*\*, ĐIKIĆ DRAGOSLAVA\*\*, NIKOLIĆ I\*\*\*, MARINKOVIĆ S\*\*\*\* and SLAVIK E\*\*\*\*\*

\*University of Belgrade, Faculty of Veterinary Medicine, Serbia; \*\*University of Belgrade, Institute for Medical Research, Serbia; \*\*\*University of Nish, School of Medicine, Institute of Histology and Embriology, Serbia; \*\*\*\*University of Belgrade, School of Medicine, Institute of Anatomy, Serbia; \*\*\*\*\*Clinical Center of Serbia, Institute of Neurosurgery, Belgrade, Serbia

(Received 14. June 2008)

*It is well established that megacolon in carnivores, including both cats and dogs, is a common finding. Megacolon occurs more often in the cat than the dog. Based on current data idiopathic megacolon is a common cause of constipation in cats (62% of constipated cats are affected by idiopathic megacolon). There is no evidence of idiopathic megacolon in dogs and publications about this disease in this species is very scarce.*

*We investigated the enteric nervous system in the dilated portion (DP) of the colon in dogs with idiopathic acquired (n=7) or secondary acquired megacolon (n=21) and compared the results with a normal colon in control dogs (n=3). Colonic sections of surgical specimens were investigated by conventional and immunohistochemical methods, including pan-neuronal markers (NSE, synaptophysin, and neurofilament) and VIP, as well as S-100 protein for detection of ganglionic glial cells. Compared to controls, the two megacolon groups showed no changes of density of enteric neurons in both submucosal and myenteric nervous plexuses in DP of the colon and of enteric glial cells. However, compared to controls and dogs with secondary megacolon, there was a significant decrease in the density of NFP-ir nerve fibers in the longitudinal muscle layer in dogs with idiopathic acquired megacolon. In addition, dogs with idiopathic megacolon display decreased VIP-ir in the myenteric plexus and lamina propria mucosae, and absence of VIP-ir neurons in the submucosal plexus of DP of the colon. Similar alterations, although of lesser severity, may be found in dogs with secondary acquired megacolon. We consider that both idiopathic and secondary acquired megacolon might occur on the basis of a dysplastic changes of VIP-ir enteric neurons.*

*Key words: dog, ENS, idiopathic/secondary acquired megacolon, VIP*

## INTRODUCTION

The term "megacolon" means an enlarged colon, which may be acute, toxic and chronic. In humans, chronic megacolon may be congenital (due to Hirschsprung's disease) or acquired. Acquired megacolon in children and adults is generally idiopathic or may represent the end-stage of any refractory constipation (slow transit constipation or pelvic floor dysfunction) (Bharucha and Phillips, 1999).

The pathogenesis of idiopathic megacolon has been poorly understood in humans and animals. In particular, it is unknown whether there are abnormalities involving the extrinsic nerves, the enteric nerve plexuses (Gatuso *et al.*, 1998; Iantorno *et al.*, 2007), interstitial cells of Cajal (Lee *et al.*, 2005) or the intestinal smooth muscle (Washabau and Stalis, 1996). Abnormalities of any of these components could lead to gut dilatation and impaired motility (Olsson and Holmgren, 2001). Recently, no evidence was found that a defect of the myenteric plexus is involved in the development of idiopathic megacolon. Namely, idiopathic megacolon is characterized by a complete atrophy of the tendinous fibre net in the muscularis propria, potentially of multifactorial origin (Meier-Ruge *et al.*, 2006).

It is well established that megacolon in carnivores, including both cats and dogs, is a common finding. Megacolon occurs more often in the cat than the dog, but based on some data it is an uncommon cause of constipation in both species generally (Burrows, 1996). However, other studies suggest that 96% of cases of opstipated cats are accounted for by idiopathic megacolon (62%), pelvic canal stenosis (23%), nerve injury (6%) or Manx sacral spinal cord deformity (5%). Fewer cats are accounted for by complication of colopexy (1%) and colonic neuroplasia (1%). In another 2% of cases, colonic hypoganglionosis or aganglionosis was suspected, but not proven. Inflammatory pharmacologic and environmental-behavioral causes were not cited as predisposing factors in any of the original case reports (Washabau and Hasler, 1996).

There is no evidence of idiopathic megacolon in dogs and publications about this disease in the dog are very scarce (Bright *et al.*, 1986; Burrows, 1996). Many domestic cats and dogs affected with megacolon can be managed successfully. Namely, in chronic idiopathic megacolon, medical measures, such as colonic evacuation with enemas, laxatives and the prokinetic drug cisapride may suffice. If severe motor dysfunction is confined to the colon, a subtotal colectomy may occasionally be necessary (Bright *et al.*, 1986; Washabau and Hall, 1997; Bharucha and Phillips, 1999; Snilleabhain *et al.*, 2001).

Colonic enteric nerve plexuses, including VIP innervation, have not yet been characterized in dogs affected with idiopathic megacolon. Therefore, the purpose of our study was to assess several aspects of the enteric nervous system in the affected colon, especially VIP-innervation, in dogs with idiopathic megacolon, and compare these findings with secondary megacolon and controls.

## MATERIAL AND METHODS

*Subjects*

Our prospective study includes 28 dogs which underwent surgery for acquired idiopathic (7/28) or secondary (21/28) megacolon. There are 9 German Shepherd dogs, 5 Rottweilers, 7 Serbian Shepherd dogs, 4 Giant Schnauzers and 3 mixed breed dogs affected with magacolon and three control animals (2 Rottweilers and one mixed breed). Out of 28 animals, there were 21 males (75%) and 7 females (25%), mean age  $7.53 \pm 0.21$  years (range 5-9 years). The control subjects were 2 males and one female, mean age  $6 \pm 0.57$  years (range 5-9 years) (Table 1). Animals were examined and treated at the Faculty of Veterinary Medicine, University of Belgrade, from 1996 to 2005.

Table 1. Breed, sex and age in dogs affected with megacolon and controls

Breed	Number of subjects	Sex		Age (years)				
		Female (♀)	Male (♂)	5	6	7	8	9
German Shepherd Dog	9	3	6	1 ♀			2 ♀ 4 ♂	2 ♂
Rottweiler	5		5			3 ♂	2 ♂	
Giant Schnauzer	4	1	3			1 ♀	2 ♂	1 ♂
Serbian Shepherd Dog	7	2	5	1 ♂	1 ♀ 1 ♂	1 ♂	1 ♀ 1 ♂	1 ♂
Mixed	3	1	2		1 ♂	1 ♂	1 ♀	
Total	28	7	21	2	3	6	13	4
Control subjects								
Rottweiler	2		2	1 ♀	1 ♀			
Mixed	1	1				1 ♀		
Total	3	1	2	1	1	1		

Based on anamnestic data, as well as clinical, X ray and pathohistological examinations, in 7/28 dogs (25%) affected with megacolon the cause of the disease was unknown, and those cases were determined as idiopathic acquired megacolon (see Table 3). Control subjects were dogs who had undergone surgery for car crash injuries and died during the procedure.

*Histology*

During surgery, full thickness tissue specimens intended for routine histology and immunohistochemistry, were taken from the dilated transversal colon. Samples were fixed in 10% formalin longitudinally oriented and embedded in paraffin wax. For conventional histology sections were cut at 4-5  $\mu$ m and stained with haematoxylin and eosin (H&E), periodic acid Schiff (PAS) and phosphotungstic acid haematoxylin (PTAH).

*Immunohistochemistry*

Well-oriented tissue colonic samples from each animal were used for immunohistochemistry and light microscope morphometry. The formalin fixed and paraffin-embedded 4  $\mu\text{m}$  - thick tissue sections were deparaffinised and heated in a microwave oven at 680 W for 21 minutes, in citrate buffer pH 6.0 for antigen retrieval, or incubated with proteinase K 10 min. at room temperature. Immunostaining was performed by incubating tissue sections with appropriate sera for 60 min at room temperature in a humid chamber, using the streptavidin-biotin technique (LSAB+ Kit, Peroxidase Labeling, K0690, DAKO Cytomation, Denmark). The list of primary antibodies and antigen demasking techniques are shown in Table 2. Antigen-antibody complexes were visualized with 3-amino-9-ethylcarbasole (AEC, No. K3469, DAKO Cytomation, Denmark) or diaminobenzidine hydrochloride (DAB, No. K3468, DAKO Cytomation, Denmark) substrate solution. The cell nuclei were contrastained with Mayer's haematoxylin. The control staining included omission of the primary antisera and replacement of the first layer of antibody by non-immune serum diluted 1:10 and by the diluent alone (Miller, 2002).

Table 2. Antibodies to neuronal markers used for immunohistochemical identification

Antibody	Clone	Proteolytic digestion	Citrate buffer antigen retrieval	Dilution	Company
Mo mouse anti-hu NSE	BBS/NC/VI- H14	No	No	1:50	DAKO A/S, Glostrup, Denmark
Po rabbit anti-hu Synaptophysin		No	Yes	1:50	DAKO A/S, Glostrup, Denmark
Mo mouse anti-hu Neurofilament Protein	2F11	No	Yes	1:50	DAKO A/S, Glostrup, Denmark
Po rabbit anti-cow S-100		Yes	No	1:300	DAKO A/S, Glostrup, Denmark
Po rabbit anti-hu VIP		No	No	Ready to use	Zymed Laboratories Int. US

Mo – monoclonal; Po – polyclonal; hu- human; NSE – Neuron-Specific Enolase; VIP – Vasoactive Intestinal Polypeptide

*Histological and immunohistochemical evaluation*

On the H&E stained sections the thickness of the longitudinal and circular muscle of the muscle layer, as well as muscularis mucosae was measured, using

a graded ocular scale. For each smooth muscle layer there were three separate measurements across the section, and the mean was calculated.

Expression of NSE-, SYN-, NFP- and S-100-immunoreactive neurons and nerve fibers of the enteric nerve system was determined semiquantitatively. Density of immunostained nerve fibers was assessed using a scoring system + – + + + + (+ – sparse fibers; ++ – moderate; +++ – dense; + + + + – very dense fibers; - – absence of fibers), while the number of the neurons/ganglion cells was assessed on a numeric scale 0 – 4 (0 – absence of neurons; 4 – maximum number of neurons). Analysis was performed using a TV computing image analyzing system (Euantimet 720D).

#### *Statistical analysis*

Results were analyzed using parametric and non parametric tests: Student's t-test, Chi-Square test and Mann-Whitney test. P-values <0.05 were considered significant.

## RESULTS

The subjects were 28 dogs affected with megacolon, 21 males and 7 females, mean age  $7.53 \pm 0.21$  (range 5-9) and three control dogs. There were 7/28 (25%) dogs affected with idiopathic megacolon and 21/28 (75%) dogs affected with secondary megacolon.

Results based on anamnestic data, as well as clinical and X ray examination reveal that in 7% of cases affected with megacolon the possible cause was lack of activity and keeping animals in the apartment, while in 11% the predisposing factor was keeping the animals in the backyard and irresponsibility of the owners. In 11% of cases malnutrition was a possible cause of the disease, while injuries and pathological processes in the lumbosacral spinal cord or fracture of the hind legs were present in 46% of cases. In 25% (7/28) the cause of disease was unknown, and those cases were determined as idiopathic acquired megacolon (Table 3).

#### *Histology*

Moderate *melanosis coli* was seen in 3 dogs with idiopathic (43%) and 7 dogs with secondary megacolon (33%). Also, moderate inflammatory cell infiltrate in *lamina propria mucosae* (obstructive colitis) was present in all dogs affected with megacolon. Expressive vasodilatation in the submucosal layer of the *colon transversum* was noticed in animals with idiopathic megacolon.

The thickness of the *lamina muscularis mucosae* was significantly increased in dogs affected with megacolon compared to controls ( $p < 0.01$ ), while there was no significant difference in the thickness of the longitudinal and circular muscle layers among animals with acquired idiopathic / secondary megacolon and the control group. In addition, values of circular / longitudinal muscle ratio were similar among investigated groups (Table 4).

On the PTAH stained sections, mild fibrosis in the longitudinal muscle layer and muscularis mucosae was seen in 2 dogs (33%), while mild fibrosis in the circular muscle layer was recorded in one dog (14%) with idiopathic megacolon. Inclusion bodies on PAS stained section was not detected in any of the animals.

Table 3. Age, sex, breed and predisposing factors in dogs affected with megacolon

Predisposing factors/causes		Dogs kept in house/apartment, inactivity	Dogs kept in backyard	Malnutrition	Injuries and pathological processes in LSC/fracture of the hind legs	Unknown/idiopathic	Total
Breed							
German Shepherd Dog	1 ♂ (8 years)		1 ♂ (9 years)	2 ♀ (8 years) 2 ♂ (8 years) 1 ♂ (9 years)	1 ♀ (5 years) 1 ♂ (8 years)	9 (3♀+6♂)	
Rottweiler	1 ♂ (8 years)	1 ♂ (7 years)		2 ♂ (7 years) 1 ♂ (8 years)		5♂	
Giant Schnauzer		1 ♀ (7 years)	1 ♂ (8 years)	1 ♂ (8 years)	1 ♂ (9 years)	4 (1♀+3♂)	
Serbian Shepherd Dog		1 ♀ (6 years)		1 ♀ (8 years) 1 ♂ (7 years) 1 ♂ (9 years)	1 ♂ (5 years) 1 ♂ (6 years) 1 ♂ (8 years)	7 (2♀+5♂)	
Mixed			1 ♂ (6 years)	1 ♂ (8 years)	1 ♂ (7 years)	3 (1♀+2♂)	
N	2	3	3	13	7	28	
%	7	11	11	46	25	100	

♂ – male; ♀ – female; LSC – lumbosacral spinal cord

Table 4. Thickness of the muscle layers of the *colon transversum* in dogs with idiopathic / secondary megacolon and controls

Thickness of the muscle layer of the <i>colon transversum</i> (mean/range)			
	Controls	IM	SM
Number	3	7	21
Muscularis mucosae (µm)	23 (17-32)	28 (29-41)*	26 (17-30)*
Circular muscle (µm)	396 (193-708)	429 (397-1035)	407 (167-700)
Longitudinal muscle (µm)	271 (53-818)	306 (149-798)	280 (150-1560)
Circular/longitudinal muscle ratio	2.06 (0.43)	1.98 (0.61)	2.01 (0.97)

IM – idiopathic megacolon; SM – secondary megacolon; \*p<0.01

#### *Immunohistochemistry*

Immunohistochemical analysis revealed that in control animals, as well as in megacolon dogs, NFP-immunoreactivity (ir) in neurons and nerve fibers was present in both the submucosal and myenteric plexus, but was more intensive in the myenteric plexus. Also, the dense network of NFP-ir nerve fibers was noticed in all subjects in the circular, but not in the longitudinal muscle layer, where we found sparse NFP-ir nerve fibers. Compared to controls and dogs with secondary megacolon, there was a significant decrease ( $p < 0.05$ ) in the density of NFP-ir nerve fibers in the longitudinal muscle layer in dogs with idiopathic acquired megacolon. Distribution and density of SY-immunoreactive neural tissue in both myenteric and submucosal plexus, as well as the intensity of immunoreaction, were similar to NFP-ir innervation in all groups of animals. However, it has been shown that the density of SY-ir nerve fibers within the longitudinal muscle layer and in the *lamina propria mucosae* is greater than NFP- and NSE-ir. In all analyzed tissue specimens, NSE immunostaining of neural tissue was noticed. A dense network of nerve fibers and neurons was present in the myenteric plexus, but was moderate in the submucosal plexus. Also, sparse NSE-ir unmyelinated axon-like structures have been observed in *lamina propria mucosae*, while moderate density of the same structures was detected within circular and longitudinal muscle layers (Table 5).

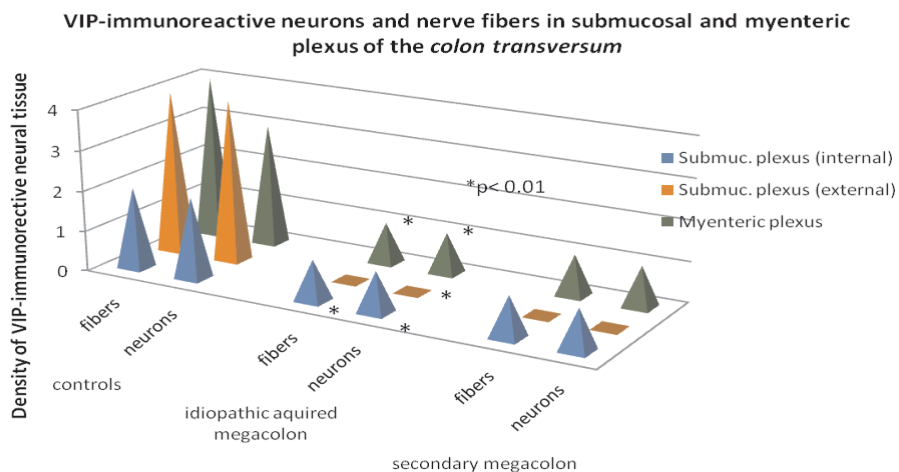
In all examined samples, intensive S-100-ir was detected in Schwann's cells, as well as in ganglionic satellite cells of both submucosal and myenteric plexus. Also, S-100 immunostaining was detected in scattered unmyelinated axons near the *muscularis mucosae*, and branched in *muscularis propria*. Intensity of S-100 immunostaining in ganglion cells was very discrete (Table 5).

In dogs with idiopathic acquired megacolon, there has been a significant decrease in density of VIP-ir nerve fibers, as well as ganglion cells in submucosal plexus, compared to controls. More over, in the external layer of submucosal plexus we noticed a complete absence of VIP-ir in ganglion cells (Figures 1 and 2).

Table 5. Density of innervation in regions of the *colon transversum* in controls and animals with idiopathic/secondary megacolon

ENS			Nerve fiber density/neurons density		
			NSE	SY	NFP
Submucosal plexus	Internal	Controls (n= 3)	++ / 2	++ / 3	++ / 3
		IM (n= 7)	++ / 2	++ / 3	++ / 3
		SM (n= 21)	++ / 2	++ / 3	++ / 3
	External	Controls (n= 3)	++ / 2	++ / 3	++ / 4
		IM (n= 7)	++ / 2	++ / 3	++ / 4
		SM (n= 21)	++ / 2	++ / 3	++ / 4
Myent. plexus		Controls (n= 3)	+++ / 3	++++ / 4	++++ / 4
		IM (n= 7)	+++ / 3	++++ / 4	++++ / 4
		SM (n= 21)	+++ / 3	++++ / 4	++++ / 4
Muscle layer	Circular	Controls (n= 3)	++	+++	+++
		IM (n= 7)	++	+++	+++
		SM (n= 21)	++	+++	+++
	Longitudinal	Controls (n= 3)	++	+++	+
		IM (n= 7)	++	+++	-/+*
		SM (n= 21)	++	+++	+
Lamina propria mucosae		Controls (n= 3)	+	++	-
		IM (n= 7)	+	++	-
		SM (n= 21)	+	++	-

IM – idiopathic acquired megacolon; SM – secondary megacolon, NSE – Neuron Specific Enolase; SY – Synaptophysin; NFP – Neurofilament Protein; \* $p < 0.05$  (IM: Controls / SM)

Figure 1. Density of VIP-immunoreactive neurons and nerve fibers in submucosal and myenteric plexus of the *colon transversum* of controls and affected dogs



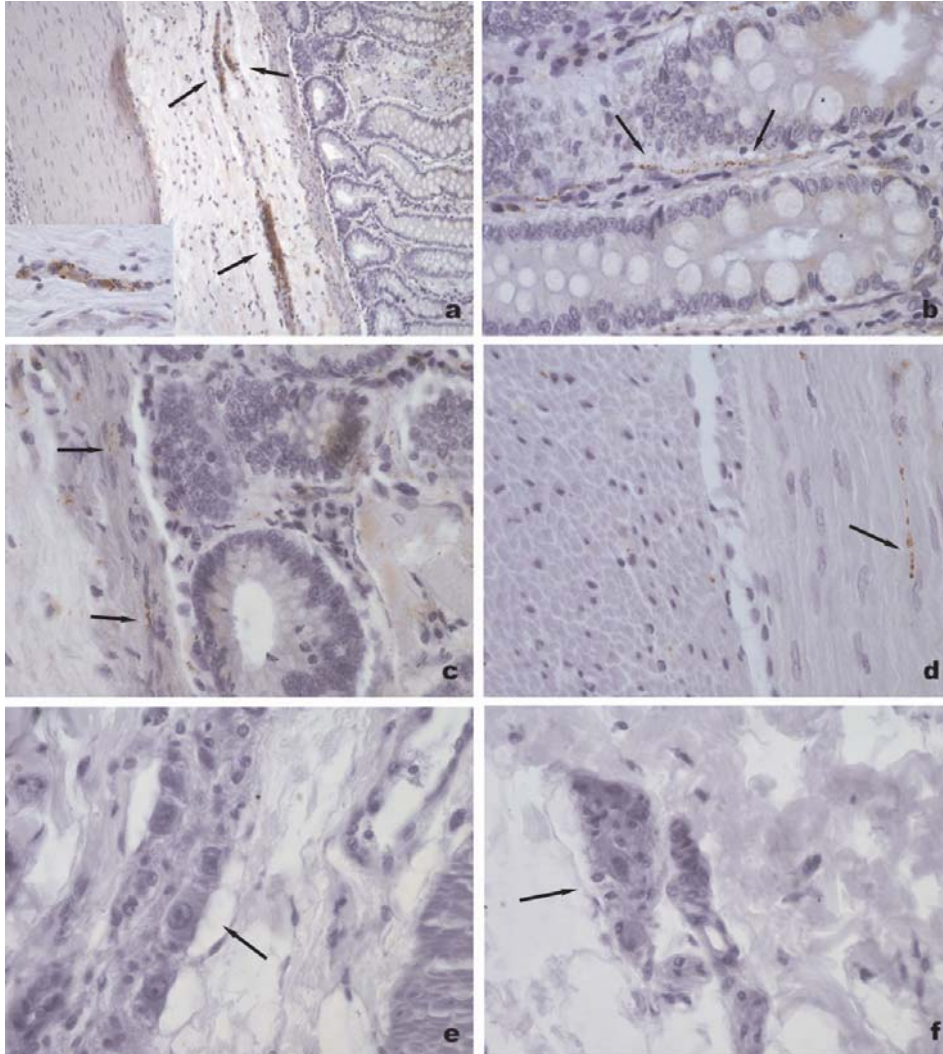


Figure 2. Histological features of VIP-innervation of the normal colon transversum specimens of control dog (a-d) and affected dogs with idiopathic acquired megacolon (e) or secondary megacolon (f).

Immunoreactivity for VIP is observed as strong immunostaining not only in the neuronal soma and neurites in submucosal ganglia (arrows in a; insert in a), but also in neurites in each *lamina propria mucosae* (arrows in b), *lamina muscularis mucosae* (arrows in c) and longitudinal muscle layer (arrow in d) in control dog. Note that there are no VIP-immunoreactivity in the submucosal plexus in affected dog with idiopathic acquired megacolon (e) or secondary megacolon (f).  
 LSAB+ /HRP, anti VIP; X 100 (a), X 200 (insert in a, b, c, d), X 400 (e, f)

Moderate density of VIP immunostained nerve fibers was seen in the muscle layer of healthy dogs, but was rare in dogs with megacolon. In the *lamina propria mucosae* of idiopathic megacolon dogs, decrease in density of VIP-ir nerve fibers compared to controls, reached a significant level (Figure 3).

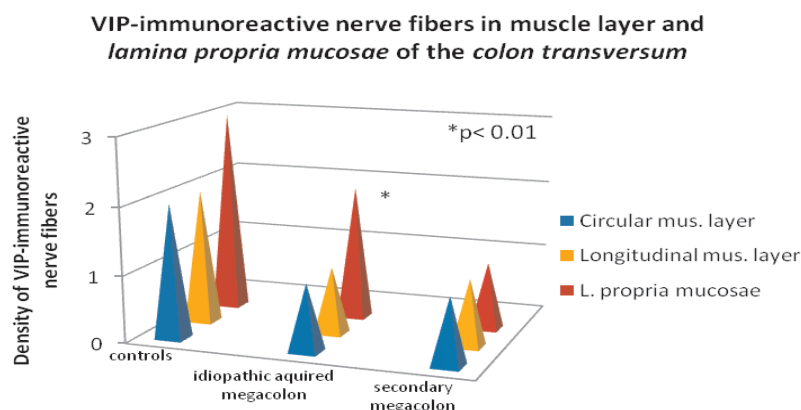


Figure 3. Density of VIP-immunoreactive nerve fibers in muscle layer and *lamina propria mucosae* of the colon transversum of controls and affected dogs

## DISCUSSION

The enteric nervous system (ENS) encompasses an estimated  $10^8$  neurons within the intestinal wall that constitute a complex network of intrinsic primary afferent neurons, interneurons, and effector neurons organized in ganglionated neural plexuses (submucosal and myenteric). The role of ENS is well established in regulating intestinal secretion, motility, active transepithelial ion transport, and modulation of intestinal immune functions involved in mucosal protection and defense (Todorovic *et al.*, 1998; Olsson and Holmgren, 2001; Brehmer, 2006; Furnes, 2006). Enteric neurons innervate the intestinal mucosa, including the gut associated lymphoid tissue, which carries out the dual tasks of maintaining tolerance to food antigens and commensal microflora while initiating innate and acquired immune responses against luminal pathogens (Vulchanova *et al.*, 2007).

Although the gastrointestinal tract harbours the largest number of neurons outside the CNS and is, in this context, not smaller than the spinal cord (Furness, 2006), our knowledge on disease related to defects in the innervation of the gut is rather limited. As a consequence, a number of gastrointestinal disorders is referred to as "functional" because of the absence of morphological abnormalities of gut tissue including the ENS. On the other hand, neuropathological changes in the gut segments affected by inflammation, tumour or Hirschsprung disease are well established. In addition, neuropathological disorders correlate to functional gastrointestinal disorders, thus changes in specific inflammation states were searched for (Todorović *et al.*, 1996; Ardizzone and Poro, 2002).

Patients with intractable constipation can be divided into those with normal gut diameter and those with a dilated gut. The former includes slow-transit constipation, pelvic outlet obstruction and the latter includes congenital megacolon (Hirschsprung disease), colonic pseudo-obstruction and acquired megacolon or megarectum. The pathophysiology of constipation in these entities is poorly understood, although there have been several investigations on this matter (Bharucha and Philips, 1999; Galvez *et al.*, 2004; Lee *et al.*, 2005; Matsuda *et al.*, 2006; da Silveira *et al.*, 2007a, 2007b).

The pathology of acquired megacolon, which might help in understanding the mechanism of the disease, is poorly delineated. In contrast, in the congenital megacolon, an aganglionic segment was revealed. Patients and animals with megacolon can be diagnosed as having an acquired form when there is no aganglionic colonic segment. On the other side, several proposed pathophysiological mechanisms of idiopathic acquired megacolon are yet to be verified. These include quantitative and functional alterations of the enteric nervous system, decreased number of interstitial cells of Cajal, and abnormalities of the intestinal smooth muscle, and a complete atrophy of the tendinous fibre net in the muscularis propria (Basilova *et al.*, 1995; Wedel *et al.*, 1999; Lee *et al.*, 2005; Meier-Ruge *et al.*, 2006; da Silveira *et al.*, 2007a, 2007b).

In our study, the two megacolon groups showed no changes of density of enteric neurons in both submucosal and myenteric nervous plexuses in DP of the colon. However, compared to controls and dogs with secondary megacolon, there was a significant decrease in the density of NFP-ir nerve fibers in the longitudinal muscle layer in dogs with idiopathic acquired megacolon. NFP immunohistochemistry, performed in our study, is an appropriate tool for representation of morphologically defined enteric neuron types in both pig and man. Combination of this technique with immunohistochemistry for neuroactive substances may be useful for making both morphological and chemical classification schemes mutually more precise (Brechmer *et al.*, 2002; Brechmer, 2006). Similar to our study, some previous studies also reported that the architecture of the ganglionic cells of ENS seems to be intact under immunohistochemical studies, and presumed that functional abnormalities of ENS might be the possible cause (Gattuso *et al.*, 1997; Meier-Ruge *et al.*, 2006). In contrast, another study found neuronal dysplasia in patients with acquired idiopathic megacolon (Lee *et al.*, 2005; Iantorno *et al.*, 2007), patients with chagasic megacolon (Iantorno *et al.*, 2007) or slow-transit constipation (Lee *et al.*, 2005), as well as in rat model of chronic intestinal obstruction (Galvez *et al.*, 2004), and postulated that changes in neuronal structures, together with decrease in ICC, might play a pivotal role in those patients. The underlying reasons for the decreased number of neurons and neuronal loss in patients with idiopathic megacolon are myenteric ganglionitis as the contributing factor to reduction of ganglionic cells, and there is no increased apoptosis of enteric neurons. Because previous data have shown both normal architecture and number of enteric neurons and neuronal dysplasia, it seems likely that patients with "idiopathic" megacolon represent a heterogeneous group of patients with a common macroscopic expression and different underlying pathologic aspects, as shown by the presence of megacolon and muscular diseases (Iantorno *et al.*, 2007).

The significance of the thickened muscularis mucosae, increased density of nerve fibers in the lamina propria, and decrease in density of NFP-ir nerve fibers in the longitudinal muscle layer in dogs with idiopathic acquired megacolon in our study is unknown. These changes may be secondary to a "functional obstruction". In contrast to our study, analysis of colon in patients with idiopathic megacolon have shown abnormally large numbers of neurofilaments and smooth endoplasmic reticulum tubules (Faussone-Pelegrini *et al.*, 1999).

VIP belong to the secretin-glucagon superfamily of peptides, which includes (beside VIP), gastric inhibitory peptide, glucagon-like peptide, growth hormone-releasing hormone, PACAP/PACAP-related peptide, peptide histidine isoleucine, peptide histidine methionine, and exendins. These peptides have a broad physiological spectrum in the GIT. The peptidergic transmitter VIP is especially important for smooth muscle relaxation of the intestinal wall and modulation of the basal muscle tone (Olsson and Holmgren, 2001). It is established that VIP not only acts as a neurotransmitter but also plays a role in neuroprotection, growth regulation, and functions as an anti-inflammatory agent. In addition, VIP have been implicated in the regulation of feeding behavior (as anorexigenic peptide), psychomotor activity and energy homeostasis in some vertebrates (Matsuda and Maruyama, 2007).

VIP-positive neurons and fibers is found in both plexuses of the GIT in different species, dogs included (Daniel *et al.*, 1987; Sundler *et al.*, 1989; Furness *et al.*, 1990; Messenger and Furness, 1990). Submucosal neurons project to other submucous ganglia by large numbers of synaptic junction and to the mucosa and submucosa. However, it is established that in the large intestine VIP-positive submucosal neurons project also in subjacent circular muscle. Generally, in the dog those neurons issue descending projections (Sundler *et al.*, 1989). Submucosal VIP-ergic ganglia act partly as interneurons. Myenteric VIP-ergic neurons issue predominantly descending projections to other myenteric ganglia and to the muscle layers. The majority of nerve fibers that innervate the circular muscle, including fibers with immunoreactivity for VIP, enkephalin, substance P, NPY, galanin and GRP come from the myenteric ganglia (Messenger and Furness, 1990). Results of various studies regarding proportion of VIP-positive neurons in submucosal and myenteric plexuses differ. The proportion of human myenteric VIP-positive neurons given by different authors lays between 7% (jejunum) and 22.4% (sigmoid colon) of all neurons. VIP myenteric neurons are prevalently spiny (Type I) neurons, which may be descending motor or interneurons. VIP mediates distal colonic peristaltic relaxation. Oral distension affects the caudal release of VIP and is followed by projective distal hyperpolarization within the circular muscle layer. This descending relaxation indicates mechanoreceptive mucosal nerves and proves the influence of VIP on descending peristaltic inhibition (Brehmer, 2006; Furness, 2006).

Several authors investigated the numbers and proportion of VIP-positive neurons in various pathological conditions, including human aganglionosis (Tomita *et al.*, 1994), human idiopathic acquired megacolon and chagasic megacolon (Koch *et al.*, 1993; da Silveira *et al.*, 2007a), idiopathic chronic constipation (Cortesini *et al.*, 1995), and ulcerative colitis (Todorović *et al.*, 1996).

The proportion of VIP neurons in these disorders seems to be dependent on a number of factors. Beside that, it is not clear which subpopulations of neurons are normally VIP-negative but express VIP immunoreactivity under various pathological conditions. It may be possible that nitrinergic neurons upregulate their VIP expression but also that non-nitrinergic neurons change their chemical phenotype (Cortesini *et al.*, 1995). In addition, the reduction of VIP-receptors in developmental flaws of the enteric nervous system in aganglionosis, intestinal neuronal dysplasia, or hypoganglionosis, may be an indicator of a sensomotor disturbance (Schmittenebecher *et al.*, 2002). For human idiopathic acquired megacolon, only single information was reported (Koch *et al.*, 1993; da Silveira *et al.*, 2007a). However, disturbances of VIP innervation in the affected colon of dogs with idiopathic megacolon have not been examined.

In the present work we demonstrate the changes in expression of VIP in neuronal plexuses from the colons of dogs with both idiopathic and secondary megacolon. Dogs with idiopathic megacolon display decreased VIP-ir in the myenteric plexus and *lamina propria mucosae*, and absent of VIP-ir neurons in submucosal plexus of the dilated portion of the colon. Koch and colleagues established that in acquired megacolon VIP-containing nerve fibers were diminished in circular and longitudinal smooth muscles, and immunostaining of nerve cell bodies in the plexus submucosus externus also were diminished. In addition, there were significantly decreased concentrations of VIP and decreased acetylcholinesterase activity in muscularis externa from patients with acquired megacolon. These results suggest the hypothesis that production of VIP is altered allowing secondary colonic hypertrophy to develop from prolonged cholinergic nerve-mediated contraction of circular smooth muscle (Koch *et al.*, 1993). On the other hand, results of da Silveira and colleagues showed an increased in SP-ir neurons in both enteric plexuses and a selective destruction of inhibitory motor neurons (VIP- and NOS-immunoreactive) in the colon of chagasic patients with megacolon, and suggest that VIP/NOS neurons were preferentially destroyed by *Trypanosoma cruzi* and/or the inflammatory process (da Silveira *et al.*, 2007a).

Our data showed clearly that VIP-ir neurons in both neuronal plexuses of the colon were decreased, and that VIP-ergic nerve fibers in the mucosal layer were diminished in dogs with idiopathic and secondary megacolon, and suggest that depletion of VIP innervation may prevent smooth muscle relaxation in the damaged colon, affect transit, colonic tone, or muscular relaxation responsible for decreased outlet resistance, as well as affect intestinal secretion, and active transepithelial ion transport.

#### ACKNOWLEDGEMENT:

This study was supported in part by the Serbian Ministry of Science (Grant No 145064 and Grant No 145087).

Address for correspondence:  
Vera Todorović, MD, PhD  
University of Belgrade – Institute for Medical Research  
Dr Subotića 4, PO BOX 102  
11129 Beograd, Serbia  
E-mail: verat@imi.bg.ac.yu

## REFERENCES

1. Ardizzone S, Poro GB, 2002, Inflammatory bowel disease: new insights into pathogenesis and treatment, *J Intern Med*, 252, 475-96.
2. Basilova TI, Vorobjev GI, Nasyrina TA, 1995, Changes in the intramural nervous system in idiopathic megacolon in adults, *Arkh Pathol*, 57, 28-30.
3. Bharucha AE, Philips SF, 1999, Megacolon: acute, toxic, and chronic, *Curr Treat Opp, Gastroenterol* 2, 517-23.
4. Brehmer A, Schrodli F, Neuhuber W, 2002, Morphological phenotyping of enteric neurons using neurofilament immunohistochemistry renders chemical phenotyping more precise in porcine ileum, *Histochem Cell Biol*, 117, 257-63.
5. Brehmer A, 2006, Structure of enteric neurons, *Adv Anat Embriol Cell Biol*, 186, 1-94.
6. Bright RM, Burrows CF, Goring R, Fox S, Tilmant L, 1986, Subtotal colectomy for treatment of acquired megacolon in the dog and cat, *J Am Vet Med Assoc*, 188, 1412-6.
7. Burrows CF, 1996, Constipation, obstipation and megacolon in the cat, *Waltham Focus*, 6, 9-14.
8. Cortesini C, Cianchi F, Infantino A, Lise M, 1995, Nitric oxide synthase and VIP distribution in enteric nervous system in idiopathic chronic constipation, *Dig Dis Sci*, 40, 2450-5.
9. Daniel EE, Furness J, Costa M, Belbeck L, 1987, The projections of chemically identified nerve fibers in canine ileum, *Cell Tiss Res*, 247, 377-84.
10. da Silveira ABM, D'Avila Reis D, de Oliveira EC, Neto SG, Luquetti AO, Poole D *et al.*, 2007a, Neurochemical coding of the enteric nervous system in chagasic patients with megacolon, *Dig Dis Sci*, 52, 2877-83.
11. da Silveira AB, Lemos EM, Adad SJ, Correa-Oliveira R, Furness JB, D'Avila Reis D, 2007b, Megacolon in Chagas disease: a study of inflammatory cells, enteric nerves and glial cells, *Hum Pathol*, 38, 1256-64.
12. Faussonne-Pellegrini MS, Infantino A, Matini P, Masin A, Mayer B, Lise M, 1999, Neuronal anomalies and normal muscle morphology at the hypomotile ileocecolonic region of patients affected by idiopathic chronic constipation, *Histol Histopathol*, 14, 1119-34.
13. Furness JB, Lloyd KCK, Sternini C, Walsh JH, 1990, Projections of substance P, vasoactive intestinal peptide and tyrosine hydroxylase immunoreactive nerve fibers in the canine intestine, with special reference to the innervation of the circular muscle, *Arch Histol Cytol*, 53, 129-40.
14. Furness JB, 2006, *The Enteric Nervous System*, Blackwell Publishing, Malden, MA.
15. Galvez Y, Škaba R, Vajtrova R, Frantlova A, Herget J, 2004, Evidence of secondary neuronal intestinal dysplasia in rat model of chronic interstitial obstruction, *J Invest Surg*, 17, 31-9.
16. Gattuso JM, Kamm MA, Talbot JC, 1997, Pathology of idiopathic megarectum and megacolon, *Gut*, 41, 252-7.
17. Gattuso JM, Smith VV, Kamm MA, 1998, Altered contractile proteins and neural innervation in idiopathic megarectum and megacolon, *Histopathology*, 33, 34-8.
18. Iantorno G, Bassoti G, Kogan Z, Luni CM, Cabanne AM, Fisogni S *et al.*, 2007, The enteric nervous system in chagasic and idiopathic megacolon, *Am J Surg Pathol*, 31, 460-8.
19. Koch TR, Schulte-Bockholt A, Telford GL, Otterson MF, Murad TM, Stryker SJ, 1993, Acquired megacolon is associated with alteration of vasoactive intestinal peptide levels and acetylcholinesterase activity, *Regul Pept*, 48, 309-14.
20. Lee JI, Park H, Kamm MA, Talbot IC, 2005, Decreased density of interstitial cells of Cajal and neuronal cells in patients with slow-transit constipation and acquired megacolon, *J Gastroenterol Hepatol*, 20, 1292-8.
21. Matsuda H, Hirato J, Kuroiwa M, Nakayato Y, 2006, Histopathological and immunohistochemical study of the enteric innervations among various types of aganglionoses including isolated and syndromic Hirschsprung disease, *Neuropathology*, 26, 8-23.
22. Matsuda K, Maruyama K, 2007, Regulation of feeding behavior by pituitary adenylate cyclase-activating polypeptide (PACAP) and vasoactive intestinal polypeptide (VIP) in vertebrates, *Peptides*, 28, 1207-13.

23. Meier-Ruge WA, Müller-Lobeck H, Stoss F, Bruder E, 2006, The pathogenesis of idiopathic megacolon, *Eur J Gastroenterol Hepatol*, 18, 1209-15.
24. Messenger JP, Furness JB, 1990, Projections of chemically specified neurons in the guinea-pig colon, *Arch Histol Cytol*, 53, 467-95.
25. Miller K, 2002, Immunocytochemical techniques. In: Theory and Practice of Histological Techniques, Bancroft J, Gamble M (eds.), fifth edition, Churchill Livingstone, London, UK, 421-64.
26. Olsson C, Holmgren S, 2001, The control of gut motility, *Compar Biochem Physiol Part A*, 128, 481-503.
27. Schmittbecher PP, Schuster F, Heiny-Eran P, Gais P, 2002, Colonic mucosal vasoactive intestinal peptide receptors in malformations of the enteric nervous system are reduced compared with morphologically normal innervated colon, *Pediatr Surg Int*, 18, 264-8.
28. Snilleabhain CB, Anderson JH, McKee RF, Finlay IG, 2001, Strategy for the surgical management of patients with idiopathic megarectum, *Br J Surg*, 88, 1392-6.
29. Sundler F, Ekblad E, Håkanson R, 1989, Projections of enteric peptide-containing neurons in the rat, *Arch Histol Cytol*, 52 (Suppl), 181-9.
30. Todorović V, Janić B, Koko V, Micev M, Nikolić JA, Ratković M et al., 1996, Colonic vasoactive intestinal polypeptide (VIP) in ulcerative colitis – a radioimmunoassay and immunohistochemical study, *Hepatogastroenterology*, 43, 483-8.
31. Todorović V, Koko V, Nikolić I, Petrović S, Đuknić-Pejović M, Perić P, 1998, The enteric nervous system, *Folia Anat*, 26 (Suppl. 2), 23-5.
32. Tomita R, Manakata K, Kurosu Y, 1994, Peptidergic nerves in Hirschsprung disease and its allied disorders, *Eur J Pediatr Surg*, 4, 346-51.
33. Vulchanova L, Casey MA, Crabb GW, Kennedy WR, Brown DR, 2007, Anatomical evidence for enteric neuroimmune interactions in Peyer's patches, *J Neuroimmunol*, 185, 64-74.
34. Washabau RJ, Hasler AH, 1996, Constipation, obstipation and megacolon, In: Consultations in Feline Internal Medicine, 3<sup>rd</sup> ed, August JR (ed), WB Saunders Co, Philadelphia, Chapter 15, 104-13.
35. Washabau RJ, Stalis IH, 1996, Alterations in colonic smooth muscle function in cats affected with idiopathic megacolon, *Am J Vet Res*, 57, 580-6.
36. Washabau RJ, Hall JA, 1997, Gastrointestinal motility disorders of dogs and cats, *Eur J Comp Gastroenterol*, 2, 9-19.
37. Wedel T, Roblick U, Gleiss J, Ott V, Eggers R, Kühnel W et al., 1999, Disorders of intestinal innervation as a possible cause for chronic constipation, *Zentralbl Chir*, 124, 796-803.

## IDIOPATSKI I SEKUNDARNI STEČENI MEGAKOLON KOD PASA UDRUŽENI SU SA SMANJENOM VIP-INERVACIJOM U OŠTEĆENOM KOLONU

PROKIĆ B, TODOROVIĆ VERA, DRNDAREVIĆ NEDA, VIGNJEVIĆ SANJA,  
ĐIKIĆ DRAGOSLAVA, NIKOLIĆ I, MARINKOVIĆ S i SLAVIK E

### SADRŽAJ

Poznato je da se megakolon javlja kod mesojeda, uključujući mačke i pse, pri čemu je ovo oboljenje daleko učestalije kod mačaka. Na osnovu dosadašnjih saznanja, idiopatski megakolon je čest uzročnik konstipacije kod mačaka i 62%

mačaka sa konstipacijom ima idiopatski megakolon. Istovremeno, podaci o psima sa idiopatskim megakolonom veoma su oskudni.

U ovom radu je proučavan enterični nervni sistem u dilatiranom delu kolona kod 7 pasa sa idiopatskim megakolonom i 21 psa sa sekundarnim stečenim megakolonom, a rezultati su upoređeni sa normalnim kolonom kod 3 kontrolne zdrave životinje. Tkivni preseći kolona bojeni su klasičnim histološkim i imunohistochemijskim metodama, pri čemu su primenjeni pan-neuronski markeri (NSE, sinaptofizin i neurofilament) i VIP, kao i S-100 protein za detekciju glijalnih ćelija u enteričnim ganglijama. Nisu otkrivene razlike u gustini enteričnih neurona u submukoznom i mijenteričnom pleksusu kod životinja sa megakolonom, kao ni razlike u gustini glijalnih ćelija enteričnih ganglija, u odnosu na kontrolnu grupu životinja. Međutim, u odnosu na kontrolnu grupu, kod životinja sa idiopatskim megakolonom dokazana je smanjena VIP-imunoreaktivnost (ir) u mienteričnom pleksusu i krznu mukoze, kao i kompletno odsustvo VIP-ir neurona u submukoznom pleksusu dilatiranog dela kolona. Slične promene, ali u manjem stepenu, postojale su kod pasa sa sekundarnim stečenim megakolonom. Može da se zaključi da u patogenezi idiopatskog i sekundarnog stečenog megakolona značajnu ulogu imaju displastične promene u VIP-ergičkim neuronima enteričkog nervnog sistema.