



COPYRIGHT AND USE OF THIS THESIS

This thesis must be used in accordance with the provisions of the Copyright Act 1968.

Reproduction of material protected by copyright may be an infringement of copyright and copyright owners may be entitled to take legal action against persons who infringe their copyright.

Section 51 (2) of the Copyright Act permits an authorized officer of a university library or archives to provide a copy (by communication or otherwise) of an unpublished thesis kept in the library or archives, to a person who satisfies the authorized officer that he or she requires the reproduction for the purposes of research or study.

The Copyright Act grants the creator of a work a number of moral rights, specifically the right of attribution, the right against false attribution and the right of integrity.

You may infringe the author's moral rights if you:

- fail to acknowledge the author of this thesis if you quote sections from the work
- attribute this thesis to another author
- subject this thesis to derogatory treatment which may prejudice the author's reputation

For further information contact the University's Copyright Service.

sydney.edu.au/copyright

**CLINICAL AND RADIOGRAPHIC EVALUATION OF
NOBELACTIVE™ DENTAL IMPLANTS**



Danny Sai-Wah Ho

BDS (Hons) (Syd), FRACDS

A thesis submitted in partial fulfilment
of the requirements for the degree of

Doctor of Clinical Dentistry

Discipline of Periodontics

Faculty of Dentistry

University of Sydney

2010

© Danny Sai-Wah Ho 2010

DECLARATION OF AUTHORSHIP

This is to certify that the work presented in this thesis was carried out by the author Danny Sai-Wah Ho, who is a candidate for the degree of Doctor of Clinical Dentistry, in the discipline of Periodontics, Faculty of Dentistry, The University of Sydney. The work was carried out at the Westmead Centre for Oral Health. Any contribution made to the research by others with whom I have worked is explicitly acknowledged in the thesis. The work presented in this thesis has been submitted only to the University of Sydney for a higher degree.

Danny Sai-Wah Ho
3rd September 2010

ACKNOWLEDGEMENTS

I would like to thank my supervisor, Associate Professor Stephen Yeung for his valuable guidance, critical appraisal, intellectual input, and great support throughout the study. His dedication, organisation and surgical participation were essential for the completion of the study.

Thanks to Associate Professor Kwan Yat Zee for his critical appraisal, valuable input and guidance, especially regarding the development and implementation of radiographic methodology. His surgical participation was also integral to the completion of the study.

Thanks to Dr. Vijay Tumuluri and Dr. Peter Hell for their assistance with surgical and prosthodontic procedures.

Thanks to Dr. Bradley Curtis for his statistical analysis and guidance relating to data analysis.

Thanks to Dr. Bruce Waters and the team in the Radiology Department, Westmead Centre for Oral Health, for their efforts in taking the cone beam computed tomography scans.

Thanks to all the staff of the Periodontics Department in the Westmead Centre for Oral Health for their assistance and support.

Thanks to Nobel Biocare Australia for their generous donation of implants and components that were used in the study.

Thanks to the Australian Periodontology Research Foundation for the funding support.

I would also like to express my sincere appreciation and gratitude to my fiancé, Cherry, and my family for their continuous support throughout the years.

ABSTRACT

Dental implants have been very successful in providing support for dental restorations after loss of teeth. However, a common challenge involves the placement of implants in the compromised site with deficient bone volume and/or poor bone density, resulting in the technical difficulty of achieving primary stability. An unstable implant at the time of placement has been identified as a major cause of early implant failure. The NobelActive™ dental implant is specifically designed to overcome “soft” bone and facilitate “stable” implant placement in difficult, compromised conditions. The purpose of this study is to conduct a pilot randomised controlled trial to evaluate the clinical and radiographic efficacy of the NobelActive™ system and to evaluate the relative importance of achieving primary stability at placement.

32 subjects were recruited and using a split-mouth design, the NobelActive™ implant was compared with a contralaterally matched Brånemark implant. Both implants were placed in a single surgical procedure into healed sites using a one-stage protocol and reviewed at monthly intervals. NobelActive™ implants were functionally loaded with provisional restorations at one month and all implants were restored with final crowns three months post-implant placement. The implant was assessed using peak insertion torque values, resonance frequency analysis, clinical parameters, digital subtraction radiography, and cone beam computed tomography.

The findings of this study confirmed that the NobelActive™ implant is capable of achieving greater primary stability as a result of requiring a higher insertion torque. The insertion torque was significantly greater for the NobelActive™ implant group ($p=0.02$) though no observable difference in resonance frequency analysis values were found. Preliminary results of up to one year follow-up suggest comparable healing responses between the test and control implants. Changes observed in the marginal bone levels surrounding the implants during the initial healing period were also comparable when examined using digital subtraction radiography and cone beam computed tomography. Within the limits of our sample population, the survival rates were lower with the test implants, though not statistically significant.

TABLE OF CONTENTS

	Page
Title Page	i
Declaration of Authorship	ii
Acknowledgments	iii
Abstract	iv
Table of Contents	v
List of Tables	viii
List of Figures	ix
1. INTRODUCTION	1
2. LITERATURE REVIEW	2
2.1 Primary implant stability	2
2.2 Factors affecting stability	4
2.2.1 Implant length and diameter	5
2.2.2 Implant geometry	5
2.2.3 Implant surface	6
2.2.4 Surgical technique	7
2.2.5 Bone condensation	7
2.2.6 Poor primary stability	9
2.3 Measurement of implant stability	10
2.3.1 Damping capacity assessment	12
2.3.2 Resonance frequency analysis	13
2.3.3 Periotest TM vs. Resonance frequency analysis	16
2.4 Micromotion	18
2.4.1 Reducing micromotion	20
2.5 Implant success and survival in compromised sites	21
2.6 Brånemark TM dental implants	23
2.7 TiUnite TM implant surface	25
2.8 Placement protocol	27
2.9 Monitoring of implants	30
2.10 Radiographic monitoring of implants	32
2.11 Standardisation of periapical radiographs	33
2.12 Digital subtraction radiography	33
2.13 Subtraction radiography and periodontics	35

2.14	Cone beam computed tomography and implant monitoring	37
2.14.1	Accuracy of cone beam computed tomography	38
2.14.2	Cone beam computed tomography and periodontics	39
2.14.3	Cone beam computed tomography and implants	40
2.15	Dental radiography and radiation dosage	41
2.16	Bone remodelling following implant placement	44
2.16.1	Platform switching	46
2.17	NobelActive™ dental implants	48
2.18	Summary of literature review	52
3.	HYPOTHESIS	54
4.	AIMS AND OBJECTIVES	55
5.	MATERIALS AND METHODS	56
5.1	Ethics approval	56
5.2	Study population	56
5.3	Test and control implants	58
5.4	Study design	59
5.5	Surgical protocol	59
5.6	Surgical assessment	60
5.7	Prosthetic reconstruction	61
5.8	Clinical assessment	61
5.9	Radiographic assessment	62
5.10	Data analysis	64
6.	RESULTS	67
6.1	Study population	67
6.2	Location of implants	69
6.3	Description of implants	69
6.4	Survival of implants	70

6.5	Complications	71
6.6	Duration of surgical procedure	73
6.7	Visual analogue scales	73
6.8	Insertion torques	75
6.9	Resonance frequency analysis	75
6.10	Marginal bone levels	77
6.11	Computer-assisted densitometric image analysis	80
6.12	i-CAT cone beam computed tomography	82
7.	DISCUSSION	84
7.1	Study population	84
7.2	Insertion torques	85
7.3	Implant survival and complications	89
7.4	Visual analogue scales	91
7.5	Duration of surgical procedure	92
7.6	Resonance frequency analysis	92
7.7	Marginal bone levels	93
7.8	Computer-assisted densitometric image analysis	96
7.9	Comparison with other studies involving NobelActive™ implants	97
7.10	Strengths of the study	99
7.11	Limitations of the study	101
7.12	Further research	103
7.13	Final thoughts	105
8.	CONCLUSIONS	106
9.	APPENDIX	107
10.	REFERENCES	127

LIST OF ILLUSTRATIONS

Figure 2.1	NobelActive™ design	49
Figure 5.1	Flow diagram of participants and implant therapy	66
Figure 6.1	Flowchart of participant progression through the trial	68
Figure 6.2	Summary of operator post-surgery subjective evaluation of implant placement	74
Figure 6.3	Resonance frequency analysis values of the test and control implants	76
Figure 6.4	Numbers of test and control implants with different degrees of bone change relative to implant structure	78
Figure 6.5	Mean CADIA values at different time points	81

LIST OF TABLES

Table 6.1	Patient demographics	67
Table 6.2	Distribution of implant positions	69
Table 6.3	Distribution of implant diameters and lengths	70
Table 6.4	Key for assessing bone levels relative to the test implant structure	77
Table 6.5	Key for assessing bone levels relative to the control implant structure	77
Table 6.6	Mean bone changes around implants	79
Table 6.7	Mean bone level distance from the tip of the first implant thread	80
Table 6.8	Noise level in different threshold values	80
Table 6.9	Cone beam computed tomography mean bone levels relative to the implant shoulder	83

1. INTRODUCTION

Endosseous dental implants have been very successful in providing anchorage and support for dental restorations allowing replacement of missing teeth (Jung et al. 2008, Lekholm et al. 1999, Pjetursson et al. 2004). Though implants may be used in a variety of situations resulting in long survival periods, this success is highly dependent upon the interplay between a range of factors, including procedure- and patient-related factors (Ekfeldt et al. 2001, Alsaadi et al. 2008). As an unstable implant at the time of placement has been identified as a major cause of early implant failure (Albrektsson et al. 1981), the technical requirements of achieving and maintaining implant stability are important prerequisites for successful clinical outcomes with dental implants (Albrektsson & Zarb 1993).

2. LITERATURE REVIEW

2.1 Primary implant stability

Primary stability of dental implants is defined as the capacity of the implant to withstand loading in axial, lateral, and rotational directions (Mesa et al. 2008). It is the most important clinical goal to be achieved at the time of implant placement. The rigid fixation of the implant within the host bone cavity, in the absence of micromotion (Adell et al. 1981, Futami et al. 2000), is a key factor as signs of subclinical mobility may have an effect on implant integration (Salonen et al. 1993). Osseointegration is the process in which clinically asymptomatic rigid fixation of alloplastic materials is achieved and maintained in bone during functional loading (Albrektsson et al. 1994). It involves a complex cascade of cellular and molecular events that is triggered by site preparation and, with subsequent placement of the implant, results in primary bone healing and bone deposition. This dynamic process achieves maximum bone deposition by 3-4 months, though the interface is maintained by constant remodelling throughout life.

Additionally, changes in implant stability that occur early, during the first 8 weeks after insertion, have been attributed to a delay in bone healing (Buser et al. 2004). The increase in stability due to regeneration and remodelling of the bone at the implant-tissue interface is considered to be the secondary stability. Hence, though primary osseointegration is associated with the mechanical engagement of an implant with the surrounding bone after implant insertion, secondary osseointegration involves biological stability due to bone regeneration and remodelling.

Initial implant stability is provided by the cortical bone surrounding the inserted implant but as bony healing occurs, stability will be modified as well. In the first weeks after implant insertion, there is sparse bone to implant contact (Johansson & Albrektsson 1987). Resistance to removal torque forces and direct bone-to-implant contact will gradually increase as bony healing and apposition proceeds over the initial three months. However, complete bone-to-implant contact rarely occurs and clinically observed osseointegration corresponds to approximately 80% of bony contact histologically, though >60% bone-to-implant contact is considered to be adequate for stability (Albrektsson et al. 1993). This ratio will vary depending upon the material and design of the implant, the state of the host, the surgical technique, the loading conditions, and healing time (Masuda et al. 1998). Over time, the stability of implants in different types of bone, as measured with resonance frequency analysis, appears to steady and be comparable, regardless of the density of the bone as determined by cutting torque at placement (Friberg et al. 1999c). The cutting torque has been found to correlate well with the Lekholm and Zarb index of bone quality (Johansson et al. 2004).

Stability is frequently a subjective perception related to the rotational resistance of the implant site during placement of the implant (Friberg et al. 1999a) or the application of a removal torque (Sullivan et al. 1996). Sullivan et al. stated that a removal torque below 20Ncm is not believed to be detrimental to osseointegration and hence bony stability should be preserved. However, greater values of torque may cause an osseointegrating implant to become mobile.

2.2 Factors affecting stability

Primary stability is a function of local bone quality and quantity, the geometry of the implant (length, diameter, and type), the micromorphology of the implant surface, and the placement technique used (osteotomy size in relation to the implant diameter, pre-tapping, or self tapping) (Meredith 1998). It is related to the level of primary bone contact and the biomechanical properties of the surrounding bone (Meredith et al. 1997, Rasmusson et al. 1998) and hence the presence of adequate bone quantity and quality plays an important role in obtaining a high primary stability (Friberg et al. 1991, Truhlar et al. 1997, Esposito et al. 1998). An implant placed in dense cortical bone is more stable than an implant placed in an open trabecular network.

Numerous animal studies confirm the importance of adequate implant anchorage to obtain osseointegration. Sennerby et al. (1992) showed, in a rabbit model, that implants stabilised by only three threads in the cortical bone had a higher bone-to-implant contact percentage compared to implants that were completely surrounded by trabecular bone. Furthermore, higher forces were necessary to dislodge the implants with cortical engagement. Lioubavina-Hack et al. (2006) compared the osseointegration of stable and unstable dental implants within an experimental capsule using a rat model. It was found that implant instability resulted in fibrous encapsulation, whereas stability, even if provided by the apex of the implant only, allowed for osseointegration to occur.

In a 10-year retrospective study of 1084 Brånemark™ implants, Mesa et al. (2008) used multivariate analysis to determine the variables associated with primary implant

stability. Examination of clinical variables, such as smoking status and history of periodontitis, and implant-related variables, such as length, diameter, bone quality, and location, were correlated to Periotest[®] values obtained at first-stage surgery. Significant associations between early failures due to loss of stability were found. Females and non-anterior mandible implants showed higher risks for primary implant stability failures, as did having implant lengths shorter than 15mm. A limitation of this study is the primary use of the Periotest[®] instrument to determine lack of stability, with minimal emphasis on other means of assessing stability.

2.2.1 Implant length and diameter

Greater implant length and diameter increase the contact surface area at the bone–implant interface. The diameter of the implant potentially has the greatest influence on implant stability (Ostman et al. 2006), whereas implant length, localisation, or bone level show no adverse or beneficial impact (Horwitz et al. 2003). Mesa et al. (2008) found that primary implant stability was significantly associated with implant length, in agreement with Tricio et al. (1995) and Aparicio (1997), but not with implant diameter. However, Teerlink et al. (1991) found no relationship between implant stability (measured using the Periotest[™]) and implant length and one group observed a relationship only with diameter (Deporter et al. 2002).

2.2.2 Implant geometry

The design of the implant appears to influence its primary stability and the placement torque (da Cunha et al. 2004). Comparing the non-self-tapping Ankylos system with

the self-tapping Camlog system, Rabel et al. (2007) showed that the insertion torque values were significantly greater for the non-self-tapping implants. This was in agreement with an earlier study on cadavers (O'Sullivan et al. 2000). Implant design features such as thread pitch, thread geometry, helix angle, thread depth and width may also affect implant stability (Abuhussein et al. 2010). The screw or “threaded” design minimises implant micromotion during function (Hall et al. 2005) and also increases the surface area of the implant for bone-to-implant contact, compared to cylindrical implants (Vandamme et al. 2007). Additionally, tapered implant designs bring higher primary stability than straight cylindrical implant geometry as they may provide a degree of compression of the cortical bone in a poor bone implant site (O'Sullivan et al. 2004b). Conversely, other studies have not found a correlation between implant geometry and primary stability (Balleri et al. 2002, Bischof et al. 2004). Chong et al. (2009) found the association strength between implant design and initial stability to be less relevant than other factors, such as bone quality and quantity. Thus, the evidence for the influence of implant geometry is conflicting and inconclusive.

2.2.3 Implant surface

Rough implant surfaces, which enlarge the implant surface area in contact with the host bone, favour primary stability (Hansson 1999) and also aid in mechanical fixation of the implant to the bone. Rougher implant surfaces have been shown to provide greater mechanical bone anchorage, as shown through push-out, pull-out, and torque testing studies (Wennerberg et al. 1996, Han et al. 1998). Additionally, surface topography and roughness positively affect the healing processes by promoting

favourable cellular responses by means of protein surface and cell surface interactions (Borsari et al. 2005, Mustafa et al. 2000). The correlation between low bone density and poor primary stability can be moderated by using a minimally rough surface implant (Tabassum et al. 2009).

2.2.4 Surgical technique

Surgical placement technique can be modified to improve primary stability. ‘Underpreparing’ an osteotomy, by using a drill with a smaller diameter than the implant, will result in the production of compressive forces on the bone when the implant is inserted (Sakoh et al. 2006). This results in the production of hoop stresses, which may be beneficial in enhancing the primary stability of an implant (Tabassum et al. 2009). Should the forces be too great, however, there may be detrimental effect on the surrounding bone, resulting in necrosis and local ischemia of the bone at the implant-tissue interface. The use of additional thread cutters and bone condensers has been shown to lessen primary stability significantly, compared with drilling alone (Buchter et al. 2003). An atraumatic surgical technique is essential to maintain cellular viability, prevent the formation of an epithelial-connective tissue layer along the bone-implant interface, and promote healing (Romanos 2004).

2.2.5 Bone condensation

Bone condensation during surgery has been suggested to increase primary stability of dental implants by compacting surrounding bone rather than removal through cutting. The trabecular bone is compressed laterally with an implant-shaped instrument. This

procedure has been shown to increase bone-to-implant contact during the early healing phases (Summers 1994) and, as it is difficult to obtain implant anchorage in bone that is not very dense, increasing bone density may improve primary stability and implant success. Lateral osseocompression during site preparation with osteotomes can improve the quality of type IV bone so that it is similar to type 3 bone; the same technique can be applied to make type 3 bone seem more like type 2 bone (Hahn 1999).

The effect of condensation on the bone surrounding implants was examined by de Oliveira et al. (2007) in a dog model. It was found that the use of an implant with a macroscopic design aimed at promoting considerable bone condensation upon insertion could significantly increase the bone-to-implant contact percentage immediately adjacent to the implant surface. Similarly, the use of bone condensers to prepare an implant site, compared with a standard drilling preparation, resulted in significantly greater bone-to-implant contact percentage and peri-implant bone density within the first two weeks (Schlegel et al. 2003). After eight weeks, however, differences were not significant and hence, it was concluded that bone condensation may only produce a topical conditioning within the initial healing phase.

Gulsahi et al. (2007) used dual energy x-ray absorptiometry and periapical radiography to assess bone density differences after conventional and bone-condensing techniques during the placement of single tooth implants. Implants were placed bilaterally according to a split-mouth design. There were no significant differences in bone mineral density, bone mineral content, or photodensitometry between the two techniques though all parameters increased over the following 6 and

12 months. The success rate was 92.9% for implants placed through the conventional technique and 71.5% for the bone-condensing technique. The lower success rate may be the result of trabecular fracture associated with the bone condensation (Nkenke et al. 2002, Buchter et al. 2005). Another study reported the fracture of the labial cortical plate in three patients when the bone condensation method was used in the placement of 22 implants (Strietzel et al. 2002).

2.2.6 Poor primary stability

Some evidence suggests that the early failure of implants following placement may be caused by excessive mechanical stresses and poor primary stability at placement (Albrektsson 1993, Friberg et al. 1991). Poor stability can result in micromotion, disrupting the normal healing process. This may result in the formation of a fibrous tissue capsule, resulting in mobility of the implant and subsequent clinical failure. The cause of failure of primary implant stability remains controversial and may be dependent upon the implant site, surgical techniques, and implant design (O'Sullivan et al. 2004a).

Thus, as the success of an implant is highly dependent upon achieving stability, placement of an implant with a high initial primary stability should be the aim of surgery. The stability of the implant would need to be measured and monitored prior to and following placement into function.

2.3 Measurement of implant stability

As the primary stability of implants is dependent upon the contact of bone with implant, various methods have been used to assess objectively the stability of the bone–implant interface (Ersanli et al. 2005) at the time of insertion and throughout the osseointegration period. The measurement of implant stability at the time of insertion and at the time of prosthetic placement is difficult and sometimes, at best, subjective. The cutting resistance of the implant during insertion provides a clinical perception of the stability, especially if there is the sense of an abrupt seating of the implant to the base of the osteotomy preparation. This perception may be accentuated with tapered implants due to the root form geometry. Insertion torque measurements only assess conditions at the time of implant installation, but may be used to determine primary implant stability (Aparicio et al. 2006).

Percussion tests, similar to testing of ankylosed teeth, involve the tapping of a metal instrument, such as the metal handle of a mirror, against the implant carrier. The sound produced by the contact, depending upon the pitch of ringing, may indicate good stability or osseointegration (Adell et al. 1985). A low pitch or dull sound may indicate that the implant is not well-integrated. Quantitative measurement of stability based upon this method is not possible and the interpretation of the sound is highly subjective, hence the percussion test cannot be used to monitor peri-implant changes following placement.

Application of a reverse or unscrewing torque has also been proposed for the assessment of implant stability at the time of abutment connection (Sullivan et al.

1996). Implants that cannot withstand an applied reverse torque of 10-20 Ncm and rotate would be considered to be failures, which would then require removal. Since the removal torque is related to the degree of bone-to-implant contact (Johansson & Albrektsson 1987, Sennerby et al. 1992), it could be assumed that torque values would increase as osseointegration matured. However, an implant surface in the process of osseointegrating, albeit slowly, may fracture under the applied torque stress, whereas if allowed to heal for a longer period of time, adequate bone-to-implant contact could be achieved. Additionally, as animal experiments have demonstrated, there is potential for the re-integration of loosened and rotationally mobile implants (Ivanoff et al. 1997). Hence, reverse torque testing has fallen into disrepute and, additionally, longitudinal testing of the implant using this method is not possible.

Currently, there are two techniques available to provide an objective measurement of implant stability and osseointegration that are non-invasive and do not damage/disrupt the implant-tissue interface: resonance frequency analysis (Osstell™), and damping capacity assessment (Periotest™). These have been described as being useful methods to assess primary implant stability (Göransson & Wennerberg 2005). They were also reported to yield valuable information on bone healing during osseointegration (Huang et al. 2005) and on changes in the bone-implant interface after uncovering (Morris et al. 2003).

2.3.1 Damping capacity assessment

The Periotest™ is a non-invasive, electronic device that assesses the damping characteristics of the peri-implant tissues to provide an objective measurement of the reaction of the periodontium to a defined impact load applied to the tooth crown (Schulte 1988). Although originally designed to assess the periodontium surrounding natural teeth, the testing characteristics were transferable for assessment of implants.

The instrument utilises an electronically controlled translational hammer that, when activated with an electromagnet, taps the implant abutment up to 16 times in four seconds. Periotest™ measures the elapsed time from initial contact to the first rebound off the implant. The greater the implant stability, the shorter the elapsed time is and, conversely, the greater the time, the more mobility is present. A microprocessor and software are used to average and convert these millisecond measurements into Periotest™ values, or PTV. PTVs range from -8 (low mobility) to +50 (high mobility), and can monitor primary implant stability at first-stage surgery, osseointegration at second-stage surgery and over the long-term. As Periotest™ was originally designed to assess teeth supported by periodontal ligament, values obtained for healthy implants will tend to be lower and lie within a narrower range, between -5 and +5 (Olive & Aparicio 1990).

Many groups have reported the potential application of the Periotest™ to measure implant mobility (Teerlinck et al. 1991, van Steenberghe et al. 1995, Carr et al. 1995). However, measurement has produced inconsistent results, especially for implants (Derhami et al. 1995, Aparicio 1997). The PTV can be affected by clinical variables,

including the position that the rod impacts the implant, the angulation of the handpiece, and sensitivity to the physiological variables (bony changes and integration of the implant). Faulkner et al. (2001) showed that a change in position of 1mm in striking height can produce a difference in PTV of between 1 and 2, and angulation also affects the value. Noguerol et al. (2006) showed that the PTV is a good predictor of early failure and has a greater discriminative capacity compared with radiographic data obtained at second-stage surgery after completion of osseointegration. A PTV threshold value of -2 identified 84% of the implants undergoing early failure.

One concern regarding an electronic mechanical tapping device is the potential for the tapping force to cause loss of integration. Seong et al. (2009) used the tapping device on implants inserted into cadaver mandibles. It was found that repeated measurement with the device resulted in displacement of the implant and damage to the bone-implant interface, with implant mobility resulting in some cases.

2.3.2 Resonance frequency analysis

Use of resonance frequency analysis (RFA) to quantify implant stability was first described by Meredith et al. (1996). The original design involved the attachment of a transducer either directly to an implanted implant or via a trans-mucosal abutment using a screw. The transducer, which consists of a small beam to which two piezo-ceramic elements are attached, is vibrated by exciting one of the elements over a range of frequencies, typically 5 to 15Hz. The response is then measured by the second element and a frequency response analyser subsequently analyses the response

of the beam. At the first flexural resonance of the beam, there is a marked change in amplitude and in phase of the received signal. The resonance frequency can thus be identified in a plot of the frequency against the amplitude. More recently, the instrument has evolved to become a magnetic device that uses magnetic frequencies between the transducer (a magnetic peg) and the resonance frequency analyser. The transducer is a metallic rod with a magnet on top that is screwed onto an implant and is similarly vibrated by a magnetic pulse. The magnet then induces an electric voltage in the probe coil, and the voltage is the measurement signal sampled by the resonance frequency analyser. As the resonance frequency of each transducer is unique and hence variable, the first commercial version of the RFA technique (Osstell™) had transducers that were calibrated by the manufacturer. The latest model of the Osstell™ device is the Osstell ISQ instrument, which was released in 2009. Resonance frequency measurements are expressed as the implant stability quotient (ISQ) with values from 1 to 100.

Resonance frequency analysis has been assessed to evaluate its usage in the prediction of implant failure. Friberg et al. (1999b) evaluated 75 one-stage implants that were placed with healing periods ad modum Brånemark in fifteen edentulous mandibles by means of repeated resonance frequency analysis measurements. At second-stage surgery, one implant showed a decreasing stability from week 2 to week 15, when the implant was found to be clinically mobile. The lowered resonance frequency value indicated the failure several weeks before mobility was clinically diagnosed. In a second patient, three of five implants showed a marked decrease in stability from week 2 to week 6, which corresponded to the period of implant loading with a relined denture. After asking the patient to refrain from wearing the denture, the implant

stability increased for two implants and was maintained at the same level for one implant.

Glauser et al. (2004), in an immediate loading study, monitored the resonance frequency of 81 implants from placement to 1 year in function. A total of nine implants failed during the 1-year observation period. All implants showed a high degree of initial stability, around implant stability quotient 70, but the group of future failures showed a continuous decrease in implant stability. After 1 month, the mean implant stability quotient value of 52 was statistically lower for the group of future failures than for the successful implants, which showed an implant stability quotient of 68. Also, implant stability quotient values of 49–58 were associated with an 18.2% risk of failure. Evidently, the lower the implant stability quotient value after 1 month of immediate loading, the higher the risk for future failure. Some of the failing implants may have been rescued by unloading and allowing a period of healing. However, the study of Glauser et al. (2004) analysed the resonance frequency analysis measurements retrospectively and no intervention could be taken chairside.

Some studies examining the applications of resonance frequency analysis have found no correlation between implant stability quotient values and histological parameters of osseointegration (Abrahamsson et al. 2009). Ito et al. (2008) similarly found that resonance frequency analysis did not correlate with histological bone-to-implant contact but also concluded that the connection between the implant and bone at the neck region of the implant affects the value significantly. Hence they considered that the resonance frequency analysis was useful for monitoring implant osseointegration clinically.

Rabel et al. (2007) concluded that within implant systems, no correlation between insertion torque and resonance frequency values could be determined and that ISQ values obtained from different implant systems are not comparable. It has been claimed that failing implants might be identified by RFA and consequently managed quickly and appropriately. Failing implants tended to show a continuous decrease of ISQ values until failure (Sennerby & Meredith 1998) but one longitudinal study revealed that a decrease in ISQ values by over 20 indicated an already disintegrated, rather than disintegrating, implant (Huwiler et al. 2007).

A recent meta-analysis that included 47 studies, however, found a strong correlation between cutting torque/insertion torque measurements and resonance frequency analysis (Cehreli et al. 2009). Also, ISQ values have been seen to increase as healing proceeds, but may be influenced by bone structure and, to a lesser extent, implant length (Sim & Lang 2010). Two studies involving finite element analyses found good correlations between the level of osseointegration and RFA (Natali et al. 2006, Deng et al. 2008).

2.3.3 Periotest™ vs. Resonance frequency analysis

Both the Osstell™ and the Periotest™ devices assess implant stability immediately following insertion or at different stages of osseointegration. However, the technical method of testing the stability varies. Lachmann et al. (2006a) evaluated the reliability of the Osstell™ and the Periotest™ devices in the assessment of implant stability using an *in vitro* model of dental implants placed into bovine rib segments of different anatomical origins and densities. Eight implants were repeatedly measured for

stability and the reliability of both devices determined. Both devices showed good repeatability with the Periotest™ consistently showing measurements of ± 1 PTV units around the ‘true’ value, and the RFA Osstell™ having a repeatability within a range of less than 1% (± 1 ISQ).

Lachmann et al. (2006b), in a second experiment, assessed the performance of the two devices in an *in vitro* situation simulating peri-implant bone loss. Dental implants were polymerised into acrylic blocks with bone loss simulated by progressively removing defined portions of material surrounding the implants in millimetre increments. The repeatability of the two devices was comparable and deviations were clinically negligible. Both instruments were able to detect decreases in implant stability related to increasing peri-implant ‘bone loss’. It was found that RFA may detect bone loss somewhat earlier than the Periotest™ device and, due to its higher reproducibility, may replace the Periotest™ technique for clinical assessment and monitoring of implant stability.

Recently, the precision and usefulness of both techniques were assessed in the dog model and it was found that there was a correlation between the Periotest™ and the Osstell™ Mentor instrument (Oh et al. 2009). The authors also considered that both tests were effective for evaluating the degree of osseointegration. However, using finite element analysis, Winter et al. (2010) found that although both measuring devices reacted similarly when different parameters of implant stability, such as implant length, bone quality, and bone loss, were changed, a good correlation between Periotest™ values and implant stability quotients was only observed when measurement values of implants without bone loss were considered.

2.4 Micromotion

The original Brånemark protocol involved a long healing period of at least 3 months in the mandible and at least 5-6 months in the maxilla (Brånemark et al. 1977, Adell et al. 1981, Albrektsson et al. 1986). The rationale for this delayed healing period was that earlier loading would result in fibrous tissue encapsulation instead of direct bone apposition (Albrektsson et al. 1981, Albrektsson et al. 1986). Additionally, it was considered that the necrotic bone at the implant bed border was not capable of load-bearing and hence needed to be first replaced by newly formed bone.

Early failures caused by fibrous tissue encapsulation have not been attributed to early loading itself, but rather to the micromotion at the implant-bone interface caused by forces exerted on the healing implant (Brunski 1993, Szumukler-Moncler et al. 1998). The amount of micromotion of an inserted implant is related to the primary stability of an implant. This can be attributed to the local bone quality and quantity, the implant geometry, and the surgical technique used. Trisi et al. (2009), in an in-vitro study, found that the micromotion of an implant is highly correlated with the peak insertion torque, with greater micromotion occurring in sites with soft bone and low insertion torque.

The effect of micromotion on implants was first examined in the orthopaedic field, observing the effect of controlled motions on the interface between bone and the implanted prosthesis. Søbelle et al. (1992a) compared stable and unstable knee implants with and without hydroxyapatite coatings in the dog model. Unstable implants were subjected to 150µm of micromovement and all implants were inserted

into weight-bearing regions of the medial femoral condyles. After four weeks of function, histologic analysis showed that a fibrous membrane surrounded all implants subjected to micromovements, regardless of the coating, whereas the stable implants achieved bony ingrowth. It was concluded that micromovements between bone and implant inhibit bone ingrowth and lead to the development of a fibrous membrane. This was consistent with an earlier study which examined micromovements of 500 μm (Soballe et al. 1992b).

However, as can be seen by the clinical success of implants that have been subjected to early loading (Esposito et al. 2007), some degree of tolerance to micromotion is present to allow osseointegration in the loaded situation. Small amounts of micromotion did not prevent bone ingrowth into porous Vitallium staples in the dog model (Cameron et al. 1972), however, micromotion due to the application of up to 200 pounds of force resulted in fibrous tissue integration instead of bone infiltrating the staple (Cameron et al. 1973).

Maniatopoulos et al. (1986), using the dog model, inserted endodontic implants into bone through the interradicular bridge of the molars and the endodontic canal of the incisors, using three different implant designs: screws, smooth tapered implants, and porous cylinders. Masticatory forces applied to the implants through the periodontal ligament resulted in implant micromotion. After three months of healing, it was found that only the porous cylinder design implants osseointegrated whereas the smooth surfaced designs were encapsulated by a fibrous membrane. This would indicate that there may be a tolerance to micromotion, which, depending upon the type of implant, may not necessarily result in failure to osseointegrate.

The same mechanisms are thought to be responsible for the failures of fracture healing according to the strain theory (Perren 2002). Ideally, the ends of a fractured bone are tightly opposed and compressed, resulting in a minimal space between the pieces. This would minimise movement to a negligible amount, which is essential for healing as even small movements could induce a stretch or strain. This would result in the destruction of new cells and disruption of new vessels that are forming and bridging the gap. The failure of the bone cells to grow into the healing site allows fibrous ingrowth, leading to implant failure.

2.4.1 Reducing micromotion

Several immediate loading protocols have been developed to minimise the amount of micromotion that occurs during the initial healing phase. For overdenture cases in edentulous patients, splinting of 3-4 implants in the interforaminal area may result in survival rates comparable with implant-retained overdentures with traditional healing (Babbush et al. 1986, Chiapasco et al. 1997, Gatti et al. 2000), though success rates may be lower (Chiapasco & Gatti 2003). However, for this protocol to be predictable, several important criteria need to be fulfilled, including careful patient selection, bicortical anchorage, adequate bone quality, and the use of longer implants (Chiapasco et al. 1997). For fixed dental prostheses, two alternatives have been described. One option, developed by Schnitman et al. (1990), involves the insertion of “primary and secondary implants” into the anterior and posterior regions. The “secondary” implants support a provisional prosthesis in a broad-based tripod configuration and allow the “primary” implants to heal according to the traditional protocol. At the end of the three month healing period, osseointegrated “secondary”

implants are incorporated with the “primary” implants in a definitive prosthesis (Schnitman et al. 1990, Balshi & Wolfinger 1997, Tarnow et al. 1997). The second option involves the placement of a higher number of implants (6-10), all immediately loaded in the provisional restoration (Schnitman et al. 1990, Tarnow et al. 1997). This allows distribution of load and reduction of micromotion due to splinting of a greater number of implants. However, as the evidence for these procedures is limited, further research is required before any of these procedures can be recommended to reduce micromotion.

2.5 Implant success and survival in compromised sites

Implants are a highly successful treatment option for the replacement of missing teeth and, due to advancements in surface technology and design features of recently developed implants, it has been suggested that there will be improved survival and success rates. This would be particularly favourable in situations where implant therapy would be considered to be less predictable, such as those involving compromised sites. These could include sites with deficient bone volume, poor bone density or both. With the clinical and biological success of osseointegrated implants, there has been a vast increase in the number of patients with implant supported prostheses, with greater patient acceptance (Van Steenberghe et al. 1999) and increasing usage and range of dental implants (Jokstad et al. 2003). Outcomes of implant therapy are evaluated based upon implant success and survival. An implant is considered to be successful if ‘the element (implant or reconstruction) is present at the follow-up examination and complications are absent’ whereas it has ‘survived’ if ‘the

element (implant or reconstruction) is present at the follow-up examination but its condition is not specified' (Lang et al. 2004).

A systematic review of the incidence of biological and technical complications (Berglundh et al. 2002), consisting of 51 prospective longitudinal studies of at least five years duration, found that implant loss prior to functional loading is to be expected to occur in about 2.5% of all implants placed. During function, implant loss occurs in about 2-3% of implants supporting fixed reconstructions, while in overdenture therapy >5% of the implants can be expected to be lost during a five-year period. There was a low incidence of biological and technical complications but reporting of complications was poor (and hence may not be indicative).

Jung et al. (2008) assessed the five-year survival of implant supported single crowns and, in a systematic review of 26 included studies, found that 1.9% of the inserted implants were lost before functional loading and a further 1.5% were lost in function. This resulted in a survival rate of 96.8% for implants supporting single-tooth crowns after an observation period of at least five years, coupled with a 94.5% survival rate of the implant-supported single-tooth crowns. However, the incidence of biological and technical complications was high. The most common biological complication was peri-implantitis and soft tissue complications (9.7%) and the most common technical complication was screw or abutment loosening (12.7%).

The survival rate of implants supporting fixed partial dentures, as assessed by Pjetursson et al. (2004), was found to be 95.4% after five years with implant loss prior to functional loading detected in 2.5% of all implants and an estimated annual failure

rate of 0.51% during function. However, few studies reported on the success of therapy and the proportion of patients with minor or major complications was high (38.7%). These complications included biological complications (8.6%), such as soft tissue complications and peri-implantitis, and technical complications (30.1%), such as fracture of prosthesis veneers, screw loosening, and implant fractures.

Though the overall success rate of implants is high, implant loss is still considerable in other locations of poor bone quality (Branemark et al. 1977, Adell et al. 1990). Implants placed in the posterior region of the maxilla have been reported to have significantly increased rates of failure compared to implants placed in other regions (Glauser et al. 2001b, Alsaadi et al. 2008). This has been attributed to the variation of the local anatomy and morphology of bone, as the mandible shows a higher ratio of compact to cancellous bone.

2.6 Brånemark™ dental implants

Brånemark™ system Mk III implants (Nobel Biocare) are self-cutting, parallel-walled implants with an external hex connection (see Appendix 1). They have been in use for over 40 years, though changed from a machined surface to a TiUnite® surface in 2000. Ekelund et al. (2003) continuously followed 30 patients for 20 to 23 years and found that the cumulative survival rate of Brånemark™ implants supporting fixed prostheses in the edentulous mandible was 98.9%. Reporting of technical and biological complications was poor and it was shown that some implants would be considered to be failures due to the amount of bone loss over the observation period (Albrektsson et al. 1986).

Another long-term study investigated the outcome of implant treatment in patients with fixed prostheses in edentulous jaws after 20 years (Åstrand et al. 2008). Only 21 patients from an original cohort of 48 were reviewed, with losses due to sickness and deaths. There was a survival rate of 99.2% with a minimal mean bone loss of 0.53mm between the 1st and 20th year readings. Other long-term studies have shown similarly high survival rates (Lindquist et al. 1996, Lekholm et al. 2006, Jemt & Johansson 2006) with lower survival rates in earlier studies (Adell et al. 1981, Adell et al. 1990).

Henry et al. (1996), in a prospective five-year multicentre study of Brånemark™ implants supporting single crowns, found an implant survival rate of 96.6% in maxillae and 100% in the mandible. However, 18% of patients were lost to follow-up and should a worst-case analysis be undertaken, the cumulative survival rate would be approximately 80%. Turkyilmaz et al. (2007) compared the success and survival of Brånemark™ Mk III implants supporting single tooth crowns in the maxilla, either loaded early (6 weeks) or after a traditional healing period (6 months). After four years, survival rates were comparable (approximately 95-96%) as were success rates. Bahat (2000) followed 660 Brånemark™ system implants placed in the posterior maxilla in 202 patients for 5 to 12 years. Following placement, 2% were early failures and the cumulative success rate was 94.4% at 5 years and 93.4% at 10 years. This showed that in a region typically considered to have poor bone quality, a high rate of success can be achieved with Brånemark™ system implants.

2.7 TiUnite™ implant surface

Nobel Biocare™ implants, including the NobelActive™ and Brånemark™ implants, have a TiUnite™ implant surface, which is a highly crystalline and phosphate enriched titanium oxide characterised by a microstructured surface with open pores in the low micrometre range. Introduced in 2000 (Hall & Lausmaa 2000), it is the surface coating of all recently produced Nobel Biocare™ implants. Studies have shown a more robust early bone response to the TiUnite™ surface than to machined surfaces (Albrektsson et al. 2000, Henry et al. 2000, Glauser et al. 2001a, Rocci et al. 2003).

Huang et al. (2005) placed a total of 24 TiUnite™ implants into eight Cynomolgus monkeys to evaluate local bone formation and osseointegration in type IV bone. There was a high incidence of surgical complications, including four implants which did not achieve primary stability and four implants penetrating the subantral space. The monkeys were euthanised at 16 weeks post-insertion and the local bone formation and osseointegration were assessed. It was observed that a thin layer of new bone covered most of the implant threads, with a mean bone-implant contact of 74.1%. It was concluded that the surface possesses a considerable osteoconductive potential, however, no comparative control group was available.

The osteoconductive potential of the TiUnite™ surface was examined by Xiropaidis et al. (2005) in a study that compared the bone-implant contact at a relatively smooth, highly crystalline calcium phosphate coating with a structured, porous titanium oxide (TiUnite™) modified surface. Using a dog model, with the animals euthanised at

eight weeks post surgery, the average bone-implant contact was significantly greater for the TiUnite™ surface (71% vs. 57%). It was concluded that the modified titanium oxide surface exhibited osteoconductive properties exceeding that of the calcium phosphate surface.

Friberg & Jemt (2010), in a retrospective investigation of 110 subjects, evaluated the five-year implant survival and marginal bone response of Brånemark™ MkIII implants with the TiUnite™ surface. One group of examined patients had a mixed complement of implants which included both moderately rough and machined surface implants. Due to the low number of losses, no significant differences were found in the survival rates or marginal bone losses between the two surfaces.

A short-term study compared the TiUnite™ surface with turned implant surfaces with respect to implant failure using both one- and two-stage protocols with traditional healing (Jungner et al. 2005). A total of 394 implants were placed in 136 patients, with two different groups of implants that had identical designs but had different surfaces. With a mean follow-up of 14 months for the TiUnite™ surface implants, no TiUnite surface implants were lost, however the survival rate of the turned surface implants was 96.4% over a mean follow-up period of 18 months. Over a 4-5 year follow-up period, TiUnite™ surface implants were also found to be successful in immediate loading (Glauser et al. 2007, Ostman et al. 2008) and early loading situations (Turkyilmaz et al. 2007). High implant survival rates of 99.3% after 3 years of loading have also been reported for TiUnite™ surface implants placed in compromised maxillary bone (Bahat 2009).

2.8 Placement protocol

Implant-supported prostheses placed in fully healed and non-compromised alveolar ridges have high clinical success and survival rates (Pjetursson et al. 2004, Jung et al. 2008). However, due to increasing patient demand, changing patient needs (function and aesthetics), greater practitioner confidence, and rapidly developing technology, there has been a movement towards reducing healing times and earlier implant placement.

The original Brånemark protocol advocated implant placement in two stages (Branemark et al. 1977) to allow for undisturbed, submerged osseointegration of the implant. It was believed that the implant required soft tissue coverage to eliminate bacterial contamination and avoid epithelial downgrowth between the bone and implants. An extended healing time of three months in the mandible and six months in the maxilla (Adell et al. 1981) was encouraged to allow successful osseointegration. Loading of the site was avoided as overloading was considered to be a cause of implant failure, and hence removable prostheses were sometimes avoided during the healing period. The second-stage surgery involved exposure of the implant and connection of the abutment. Six to eight weeks of healing followed, allowing time for the establishment of the soft-tissue barrier prior to any prosthetic restoration. Thus, according to the original Brånemark protocol, the total treatment time would be at least five months in the mandible and eight months in the maxilla.

The next stage in the evolution of timing protocols was the advancement to one-stage implants. As submergence of the implant was not considered a prerequisite for

successful tissue integration by the International Team for Oral Implantology, development of implants for one-stage surgical procedures occurred, with good clinical results (Buser et al. 1990). Ericsson et al. (1994), using a split-mouth technique, placed one- and two-stage Brånemark™ implants into edentulous mandibles with no short-term implant failures. There was continual follow-up until five years, with no failures in either group (Ericsson et al. 1997). Further studies involving Brånemark™ implants confirmed that the one-stage surgery protocol was a viable option with equivalent success as the original two-stage protocol (Bernard et al. 1995, Becker et al. 1997, Collaert & De Bruyn 1998). The benefits of the one-stage implant procedure include fewer patient surgeries, less time between abutment placement and final prosthetic restoration, and potentially reduced patient expense.

Becktor et al. (2007) compared a four Brånemark™ placement protocol with a six Brånemark™ placement protocol in fully edentulous mandibles, with follow-up for more than one year. Two groups of patients were examined, with 198 implants placed according to a one-stage protocol and 206 implants placed according to two-stage protocol. No significant difference for implant failures was found, though greater complications occurred more frequently in the one-stage group.

Esposito et al. (2009a), in a Cochrane systematic review, investigated the effectiveness of one- and two-stage implant placement. Five randomised controlled trials were identified, with a total 239 patients, and the meta-analyses showed no significant differences for prosthesis and implant failures. The author concluded that the two-stage submerged approach could be indicated when an implant did not obtain optimal primary stability, or when guided tissue regeneration was adjunctively

performed, or when it was expected that removable temporary prostheses could transmit excessive forces on the penetrating abutments, especially in fully edentulous patients.

As the pursuit of reducing treatment time to a minimum progressed, clinicians aimed to reduce the healing time post extraction as this comprised the greatest proportion of the treatment time. Protocols were developed based upon the stages of healing post-extraction, with immediate placement following tooth extraction and delayed placement following soft tissue healing. A classification based upon the observed hard and soft tissue changes was proposed (Chen & Buser 2008):

- Type 1 placement: Immediate placement into an extraction socket with no healing of bone or soft tissues
- Type 2 placement: Early placement into a postextraction site with healed soft tissues but without significant bone healing (typically 4 to 8 weeks of healing)
- Type 3 placement: Early placement into a postextraction site with healed soft tissues and with significant bone healing (typically 12 to 16 weeks of healing)
- Type 4 placement: Late placement into a fully healed socket (more than 6 months of healing).

Reviews of the literature have shown that the survival rates of immediately, early, or delayed placed implants are comparable with those of implants placed in healed alveolar bone (Schropp et al. 2005, Esposito et al. 2009b, Chen & Buser 2009).

2.9 Monitoring of implants

A key factor in implant maintenance is regular examination and monitoring (Bragger 1994) in order to facilitate early detection of pathology and treatment (Heitz-Mayfield 2008). Regular assessment of the implant is essential for determination of success of an implant as it allows identification of complications affecting an implant-supported restoration. Early treatment of complications will maximise the survival of an implant. For example, a common cause of late implant failures is peri-implantitis. As the peri-implantitis bone defect is a well demarcated, saucer-shaped lesion that retains osseointegration at the apical part of the implant, the resorption may proceed without any notable signs of implant mobility until osseointegration is completely lost. Additionally, because the oedema and erythema of the marginal tissues is not always prominent and the disease is symptomless (Mombelli 1999), patient self-reporting may be unlikely. Use of a periodontal probe is essential for diagnosis as probing is a reliable indicator of disease. An increase in probing depth over time is associated with attachment and bone loss. Baseline probing measurements should be taken at the time of placement of the suprastructure and repeated annually.

Bleeding on probing (BOP) is an important parameter for the diagnosis of mucosal inflammation (Mombelli et al. 1987) and though BOP is a poor positive predictor of disease activity (Badersten et al. 1985, Lang et al. 1986), its absence is a reliable indicator for stability of attachment surrounding teeth (Lang et al. 1990) and implants (Lang et al. 1994, Jepsen et al. 1996).

Suppuration in an implant site is often a sign of peri-implantitis (Roos-Jansåker et al. 2006, Fransson et al. 2008) and mobility is an indication of failure to osseointegrate or loss of osseointegration, requiring removal of the implant.

As clinical signs of peri-implantitis and other complications may not always be evident, standardised radiographs should be taken one year after implant placement and every alternate year thereafter (Mombelli 2002) to monitor marginal bone levels. This may include panoramic and intra-oral paralleling radiography to diagnose interproximal bone loss (Kullman et al. 2007). Subtraction radiography (Nicopoulou-Karayianni et al. 1997), multislice computer tomography, and cone beam volume imaging are also useful in the monitoring of implants (Mengel et al. 2006).

Additional clinical tests such as salivary analysis, peri-implant crevicular fluid analysis, and microbiological testing (Luterbacher et al. 2000) have been suggested to be beneficial adjuncts to diagnosis and prediction of disease progression. Resonance frequency analysis has also been shown to detect minor changes in the level of bone-implant contact (Meredith et al. 1996, Sennerby et al. 2005).

Roos-Jansåker et al. (2006) attributed the relatively high prevalence of complications and bone loss in their study to the absence of a structured supportive periodontal care program. Clinical supervision of a patient's implant situation with a good recall program should continue indefinitely (Tolstunov 2006).

2.10 Radiographic monitoring of implants

The long-term survival of the implant is dependent upon the osseointegration of the implant and hence the quality and apposition of bone around the implant is of utmost importance. The peri-implant bone should be monitored and periodically assessed. However, as bone quality and volume cannot be thoroughly assessed clinically, methods of radiological peri-implant bone assessment need to be utilised, including intraoral radiography (IR), panoramic radiography (PR), computer tomography (CT) and cone beam computed tomography (CBCT).

Though the use of intraoral radiographs (with long cone paralleling technique) and orthopantograms is more commonplace and exposes the patient to a lower effective radiation dose (relative to CT and CBCT), there are several significant disadvantages. With standard periapical radiographs and PR, only the mesio-distal bone surrounding implants can be assessed, with superimposition of the implant over the buccal and lingual aspects. Only two-dimensional images can be produced and volumetric quantification is not possible. Additionally, though PRs can be standardised with patient positioning and exposure times, the standardised evaluation of bone density and volume using IR is greatly influenced by variations in anatomical factors, radiographic beam angulation, quality of film development, and measurement errors (Pharoah 1993, Grondahl et al. 1998).

2.11 Standardisation of periapical radiographs

Alveolar bone changes surrounding implants can be monitored using digital radiographs or by digitisation of conventional radiographs in order to perform computer-aided subtraction. As about 30-50% of bone mineral must be lost before bony changes are visibly detectable in conventional radiographs (Dreyer 1993), conventional radiographs alone are inadequate to monitor changes in bone volume and density surrounding a natural tooth or implant. Subtraction radiography involves the subtraction of an original radiograph from a subsequent radiograph in order to visualise the changes that have occurred, which are taken in a standardised way.

In order to obtain standardised periapical radiographs for subtraction, studies utilising this method construct a custom-made acrylic or putty bite block for each area of interest. This bite block is attached to a modified film holder, which provides a rigid attachment of the bite block to a custom attachment on the X-ray machine cone. As a consequence, the angulations between the X-ray source, the object and the film are standardised. All radiographs are taken using the same X-ray machine at the same setting and the image may be captured on a charge-coupled device, phosphor plate, or plain film. Plain films can be scanned into a computer at 600dpi using a flatbed scanner, thus digitising the image for analysis.

2.12 Digital subtraction radiography

Woo et al. (2003) developed and validated a digital subtraction radiography program based upon a Linux system. Digitised images are imported into the subtraction

software allowing analysis of the alveolar bone changes. The first step in the software is to align the paired images by selecting the same sets of two reference points. The software then compares the coordinates of the reference points and moves the subsequent image vertically, horizontally, and rotationally until the pairs of images are matched. Pixel-by-pixel movement of the subsequent image can be performed manually whenever necessary. Grey-level normalisation is performed non-parametrically using a cumulative density function (Ruttimann et al. 1986). After normalisation, the images are digitally subtracted. The selected sites are defined as regions of interest on the radiographs. The computer-assisted densitometric image analysis (CADIA) value is calculated for each region of interest according to a formula described by Brägger (1988). CADIA value is used to quantify alveolar bone changes and is presented as a net value between two standardised radiographic images at different time points.

Paired radiographs are taken at the same appointment and processed together in different patients randomly in order to determine the threshold used for the digital subtraction radiography system (Woo et al. 2003). This threshold value is then applied in all subsequent digital radiographic subtractions and allows for the small degree of variability involved in using separate radiographs.

The use of subtraction radiography is not a new concept and has been utilised in dentistry for several decades (Webber et al. 1990, Grondahl et al. 1983, Hausmann et al. 1985). Grondahl et al. (1987) found that there was a higher inter-observer agreement in estimating periodontal bone changes from subtraction radiographs compared to conventional radiographs.

Janssen et al. (1989) examined the detection thresholds of different radiographic methods in the study of a dry human mandible. Bone cylinders at interdental sites were removed, with a variation in the diameters of the artificially created lesions (that sequentially increased in size by 0.1mm diameter). The lesions were assessed using conventional radiographs, photographically subtracted radiographs, and quantitative digital subtraction technique. The radiographs were observed by 10 individuals who were to label each radiograph as producing a 'signal' (presence of a lesion) or 'no signal' (no lesion) and this was repeated three times for each radiograph with a interval of one week between viewings. The detection threshold was defined as the smallest defect in a series of at least three consecutive increasing defect sizes which was consistently detected at the three examinations performed at intervals of one week. It was found that the smallest periodontal bone changes were detected with the quantitative digital subtraction technique compared to the other methods. However, had the experiment been *in vivo*, results may have varied due to the difficulty of standardising X-ray images and changes in exposure parameters between baseline and follow-up examinations. Other *in vitro* studies have examined the sensitivity of digital subtraction radiography (Nicopoulou-Karayianni et al. 1991).

2.13 Subtraction radiography and periodontics

Digital subtraction radiography has also been used to assess the progression of untreated periodontitis (Hausmann et al. 1986), the efficacy of potential new treatments for periodontitis (Jeffcoat et al. 1991), the bone changes after guided tissue regeneration (Wenzel et al. 1992), treatment of furcations (Cury et al. 2004), and periodontal treatment in general (Grondahl et al. 1987, Reddy 1992, Hausmann 2000,

Nummikoski et al. 2000). Quantitative analysis of the greyscale information was developed to allow assessment of the amount of bone loss and gain (Jeffcoat 1992). Recently, digital subtraction radiography has been used to assess the effect of cigarette smoking on alveolar bone (Rosa et al. 2008). The selection of areas of interest in the proximal sites allowed determination of CADIA values, which were related to bone density changes.

Toback et al. (1999) compared the ability of two forms of radiographic analyses (linear measurement and CADIA) to assess postsurgical bone fill as measured at a re-entry procedure. Forty-five intrabony defects that were regenerated were evaluated, comparing baseline and one-year results. The study found that linear measurements tended to underestimate the bone fill, whereas a combined linear-CADIA method provided the highest level of accuracy. Notably, however, 53% of the sites were excluded from the study due to poor standardisation or poor defect quality and 40% of all pairs of radiographs were judged to have poor standardisation. Hence the study emphasises the importance of utilising a consistent method of radiographic standardisation.

Bittar-Cortez et al. (2006) compared the peri-implant bone density assessed by the mean grey value of the histogram in digitised conventional radiographs and two digital subtraction image methods: linear and logarithmic. Thirty-four patients were monitored by standardised radiographs one week after surgery and four months later. Linear and logarithmic subtraction methods are similar but in the latter, there is enhancement of small differences and, at the same time, noise and contrast also increases. It was found that all three methods of analysis were effective in detecting

bone density surrounding an implant, with no significant differences between the methods. Other authors have used digital subtraction radiography clinically to assess the bony healing around implants (Wakoh et al. 2006), the bony changes in the treatment of peri-implantitis (Schou et al. 2003), the effects of drug administration (Sakakura et al. 2007), and also to assess the effect of homeopathic medicine on osseointegration (Sakakura et al. 2008).

2.14 Cone beam computed tomography and implant monitoring

Cone beam computed tomography or volumetric tomography was developed during the 1990s (Arai et al. 1999) and the first machines became commercially available during 2000 (Terakado et al. 2000, Ito et al. 2001a). As the technology developed, scan times became faster and the radiation dose reduced, thus increasing the appeal of CBCT to more practitioners. There are now several machines available on the market, including the i-CAT and Newtom CB3D scanners, and scanners are constantly being refined and upgraded.

Similar to conventional multi-slice CT, CBCT allows three-dimensional visualisation of the oral hard tissues, though there are some fundamental differences. Whereas conventional CT scanners use a fan-shaped beam with the transmitted radiation taking the form of a helix or spiral, CBCT scanners utilise a cone beam that encompasses a large volume in a single rotation around the patient (Arai et al. 1999). Volumetric image acquisition is then achieved using an image intensifier or flat panel detector. Data from CT is interpolated by the scanner into a set of slices, producing a volume. CBCT data is reconstructed using algorithms to produce three-dimensional images at

high resolution. Additionally, CT scanners require the patient to be supine during image acquisition, whereas the majority of CBCT scanners position the patient in a seated or standing position.

As cone-beam technology is based upon complex-motion tomography, the radiation dose is lower than a multi-slice CT scan of the jaws (Hashimoto et al. 2003) though the reduced exposure results in a reduction in soft tissue contrast and increased intrusion of noise (Ludlow et al. 2003, Schulze et al. 2004).

2.14.1 Accuracy of cone beam computed tomography

The accuracy of cone beam computed tomography in dentistry has been widely examined in the past years, spurred by the increase in usage of this radiographic method. Sherrard et al. (2010) assessed the accuracy and reliability of an i-CAT machine at evaluating tooth and root lengths in porcine heads. Different voxel sizes were used and the measurements were compared to periapical radiographs. While the periapical radiographs could overestimate or underestimate root and tooth lengths by up to a mean of 2.58mm, the CBCT could reproducibly and accurately measure with a mean error of less than 0.3mm.

Using an *in vitro* geometric model, Marmulla et al. (2005) found that the mean variation in measurement was 0.13mm with a maximum deviation of 0.3mm, when using the NewTom 9000 scanner (NewTom AG, Marburg, Germany). Using the same CBCT scanner, Lascala et al. (2004) compared direct large measurements of eight dry skulls with linear measurements obtained in CBCT images. It was found that the

CBCT tended to underestimate the measurement but the difference was only significant when measuring the skull base. Additionally, measurement of anatomical structures on CBCT scans may be affected by operator influence and subjectivity. Using CBCT to evaluate the accuracy of three-dimensional measurements, Pinsky et al. (2006) assessed *in vitro* simulated bone defects in an acrylic block and a human mandible. Volume measurements showed that manual measurements of CBCT scans had a mean inaccuracy of -6.9mm^3 compared to direct volumetric measurements. Other studies have found similar accuracies (Ballrick et al. 2008, Stratemann et al. 2008, Damstra et al. 2010, Liu et al. 2010).

2.14.2 Cone beam computed tomography and periodontics

Measurement of periodontal defects using CBCT may show accuracy comparable to traditional radiography with the additional benefit of visualisation of buccal and lingual lesions (Misch et al. 2006). They may also provide greater imaging quality in comparison to IR, PR, and CT techniques, with comparable measurements of periodontal defects to histological specimens (Mengel et al. 2005, Stavropoulos & Wenzel 2007). Mengel et al. (2006) compared the accuracy and quality of IR, PR, CT, and CBCT measurements in the examination of peri-implant defects in native pig mandibles. Examining dehiscences, fenestrations, and 2- to 3-walled intrabony defects, it was found that CBCT yielded the most accurate measurements compared to direct stereomicroscope measurement, with a mean deviation of $0.17 \pm 0.11\text{mm}$. The subjective quality rating of CBCT scans, based upon contrast, brightness, distortion, overlay, clarity, and focus, was also the greatest of the radiographic methods. These results were supported in a recent study in a clinical situation (Grimard et al. 2009). A

case report showed that regeneration of bone in a furcal defect could be more accurately monitored using CBCT compared to IR (Ito et al. 2001b).

However, examining natural buccal alveolar fenestrations and dehiscences on dry human skulls, Leung et al. (2010) found that assessment of the buccal bone overlying roots was less accurate than reported with the artificially created defects in previous studies. A higher number of false positives and negatives occurred with CBCT assessment and this was attributed to the spatial resolution limitations of the CBCT, which meant that areas with bone less than 0.6mm thick were seen on the image as areas without bone. Thicknesses of bone less than 0.6mm were indistinguishable from the root surface. Hence, naturally occurring defects, with indistinct and gradually changing margins, may be less accurately detected compared with artificially created defects.

2.14.3 Cone beam computed tomography and implants

Monitoring of peri-implant bone levels and detection of peri-implant diseases could ideally be achieved using CBCT as an adjunct to clinical examination. However, X-ray imaging techniques are prone to produce artefacts with the presence of metal in a radiographic field of view. Beam hardening is the most common artefact associated with implants and occurs when a high-density object in the path of the beam absorbs all the X-ray photons of lower energy. This means that the X-ray beam gradually gets 'harder', that is, contains photons of higher energy. Schulze et al. (2009) found that a typical implant body absorbs large amounts of low-energy radiation whereas high-energy radiation is only marginally absorbed. This resulted in the CBCT analysis

overcompensating for this effect, resulting in an artefact on the reconstruction. This can affect the quality of CBCT images and lead to inaccurate or false diagnoses (Zhang et al. 2007).

Thus, though CBCT scans are reliable and accurate in dental treatment with a rapidly expanding repertoire of applications, there is no evidence supporting the use of CBCT in the post-placement monitoring of implants, despite the increasing usage of CBCT for implant assessment. However, it is still the most accurate and reliable method of assessing 3D bone level changes around an osseointegrating implant, especially in the buccal and lingual/palatal areas.

2.15 Dental radiography and radiation dosage

The primary aim of any modality of dental radiography is to provide adequate, useful, and adjunctive information in order to aid diagnosis and treatment planning. With regard to implants, information regarding bony morphology, bone quality, and location of anatomical structures are provided almost entirely by radiographs alone and hence they are considered essential for planning and monitoring. CBCT is currently advocated for the assessment of the jaws prior to implant placement (Guerrero et al. 2006). Overlying all considerations, however, is the requirement to minimise the exposure of the patient to ionising radiation in adherence with the ALARA principle (as low as reasonably achievable).

The International Commission on Radiological Protection (ICRP) is an advisory body providing recommendations and guidance on radiation protection. The

recommendations of radiological protection aim “to provide an appropriate standard of protection for man without unduly limiting the beneficial actions giving rise to radiation exposure”. The latest guidelines (Wrixon 2008) establish thresholds on the maximum individual dose (from specified sources) for safe radiation doses to patients and also quantify tissue weighting for effective dose calculations. For situations that have a societal benefit but no individual benefit, in a single year, the 2007 ICRP guidelines recommend a Maximum Effective Dose of 1mSv or 1000 μ Sv.

Effective dose is used to compare the stochastic risk, such as carcinogenesis and hereditary effects, of a non-uniform exposure of ionising radiation with the risk caused by a uniform exposure of the whole body. As different body tissues have different susceptibilities to radiation, the effective dose is calculated using the equivalent dose to different body tissues and the weighting factors designed to reflect the different radiosensitivities of the tissues. Additionally, the 2005 and 2007 Recommendations apply individual tissue weighting to the salivary glands and brain tissue, which were not included in the 1990 Recommendations. Hence, for dental radiography, which has a high possibility of including susceptible body tissues, the effective dose of different modalities increased due to increased tissue weightings.

The effective doses of different modalities of dental radiography vary depending upon the settings of the X-ray unit, including the kilovolt potential (kVp) and tube current (milliamperes). Additionally, effective doses have been reduced due to the use of collimation, intensifying screens and digital enhancement of images. Ngan et al. (2003) compared the radiation doses of facial CT scans with the radiation doses when taking a lateral cephalometric radiograph, a panoramic radiograph (OPG), an occlusal

film, and an intra-oral periapical radiograph. Doses were as follows (based upon 1990 ICRP guidelines):

Long-cone paralleling periapical radiograph	5 μ Sv
Panoramic radiograph (OPG)	10 μ Sv
Mandibular CT scan	1320 μ Sv
Maxillary CT scan	1400 μ Sv
Maxillo-mandibular CT scan	2100 μ Sv

The effective dose of CBCT scans has been shown to be greater than conventional dental radiographs and panoramic radiographs but lower than conventional CT scans (Arai et al. 1999). A review of multiple CBCT machines has found that the effective dose of a CBCT scan ranges from 52 μ Sv to 1025 μ Sv (Monsour & Dudhia 2008) and of four machines assessed, the i-CAT CBCT machine had the best image quality for the radiation dose (Loubele et al. 2008). Studies evaluating the effective dose of the i-CAT CBCT machine vary depending upon the tissue weighting. Using the 2007 Recommendations (which were the same as the 2005 draft recommendations), the effective dose of an i-CAT full field of view scan (of the maxillae and mandible) is approximately 101.5 μ Sv (Brooks 2005), up to 193 μ Sv (Ludlow et al. 2006). Recently, Roberts et al. (2009) found that the effective dose of a high resolution scan of the mandible is 188.5 μ Sv and a high resolution scan of the maxilla is 93.3 μ Sv. Standard resolution scans and full 13cm scans (compared with combined single scans) produced much lower effective doses of radiation. Thus, based upon radiation exposure to patients, the i-CAT CBCT scanner could be safely used to longitudinally assess implant osseointegration should the need be warranted.

2.16 Bony remodelling following implant placement

The use of standardised radiographs, CBCT scans, and digital subtraction radiography to monitor implants has provided information about remodelling of the proximal bone surrounding the implants of different implant systems, though there are methodological limitations relating to the evaluation of non-standardised radiographs using reference dimensions of implants (Bragger 1998).

A 15-year study of machined implants indicated that the alveolar bone loss during the first year after abutment connection averaged 1.2mm, with subsequent annual bone loss thereafter remaining at approximately 0.1mm (Adell et al. 1981). This led Adell (1983) to propose that the success of implant therapy should be judged after a year of service and this concept was propagated when Smith and Zarb (1989) suggested that one of the criteria for implant success is that less than 0.2mm of alveolar bone loss occur per year after 12 months. This is supported by a recent study which found that clinically significant remodelling of the marginal bone occurs during the first six months after implant placement, with a mean marginal bone loss of 2.44 ± 1.22 mm (Cochran et al. 2009). Additionally, there are minimal marginal bony changes occurring after placement of a restoration and in the subsequent years.

The reported mean bone loss pattern for two-stage Brånemark™ type implants is 1-1.5mm in the first year following implant insertion and less than 0.2mm in subsequent years (Lindquist et al. 1988, Albrektsson et al. 1986, Quirynen et al. 1992), with a characteristic ‘saucerisation’ in the marginal bone.

Numerous longitudinal radiographic studies have assessed the initial bone remodelling that is associated with placement using a one-stage protocol with a one-piece implant design. Weber et al. (2000) reported a mean of 0.6mm of radiographic bone loss within the first year of placement without any significant annual changes for visits up to five years. Other studies reported results for one-stage ITI implants as being 0.75-1mm crestal bone loss at 12 months and less than 0.1mm annually in the following years (Weber et al. 1992, Bragger et al. 1998, Pham et al. 1994).

When the bone levels were assessed at three-monthly reviews, it was found that more than 50% of the total bone loss recorded in a 12-month period occurred in the first three months (Jung et al. 1996). This was attributed to periosteal elevation, surgical trauma during implant placement, and stress concentration as a result of torquing of the implant (Adell et al. 1986, Quirynen et al. 1992). The bone level stabilised at the margin of the polished neck or at the first thread of the implant (Jung et al. 1996). Studies in both patients with mandibular edentulism (Behneke et al. 2002) and partial edentulism (Behneke et al. 2000) reported that the initial bone remodelling from the time of implant placement to functional loading was greater than the subsequent bone-remodelling over a five- year period.

The influence of the implant surface on the marginal bone level after functional loading has been examined quarterly, comparing the marginal bone loss occurring in the first twelve months around machined and rough surface necks. All types of implants showed the greatest amount of significant bone loss within the first three months following functional loading, with machined neck implants showing greater loss than rough surface implants (Shin et al. 2006). Non-submerged implants also

have demonstrated greater early marginal bone loss in the maxilla than in the mandible after the first year of function (Weber et al. 1992, Bragger et al. 1998).

The causes of early implant crestal bone loss has been reviewed by Oh et al.(2002), with potential causes that include surgical trauma, occlusal overload, peri-implantitis, presence of a micro-gap, biologic width, and the concept of the implant crest module. However, no definite singular cause has been identified.

Thus, following dental implant placement, a certain amount of bony remodelling is expected within the first few months. With bone level implants, it can be assumed that bone remodelling will result in 1-1.5mm of bone loss within the first year, with stabilisation to the first thread of the implant. One-piece implants will similarly undergo marginal resorption to the rough-smooth border (Hermann et al. 2000). In the subsequent years, the bone height changes are minimal around a healthy implant.

2.16.1 Platform switching

Platform switching involves the connection of a smaller diameter abutment relative to the platform diameter of the titanium implant (Prosper et al. 2009). This creates a 90° step between the implant and abutment (Gardner 2005, Lazzara & Porter 2006) and aims to influence the remodelling of the marginal bone surrounding the implant. As a consequence of the reported benefits of platform switching, an increasing number of implant systems have incorporated platform switching into their designs to preserve peri-implant bone.

The remodelling process of the marginal bone has been attributed to several factors, including surgical trauma to the periosteum and bone (Gomez-Roman 2001), bacterial colonisation of the micro-gap at the implant-abutment interface (Ericsson et al. 1995, Hermann et al. 2001b, Weng et al. 2008), biological width and soft tissue considerations (Berglundh & Lindhe 1996), micro-movements of the implant and prosthetic components (King et al. 2002), and repeated abutment dis/reconnection (Abrahamsson et al. 1997). The concept of platform-switching is not fully understood, though several theories have been proposed to explain this phenomenon. One theory suggests that the transference of the implant-abutment connection medially shifts the location of the biologic width, reducing marginal bone resorption (Grunder et al. 2005, Lazzara & Porter 2006). This theory arose from studies that found that placement of the implant-abutment junction below the level of the marginal bone resulted in vertical bone resorption to re-establish the biologic width (Hermann et al. 2001a, Todescan et al. 2002). The biomechanical theory suggests that the platform switching shifts the stress concentration zone away from the bone-implant interface and directs occlusal forces along the axis of the implant (Maeda et al. 2007, Schrottenboer et al. 2008), while another theory suggests that the bone resorption is caused by an inflammatory cell infiltrate at the implant-abutment interface (Ericsson et al. 1995).

The concept of platform switching incidentally arose as a result of the commercial introduction of wide-diameter implants in the 1980s. Wide-diameter implants were restored with standard-diameter abutments due to the lack of matching prosthetic components, which, as reported by several clinical reports, led to maintenance of post-loading marginal bone levels (Fickl et al. 2010). Wagenberg and Froum (2010),

in a long-term prospective study with a follow-up period of 11-14 years, found that the majority of the 94 platform-switched implants (>84% of interproximal surfaces) had ≤ 0.8 mm of marginal bone loss. However, no control group was included for comparison. Several randomised controlled trials have examined the outcomes of platform-switching with both beneficial (Prosper et al. 2009, Canullo et al. 2010) and negligible results (Becker et al. 2009, Vigolo & Givani 2009). A recent systematic review examined ten studies with a minimum of twelve months of follow-up (Atieh et al. 2010). It was found that the marginal bone loss around platform-switched implants was significantly less than platform-matched implants and there was a more favourable bone response if the diameter difference was ≥ 0.4 mm. No difference in implant survival was found.

It has also been suggested that platform-switched implants can also be used in anatomic sites where the recommended minimum distances between implants and adjacent units cannot be achieved (Rodriguez-Ciurana et al. 2009a).

Hence, platform switching may potentially have a beneficial effect on the amount of peri-implant marginal bone resorption compared to implants with matched diameter abutments.

2.17 NobelActive™ dental implants

NobelActive™ implants are the latest implant design from Nobel Biocare®, launched in May 2007. The indications for placement of NobelActive™ implants, as recommended by Nobel Biocare®, includes all bone types (based upon the

classification by Lekholm and Zarb (1985)) and all procedures for replacement of single and multiple missing teeth in all areas of the dentition. Though a two-stage surgical procedure can be used, immediate placement and function protocols have been emphasised.

Clinical benefits of the design have been identified by Nobel Biocare® as the increased ease of redirection of implant axis during insertion, speedier placement due to the implant thread pitch, high initial stability, and bone-condensing property (see Figure 2.1, Appendix 1 and 2).

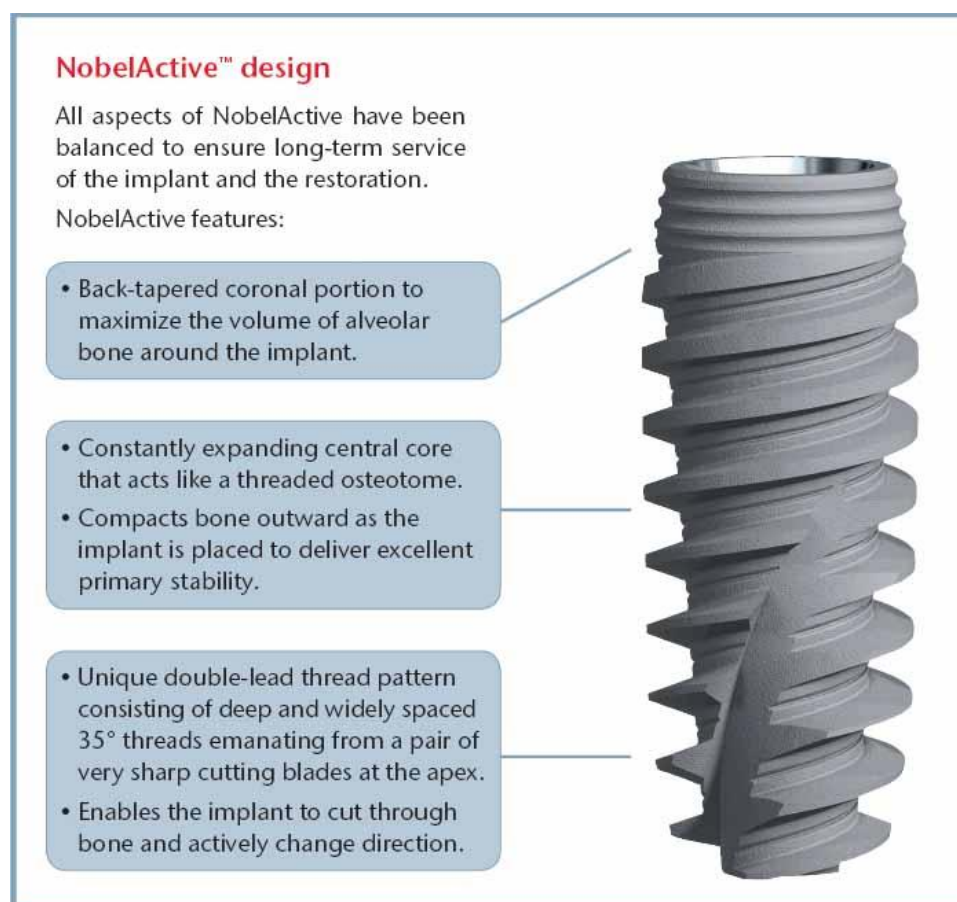


Figure 2.1: NobelActive™ design

The NobelActive™ implant design is based upon the SPIRAL implant (AlphaBio, Petach-Tikva, Israel), which similarly is self drilling, self-tapping, and self-condensing. A retrospective study assessing the survival rate of the SPIRAL implant was presented as a poster at the Nobel Biocare World Conference in Las Vegas (Karmon et al. 2007). A total of 648 implants were placed in 251 patients, in all areas of both maxillary and mandibular jaws, following a variety of loading protocols: immediate, early, and delayed loading. Both healed and extraction sites were included and 2.3% had previous augmentation procedures. Some sites were augmented at the time of implant placement and insertion into augmented maxillary sinuses also occurred with the follow-up period ranging from 12 to 48 months (mean time 27.4 months). A cumulative survival rate of 98.9% for one year and 98.3% for four years (110 implants) was found, though no success rates were reported.

At present, there are a limited amount of published studies involving the use of NobelActive™ implants. Kielbassa et al. (2009), in a multi-centre, randomised controlled trial, compared NobelActive™ Internal, a tapered implant with variable-thread design, and NobelActive™ External, a transmucosal tapered implant with variable-thread design, with NobelReplace™ Tapered Groovy, a standard tapered implant. A total of 177 patients were included in the study with 325 implants being placed in healed sites. Almost all implants were immediately non-occlusally loaded. As the study involved 12 centres, there was some variation in protocols between subjects, no standardisation of radiographs, and stability was assessed clinically without the use of objective measures such as resonance frequency analysis or damping capacity assessment. There were no significant differences in survival rate between the treatment groups over the one year observation period but no success

rates were published. Additionally, though no significant differences in bone remodelling between the different treatment groups were found, there was a greater number of implants in the NobelActive™ Internal group which lost greater than 1.0mm of bone compared with the NobelActive™ External and NobelReplace™ groups. The insertion torques for all implants were presented in a column chart showing that the NobelActive™ implants were generally placed at higher torques than the NobelReplace™ group. However, all groups had some implants inserted at up to 100Ncm of torque (above the recommended force). This entire study group is under ongoing observation and further studies on the NobelActive™ implant are currently underway.

Irinakis and Wiebe (2009b) examined the initial torque stability of the NobelActive™ implant, with 140 implants placed in 84 consecutive patients. Implants were placed in healed sites and immediately into extraction sockets. The insertion torque was measured using a manual torque control wrench with the quality of bone being assessed at time of placement. The mean insertion torque of immediate implants was 52.6Ncm, whereas implants placed in healed sites were inserted at a mean of 49.7Ncm. It was noted that placement into soft bone similarly involved a high insertion torque, greater than conventional parallel walled and tapered implants. The authors concluded that the high insertion torque would deem the NobelActive™ implants suitable for early provisionalisation and loading.

In a further study by the same authors, a case series of 107 NobelActive™ implants was presented (Irinakis & Wiebe 2009a). Implants were placed in 67 patients and the features of the implant design were reviewed. It was concluded that the implant

exhibited the properties that the manufacturer claimed. However, they stated that the implant did not replace conventional parallel walled or tapered implants but instead provided an adjunctive treatment option, mainly due to its ability to achieve primary stability in compromised situations. Similarly, an article by Orientlicher and Teich (2010) described the clinical features of the NobelActive™ implant and presented two case reports involving the system.

At present, there are no published studies on the success rates of the NobelActive™ implant. Though unpublished ongoing studies have shown promising early results, the absence of long-term results precludes the capability to substantiate the potential quoted benefits of this new implant design and its indicated usage in compromised implant site situations.

2.18 Summary of literature review

The NobelActive™ dental implant is a recently released design that, despite being based upon an older design of implant, has limited published clinical data detailing its survival and success rates. Based upon its design features, it has been proposed that the implant provides greater primary stability and hence improves implant osseointegration and success, especially in compromised site situations. As implant stability has been shown to be integral to implant success, the initial assessment of stability and regular monitoring of stability, using means such as damping capacity and resonance frequency assessment, are essential to evaluate the success of an implant. Achieving good primary stability minimises the amount of micromotion, reducing the possibility that the implant will fail to osseointegrate. Implants have been

shown to have high survival and success rates and hence, new designs of implants should be compared to similar implants with published clinical success. However, compromised implant sites, such as areas of poor quality or quantity, show lower rates of success. Though long-term data is available regarding the clinical outcomes of other comparable implants and surfaces, clinical evidence is lacking for the NobelActive™ internal connection implant specifically. To assess an implant, clinical monitoring and radiographic evaluation over the long-term involves clinical assessment and use of standardised radiographs and cone beam computed tomography. The use of radiographs is essential for monitoring peri-implant bone levels and has been used extensively in implant dentistry, with great accuracy. Thus, at present, the reported clinical data regarding the NobelActive™ internal connection dental implant is limited and further clinical and radiographic assessment over a long observation period is required.

3. HYPOTHESIS

The Null Hypothesis states that there is no difference between a “highly retentive” implant design (NobelActive™) and a conventional implant design (Brånemark™) in terms of clinical performance in the short term (such as early loading) and in the longer term (such as implant survival).

4. AIMS AND OBJECTIVES

4.1 Aims

The aim of this study is to conduct a pilot randomised controlled trial to evaluate the clinical and radiographic efficacy of the NobelActive™ dental implant system, using a split mouth design.

4.2 Objectives

1. To investigate the clinical and radiographic changes around NobelActive™ dental implants and compare the changes with a control implant system using the following parameters:
 - a. Insertion torque
 - b. Resonance frequency analysis
 - c. Digital subtraction radiography
 - d. Cone beam computed tomography
2. To compare changes around test and control implants at 1-month, 2-months, 3-months, 6-months, 1 –year using the above parameters

5. MATERIALS AND METHODS

5.1 Ethics approval

Ethics approval was obtained from the SWAHS Human Research Ethics Committee (Westmead Campus): Reference HREC 2008/11/4.13/ (2825). Site specific approval was obtained for the study to be undertaken at Westmead Hospital: Reference 08/WMEAD/185.

5.2 Study population

Patients referred to the Periodontics Department at the Westmead Centre for Oral Health for implant treatment with bilateral edentulous spaces were approached to participate in this study. Patient recruitment was accomplished between November 2008 and January 2010. The criteria for inclusion were:

- (1) a need for rehabilitation with dental implants with at least one pair of contralateral missing teeth;
- (2) comparable missing teeth, such that molars were compared with molars, premolars with premolars, canines with canines, and incisors with incisors;
- (3) comparable occlusion opposing the edentulous areas, such that both sites were opposed with natural teeth or both sites were opposed with a removable prosthesis;
- (4) healed sites with a minimum three months post extraction healing period
- (5) completion of skeletal growth, with nil growth considerations affecting implant therapy; and

(6) in apparent good health with no contraindications for surgery.

The criteria for exclusion included:

- (1) need for prior augmentation of the implant site;
- (2) presence of persistent and unresolved infection in the implant site;
- (3) smoker, >10 cigarettes per day;
- (4) uncontrolled or poorly controlled diabetes, with BSL >8.4 mMol/ml;
- (5) currently receiving IV or oral bisphosphonate therapy;
- (6) active periodontal disease;
- (7) pregnancy;
- (8) history of chemotherapy or radiotherapy to the head and neck region;
- (9) drug or alcohol dependency;
- (10) severe bruxism or clenching habits; and
- (11) any significant medical history that could affect implant surgery.

All patients were provided with written and verbal information about the study and those who fulfilled the criteria were invited to participate in the study (see Appendix 3). All patients gave informed consent and had the right to withdraw from the study at any time, without consequences to their future care.

All subjects invited to participate in the study were examined by a prosthodontist and periodontics registrar to assess suitability. All required periodontal and restorative treatments, including oral hygiene instruction, non-surgical therapy, and endodontics, were performed prior to reconstructive therapy (implant placement) and the periodontal condition of all subjects was monitored until a full-mouth bleeding on

probing score was <20%. Subjects were considered to require no further treatment except for reconstructive therapy and maintenance.

5.3 Test and control implants

The test implant, the NobelActive™ internal connection implant (Nobel Biocare AG), is available in 3 different diameters (3.5 mm, 4.3 mm, 5.0 mm) and 6 different lengths (8.5mm, 10.0 mm, 11.5 mm, 13.0 mm, 15.0 mm, 18.0mm). There are two restorative platform sizes: narrow and regular. The control implant, Brånemark™ Mark III implant (Nobel Biocare AG), is an external hex implant with comparable diameters (3.3mm, 3.75mm, 4.0mm, 5.0mm) and the same lengths. There are three restorative platform sizes: narrow, regular, and wide. Both implants have the TiUnite™ surface. There are several differences between the two implants, primarily in their design. The test implant is tapered, has an internal connection and built-in platform switching, whereas the control implant is parallel-walled and has an external hex connection. The NobelActive™ implant system also includes the NobelActive™ external connection implant, which has some similarities to the control implant. This implant is a one piece structure with built-in platform switching and has an implant pillar joined to the screw portion of the implant. Abutments are friction-secured to the implant pillar by tapping with a mallet, producing an external connection. This configuration is less widely utilised in practice and is quite different to the Brånemark™ Mark III implant, hence it was not assessed as part of this study.

5.4 Study design

The study was a prospective, randomised, split-mouth pilot study involving subjects with bilateral comparable edentulous spaces in either the maxilla or mandible. Subjects received a NobelActive™ dental implant in one site and a Brånemark™ dental implant in the contralateral site as assigned by a randomisation table.

5.5 Surgical protocol

For each subject, both implants were inserted in the same session according to a one-stage protocol with connection of a healing abutment following implant placement. No platform switching was performed on the control implants. The surgical procedures were carried out by four experienced operators proficient in implant placement under local anaesthesia (2% lignocaine with adrenaline 1:100,000).

The order and side of placement of the test and control implants were randomised according to a four-way computer generated randomisation table. The surgeon was advised at the commencement of surgery by the examiner which side the test implant was to be placed and whether it was to be placed first or second. The clinical procedure was performed according to the manufacturer's guidelines for the respective implant systems.

The time taken for the surgical procedure was recorded, commencing at the start of the osteotomy preparation and ending at the placement of the implant (see Appendix 4). Primary stability of the implant was assessed using peak insertion torque values

and resonance frequency analysis (RFA) using the Osstell™ ISQ instrument (Osstell AB, Göteborg, Sweden). For each implant placed, the appropriate Smartpeg was manually inserted into the implant and the Osstell™ instrument used to obtain a reading from the labial/buccal and mesial directions. The instrument provided two readings of implant stability quotient (ISQ), of which a mean value was used to represent the RFA value or stability of the implant.

All subjects were issued with written instructions describing post-operative care (see Appendix 5). Subjects were instructed to maintain oral hygiene with minimal trauma and to rinse twice daily for one week with 0.2% chlorhexidine gluconate mouthrinse. All patients were recalled seven days after surgery for suture removal.

5.6 Surgical assessment

Immediately following the surgery, the surgeon completed an assessment form with visual analogue scales (VAS) to evaluate their subjective assessment of the test and control implant systems (see Appendix 6). The questions on the assessment sheet related to the overall experience of placing the implant, the ease of placement, the ease of placing at the correct depth, location, and angulation. All surgeons were briefed at a meeting at the commencement of the study to ensure the questions were understood and the VAS ranged from ‘very difficult/problematic’ to ‘very positive/simple’ when attempting to achieve each particular outcome. The result was based upon the surgeon’s subjective assessment of each outcome.

5.7 Prosthetic reconstruction

The test implants were restored with provisional restorations at one month post implant placement using temporary abutment cylinders, with the abutment screw being hand-tightened. All implants (test and control) were restored with long-term provisional restorations or final porcelain fused to metal crowns at three months post implant placement. All implants were restored using GoldAdapt (Nobel Biocare AG) abutments with screw-retained crowns or custom zirconium abutments with cement-retained crowns. The abutment screws were torqued to 35Ncm, as recommended by the manufacturer. Occlusal contacts were adjusted on the crowns to minimise contacts during excursive movements of the jaw.

Though the test implants had built-in platform switching, no platform switching was used with the control implants as previous radiographic data assessing the Branemark™ system utilised abutments with matching diameters (Bahat 2000, Turkyilmaz et al. 2007). Similarly, Kielbassa and co-workers (2009) did not use platform switching with their control implants, the NobelReplace Tapered Groovy implant.

5.8 Clinical assessment

A single examiner collected all data post surgery. Each subject was recalled and clinically assessed at one month, two months, three months, six months and one year post surgery. Each review appointment involved clinical examination including full mouth bleeding on probing assessment, periodontal probing, resonance frequency

analysis using the Osstell™ ISQ instrument (to monitor the implant stability quotient), and standardised periapical radiographs (see below).

Probing depth was evaluated at six sites around each implant/prosthesis: the buccal/labial, lingual/palatal, mesiobuccal/labial, distobuccal/labial, mesiopalatal/lingual and distopalatal/lingual aspect of each implant. A manual periodontal probe with millimetre gradations was used. Bleeding on probing was also evaluated around the implant or implant-supported restoration.

All adverse events, including biological and technical complications, were recorded. Appropriate treatment was provided when indicated. Due to the nature of the treatment and the clinical and radiographic appearance of the implants, the examiner was not blinded to the implant assignment during follow-up.

5.9 Radiographic assessment

Periapical radiographs were taken using a standardised paralleling set-up using a size 2 E-speed film. The setup incorporated a custom made metal ring frame attached to the radiographic collimator tube and connected with an X-ray film positioning system. The X-ray film holder was positioned intraorally through the addition of a putty template, which was made at the cessation of implant surgery (see Appendix 7). Adjustments to the putty template were made during the review period of the study, to allow for the standardised positioning of the X-ray film following restoration of the implant with a provisional or final crown. The periapical radiographs were taken

immediately after healing abutment placement and at one month, two months, three months, six months, and one year after implant placement.

As the radiographic setup allowed the angulations between the X-ray source, the object, and the film to be reproducible, digital subtraction radiography was performed on all radiographs. The standardised periapical radiographs were scanned at 600dpi with a flatbed scanner (Epson Perfection 4990 Photo Scanner, Epson, Australia) and stored in the hard disk of a personal computer. The images were imported into software based on the Linux system as described by Woo et al. (2003). Firstly, the software aligns a pair of images by selecting the same sets of reference points on both images. The software compares the coordinates of the reference points and moves the comparison image vertically, horizontally, and rotationally until the pair of images is matched. Manual pixel-by-pixel movement of the comparison image could also be performed as necessary (see Appendix 8). Grey-level normalisation was performed using the software and then the images were digitally subtracted. Determination of noise levels was performed using duplicate radiographs taken throughout the course of the study. A region of interest was chosen around the mesial and distal of all implants and the percentage of pixels deviating from a preset threshold value was evaluated. This allowed quantification of density changes surrounding an implant (mesiodistally) through the healing period. Interproximal peri-implant bone levels were also quantified using the measurement tool in the digital subtraction radiography software, with values proportioned according to the magnification factor of the radiograph. The known implant length was used as a reference.

To assess bone level changes that occur around an implant following placement (post-insertion healing), a cone beam computed tomography (CBCT) scan was taken prior to surgery for treatment planning, immediately after implant placement, at one month, two months, and three months after implant placement. These scans were in addition to the periapical radiographs taken at specified intervals and involved the use of the i-CAT cone beam imaging system (Imaging Sciences, Pennsylvania, USA). Conventional medical CT scanning (either spiral or serial imaging) was not used in this study. The scan images were evaluated using the i-CAT Vision software (Imaging Sciences International) to quantify marginal bone height changes on the buccal/labial and palatal/lingual sides of the implant. Magnification was taken into account through use of the known implant length as a standard.

To assess examiner reproducibility, 10% of all radiographs were randomly chosen and remeasured. The intraexaminer repeatability between the 1st and 2nd radiographic measurements was 0.94 (Pearson correlation, $p < 0.01$), which was considered to be acceptable (Thompson & Walter 1988).

5.10 Data analysis

The choice of a split-mouth technique was used to account for many of the “within-patient” variables that could have potentially confounded the results of this study. In order to test whether this pairing was effective, the Pearson correlation coefficient (r) and p -value were calculated. A priori, the sample size was calculated assuming a clinically meaningful difference in the mean survival time to be three months longer in the treatment group with 90% power, and two-sided significance test at 5%, (PS

Version 2.1.31). The resultant sample size (n=30) included an allowance of (expected) 10% loss to follow-up.

Descriptive statistics for demographic variables were created. The primary efficacy measure, mean survival time (days), was analysed using two methods: 1) Days were assumed to be a continuous variable using the paired t-test; and 2) Cox regression model (survival analysis). In addition, the proportion of implants that failed in each group was analysed.

Other secondary outcomes were analysed using chi-square tests (Fisher's exact test in order to account for the modest sample size) for proportions, paired t-tests for continuous outcomes, and ANOVA models testing for significant covariates as appropriate. An important source of potential measurement error, radiographic measurements, was subjected to test-retest analysis using the Pearson correlation coefficient. A coefficient of >0.75 was considered substantial (Thompson & Walter 1988). All analyses were undertaken using a statistical database (SAS v.8.2, SAS Institute, Cary, NC, and SPSS v15). The alpha for statistical significance was set at 0.05.

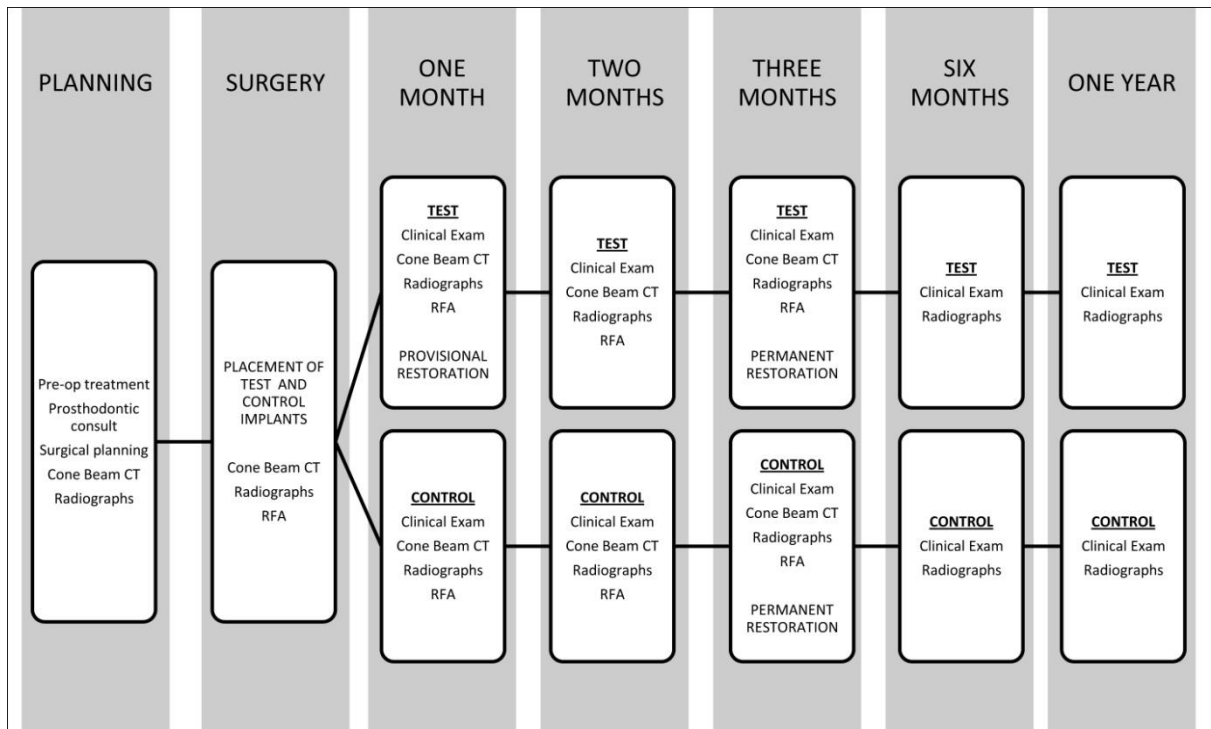


Figure 5.1 – Flow diagram of participants and implant therapy

6. RESULTS

6.1 Study population

Patients referred to the Periodontics Department at the Westmead Centre for Oral Health (Sydney, Australia) during the period from January 2009 to January 2010 were assessed for eligibility to participate in this study. 42 patients with bilateral edentulous spaces were identified and approached to participate in the study. 32 patients fulfilled the inclusion and exclusion criteria and gave informed consent for participation in the study. The reasons for the 10 excluded patients included: lack of interest in implant therapy (4), inadequate bone volume for implants (3), ineligible for treatment (1), incomplete prosthodontic treatment (1), and ongoing orthodontic treatment (1).

32 patients participated in this study, consisting of 21 females and 11 males. The mean age of subjects was 50.47 ± 13.27 years, with an age range of 22-70 years. One male was a smoker and another male was a controlled diabetic. Six patients, four males and two females, had a history of treated periodontitis (See Table 6.1).

Table 6.1: Patient demographics

Females: Males	21:11
Mean age	50.47 years
Age standard deviation	13.27 years
Age range	22-70 years
	No. of patients
Smokers	1
Diabetics	1
History of treated periodontitis	6

All subjects completed the study for the period of data collection. However, due to the loss of four test implants and one control implant, five subjects were exited from the study (see Figure 6.1). Due to the variation in recruitment and time constraints, the one-year data was available for 4 of the 27 subjects, the six-month data was available for 22 of the 27 subjects, and the three-month data was available for all 27 remaining subjects. Therefore, all the one-year data analysed and presented in this study is based upon 4 subjects; all the six-month data analysed and presented in this study is based upon 22 subjects; and the three-month data is based upon all 27 subjects.

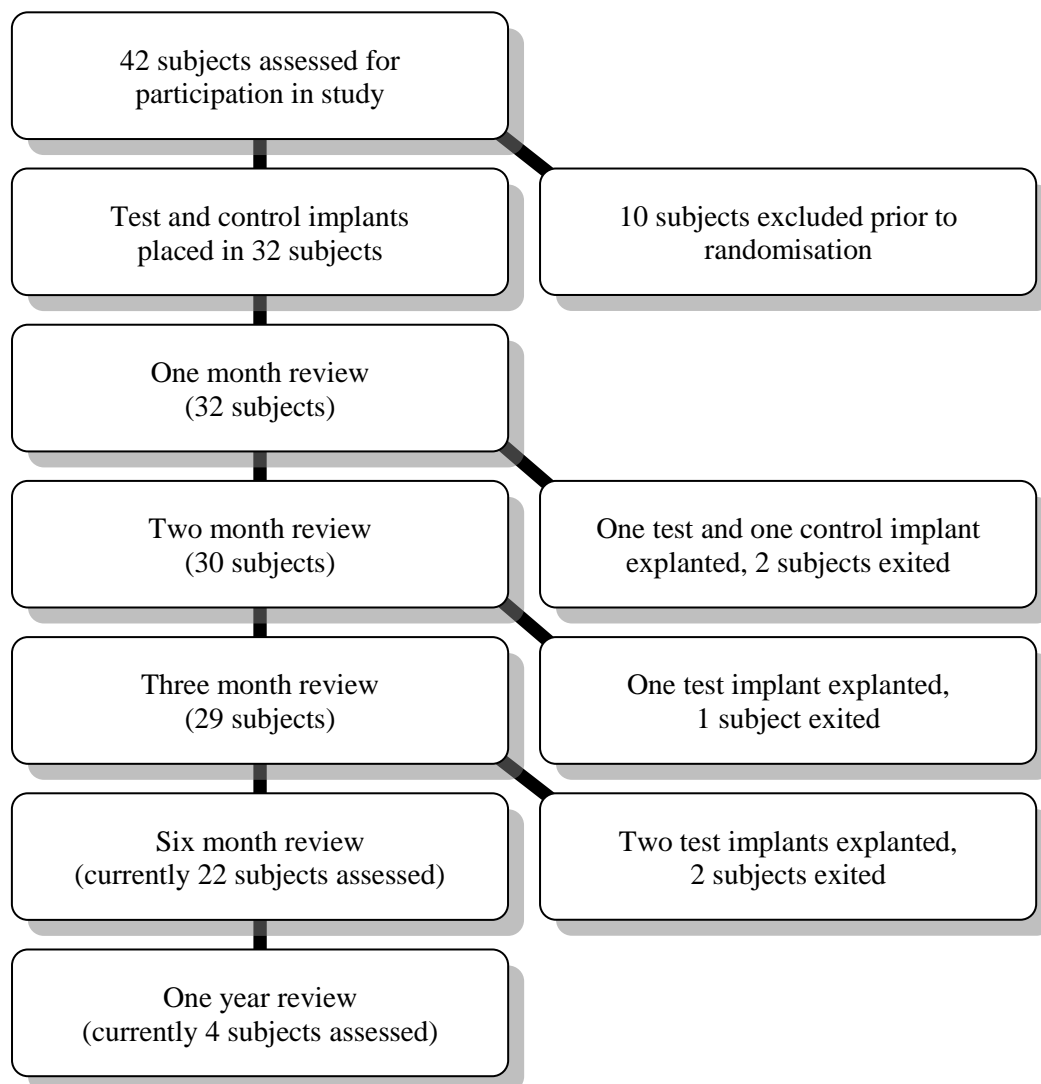


Figure 6.1: Flowchart of participant progression through the trial

6.2 Location of implants

A total of 64 implants, consisting of 32 test and 32 control implants were placed between May 2009 and January 2010. 22 implants were placed in the maxillae and 42 implants were placed in the mandible. The majority of implants were placed in the mandibular molar region (34), followed by the maxillary premolar region (12), mandibular premolar region (8), maxillary anterior region (6), and the maxillary molar region (4). No implants were placed in the mandibular anterior region. The data is shown in Table 6.2.

Table 6.2: Distribution of implant positions

	MAXILLA	MANDIBLE
Anterior	6	0
Premolar	12	8
Molar	4	34

6.3 Description of implants

Due to the various implant sites, a variety of diameters and lengths of implants were used. Generally, matching implants were placed bilaterally such that in each subject, the test and control implants were the same length and the diameters were comparable. In three subjects, however (subjects 18, 21, and 32), the length of implants varied bilaterally. In subject 18, the control implant was longer than the test implant (13.0mm vs. 10.0mm). In subjects 21 and 32, the test implants were longer

than the control implants (10.0mm vs. 8.5mm and 11.5mm vs. 10.0mm respectively).

The data is shown in Table 6.3.

Table 6.3: Distribution of implant diameters and lengths

DIAMETER (mm)	LENGTH (mm)			
	8.5	10.0	11.5	13.0
3.0 or 3.3	0	2	2	2
4.0 or 4.3	0	11	8	0
5.0	13	21	3	2

6.4 Survival of implants

Of the 64 implants placed, five implants had been explanted as they had become clinically mobile. Four of the explanted implants were test implants and one was a control implant. The test implants were lost at different times in the follow-up period, with one implant lost after the one month review, one implant lost after the two month review, and two implants lost after the three month review. The control implant was lost after the one month review. The cumulative overall survival rate of all implants placed was 92.1%, with the cumulative survival rate of test implants being 87.5% and the cumulative survival rate of control implants being 96.9%. This was not statistically significant ($p= 0.64$). Three of the implants (two test and one control) were removed prior to connection of the prosthetic reconstruction (provisional or permanent crown) and hence were regarded as early losses, indicative of a lack of tissue integration (Berglundh et al. 2002). The other two implants were removed

following the connection of the prosthetic reconstruction and hence were regarded as late failures.

The length of survival time (in days) was also compared between the test and control implants. At the completion of the data collection period, the test implants had a mean survival time of 276.6 days, whereas the control implants had a mean survival time 295.7 days. Statistical analysis comparing survival data between the two groups demonstrated no difference over the observation period ($p=0.22$; simple paired t-test) and this was confirmed using COX regression analysis ($p=0.21$).

6.5 Complications

During the healing period following implant placement, the implants were periodically reviewed to identify complications associated with the implant and prosthesis. Patient reported symptoms and clinical parameters were assessed monthly and patients were asked to report any discomfort or concerns. Of the five implants that were removed, four of the patients reported pain and discomfort associated with the peri-implant tissues. The fifth patient, who lost her implant following the insertion of the permanent crown, did not report any pain or discomfort, only that her crown was mobile.

Several surgical complications occurred during the placement of the test and control implants. One surgeon reported difficulty with removing the implant driver from the implant following its insertion. This occurred with two subjects, though the driver was successfully retrieved without further incident. Fracture of the buccal cortical bone

occurred during the placement of four test implants. This occurred during the insertion of the implant, not during the osteotomy preparation. In two cases, the fracture resulted in visible disruption and mobility of the cortical bone, however, the bone remained around the implant. In the other two cases, the buccal cortical bone was lost, resulting in exposure of the buccal threads (dehiscence). Of the four cases with buccal bone fracture, three test implants were eventually lost prior to loading. Additionally, difficulty with insertion of the test implant into dense bone was reported in four cases, especially with placement of implants into posterior mandible sites.

As peri-implant pocket depths were measured at six points around the implant at each review, changes in depths and presence of bleeding on probing (BOP) allowed early management of peri-implant mucositis and peri-implantitis. A single case of a deepened pocket depth occurred, with a single site around a control implant measuring 8mm at the one month review. This was not associated with BOP or suppuration and was treated with debridement and chlorhexidine gel application. Following the treatment, the deep pocket depth site had healed to a pocket depth of <3mm.

Suppuration on probing was present around three test implants and three control implants. These were similarly treated with debridement and chlorhexidine gel application. Following treatment, all lesions resolved without further incidence.

6.6 Duration of surgical procedure

The total time for the osteotomy preparation for both the test and control implant systems was recorded. This was taken as the time from the commencement of drilling (following the raising of a mucoperiosteal flap) to the completed insertion of the implant. This is the time period that is required for an implant to be placed and could differ between different implant systems, depending upon the placement protocol and implant design. The average time for the placement of the test implant was 16 minutes and 52 seconds and the average time for the placement of the control implant was 14 minutes and 51 seconds. The difference was not statistically significant ($p=0.41$).

6.7 Visual analogue scales

The subjective assessment of the implant systems following surgery by the operator was performed through the use of visual analogue scales. The assessment of the overall experience of placing the implant was scored as a mean of 7.7 for the test implant and 8.64 for the control implant, with 0 being very problematic and 10 being very positive. The ease of placing the implant was scored as a mean of 7.54 for the test implant and 8.75 for the control implant, with 0 being very difficult and 10 being very simple. The ease of placing the implant to the proposed depth was scored as a mean of 7.7 for the test implant and 8.88 for the control implant, with 0 being very difficult and 10 being very simple. The ease of placing the implant at the proposed location was scored as a mean of 8.0 for the test implant and 8.75 for the control implant, with 0 being very difficult and 10 being very simple. The ease of placing the implant at the proposed angulation was scored as a mean of 7.78 for the test implant

and 8.52 for the control implant, with 0 being very difficult and 10 being very simple. The ease of using the implant kit was scored as a mean of 8.33 for the test implant and 8.72 for the control implant, with 0 being very difficult and 10 being very simple. Overall, the mean score for the subjective assessment of the test implant placement was 7.84 and 8.71 for the control implant placement, with a higher number being more favourable (see Figure 6.2). Of these subjective assessments, the control implant scored significantly higher for the overall experience, ease of placement, and ease of placement to the proposed depth and location ($p < 0.05$).

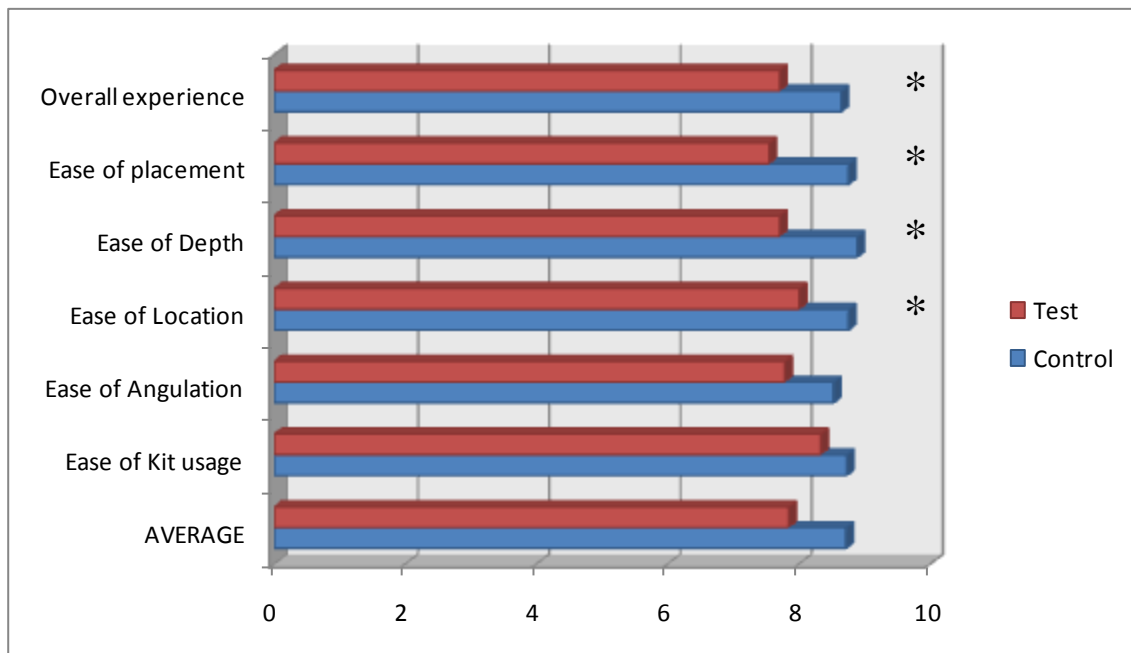


Figure 6.2: Summary of operator post-surgery subjective evaluation of implant placement (* = $p < 0.05$, paired t-test)

The additional comments that were provided described local factors affecting implant placement or complications that occurred during placement. Generally, the additional comments were positive, such as in two cases where the test implant achieved good

primary stability in a site with soft bone. Conversely, several complications were reported. In two cases, the operator had trouble with removing the implant driver from the test implant following placement. This was attributed to the high insertion torque during placement, which seemed to lock the driver into the internal connection. In four cases, the operators reported difficulty with test implant placement due to the presence of dense bone (Type I), which affected placement to depth or to the correct angulation. In another four cases, the operators reported that the implant caused the fracture of the buccal cortical bone in the implant site. This occurred during the insertion of the implant, after the osteotomy preparation.

6.8 Insertion torques

The mean insertion torque for the test implant was 47.1Ncm (range= 20-70Ncm) and the mean insertion torque for the control implant was 39.8Ncm (range= 20-50Ncm). This difference was significant ($p=0.02$). However, four test implants and one control implant required the use of the torque wrench to complete the insertion, which did not allow for accurate quantification of the insertion torque. For these particular implants, the final machine driven value was used as the insertion torque but would be lower than the true value. Hence, the mean insertion torque values should be greater for the test and control implants.

6.9 Resonance frequency analysis

For each test and control implant, resonance frequency analysis was used to assess implant stability immediately after placement, after one month, two months and three

months. No later assessment was performed as the presence of a permanent reconstruction prevented the connection of an Osstell™ Smartpeg. For both implant systems, excluding the values of the exited subjects, the implant stability quotient (ISQ) values increased steadily as osseointegration progressed. The mean ISQ values at placement were 69.90 ± 10.32 for the test implants and 72.28 ± 10.16 for the control implants. After three months of healing, the ISQ for the test implants increased by a mean value of 6.09 ($p < 0.05$), while the control implants increased by a mean value of 7.17 ($p < 0.001$). The mean ISQ values for control implants were greater than the test implants at all time points, though the difference was only significant at the two-month review ($p = 0.027$) (see Figure 6.3).

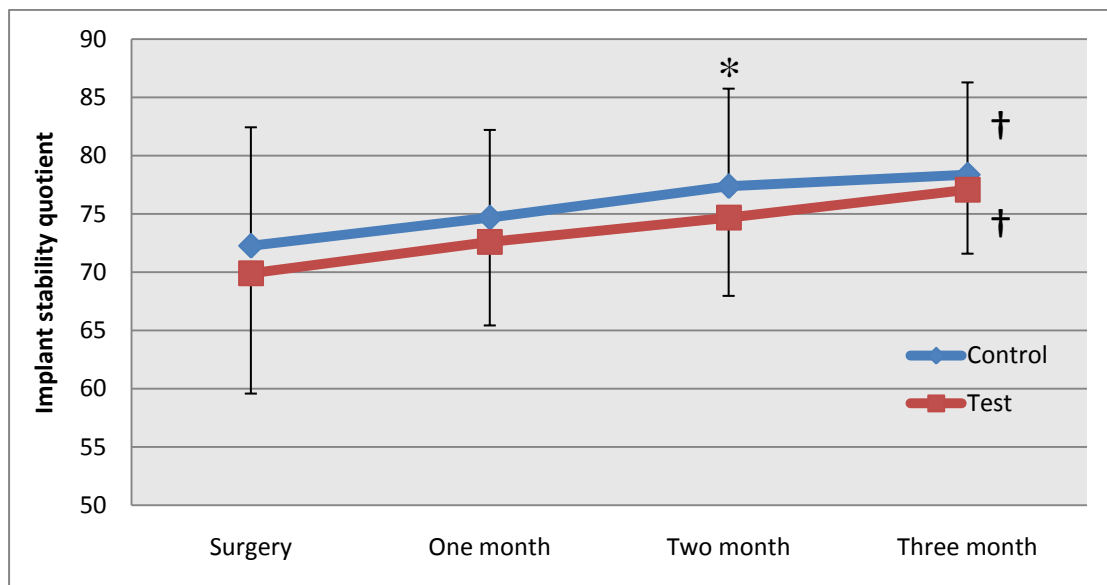


Figure 6.3: Resonance frequency analysis values of the test and control implants

(* = $p < 0.05$, test vs. control, † = $p < 0.05$, surgery vs. three month, paired t-test).

6.10 Marginal bone levels

The marginal bone levels around the mesial and distal of each surviving implant were assessed using standardised, digitised periapical radiographs. A key was devised to represent the different bone levels around the test and control implants (see Tables 6.4 and 6.5). For each implant, the most apical bone level of the mesial and distal surface was chosen to represent the implant (see Figure 6.4). The bone levels around the test implants tended to be maintained around the coronal portion of the implant, whereas the bone levels around the control implants tended to remodel down to around the tip of the first thread.

Table 6.4: Key for assessing bone levels relative to the test implant structure

Score	Level of bone relative to test implant
0	Shoulder level (no bone loss)
1	Coronal portion
2	Up to tip of 1 st thread
3	Up to tip of 2 nd thread
4	Beyond tip of 2 nd thread

Table 6.5: Key for assessing bone levels relative to the control implant structure

Score	Level of bone relative to control implant
0	Shoulder level (no bone loss)
1	Polished region
2	Up to tip of 1 st thread
3	Up to tip of 2 nd thread
4	Beyond tip of 2 nd thread

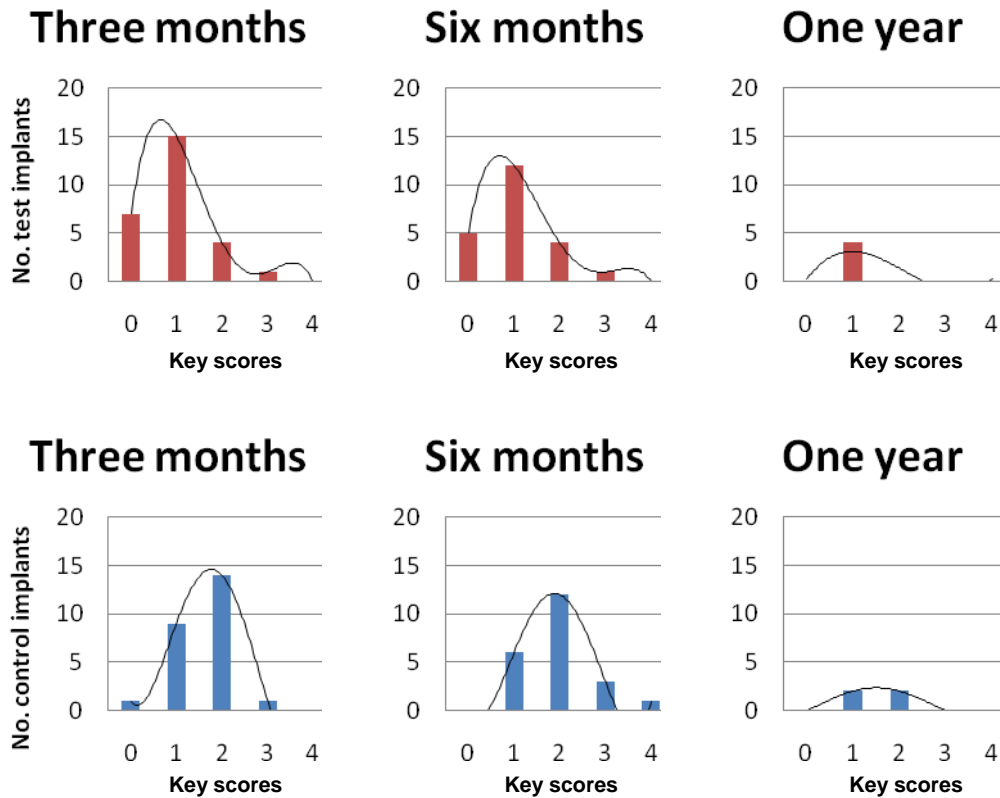


Figure 6.4: Numbers of test and control implants with different degrees of bone change relative to implant structure

Additionally, the standardised, digitised periapical radiographs were further assessed to determine mean bone changes around the mesial and distal of the test and control implants. The digitised image was measured using the measurement tool on the digital subtraction radiography program. This measurement was then adjusted to account for magnification and angulation errors, using the known implant length as the reference length. The baseline reference point was taken as the bone level at implant placement and hence any changes were recorded as the distance from the initial bone level (see Table 6.6). At every time point, there was no significant difference between the test and control implants with regard to bone level changes. Additionally, there was no statistically significant difference between bone levels at 3, 6 and 12 months within

both the test and control implant groups ($p>0.05$), such that the bone levels within each group were maintained over the duration of data collection.

Table 6.6: Mean bone changes around implants (paired t-test)

Time period	Test (mm)	Control (mm)	P-value
Surgery to one month	0.94±0.77 CI= 0.18 (Range 0 - 3.13)	0.81±0.67 CI= 0.21 (Range 0 - 3.32)	0.20
Surgery to two month	1.23±0.74 CI= 0.19 (Range 0 - 3.13)	1.20±0.68 CI= 0.21 (Range 0 - 3.04)	0.70
Surgery to three month	1.19±0.75 CI= 0.18 (Range 0 - 2.78)	1.34±0.65 CI= 0.21 (Range 0 - 3.08)	0.40
Surgery to six month	1.20±0.83 CI= 0.21 (Range 0 - 3.16)	1.50±0.71 CI= 0.25 (Range 0 - 3.08)	0.38
Surgery to one year	1.02±0.40 CI= 0.41 (Range 0.46 – 1.52)	1.37±0.55 CI= 0.30 (Range 0 – 1.85)	0.24

(CI= 95% confidence interval)

In order to relate the bone level to the implant geometry, the interproximal bone level at 3, 6, and 12 months was also assessed in relation to the position of the first implant thread. The mean bone level around the test implants was greater than 1.5mm coronal to the first thread, whereas the mean bone level around the control implants were within 0.5mm coronal to the first thread.

Table 6.7: Mean bone level distance from the tip of the first implant thread

Review	Test (mm)	Control (mm)
Three month	1.73±0.98 CI=0.27 (Range 0 – 4.10)	0.32±0.62 CI=0.17 (Range -0.80 – 1.81)
Six month	1.74±0.98 CI=0.29 (Range 0.15 - 3.23)	0.14±0.52 CI=0.15 (Range -0.83 – 1.23)
One year	1.61±0.42 CI=0.31 (Range 1.03 – 2.38)	0.42±0.96 CI=0.71 (Range -0.80 – 1.81)

(Negative values indicate that the bone level is apical to the first implant thread,
CI=95% confidence interval)

6.11 Computer-assisted densitometric image analysis

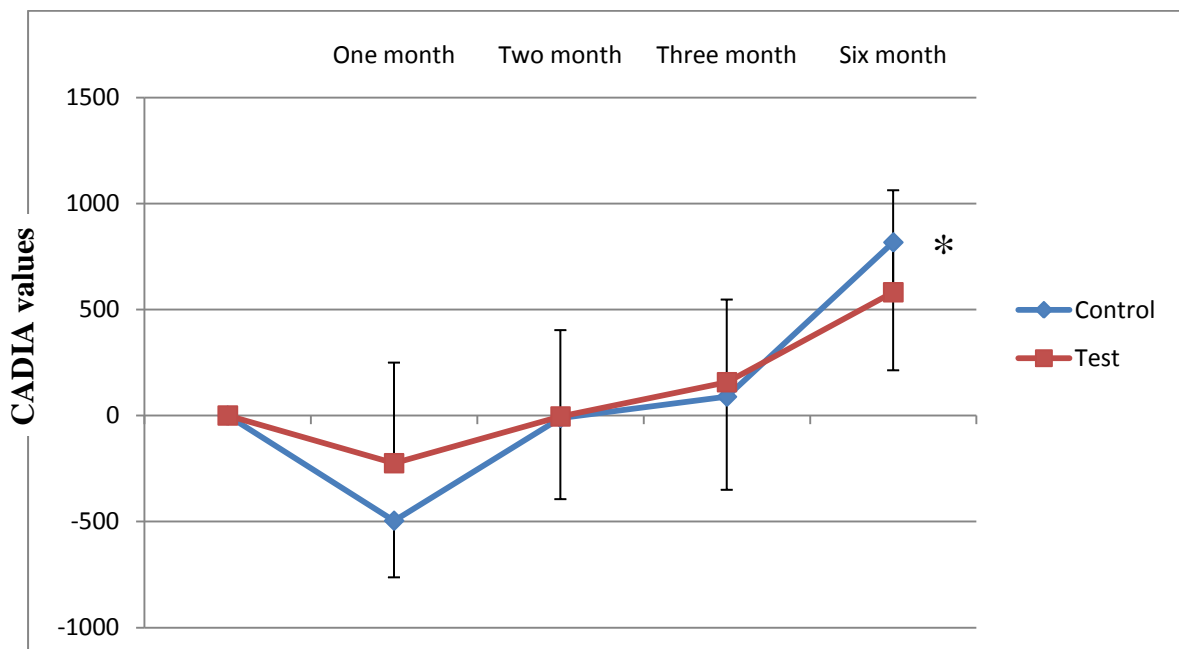
A total of 13 repeats of periapical radiographs were taken in different patients in order to determine the threshold to be used for the digital subtraction radiography system (Woo et al. 2003). All these paired radiographs were taken at the same appointment and processed together. Hence, there should be no difference in bone levels between each of the paired radiographs. Table 6.8 shows the noise levels when the threshold is set between “10-19”. 14 was determined to be the optimal threshold as the noise level was <5% for the calculation of CADIA values. This threshold was applied in all subsequent digital subtraction analyses.

Table 6.8: Noise level in different threshold values

Threshold	10	11	12	13	14	15	16	17	18	19
Noise level (%)	12.54	9.86	7.62	6.01	4.71	3.67	2.86	2.21	1.72	1.39

The quantification of bone density changes adjacent to implants through the use of digital subtraction radiography showed that bone density reduced in the first month following implant placement but steadily increased as osseointegration progressed (see Figure 6.5). The greatest increase occurred following the placement of the permanent restoration. Relative to the control group, the test group showed a greater reduction in mean CADIA values in the first month but greater overall increases occurred over the following five months. However, no statistically significant differences in CADIA values were found between the test and control groups at any time point. Within the control group, there was a significant increase in the mean CADIA value between the three- and six-month reviews ($p=0.03$). This was not found with the test implants or in comparisons within other time periods.

Figure 6.5: Mean CADIA values at different time points (* = $p<0.05$, control group, three months vs. six months, paired t-test. 95% confidence interval bars are shown.)



6.12 i-CAT cone beam computed tomography

Using the viewing software utilised in i-CAT cone beam scans, known as i-CAT Vision (Imaging Sciences International), the distance between the implant shoulder and the bone levels was measured. Measurements were adjusted to account for magnification and angulation errors, using the known implant length as the reference length. The results from subjects in which implants had failed to survive were excluded. Examining the buccal and palatal/lingual bone levels, there were minimal changes in the three months following implant placement, even though the provisional restoration was placed on the test implant after one month of healing. The mean bone level changes can be seen in Table 6.9. The test group mean palatal/lingual bone level at the three-month review was significantly different from the baseline level, as well as being significantly different to the three-month control implant palatal/lingual mean bone level. No significant difference was found between the test and control groups at any other time point, nor at different time points within the control group. Though the mean values of bone level changes are comparable between the test and control implants, there was a greater range in values associated with the test implants. For the test implants, there were nine subjects with bone loss $>2.5\text{mm}$ on the buccal (at any time point) compared with six subjects in the control group.

Table 6.9: Cone beam computed tomography mean bone levels relative to the implant shoulder (* = p<0.05, test vs. control, † = p<0.05, test group, three month vs. baseline, paired t-test)

	TEST IMPLANTS		CONTROL IMPLANTS	
	Buccal (mm)	Pal/Ling (mm)	Buccal (mm)	Pal/Ling (mm)
Surgery	1.16±1.93 CI= 0.73 (R= -1.60 – 6.77)	0.32 [†] ±0.75 CI=0.28 (R= -1.00 – 2.79)	0.56±1.39 CI=0.52 (R= -0.67 - 5.89)	0.13±0.72 CI=0.27 (R= -2.25 - 1.60)
One month	1.11±1.60 CI=0.62 (R= 0 – 6.36)	0.35±0.92 CI=0.35 (R= -1.11 – 2.85)	0.55±1.37 CI=0.53 (R= -1.90 - 4.78)	0.20±0.69 CI=0.27 (R= -2.14 - 1.55)
Two month	1.09±1.56 CI=0.60 (R= 0 – 6.22)	0.65±0.83 CI=0.32 (R= -0.47 – 2.42)	0.72±1.10 CI=0.42 (R= 0 - 3.90)	0.42±1.10 CI=0.42 (R= 0 - 3.90)
Three month	0.99±1.28 CI=0.48 (R= 0 – 3.48)	0.80 ^{*†} ±0.98 CI=0.37 (R= 0 – 3.33)	0.85±0.95 CI=0.36 (R= 0 - 3.37)	0.39 [*] ±0.56 CI=0.21 (R= 0 - 1.88)

(Negative values indicate that the bone level is coronal to the implant shoulder,

CI=95% confidence interval, R=range)

7. DISCUSSION

7.1 Study population

The study population was recruited from patients referred to the Periodontics Department, including hospital and private patients, and may be considered to be representative of the general population. Generally, the study population was healthy, with only a single subject reporting to have controlled diabetes. Only one subject was a reported smoker (3.1% of the study population), whereas the reported prevalence of smoking in Australian people over the age of 15 years is 20% (Australian Bureau of Statistics 2009). This lower proportion can be attributed to the exclusion criteria where heavy smokers were excluded as smoking is a risk factor for early implant failure (van Steenberghe et al. 2002, Alsaadi et al. 2008). Potential subjects with other conditions that could be possible risk factors for implant failure were also excluded from the study (Buser et al. 2000, Bornstein et al. 2009). Additionally, six of the subjects had a history of treated periodontitis (18.8%), which can be considered to be representative of the Australian population. Moderate or severe periodontitis affects 22.9% of Australian adults and is significantly elevated in older adults, males, and those of lower socio-economic status (Slade et al. 2007). All subjects were considered to have 'treated' periodontitis and stable periodontal health and maintained a full mouth bleeding score of <20% prior to and during the study period. Additionally, clinical attachment levels and periodontal probing depths were monitored throughout the study, ensuring that the periodontal condition was maintained as optimally as possible. A history of treated periodontitis and smoking are both considered to be significant risk factors for implant complications (Heitz-Mayfield & Huynh-Ba 2009).

Though bilateral implant sites cannot be identical in every respect, the split-mouth design of this study excludes within-subject variables. This would suggest that the differences in clinical and radiographic results can be attributed to local (site) factors, implant design, and placement protocol. Additionally, as part of the inclusion criteria, the occlusion opposing each implant needed to be similar to the contralateral site and the replaced tooth type was matched bilaterally. Hence, every attempt was made to ensure implants were placed under similar conditions.

The number of subjects enrolled in the study exceeded the proposed sample size as determined through power calculations, which also included a 10% loss to follow-up. At the completion of the data collection period, no subjects had been lost to follow-up and it was considered that complete data collection had occurred.

7.2 Insertion torques

The insertion torques of the test implants were significantly greater than the control implants (47.1Ncm vs. 39.8Ncm) and this can be attributed to differences in the insertion procedure. The recommended osteotomy preparation for a 4.3mm diameter NobelActive™ implant involves a sequence of three to four drills, depending on the type of bone density available. The final drill for Type IV soft bone may be the 2.4/2.8 drill, which is 2.4mm in diameter at the tip and 2.8mm closer to the shank, or the 2.8/3.2 drill. Comparatively, the Type I (dense) bone drilling sequence may terminate with a 3.2/3.6 or 3.8/4.2 drill. The widest part of the implant is closer to the shoulder due to the taper of the implant core but apical to the inversely tapered coronal part. However, for the similar control implant, the 4mm diameter

Branemark™ Mk III implant, the final drill may be 3-3.15mm in diameter. Hence, the discrepancy between the diameter of the osteotomy and the implant diameter is much greater for the NobelActive™ implant (up to 1.5mm) compared to the Brånemark™ implant (up to 1mm). This would require a higher insertion torque in order to place the implant to the full depth, especially in cases with soft bone, resulting in production of compressive forces on the bone wall when the implant is inserted (Sakoh et al. 2006). The production of hoop stresses that result may be beneficial in enhancing the primary stability of an implant (Tabassum et al. 2009).

The higher insertion torque can also be attributed to the design of the NobelActive™ implant, which, instead of cutting upon insertion, is designed to act like a threaded osteotome, condensing the surrounding bone. The process of bone condensation requires greater forces than the process of bone cutting, increasing the bone-to-implant contact during the early healing phases (Summers 1994). Another unique feature of the NobelActive™ implant is that during reverse movement, the threads ‘break’ the trabeculae. Thus, the implant condenses when being placed and cuts when reversed. This allows the implant to release the stress that builds up during placement through a reversing action. As a result of the design, the NobelActive™ system does not utilise a tapping drill as the final preparation does not involve bone cutting. Pre-tapping of the osteotomy site has been shown to lessen primary stability significantly, compared with drilling alone (Buchter et al. 2003).

A high insertion torque has been shown to be favourable in achieving primary stability and hence, the NobelActive™ implant should be able to provide additional primary stability in sites of compromised bone quality. As the peak insertion torque

has been linked to the degree of micromotion (Trisi et al. 2009), the greater the insertion torque, the greater the primary stability. The reduction in micromotion should in turn reduce the amount of early failures as a result of osseointegration being disturbed (Romanos 2004).

The results from this study are consistent with those from another study examining the initial torque stabilities of NobelActive™ implants. Irinakis and Wiebe (2009b), in the placement of 140 NobelActive™ implants, of which 86 were delayed placement, found that the mean torque stability of the implants placed in healed sites was 49.7Ncm. This is similar to the mean insertion torque of 47.1Ncm achieved in this study. However, as the hand wrench was used for insertion of some implants in this study, the true mean insertion torque should be higher than reported. Similarly, measurement of insertion torque in the Irinakis and Wiebe study involved reading values off the NobelActive™ torque wrench, which only has markings at 35Ncm and 70Ncm and hence, may not be entirely reliable in accurate representation of insertion torque. Though the manufacturer's recommended protocol for placement was followed (including the use of the torque wrench), complete machine-driven implant insertion would have allowed more accurate measurement of the insertion torque.

Conversely, too great an insertion torque may result in detrimental effects on the peri-implant bone. Duryk et al. (2010) evaluated an experimental implant design with a high insertion torque, placing a total of 80 experimental and control (Astra) implants into the maxillae and mandibles of mini-pigs. 92.5% of the test implants were installed at greater than 50Ncm of insertion torque and implants were placed at two time points, allowing monthly radiographic assessment and histological assessment

after one and three months of healing. The study found that there was a significantly greater amount of bone level change with a significantly larger histological marginal bone defect around the experimental implants. Additionally, *in vitro* assessment of the experimental implant in a limited number of samples found that the increased insertion torque tended to fracture the cortical bone and elicited an increased strain on the surrounding peri-implant bone. However, results are based upon the mini-pig model where the alveolar crest is thinner, and hence more prone to dehiscences and cortical bone loss/fracture.

The influence of lateral pressure during implant insertion was recently examined in a dog model (Pantani et al. 2010). Twenty-four implants of 3.75mm diameter were placed in six Labrador dogs following three months of post-extraction healing. In a split-mouth design, implant bed preparation on one side involved the use of a 3.0mm diameter final drill in conjunction with pre-insertion tapping. Contralaterally, the final drill diameter used was 2.8mm, with no tapping performed, resulting in application of pressure to the lateral walls of the implant bed. The mean insertion torque for both molars and premolars was significantly greater for the test procedure compared to the control procedure, with values more than doubled. Following four months of healing, the animals were sacrificed and evaluated histologically. No significant differences were found between the two groups of implants in relation to bone-to-implant contact and the bone distance to the rough-smooth border of the implant. It was concluded that following four months of healing, there was no correlation between histological and histomorphometric bony values and insertion torques. The authors stated, however, that the study did not examine early bone healing changes of osseointegration, and that resorptive processes identified at sites under lateral pressure

are replaced by bone apposition at later stages (Abrahamsson et al. 2004), becoming undetectable by four months. In this current study, we noted the importance of performing the reversing action when inserting the NobelActive™ implant following insertion at high torques, as this releases the stresses exerted on the surrounding bone.

7.3 Implant survival and complications

In total, out of 32 test and 32 control implants, four test implants and one control implant were lost during the follow-up period in five different subjects. However, though implant losses were clinically significant, the differences in survival between the test and control groups were not statistically significant, mainly due to the low number of losses in each group. The survival time (in days) and the overall group analysis showed comparable survival times in both groups, though this may be due to the limited data collection period for some of the implants. The reasons for explanation varied though all five failed implants had become clinically mobile, with lateral movement of the implant when tested. This is indicative of lack of osseointegration and fibrous tissue encapsulation of the implant. Two of the test implants were lost following loading, one after the placement of a temporary crown, the other following the insertion of the permanent crown. The other implants were lost prior to loading, and could be considered to be early failures. However, on closer examination of the cases, it can be seen that two of the subjects suffered surgical complications during the surgery, with fracture and loss of the buccal plate of cortical bone. These sites were then subsequently grafted with fully synthetic biphasic calcium phosphate particles, consisting of 60% hydroxyapatite and 40% tricalcium phosphate (Straumann® Bone Ceramic). Unfortunately, these grafts were not successful,

ultimately leading to the failure of the implant. A third test implant could be seen on the CBCT scan to have lost buccal bone during the initial few months of post-implant insertion healing, though this was not apparent at the time of surgery.

Two other implants that were lost, one control and one test, could be attributed to operator factors, rather than a result of the implant design or characteristics. One implant lost osseointegration due to suspected disturbances in the internal thread during healing, whilst the control implant failed due to close proximity with the adjacent tooth. The stripping of the internal threads of the test implant may have resulted in incorrect angulation of the healing abutment and provisional crown during placement, leading to loss of stability and micromotion. Following closer examination of the data, it can be concluded that one single loss in the test group was unexplained, without other confounding factors such as graft failure or operator error.

Two of the implants that failed involved the augmentation of a buccal dehiscence (exposure of buccal threads) with Straumann® Bone Ceramic. Bone augmentation in the treatment of localised peri-implant defects is a successful procedure (Jensen & Terheyden 2009). However, as Straumann® Bone Ceramic is a relatively new material, there are limited human studies involving its use. It has been found to produce amounts of newly formed bone comparable to bovine xenograft in cases of maxillary sinus grafting or ridge preservation (Cordaro et al. 2009, Frenken et al. 2010, Mardas et al. 2010).

The length of implant survival was assessed as one of the primary outcomes of this study. Though it is an unconventional measure of implant treatment outcome,

considering the expected high success rates of modern implant treatment, it was utilised as a measurable outcome due to the ongoing nature of the study. Implants were placed over a period of approximately eight months, with a planned follow-up period of at least five years. As the implants were placed over an extended period, the analysis of implant survival allowed interim comparative assessment of implant survival between the two groups.

7.4 Visual analogue scales

The subjective assessment of the NobelActive™ implant system through the use of visual analogue scales given to the surgeons showed that the surgeons found the control implant system to be significantly simpler than the test implant. The control implant was considered to have greater ease of placement and greater ease to achieve the proposed depth and location. The overall experience of using the control implant was also considered to be more positive than the test implant. However, though the control implant was subjectively rated higher than the test implant, the results can be explained by the previous experiences of the surgeons. The surgeons involved in the study all had previous experience in placing the Brånemark™ control implant and though all had been trained in using the NobelActive™ system, their experience in that system was variable and in some cases limited. Hence, due to the previous experience with the control implant, there was a natural bias and preference away from the test implant. The familiarity with the Brånemark™ system would ensure that the procedure of placing the control implant would be considered to be easier and hence, perform more favourably on any subjective assessment. However, even though

the test implant did not perform as well as the control implant, the VAS scores were very positive and well above the neutral ratings.

7.5 Duration of surgical procedure

There was no significant difference in the time taken to prepare the osteotomy for implant placement. The NobelActive™ system permits more rapid preparation due to the drill configuration and sequence and also more rapid insertion due to the greater thread pitch compared to the control system. However, the familiarity of the surgeons to the control system meant that the control implants could be placed rapidly with less need for scrutiny of the drilling sequence. Additionally, the times may not be indicative of the true clinical duration due to the Hawthorne effect, which may have resulted in expeditious of the surgical procedure, and the need for photography at various stages during the course of the surgery.

7.6 Resonance frequency analysis

Resonance frequency analysis was used to assess implant stability during the initial healing of post-implant placement. In both test and control implants, high implant stability quotients were achieved at placement and these values increased as healing progressed. The three-month ISQ values were significantly greater than the initial ISQ values for both the test ($p < 0.001$) and control implants ($p = 0.015$). Though the ISQ values for the control implants were consistently greater than the test implants at all time points, the values were only statistically different at the two month review. Regardless, due to the variation in implant design and Osstell™ Smartpeg, direct

comparison of stability between different implants may not be accurate (Rabel et al. 2007). The lower ISQ values for the NobelActive™ implant have been attributed not to lower implant stability but to the lower bulk of material within the implant. As the NobelActive™ dental implant is tapered, with greater thread depth and increased pitch, the core of the implant is thinner and hence has less volume. Importantly, however, the implant stability quotient increased consistently over time for both implants, suggesting a progressive increase in the bone-implant interface formation.

7.7 Marginal bone levels

All implants undergo peri-implant marginal bone remodelling following placement, especially within the first three months (Jung et al. 1996). Additionally, following the placement of a prosthetic restoration, further remodelling occurs within three months until stability is achieved around a healthy implant (Shin et al. 2006). In this study, the NobelActive™ implant was provisionally restored after one month of healing, whereas the control implant was restored after three months. This was included in the protocol in order to utilise the benefits afforded by unique design of the NobelActive™ implant. Hence, theoretically, the remodelling around the test implant should occur earlier in the healing period. However, there was no significant difference in mean bone level changes between the two implant systems, even at the six month and one year reviews, though the number of implants reviewed at one year was limited. This data supports the recommendations that the NobelActive™ implant can be successfully restored and loaded one month after placement with no adverse effect and no significant increase in marginal bone remodelling. Additionally, the bone changes around both implant systems were minimal, with a mean bone level loss

of 1.2mm and 1.5mm after six months and 1.02mm and 1.37mm after one year for the test and control implants, respectively. This is similar to the reported bone loss in the first year around machined BrånemarkTM implants (Albrektsson et al. 1986) and the NobelActiveTM implants in the Kielbassa and co-workers study (2009). Following the placement of permanent restorations, no statistically significant change in bone levels occurred for both the test and control implants, indicating that the marginal bone remained stable at the six month and one year reviews.

The bone levels around BrånemarkTM implants have been reported to remodel down to the margin of the polished collar or around the first thread (Jung et al. 1996). In this study, the mean bone levels were within 0.5mm of the first thread with the BrånemarkTM implant, whereas the mean bone levels around the NobelActiveTM implant were approximately 1.7mm above the first thread after three and six months. Though this was significantly different from the control implants, it needs to be taken into account that the NobelActiveTM implant does not have a polished neck and the first thread is at a variable distance from the shoulder. Closer analysis of the data revealed that the bone level tended to remodel to the micro-rings on the NobelActiveTM implant.

The analysis of the standardised periapical radiographs involved scanning and digitisation of the image and using a Linux based digital subtraction radiography program. The protocol of using a putty bite and X-ray mount for the standardisation of the alignment and angulation of the radiographs has been validated by Woo et al. (2003). Using the software, two images could be aligned by shifting the image pixel by pixel. Hence, fine alignment of the images allowed a high degree of accuracy in

determining marginal bone changes. Additionally, the images could be magnified and a digital measurement device within the program could measure distances to less than one-tenth of a millimetre. All measurements, even when magnified, were to scale with the original radiograph, so that the digital measurement would provide a true measurement, though the enlarged image would allow easier identification of the radiographic bone margin. The marginal bone level measurements were also adjusted to account for magnification and angulation, using the known implant length as a reference length. Hence, measurement errors were minimised with subsequent improvements in measurement accuracy and validity.

Similarly, the cone beam computed tomography scans showed that the buccal and palatal/lingual bone levels were comparable between the two implant systems. When the immediate post-surgical bone levels were compared with the three month bone levels, no significant difference was found for the test and control implants, except for the lingual bone level on the test implant. The bone level on the lingual of the NobelActive™ implant changed by a mean of approximately 0.5mm ($p=0.005$) over the initial 3 months, which is not clinically significant and is unlikely to cause an aesthetic or functional problem clinically. Importantly, no significant change in buccal bone level occurred over the first three months for both the test and control implants, which indicates that the buccal marginal bone remained stable following implant placement in a healed site.

The implants in different subjects were restored with GoldAdapt abutments and screw-retained restorations though, in some patients, the implants were restored with custom zirconium abutments and cemented crowns. The decision to use a particular

modality was based on the preference of the restoring prosthodontist ensuring that the greatest aesthetic and functional outcomes were achieved. The preference for restoration did not affect the results of the study as both study and control implants within a subject were similarly restored.

7.8 Computer-assisted densitometric image analysis

The computer-assisted densitometric image analysis (CADIA) values showed that the bone density changes around both systems during osseointegration were comparable, with bone density increasing around the neck and first few implant threads. This is consistent with bony healing and remodelling due to occlusal loading. For the control implant, a significant increase in CADIA occurred between the three-month review and the six-month review ($p=0.03$), indicating that bone density increased following loading of the implant. However, no significant increase occurred for the test implant following loading at one-month. An area of interest would have been the bone surrounding the test implant following insertion and bone condensation. A comparison between pre-placement bone density and immediate post-placement density may have shown a definite increase as a result of the bone condensation, though this has not been found with implant placement with osteotomes assessed by photodensitometry of periapical radiographs (Gulsahi et al. 2007).

The digital subtraction radiography system used for the CADIA has been calibrated and validated in an *in vitro* study, which reported that the system was able to obtain a high and statistically significant correlation between actual bone mass and CADIA value (Woo et al. 2003). The system was shown to have a high sensitivity and specificity (>85% and 95% respectively) and hence is suitable for the detection and

quantification of small alveolar bone changes (Bragger et al. 1988b). Bragger et al. (1988a) used CADIA to assess the radiographs of patients who had crown lengthening procedures or flap procedures with osteoplasty. The authors reported a sensitivity of 82% and specificity of 88% when using the CADIA value. Use of CADIA to analyse peri-implant bone changes has not been widely reported.

Though all attempts are made to perfectly standardise radiographs, a certain amount of noise will be produced during the processing and digitising of images, as well as during the alignment of images. Therefore, as recommended by Steffensen et al. (1989), threshold values should be determined for each analytical system initially, as well as following any equipment or computer program modifications. As the threshold value increases, the noise level reduces but should the threshold value chosen be too great, small bone changes will not be detected by the analysis. In the *in vitro* validation study by Woo et al. (2003), a threshold level of 8 was determined to be the optimal value for obtaining high sensitivity and specificity. For this clinical study, a threshold value of 14 was chosen as the optimal level, reducing the noise level to <5%. This low noise level ensured that the CADIA values obtained would include fewer false positive or negative results.

7.9 Comparison with other studies involving NobelActive™ implants

At present, there are only four published clinical studies reporting on the clinical success of the NobelActive™ implant. Kielbassa et al. (2009) reported on a randomised controlled clinical trial involving 12 centres and the placement of 325 implants, of which 117 were NobelActive™ internal implants. In comparison, this

present study involved a single centre, with four surgeons who placed a total of 64 implants. In both studies, implants were placed in healed sites, but in the multi-centre study implants were loaded immediately. After one year, the multi-centre survival rate of the NobelActive™ internal group was 96.6%, with no significant difference from the comparison groups. The greatest proportion of implants was placed in the posterior mandible, similar to the distribution in this study. Additionally, the median insertion torque was between 40-45Ncm, which is comparable to the values achieved in this study. The mean bone change around the NobelActive™ internal implants was 0.95mm with a standard deviation of 1.37mm, which correlates with the mean bone changes that occurred in our study. Hence, it could be concluded that the results achieved in our study were consistent with the outcomes of the only other randomised controlled trial involving the NobelActive™ implant system.

Irinakis and Wiebe (2009b) placed 104 NobelActive™ implants with a follow-up period of 9-13 months. A low early failure rate of 1.9% occurred and the authors were generally positive regarding the implant features. It was concluded that the NobelActive™ implant was able to achieve good primary stability through high insertion torques, though the authors stated that the system was “a useful adjunct to improve and expand treatment options for patients, but it does not replace the need for the traditionally shaped tapered and straight-walled implant systems”. In a second study, Irinakis and Wiebe (2009b) reported on the insertion torque of 140 NobelActive™ implants, with a 2.1% failure rate, mainly in the mandible. However, due to low numbers, no significant conclusion could be drawn. The mean insertion torque was shown to be very similar to the torques achieved in this study. The final

study by Orentlicher and Teich (2010) consisted of two case reports and hence could not be used for comparison.

7.10 Strengths of the study

The fundamental strength of this study was the split-mouth design, which accounted for systemic factors and factors that affected the oral environment. A feature of this design was that the treatment responses within an individual were correlated. Hence, the treatment outcome was only affected by a limited number of factors, such as, in this study, the local bone quality/quantity, implant design, and surgical protocol. There are very few studies comparing different implants placed in a split-mouth design and none comparing the NobelActive™ dental implant with a comparable system. Additionally, the control implant used in this study, the Brånemark™ Mk III implant system, is well-researched with a large amount of long-term evidence of clinical success. The control implant similarly has the TiUnite™ surface, hence removing one potential confounding factor.

The assessment of clinical and radiographic parameters was also very comprehensive, especially during the initial healing period. Resonance frequency analysis, using the most recent model (Osstell™ ISQ instrument), was recorded immediately after implant placement and at monthly intervals thereafter. RFA is considered to be the most accurate method to objectively monitor implant stability (Lachmann et al. 2006b, Oh et al. 2009) and hence, there is currently no better method to monitor the post-insertion healing of these implants.

The standardisation of periapical radiographs and the use of digital subtraction radiography allowed the detection of smaller bony changes and a more accurate analysis of bone levels than with conventional radiography (Janssen et al. 1989). Most studies involving the radiographic evaluation of implants use a long cone paralleling radiographic technique, which is suitable for monitoring of implants in the clinical setting. However, due to problems with exposure differences, variations in processing, changes in angulation, detection of small bony changes may be difficult and inaccurate, especially as about 30-50% of bone mineral must be lost before bony changes are visibly detectable in conventional radiographs (Dreyer 1993). The use of a putty bite and X-ray mount to standardise the angulation of the periapical radiograph ensured that accurate comparative measurements could be made longitudinally, which is essential for digital subtraction radiography (Toback et al. 1999). Though the measurements can always be proportioned according to a known reference length, such as the length of the implant, changing angulations over periods of months and years would affect the accuracy of small measurements and render comparison difficult.

The use of cone beam computed tomography in the regular monitoring of peri-implant implant bone has not been previously reported. The advantage of being able to visualise the thickness and height of the buccal and lingual/palatal cortical plates is invaluable, especially as these areas are usually superimposed on the implant body, preventing any assessment except through the invasive procedure of bone sounding/mapping. This tool could prove to be indispensable in the future to evaluate the possibility of future complications and also to monitor buccal marginal bone levels, which is of great importance around implants placed in aesthetic regions.

This study is currently ongoing, with the aim of achieving five years of follow-up. At present, no drop-outs have occurred, thus ensuring that no loss of data has occurred. Should the trend of complete data collection continue, it is projected that the final five year data will provide comprehensive long-term clinical evaluation of the NobelActive™ dental implant system.

7.11 Limitations of the study

The Brånemark™ Mk III implant, which was the control implant in this study, differs from the NobelActive™ implant with regard to several design features, including that the NobelActive™ implant is tapered, has an internal connection, and has built-in platform switching; whereas the control implant is parallel-walled, has an external hex connection, and was not platform switched in this study. The presence and location of the micro-gap has been shown to have an effect on the location of the marginal bone level. Internal connection implants with platform switching may potentially perform better clinically in comparison with external hex implants (Rodriguez-Ciurana et al. 2009b) and will tend to affect the peri-implant bone defect differently (Wang et al. 2010). Several published clinical reports have demonstrated a more favourable soft and hard tissue response using implants placed with platform switching compared with standard ones (Vela-Nebot et al. 2006, Canullo et al. 2007, Cappiello et al. 2008, Fickl et al. 2010). However, other studies have not found any clinical benefit of platform switching (Becker et al. 2009, Prosper et al. 2009). Hence, the different designs of the implants may have been a confounding factor in the evaluation of the NobelActive™ implant as the marginal bone may have responded differently to the connection. Another choice for the control implant could have been the

NobelReplace™ Select Tapered implant (Nobel Biocare AG), which has a tapered design and an internal connection. However, the long-term clinical data is limited and hence, the Brånemark system was preferentially chosen.

One factor that may have influenced the marginal bone levels is the repeated removal of the healing abutment and temporary crown during the initial months of healing post implant placement. This was a necessary procedure in order to gain access to the implant to allow resonance frequency analysis, through the insertion of an Osstell™ Smartpeg, and also for prosthetic procedures. The repeated dis/reconnection of the abutment results in marginal bone resorption as a result of the disruption of the mucosal barrier that attaches to the abutment (Abrahamsson et al. 1997). This has been attributed to the apical repositioning of the connective tissue component of the mucosal barrier, which results in apical migration of the marginal bone due to re-establishment of the biologic width.

Though the NobelActive™ implant is recommended for use in all clinical situations and for all placement protocols, the features of the implant would be most favourable in the poor bone quantity/quality site. As the study protocol involved placement in healed sites, the ideal testing site for the NobelActive™ implant would be in Type IV bone, typically found in the posterior maxilla. Unfortunately, due to the inclusion/exclusion criteria, only 8 out of the 32 cases involved placement of implants in this region. The majority of subjects (21) required replacement of missing teeth in the posterior mandible, where there is a tendency to be Type I and Type II bone, with sufficient quantities of cortical bone (Lekholm & Zarb 1985, Misch 1999). Hence, the full potential of this new implant could not be exploited. Similarly, immediate or early

placement may also have been more suitable, though this would render recruitment of subjects extremely difficult, especially for bilateral implant placement.

The analysis of cone beam computed tomography scans in the monitoring of peri-implant bone levels may be inaccurate due to the influence of beam hardening. Recently, the i-CAT CBCT scanner was used to evaluate peri-implant bone thickness and heights around implants placed in bovine ribs (Razavi et al. 2010). The authors concluded that the i-CAT CBCT scanner may not produce sufficient resolution of the thin cortical bone thickness adjacent to the dental implant and that the CBCT tends to overestimate the vertical distance between the top of the implant and the crestal bone. Additionally, Leung et al. (2010) found that the assessment of the buccal bone overlying tooth roots was less accurate than reported with artificially created defects, especially when the bone thickness was less than 0.6mm thick. Hence, with current CBCT technology, the accuracy of measurement of peri-implant bone levels is questionable and any information obtained from the scans should be assessed in conjunction with other clinical and radiographic information.

7.12 Further research

At present, the number of clinical studies involving the NobelActive™ dental implant is limited to four published studies, with only one randomised controlled trial and several case series and reports. Additionally, the greatest length of follow-up in any of the studies is one year, which is understandable considering that the NobelActive™ implant was launched in May 2007. There are several ongoing clinical studies assessing the system at present, and this present study is also ongoing, with an aimed

follow-up period of five years. Further studies are needed to assess the long-term success and survival of NobelActive™ dental implants, especially with different placement protocols, different loading protocols, and in compromised bone situations, such as where bone quality and quantity are inadequate. Ideally, studies should be conducted as randomised controlled trials, which will minimise bias and improve the strength of evidence. A study involving the placement of NobelActive™ implants in the posterior maxilla or with an immediate loading protocol would be beneficial in assessing the favourable properties of this system.

Further research is also needed in order to allow the regular use of cone beam computed tomography in the monitoring of bone levels around implants, which is currently the only non-invasive method to assess the bone volume around osseointegrating implants. CBCT technology and software will need to continue to develop in order to account for the phenomenon of beam hardening around metallic objects, which results in the software compensating and modifying the final image. Additionally, as the technology improves, the radiation dosage for each CBCT scan will be reduced, making it a more acceptable monitoring option over the long-term.

Though there has been a recent increase in the number of studies examining primary stability, mainly as a result of the increase in placement of immediate implants, the cause of early failure of implants continues to be controversial. Even with newer implant surfaces and a greater emphasis on achieving primary stability, failure of osseointegration, even in a healthy patient, continues to occur in the absence of any identifiable explanation. Undoubtedly, further research needs to be conducted to examine this issue.

7.13 Final thoughts

The observation that the NobelActive™ implants performed as well as the Brånemark implants, in terms of marginal bone remodelling and bone density changes surrounding implants, validates that this new implant is suitable for use in most clinical circumstances. Furthermore, in low density or very ‘soft’ bone (Type IV) situations, the NobelActive™ implant has the added advantage of inducing greater primary stability because of its design features.

On the other hand, excessively high torque forces used during driver insertion in ‘dense’ bone (Type I) may cause unexpected and unwanted physical damage to the bony structure of the implant site. This has the potential to induce pressure necrosis of the osteotomy wall, which could have long-term consequences to the establishment of adequate osseointegration. The adverse sequelae associated with placement of several of the NobelActive™ implants warrant further investigation and may indicate that manufacturer recommendations for site selection require minor amendments.

This study adds further support to the proposition that greater primary stability of the implant (as characterised by greater insertion torque) allows for early loading of these implants. From a clinical standpoint, this information has the potential of reducing treatment time with no long-term ill-effect on implant performance or survival.

8. CONCLUSIONS

1. The NobelActive™ dental implant system requires higher insertion torques and can also achieve greater primary stability compared to a control implant system.
2. Short-term survival of NobelActive™ dental implants and control implants are comparable though the NobelActive™ implant system appeared to be more technique sensitive and greater operator experience is recommended.
3. Short-term marginal bone levels around NobelActive™ dental implants and control implants are comparable.
4. The suitability of NobelActive™ implants to be used in low density or “soft bone” sites was not specifically tested in this study
5. The NobelActive™ dental implant is suitable for early loading.

9. APPENDIX

Appendix List

- Appendix 1: Brånemark™ and NobelActive™ dental implants
- Appendix 2: Design features of the NobelActive™ dental implant
- Appendix 3: Participant information and consent forms
- Appendix 4: Clinical recording form
- Appendix 5: Post-op instructions for patients receiving dental implants
- Appendix 6: Operator post-surgery evaluation form
- Appendix 7: Clinical photos of the standardised radiographic setup
- Appendix 8: Screenshot from the digital subtraction radiography program

Appendix 1: Brånemark™ and NobelActive™ dental implants



Brånemark™ dental implants



NobelActive™ dental implant

Appendix 2: Design features of the NobelActive™ dental implant

The NobelActive™ dental implant has been described as a third generation implant, with six key elements aimed at influencing the condensation, insertion, and stabilisation aspects of the implant into bone: (1) implant core with grooves, (2) coronal variable width threads, (3) apical variable thinner threads, (4) reverse tapping, (5) micro-rings on the coronal part, and (6) internal hexagon connection. The implant design has been discussed by Fromovich et al. (2010), though published data is limited.

The core of the implant is tapered, with each core segment being progressively larger than the segment apical to it. As the implant is inserted, there is a gradual condensation of the bone as the larger segments exert insertion forces onto the surrounding bone.

The NobelActive™ implant has a double thread pitch of 2.4mm, with a distance of 0.6mm between the threads. Comparatively, the Brånemark™ Mk III implant has a double thread pitch of 1.2mm and hence, the NobelActive™ implant can be inserted in half the number of turns. The external thread progressively changes profile, being sharper and higher at the apical end and wider and shorter at the coronal end. The sharp apical thread profile (35°) is aimed at tapping the bone, while the increased vertical height of the thread facilitates compression of low-density bone, increasing the stability of the implant. The greater thread depth, in combination with the TiUnite™ rough surface and small groove along the core of the implant, increase the surface area for macroscopic and microscopic bone-to-implant contact.

The key feature of the NobelActive™ implant is related to the reverse tapping configuration. In a standard implant, the active side of bone tap has a sharp angle to cut the bone while the other side of the tap has a blunt angle. However, the active edge of the NobelActive™ implant has a blunt angle so that bone is compressed when the implant is inserted. The other side of the tap has a sharp angle so that the edge can cut the cortical and trabecular bone into very small particles when the implant is reversed. The purpose of this reverse tapping is to reduce the resistance created by the bone, especially if the bone is dense. This is accomplished by rotating the implant several turns counterclockwise, resulting in the aggregation of small bone particles between the edges of the tap. Upon clockwise re-rotation, these bone particles are compressed into the tap and between the threads, increasing the condensation of the bone.

The coronal part of the implant, which is approximately 2mm in height, has an inverse taper design and micro-rings allowing cortical bone rebound following insertion. It aims to maintain the cortical bone thickness and height in this region. The prosthetic connection consists of an internal hexagonal connection with built-in platform switching.

The principal purpose of the NobelActive™ implant design is to achieve a high primary stability through the gradual compression of the surrounding bone. This results from a narrow implant bed preparation and tapered configuration of the core with tapered threads. As a result of the undersized osteotomy preparation and condensation on insertion, high insertion torques of more than 50Ncm can be achieved, even in soft bone. It is also suggested that insertion torques of up to 70Ncm

can be used without causing pressure necrosis as the implant is able to evenly distribute the forces along the implant, increasing forces to the trabecular bone and reducing forces to the cortical bone.

Appendix 3: Participant information and consent forms

SYDNEY WEST

Area Health Service

PARTICIPANT INFORMATION AND CONSENT FORMS

Study Title: Clinical and radiographic evaluation of NobelActive™ dental implants : a prospective split-mouth comparative study

Short Title: Evaluation of NobelActive™ dental implants

Chief Investigator: Professor Stephen Yeung

Department of Periodontics

What is the purpose of the study?

The NobelActive™ implant is a new system recently released in the Australian market and is undergoing vigorous clinical trials in Europe and USA. It is specifically designed to overcome “soft” bone and facilitate “stable” implant placement in difficult conditions such as in situations where bone volume and quality is compromised. The manufacturer claims that the NobelActive™ implant is more “user-friendly” in difficult conditions and can achieve comparable clinical result as conventional implants. We propose to conduct a controlled clinical trial in Australia (at Westmead Hospital, Centre for Oral Health) in order to determine the clinical efficacy of this new implant system.

Who will be invited to enter the study?

You have been invited to enter the study because you have two missing teeth on both sides of your jaw. These spaces will require replacement of teeth.

What will happen on the study?

During this study, there will be several visits involving treatment planning, surgery and reviews. The timeline is as follows:

Visit	Time (after surgery)	Procedures	Time needed
1	-	Examination, records, X-rays, and local CAT scans	60 mins
2	-	Treatment planning and consent	30 mins
3	0 days	Implant surgery, X-rays and local CAT scans	120 mins
4	7 days	Review and suture removal	15 mins
5	28 days	Examination, X-rays and local CAT scans	30 mins
6	56 days	Examination, X-rays and local CAT scans	30 mins
7	84 days	Examination, X-rays and local CAT scans	30 mins
8	1 year	Examination, X-rays and local CAT scans	30 mins
9	2 years	Examination and X-rays	30 mins
10	3 years	Examination and X-rays	30 mins
11	4 years	Examination and X-rays	30 mins
12	5 years	Examination and X-rays	30 mins

See notes below

Participant's Name

Signature

Date

Version No 2 dated 29/01/09

Page 1 of 5

SYDNEY WEST

Area Health Service

PARTICIPANT INFORMATION AND CONSENT FORMS

Study Title: Clinical and radiographic evaluation of NobelActive™ dental implants : a prospective split-mouth comparative study

Note:

- Local CAT scans involve cone beam computed tomography, which provides a 3D image of the teeth and bony structures
- Examination involves routine clinical examination of all oral structures and monitoring of the implant using probing and stability assessment. This will involve probing (measurement) of the tissues surrounding the implant and identifying inflammation (bleeding on probing).
- Implants surgery is performed under local anaesthesia and involves placement of two dental implants (one in each space)

Are there any risks?

All medical procedures involve some risk of injury. In addition, there may be risks associated with this study that are presently unknown or unforeseeable. In spite of all reasonable precautions, you might develop medical complications from participating in this study. The known risks of this study are:

- Failure of the implant to integrate with your jaw bone (3%)
- Developing mobility of the implant following integration with your jaw bone (5%)
- Accidental damage to important anatomical structures such as nerves supplying the teeth and jaws (<1%)
- Probing of the implant and bleeding induced by probing will result in reversible changes, with no permanent risks.

Are there any benefits?

You will receive two dental implants for the treatment of missing teeth in your dental arch.

Will taking part in this study cost me anything and will I be paid?

Treatment within the hospital is free of charge and all surgical procedures and after-care visits will be free to you. Naturally, you need to return to your own dentist for the final restorations to be restored on these implants.

Confidentiality / Privacy

All aspects of this study, including results, will be strictly confidential and only the researchers will have access to your personal information which will be kept in a locked drawer in the Periodontics Unit at the Westmead Centre for Oral Health. All records will be retained for 15 years after the completion of the study and then destroyed. Any publication of the results from this study will only use unidentifiable information.

Participant's Name

Signature

Date

Version No 2 dated 29/01/09

Page 2 of 5

PARTICIPANT INFORMATION AND CONSENT FORMS

Study Title: Clinical and radiographic evaluation of NobelActive™ dental implants : a prospective split-mouth comparative study

Compensation

Every reasonable precaution will be taken to ensure your safety during the course of this study. If you suffer any serious injuries or complications as a result of your participation in this study, you should, as soon as possible, contact the study doctor who will arrange appropriate medical treatment free of charge in any Australian public hospital.

Your participation in this study will not affect any right to compensation that you might have under statute or common law for any serious injuries or complications resulting from this study, caused by unsafe drugs or equipment or by negligence.

Do you have a choice?

Your participation in this study is entirely voluntary. If you choose not to join the study, or you wish to withdraw from it at any time, your medical care will not be affected.

Complaints

If you have any concerns about the conduct of the study, or your rights as a study participant, you may contact

Westmead Hospital Patient Representative, Ms Jillian Gwynne Lewis,
Telephone No 9845 7014 or email jillian.lewis@swahs.health.nsw.gov.au

Contact details

If you have any problems while on the study, please contact

Dr Danny Ho
Periodontics Registrar
Working hours Telephone No – (02) 98457428
After hours Telephone No - 0403315231

Participant's Name

Signature

Date

Version No 2 dated 29/01/09

Page 3 of 5

CONSENT TO PARTICIPATE IN RESEARCH

Study Title: Clinical and radiographic evaluation of NobelActive™ dental implants : a prospective split-mouth comparative study

Name of Researcher: Professor Stephen Yeung

1. I understand that the researcher will conduct this study in a manner conforming with ethical and scientific principles set out by the National Health and Medical Research Council of Australia and the Good Clinical Research Practice Guidelines of the Therapeutic Goods Administration.
2. I acknowledge that I have read, or have had read to me the Participant Information Sheet relating to this study. I acknowledge that I understand the Participant Information Sheet. I acknowledge that the general purposes, methods, demands and possible risks and inconveniences which may occur to me during the study have been explained to me by Dr Danny Ho and I, being over the age of 16 years, acknowledge that I understand the general purposes, methods, demands and possible risks and inconveniences which may occur during the study.
3. I acknowledge that I have been given time to consider the information and to seek other advice.
4. I acknowledge that refusal to take part in this study will not affect the usual treatment of my condition.
5. I acknowledge that I am volunteering to take part in this study and I may withdraw at any time.
6. I acknowledge that this research has been approved by the Sydney West Area Health Service Human Research Ethics Committee.
7. I acknowledge that I have received a copy of this form and the Participant Information Sheet, which I have signed.
8. I acknowledge that any regulatory authorities may have access to my medical records to monitor the research in which I am agreeing to participate. However, I understand my identity will not be disclosed to anyone else or in publications or presentations.

Before signing, please read 'IMPORTANT NOTE' following.

Name of participant _____ Date of Birth _____

Address of participant _____

Name of parent or person responsible (where applicable) _____

Address of parent or person responsible (where applicable) _____

Signature of participant _____ Date: _____

Signature of parent or person responsible (where applicable) _____ Date: _____

Signature of researcher _____ Date: _____

Signature of witness _____ Date: _____

IMPORTANT NOTE

Participant's Name

Signature

Date

SYDNEY WEST

Area Health Service

This consent should only be signed as follows:

1. Where a participant is over the age of 16 years, then by the participant personally.
2. Where a participant is between the age of 14 and 16 years, it should be signed by the participant and by a parent or person responsible.
3. Where a participant is under the age of 14 years, then the parent or person responsible only should sign the consent form.
4. Where a participant has impaired capacity, intellectual disability or is unconscious, then specific approval for the process for obtaining consent must be sought from the Human Research Ethics Committee.

WITNESS:

I, _____ (name of witness) hereby certify as follows:

1. I was present when _____ (the 'participant') appeared to read or had read to him/her a Participant Information Sheet comprising (_____ pages); **or** was told by _____ the participant that he/she had read the Participant Information Sheet (*delete as applicable*).
2. I was present when _____ (the 'researcher') explained the general purposes, methods, demands and the possible risks and inconveniences of participating in the study to the participant. I asked the participant whether he/she had understood the Participant Information Sheet and understood what he/she had been told and he/she told me that he/she did understand.
3. I observed the participant sign the consent to participate in research and he/she appeared to me to be signing the document freely and without duress.
4. The participant showed me a form of identification which satisfied me as to his/her identity.
5. I am not involved in any way as a researcher in this project.
6. (*Delete this clause if not applicable*) I was present when _____ (the 'interpreter') read the Participant Information Sheet to the participant in the _____ (*insert appropriate language*) language. I certify that when the researcher explained the general purposes, methods, demands and possible risks and inconveniences of participating in the study that what was said by both the researcher and the participant was translated by the interpreter from the English language into the above language and vice versa. When I spoke to the participant, what I said and what the participant said was translated by the interpreter from the English language into the above language and vice versa.

Name of witness _____ Relationship to participant _____

Address of witness _____

Signature of witness _____ Date: _____

Name of interpreter (if applicable) _____

Signature of Interpreter (if applicable) _____ Date: _____

Participant's Name

Signature

Date

Version No 2 dated 29/01/09

Page 5 of 5

Appendix 4: Clinical recording form

Clinical Recording Form

Subject number:

Pre-surgery evaluation

Date:

Full mouth BOP %:

Clinical recordings:	YES/NO
Study models taken:	YES/NO
Radiograph standardisation:	YES/NO
Site radiographs:	YES/NO
i-CAT taken:	YES/NO
Treatment plan:	YES/NO

Immediate post-placement

Date:

Left side:

Order of placement:

Implant diameter:

Implant length:

ISQ:

Insertion torque:

Time taken:

Radiograph taken: YES/NO

Right side:

Order of placement:

Implant diameter:

Implant length:

ISQ:

Insertion torque:

Time taken:

Radiograph taken: YES/NO

i-CAT taken: YES/NO

One month review

Date:

Full mouth BOP %:

i-CAT taken: YES/NO

Temp provisionalisation: YES/NO

Left side:

BOP:

	Mesial	Mid	Distal
Buccal			
Palatal/lingual			

PPD:

	Mesial	Mid	Distal
Buccal			
Palatal/lingual			

Mobility:

ISQ:

Suppuration: YES/NO

Pain (TTP): YES/NO

Periapical taken: YES/NO

Right side:

BOP:

	Mesial	Mid	Distal
Buccal			
Palatal/lingual			

PPD:

	Mesial	Mid	Distal
Buccal			
Palatal/lingual			

Mobility:

ISQ:

Suppuration: YES/NO

Pain (TTP): YES/NO

Periapical taken: YES/NO

Two month review

Date:

Full mouth BOP %:

i-CAT taken: YES/NO

Left side:

BOP:

	Mesial	Mid	Distal
Buccal			
Palatal/lingual			

PPD:

	Mesial	Mid	Distal
Buccal			
Palatal/lingual			

Mobility:

ISQ:

Suppuration: YES/NO

Pain (TTP): YES/NO

Periapical taken: YES/NO

Right side:

BOP:

	Mesial	Mid	Distal
Buccal			
Palatal/lingual			

PPD:

	Mesial	Mid	Distal
Buccal			
Palatal/lingual			

Mobility:

ISQ:

Suppuration: YES/NO

Pain (TTP): YES/NO

Periapical taken: YES/NO

Three month review

Date:

Full mouth BOP %:

i-CAT taken: YES/NO

Left side:

BOP:

	Mesial	Mid	Distal
Buccal			
Palatal/lingual			

PPD:

	Mesial	Mid	Distal
Buccal			
Palatal/lingual			

Mobility:

ISQ:

Suppuration: YES/NO

Pain (TTP): YES/NO

Periapical taken: YES/NO

Final restoration: YES/NO

Right side:

BOP:

	Mesial	Mid	Distal
Buccal			
Palatal/lingual			

PPD:

	Mesial	Mid	Distal
Buccal			
Palatal/lingual			

Mobility:

ISQ:

Suppuration: YES/NO

Pain (TTP): YES/NO

Periapical taken: YES/NO

Final restoration: YES/NO

Six month review

Date:

Full mouth BOP %:

Left side:

BOP:

	Mesial	Mid	Distal
Buccal			
Palatal/lingual			

PPD:

	Mesial	Mid	Distal
Buccal			
Palatal/lingual			

Mobility:

Suppuration: YES/NO

Pain (TTP): YES/NO

Periapical taken: YES/NO

Right side:

BOP:

	Mesial	Mid	Distal
Buccal			
Palatal/lingual			

PPD:

	Mesial	Mid	Distal
Buccal			
Palatal/lingual			

Mobility:

Suppuration: YES/NO

Pain (TTP): YES/NO

Periapical taken: YES/NO

One year review

Date:

Full mouth BOP %:

Left side:

BOP:

	Mesial	Mid	Distal
Buccal			
Palatal/lingual			

PPD:

	Mesial	Mid	Distal
Buccal			
Palatal/lingual			

Mobility:

Suppuration: YES/NO

Pain (TTP): YES/NO

Periapical taken: YES/NO

Right side:

BOP:

	Mesial	Mid	Distal
Buccal			
Palatal/lingual			

PPD:

	Mesial	Mid	Distal
Buccal			
Palatal/lingual			

Mobility:

Suppuration: YES/NO

Pain (TTP): YES/NO

Periapical taken: YES/NO

Appendix 5: Post-op instructions for patients receiving dental implants



Westmead Centre for Oral Health

IMPLANT UNIT

Instructions for patients receiving Osseointegrated Dental Implants

To assist the healing process, the following directions are to be observed during the two weeks after the operation:

1. Only soft food should be consumed during the first 6 days in order to avoid inadvertent food particles contaminating the wound. Please do eat - stews, soup, eggs, noodles, pasta, mashed potato, and any other soft nutritious foods are suitable. Smoking and consumption of alcoholic beverages should be avoided during this time period, as should excessive activity.
2. If possible, elevate the head with an extra pillow during the first two nights after the operation to reduce swelling in the operated areas.
3. Should any oozing/bleeding occur in the operated jaw it may usually be stopped by softly biting for 15 minutes on a roll of gauze dressing soaked in saline. If, following this procedure, the bleeding does not stop, your surgeon should be contacted. After hours Casualty Department 9845-6520.
4. After each meal the mouth should be thoroughly rinsed with warm saline solution. Cleaning of the mouth is most important to minimise the possibility of infection occurring.
5. A mouthwash containing chlorhexidine can be used alternatively with the saline solution.
6. Specific mouth washes or other disinfectants should not be used.
7. Oral hygiene - Don't brush the wound area for **at least one week**. To keep the area clean, you have been given an antiseptic mouth rinse call Chlorhexidine - rinse your mouth **twice a day** with 10 mls (one tablespoon) for **one minute**, then spit out. You can clean (brushing, flossing, etc.) Non-operated areas of the mouth as usual.
8. Old dentures may not be worn until refitting adjustments (relining) have been made. Insertion of dentures too early may jeopardize a successful healing process.
9. It is essential to take the supplied antibiotics as directed (usually 1 capsule 4 times daily for 10 days).
10. Analgesic tablets should be taken as prescribed as necessary for pain.
11. If you are in doubt or there is any sign whatsoever of a disorder related to the healing of your implant areas, you are requested to contact your surgeon.
12. Apply vaseline or lanolin lightly to the lips for first 2-3 days to keep lips from drying and cracking.
13. Covered ice packs applied to the side of the face for several hours post-operatively will provide some comfort for swelling resulting from surgery. However, the packs must be removed regularly to prevent skin damage.
14. Sutures will be removed 10 days post-operatively. An appointment will have been given to you for this purpose.


Appendix 6: Operator post-surgery evaluation form

Operator Post-Surgery Evaluation Form

1. How would you rate the overall experience of placing this implant?

Very problematic

Very positive



2. How would you rate the ease of placement of this implant?

Very difficult

Very simple



3. How would you rate the ease of placing the implant to the proposed depth?

Very difficult

Very simple



4. How would you rate the ease of placing the implant at the proposed location?

Very difficult


Very simple



5. How would you rate the ease of placing the implant at the proposed angulation?

Very difficult


Very simple



6. How would you rate the ease of use of the kit?

Very difficult

Very simple



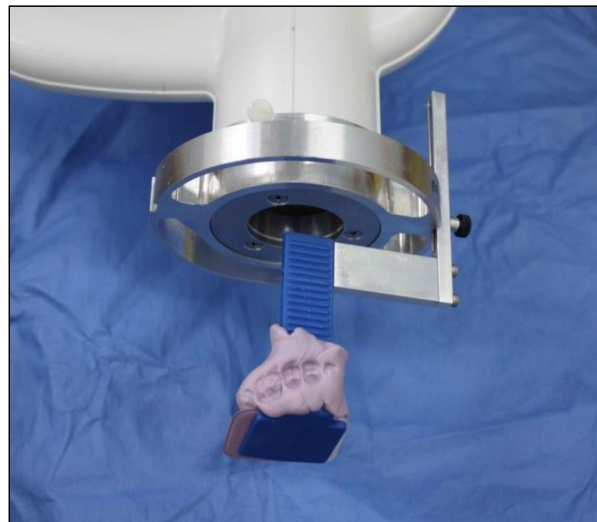
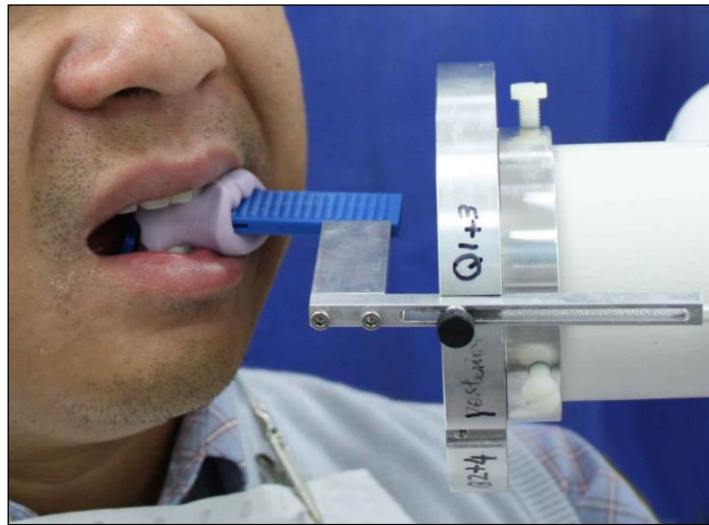7. Total time for placement?

_____ mins

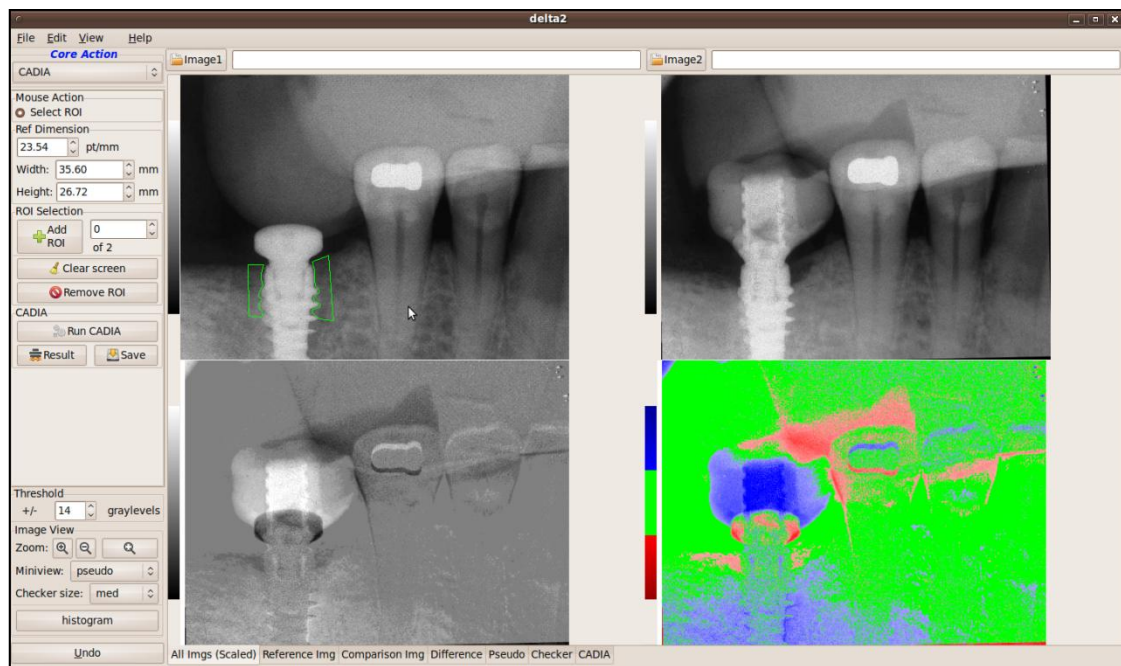
8. Any complications with placement?

Comments:

Appendix 7: Clinical photos of the standardised radiograph setup



Appendix 8: Screenshot from the digital subtraction radiography program



10. REFERENCES

- Abrahamsson, I., Berglundh, T., Linder, E., Lang, N. P. & Lindhe, J. (2004) Early bone formation adjacent to rough and turned endosseous implant surfaces. *Clinical Oral Implants Research* **15**, 381-392.
- Abrahamsson, I., Berglundh, T. & Lindhe, J. (1997) The mucosal barrier following abutment dis/reconnection. An experimental study in dogs. *Journal of Clinical Periodontology* **24**, 568-572.
- Abrahamsson, I., Linder, E. & Lang, N. (2009) Implant stability in relation to osseointegration: an experimental study in the Labrador dog. *Clinical Oral Implants Research* **20**, 313-318.
- Abuhussein, H., Pagni, G., Rebaudi, A. & Wang, H. L. (2010) The effect of thread pattern upon implant osseointegration. *Clinical Oral Implants Research* **21**, 129-136.
- Adell, R. (1983) Clinical results of osseointegrated implants supporting fixed prostheses in edentulous jaws. *The Journal of Prosthetic Dentistry* **50**, 251-254.
- Adell, R., Eriksson, B., Lekholm, U., Branemark, P. I. & Jemt, T. (1990) Long-term follow-up study of osseointegrated implants in the treatment of totally edentulous jaws. *International Journal of Oral & Maxillofacial Implants* **5**, 347-359.
- Adell, R., Lekholm, U. & Branemark, P. I. (1985) Surgical procedures. In: *Tissue-Integrated Prostheses: Osseointegration in Clinical Dentistry*, (eds.) P. I. Branemark, G. A. Zarb & T. Albrektsson, pp. 232. Chicago: Quintessence.

- Adell, R., Lekholm, U., Rockler, B. & Branemark, P. I. (1981) A 15-year study of osseointegrated implants in the treatment of the edentulous jaw. *International Journal of Oral Surgery* **10**, 387-416.
- Adell, R., Lekholm, U., Rockler, B., Branemark, P. I., Lindhe, J., Eriksson, B. & Sbordone, L. (1986) Marginal tissue reactions at osseointegrated titanium fixtures (I). A 3-year longitudinal prospective study. *International Journal of Oral & Maxillofacial Surgery* **15**, 39-52.
- Albrektsson, T. (1993) On long-term maintenance of the osseointegrated response. *Australian Prosthodontic Journal* **7 Suppl**, 15-24.
- Albrektsson, T., Branemark, P. I., Hansson, H. A. & Lindstrom, J. (1981) Osseointegrated titanium implants. Requirements for ensuring a long-lasting, direct bone-to-implant anchorage in man. *Acta Orthopaedica Scandinavica* **52**, 155-170.
- Albrektsson, T., Eriksson, A. R., Friberg, B., Lekholm, U., Lindahl, L., Nevins, M., Oikarinen, V., Roos, J., Sennerby, L. & Astrand, P. (1993) Histologic investigations on 33 retrieved Nobelpharma implants. *Clinical Materials* **12**, 1-9.
- Albrektsson, T., Johansson, C., Lundgren, A., Sul, Y. T. & Gottlow, J. (2000) Experimental studies on oxidized implants. A histomorphometrical analysis. *Applied Osseointegration Research* **1**, 21-24.
- Albrektsson, T., Zarb, G., Worthington, P. & Eriksson, A. R. (1986) The long-term efficacy of currently used dental implants: a review and proposed criteria of success. *International Journal of Oral & Maxillofacial Implants* **1**, 11-25.

- Albrektsson, T. & Zarb, G. A. (1993) Current interpretations of the osseointegrated response: clinical significance. *International Journal of Prosthodontics* **6**, 95-105.
- Albrektsson, T. O., Johansson, C. B. & Sennerby, L. (1994) Biological aspects of implant dentistry: osseointegration. *Periodontology 2000* **4**, 58-73.
- Alsaadi, G., Quirynen, M., Komarek, A. & van Steenberghe, D. (2008) Impact of local and systemic factors on the incidence of late oral implant loss. *Clinical Oral Implants Research* **19**, 670-676.
- Aparicio, C. (1997) The use of the Periotest value as the initial success criteria of an implant: 8-year report. *International Journal of Periodontics & Restorative Dentistry* **17**, 150-161.
- Aparicio, C., Lang, N. P. & Rangert, B. (2006) Validity and clinical significance of biomechanical testing of implant/bone interface. *Clinical Oral Implants Research* **17**, 2-7.
- Arai, Y., Tammissalo, E., Iwai, K., Hashimoto, K. & Shinoda, K. (1999) Development of a compact computed tomographic apparatus for dental use. *Dento-Maxillo-Facial Radiology* **28**, 245-248.
- Åstrand, P., Ahlqvist, J., Gunne, J. & Nilson, H. (2008) Implant treatment of patients with edentulous jaws: A 20-year follow-up. *Clinical Implant Dentistry and Related Research* **10**, 207-217.
- Atieh, M. A., Ibrahim, H. M. & Atieh, A. H. (2010) Platform switching for marginal bone preservation around dental implants: A systematic review and meta-analysis. *Journal of Periodontology*, 1-19.
- Australian Bureau of Statistics (2009) National Health Survey: Summary of results, 2007-2008. Canberra.

- Babbush, C. A., Kent, J. N. & Misiek, D. J. (1986) Titanium plasma-sprayed (TPS) screw implants for the reconstruction of the edentulous mandible. *Journal of Oral & Maxillofacial Surgery* **44**, 274-282.
- Badersten, A., Nilveus, R. & Egelberg, J. (1985) Effect of nonsurgical periodontal therapy. VII. Bleeding, suppuration and probing depth in sites with probing attachment loss. *Journal of Clinical Periodontology* **12**, 432-440.
- Bahat, O. (2000) Branemark system implants in the posterior maxilla: clinical study of 660 implants followed for 5 to 12 years. *International Journal of Oral & Maxillofacial Implants* **15**, 646-653.
- Bahat, O. (2009) Technique for placement of oxidized titanium implants in compromised maxillary bone: prospective study of 290 implants in 126 consecutive patients followed for a minimum of 3 years after loading. *International Journal of Oral & Maxillofacial Implants* **24**, 325-334.
- Balleri, P., Cozzolino, A., Ghelli, L., Momicchioli, G. & Varriale, A. (2002) Stability measurements of osseointegrated implants using Osstell in partially edentulous jaws after 1 year of loading: a pilot study. *Clinical Implant Dentistry & Related Research* **4**, 128-132.
- Ballrick, J. W., Palomo, J. M., Ruch, E., Amberman, B. D. & Hans, M. G. (2008) Image distortion and spatial resolution of a commercially available cone-beam computed tomography machine. *American Journal of Orthodontics and Dentofacial Orthopedics* **134**, 573-582.
- Balshi, T. J. & Wolfinger, G. J. (1997) Immediate loading of Branemark implants in edentulous mandibles: a preliminary report. *Implant Dentistry* **6**, 83-88.
- Becker, J., Ferrari, D., Mihatovic, I., Sahm, N., Schaer, A. & Schwarz, F. (2009) Stability of crestal bone level at platform-switched non-submerged titanium

- implants: a histomorphometrical study in dogs. *Journal of Clinical Periodontology* **36**, 532-539.
- Becker, W., Becker, B. E., Israelson, H., Lucchini, J. P., Handelsman, M., Ammons, W., Rosenberg, E., Rose, L., Tucker, L. M. & Lekholm, U. (1997) One-step surgical placement of Branemark implants: a prospective multicenter clinical study. *International Journal of Oral & Maxillofacial Implants* **12**, 454-462.
- Becktor, J. P., Isaksson, S. & Billstrom, C. (2007) A prospective multicenter study using two different surgical approaches in the mandible with turned Branemark implants: conventional loading using fixed prostheses. *Clinical Implant Dentistry & Related Research* **9**, 179-185.
- Behneke, A., Behneke, N. & d'Hoedt, B. (2000) The longitudinal clinical effectiveness of ITI solid-screw implants in partially edentulous patients: a 5-year follow-up report. *International Journal of Oral & Maxillofacial Implants* **15**, 633-645.
- Behneke, A., Behneke, N. & d'Hoedt, B. (2002) A 5-year longitudinal study of the clinical effectiveness of ITI solid-screw implants in the treatment of mandibular edentulism. *International Journal of Oral & Maxillofacial Implants* **17**, 799-810.
- Berglundh, T. & Lindhe, J. (1996) Dimension of the periimplant mucosa. Biological width revisited. *Journal of Clinical Periodontology* **23**, 971-973.
- Berglundh, T., Persson, L. & Klinge, B. (2002) A systematic review of the incidence of biological and technical complications in implant dentistry reported in prospective longitudinal studies of at least 5 years. *Journal of Clinical Periodontology* **29**, 197-212.

- Bernard, J. P., Belser, U. C., Martinet, J. P. & Borgis, S. A. (1995) Osseointegration of Branemark fixtures using a single-step operating technique. A preliminary prospective one-year study in the edentulous mandible. *Clinical Oral Implants Research* **6**, 122-129.
- Bischof, M., Nedir, R., Szmukler-Moncler, S., Bernard, J. P. & Samson, J. (2004) Implant stability measurement of delayed and immediately loaded implants during healing. *Clinical Oral Implants Research* **15**, 529-539.
- Bittar-Cortez, J. A., Passeri, L. A., Boscolo, F. N. & Haiter-Neto, F. (2006) Comparison of hard tissue density changes around implants assessed in digitized conventional radiographs and subtraction images. *Clinical Oral Implants Research* **17**, 560-564.
- Bornstein, M. M., Cionca, N. & Mombelli, A. (2009) Systemic conditions and treatments as risks for implant therapy. *International Journal of Oral & Maxillofacial Implants* **24 Suppl**, 12-27.
- Borsari, V., Giavaresi, G., Fini, M., Torricelli, P., Salito, A., Chiesa, R., Chiusoli, L., Volpert, A., Rimondini, L. & Giardino, R. (2005) Physical characterization of different-roughness titanium surfaces, with and without hydroxyapatite coating, and their effect on human osteoblast-like cells. *Journal of Biomedical Materials Research Part B, Applied Biomaterials* **75**, 359-368.
- Bragger, U. (1988) Digital imaging in periodontal radiography. A review. *Journal of Clinical Periodontology* **15**, 551-557.
- Bragger, U. (1994) Maintenance, monitoring, therapy of implant failures. *Proceedings of the First European Workshop in Periodontology*, 365-369.
- Bragger, U. (1998) Use of radiographs in evaluating success, stability and failure in implant dentistry. *Periodontology 2000* **17**, 77-88.

- Bragger, U., Hafeli, U., Huber, B., Hammerle, C. H. & Lang, N. P. (1998) Evaluation of postsurgical crestal bone levels adjacent to non-submerged dental implants. *Clinical Oral Implants Research* **9**, 218-224.
- Bragger, U., Pasquali, L. & Kornman, K. S. (1988a) Remodelling of interdental alveolar bone after periodontal flap procedures assessed by means of computer-assisted densitometric image analysis (CADIA). *Journal of Clinical Periodontology* **15**, 558-564.
- Bragger, U., Pasquali, L., Rylander, H., Carnes, D. & Kornman, K. S. (1988b) Computer-assisted densitometric image analysis in periodontal radiography. A methodological study. *Journal of Clinical Periodontology* **15**, 27-37.
- Branemark, P. I., Hansson, B. O., Adell, R., Breine, U., Lindstrom, J., Hallen, O. & Ohman, A. (1977) Osseointegrated implants in the treatment of the edentulous jaw. Experience from a 10-year period. *Scandinavian Journal of Plastic & Reconstructive Surgery - Supplementum* **16**, 1-132.
- Brooks, S. L. (2005) Effective dose of two cone-beam CT scanners: i-CAT and NewTom 3G. *Winter 2005 AADMRT Newsletter*.
- Brunski, J. B. (1993) Avoid pitfalls of overloading and micromotion of intraosseous implants. *Dental Implantology Update* **4**, 77-81.
- Buchter, A., Kleinheinz, J., Joos, U. & Meyer, U. (2003) Primary implant stability with different bone surgery techniques. An in vitro study of the mandible of the minipig. *Mund-, Kiefer- und Gesichtschirurgie* **7**, 351-355.
- Buchter, A., Kleinheinz, J., Wiesmann, H. P., Kersken, J., Nienkemper, M., Weyhrother, H., Joos, U. & Meyer, U. (2005) Biological and biomechanical evaluation of bone remodelling and implant stability after using an osteotome technique. *Clinical Oral Implants Research* **16**, 1-8.

- Buser, D., Broggin, N., Wieland, M., Schenk, R. K., Denzer, A. J., Cochran, D. L., Hoffmann, B., Lussi, A. & Steinemann, S. G. (2004) Enhanced bone apposition to a chemically modified SLA titanium surface. *Journal of Dental Research* **83**, 529-533.
- Buser, D., von Arx, T., ten Bruggenkate, C. & Weingart, D. (2000) Basic surgical principles with ITI implants. *Clinical Oral Implants Research* **11 Suppl 1**, 59-68.
- Buser, D., Weber, H. P. & Lang, N. P. (1990) Tissue integration of non-submerged implants. 1-year results of a prospective study with 100 ITI hollow-cylinder and hollow-screw implants. *Clinical Oral Implants Research* **1**, 33-40.
- Cameron, H., Macnab, I. & Pilliar, R. (1972) Porous surfaced Vitallium staples. *South African Journal of Surgery* **10**, 63-70.
- Cameron, H. U., Pilliar, R. M. & MacNab, I. (1973) The effect of movement on the bonding of porous metal to bone. *Journal of Biomedical Materials Research* **7**, 301-311.
- Canullo, L., Fedele, G. R., Iannello, G. & Jepsen, S. (2010) Platform switching and marginal bone-level alterations: the results of a randomized-controlled trial. *Clinical Oral Implants Research* **21**, 115-121.
- Canullo, L., Rasperini, G., Canullo, L. & Rasperini, G. (2007) Preservation of peri-implant soft and hard tissues using platform switching of implants placed in immediate extraction sockets: a proof-of-concept study with 12- to 36-month follow-up. *International Journal of Oral & Maxillofacial Implants* **22**, 995-1000.
- Cappiello, M., Luongo, R., Di Iorio, D., Bugea, C., Cocchetto, R. & Celletti, R. (2008) Evaluation of peri-implant bone loss around platform-switched

- implants. *International Journal of Periodontics & Restorative Dentistry* **28**, 347-355.
- Carr, A. B., Papazoglou, E. & Larsen, P. E. (1995) The relationship of Periotest values, biomaterial, and torque to failure in adult baboons. *International Journal of Prosthodontics* **8**, 15-20.
- Cehreli, M. C., Karasoy, D., Akca, K. & Eckert, S. E. (2009) Meta-analysis of methods used to assess implant stability. *International Journal of Oral & Maxillofacial Implants* **24**, 1015-1032.
- Chen, S. & Buser, D. (2008) Implants in post-extraction sites: A literature update. In: *ITI Treatment Guide. Vol 3: Implants in extraction sockets*, (eds.) D. Buser, U. C. Belser & D. Wismeijer, pp. 11-15. Berlin: Quintessence.
- Chen, S. T. & Buser, D. (2009) Clinical and esthetic outcomes of implants placed in postextraction sites. *International Journal of Oral & Maxillofacial Implants* **24 Suppl**, 186-217.
- Chiapasco, M. & Gatti, C. (2003) Implant-retained mandibular overdentures with immediate loading: a 3- to 8-year prospective study on 328 implants. *Clinical Implant Dentistry & Related Research* **5**, 29-38.
- Chiapasco, M., Gatti, C., Rossi, E., Haefliger, W. & Markwalder, T. H. (1997) Implant-retained mandibular overdentures with immediate loading. A retrospective multicenter study on 226 consecutive cases. *Clinical Oral Implants Research* **8**, 48-57.
- Chong, L., Khocht, A., Suzuki, J. B. & Gaughan, J. (2009) Effect of implant design on initial stability of tapered implants. *Journal of Oral Implantology* **35**, 130-135.

- Cochran, D. L., Nummikoski, P. V., Schoolfield, J. D., Jones, A. A. & Oates, T. W. (2009) A prospective multicenter 5-year radiographic evaluation of crestal bone levels over time in 596 dental implants placed in 192 patients. *Journal of Periodontology* **80**, 725-733.
- Collaert, B. & De Bruyn, H. (1998) Comparison of Branemark fixture integration and short-term survival using one-stage or two-stage surgery in completely and partially edentulous mandibles. *Clinical Oral Implants Research* **9**, 131-135.
- Cordaro, L., Torsello, F. & Rocuzzo, M. (2009) Clinical outcome of submerged vs. non-submerged implants placed in fresh extraction sockets. *Clinical Oral Implants Research* **20**, 1307-1313.
- Cury, P. R., Araujo, N. S., Bowie, J., Sallum, E. A. & Jeffcoat, M. K. (2004) Comparison between subtraction radiography and conventional radiographic interpretation during long-term evaluation of periodontal therapy in Class II furcation defects. *Journal of Periodontology* **75**, 1145-1149.
- da Cunha, H. A., Francischone, C. E., Filho, H. N. & de Oliveira, R. C. (2004) A comparison between cutting torque and resonance frequency in the assessment of primary stability and final torque capacity of standard and TiUnite single-tooth implants under immediate loading. *International Journal of Oral & Maxillofacial Implants* **19**, 578-585.
- Damstra, J., Fourie, Z., Huddleston Slater, J. J. R. & Ren, Y. (2010) Accuracy of linear measurements from cone-beam computed tomography-derived surface models of different voxel sizes. *American Journal of Orthodontics and Dentofacial Orthopedics* **137**, 16.e11-16.e16.
- de Oliveira, R. R., Novaes, A. B., Jr., Taba, M., Jr., de Souza, S. L. & Papalexiou, V. (2007) The effect of bone condensation and crestal preparation on the bone

- response to implants designed for immediate loading: a histomorphometric study in dogs. *International Journal of Oral & Maxillofacial Implants* **22**, 63-71.
- Deng, B., Tan, K. B., Liu, G. R. & Lu, Y. (2008) Influence of osseointegration degree and pattern on resonance frequency in the assessment of dental implant stability using finite element analysis. *International Journal of Oral & Maxillofacial Implants* **23**, 1082-1088.
- Deporter, D., Todescan, R. & Riley, N. (2002) Porous-surfaced dental implants in the partially edentulous maxilla: assessment for subclinical mobility. *International Journal of Periodontics & Restorative Dentistry* **22**, 184-192.
- Derhami, K., Wolfaardt, J. F., Faulkner, G. & Grace, M. (1995) Assessment of the periostest device in baseline mobility measurements of craniofacial implants. *International Journal of Oral & Maxillofacial Implants* **10**, 221-229.
- Dreyer, W. P. (1993) Technological advances in the clinical diagnosis of periodontal diseases. *International Dental Journal* **43**, 557-566.
- Duyck, J., Corpas, L., Vermeiren, S., Ogawa, T., Quirynen, M., Vandamme, K., Jacobs, R. & Naert, I. (2010) Histological, histomorphometrical, and radiological evaluation of an experimental implant design with a high insertion torque. *Clinical Oral Implants Research* **21**, 877-884.
- Ekelund, J. A., Lindquist, L. W., Carlsson, G. E. & Jemt, T. (2003) Implant treatment in the edentulous mandible: a prospective study on Branemark system implants over more than 20 years. *International Journal of Prosthodontics* **16**, 602-608.
- Ekfeldt, A., Christiansson, U., Eriksson, T., Linden, U., Lundqvist, S., Rundcrantz, T., Johansson, L. A., Nilner, K. & Billstrom, C. (2001) A retrospective analysis of

- factors associated with multiple implant failures in maxillae. *Clinical Oral Implants Research* **12**, 462-467.
- Ericsson, I., Persson, L. G., Berglundh, T., Marinello, C. P., Lindhe, J. & Klinge, B. (1995) Different types of inflammatory reactions in peri-implant soft tissues. *Journal of Clinical Periodontology* **22**, 255-261.
- Ericsson, I., Randow, K., Glantz, P. O., Lindhe, J. & Nilner, K. (1994) Clinical and radiographical features of submerged and nonsubmerged titanium implants. *Clinical Oral Implants Research* **5**, 185-189.
- Ericsson, I., Randow, K., Nilner, K. & Petersson, A. (1997) Some clinical and radiographical features of submerged and non-submerged titanium implants. A 5-year follow-up study. *Clinical Oral Implants Research* **8**, 422-426.
- Ersanli, S., Karabuda, C., Beck, F. & Leblebicioglu, B. (2005) Resonance frequency analysis of one- stage dental implant stability during the osseointegration period. *Journal of Periodontology* **76**, 1066-1071.
- Esposito, M., Grusovin, M. G., Chew, Y. S., Coulthard, P. & Worthington, H. V. (2009a) Interventions for replacing missing teeth: 1- versus 2-stage implant placement. *Cochrane Database of Systematic Reviews* **3**.
- Esposito, M., Grusovin, M. G., Willings, M., Coulthard, P. & Worthington, H. V. (2007) The effectiveness of immediate, early, and conventional loading of dental implants: a Cochrane systematic review of randomized controlled clinical trials. *International Journal of Oral & Maxillofacial Implants* **22**, 893-904.
- Esposito, M., Hirsch, J. M., Lekholm, U. & Thomsen, P. (1998) Biological factors contributing to failures of osseointegrated oral implants. (II). Etiopathogenesis. *European Journal of Oral Sciences* **106**, 721-764.

- Esposito, M., Koukouloupoulou, A., Coulthard, P. & Worthington, H. V. (2009b) Interventions for replacing missing teeth: dental implants in fresh extraction sockets (immediate, immediate-delayed and delayed implants). *Cochrane Database of Systematic Reviews* **1**.
- Faulkner, M. G., Giannitsios, D., Lipsett, A. W. & Wolfaardt, J. F. (2001) The use and abuse of the Periotest for 2-piece implant/abutment systems. *International Journal of Oral & Maxillofacial Implants* **16**, 486-494.
- Fickl, S., Zuhr, O., Stein, J. M. & Hurzeler, M. B. (2010) Peri-implant bone level around implants with platform-switched abutments. *International Journal of Oral & Maxillofacial Implants* **25**, 577-581.
- Fransson, C., Wennstrom, J. & Berglundh, T. (2008) Clinical characteristics at implants with a history of progressive bone loss. *Clinical Oral Implants Research* **19**, 142-147.
- Frenken, J. W., Bouwman, W. F., Bravenboer, N., Zijdeveld, S. A., Schulten, E. A. & ten Bruggenkate, C. M. (2010) The use of Straumann Bone Ceramic in a maxillary sinus floor elevation procedure: a clinical, radiological, histological and histomorphometric evaluation with a 6-month healing period. *Clinical Oral Implants Research* **21**, 201-208.
- Friberg, B. & Jemt, T. (2010) Clinical experience of TiUnite™ implants: A 5-year cross-sectional, retrospective follow-up study. *Clinical Implant Dentistry and Related Research* **12**, e95-e103.
- Friberg, B., Jemt, T. & Lekholm, U. (1991) Early failures in 4,641 consecutively placed Branemark dental implants: a study from stage 1 surgery to the connection of completed prostheses. *International Journal of Oral & Maxillofacial Implants* **6**, 142-146.

- Friberg, B., Sennerby, L., Gröndahl, K., Bergström, C., Bäck, T. & U., L. (1999a) On cutting torque measurements during implant placement: A 3-year clinical prospective study. *Clinical Implant Dentistry and Related Research* **1**, 75-83.
- Friberg, B., Sennerby, L., Linden, B., Grondahl, K. & Lekholm, U. (1999b) Stability measurements of one-stage Branemark implants during healing in mandibles. A clinical resonance frequency analysis study. *International Journal of Oral & Maxillofacial Surgery* **28**, 266-272.
- Friberg, B., Sennerby, L., Meredith, N. & Lekholm, U. (1999c) A comparison between cutting torque and resonance frequency measurements of maxillary implants. A 20-month clinical study. *International Journal of Oral & Maxillofacial Surgery* **28**, 297-303.
- Futami, T., Fujii, N., Ohnishi, H., Taguchi, N., Kusakari, H., Ohshima, H. & Maeda, T. (2000) Tissue response to titanium implants in the rat maxilla: Ultrastructural and histochemical observations of the bone-titanium interface. *Journal of Periodontology* **71**, 287-298.
- Gardner, D. M. (2005) Platform switching as a means to achieving implant esthetics. *New York State Dental Journal* **71**, 34-37.
- Gatti, C., Haefliger, W. & Chiapasco, M. (2000) Implant-retained mandibular overdentures with immediate loading: a prospective study of ITI implants. *International Journal of Oral & Maxillofacial Implants* **15**, 383-388.
- Glauser, R., Portmann, M., Ruhstaller, P., Lundgren, A., Hammerle, C. H. & Gottlow, J. (2001a) Stability measurements of immediately loaded machined and oxidized implants in the posterior maxilla. A comparative study using resonance frequency analysis. *Applied Osseointegration Research* **2**, 27-29.

- Glauser, R., Ree, A., Lundgren, A., Gottlow, J., Hammerle, C. H. & Scharer, P. (2001b) Immediate occlusal loading of Branemark implants applied in various jawbone regions: a prospective, 1-year clinical study. *Clinical Implant Dentistry & Related Research* **3**, 204-213.
- Glauser, R., Sennerby, L., Meredith, N., Rée, A., Lundgren, A., Gottlow, J. & Hämmerle, C. (2004) Resonance frequency analysis of implants subjected to immediate or early functional occlusal loading. *Clinical Oral Implants Research* **15**, 428-434.
- Glauser, R., Zembic, A., Ruhstaller, P. & Windisch, S. (2007) Five-year results of implants with an oxidized surface placed predominantly in soft quality bone and subjected to immediate occlusal loading. *The Journal of Prosthetic Dentistry* **97**, S59-S68.
- Gomez-Roman, G. (2001) Influence of flap design on peri-implant interproximal crestal bone loss around single-tooth implants. *International Journal of Oral & Maxillofacial Implants* **16**, 61-67.
- Göransson, A. & Wennerberg, A. (2005) Bone formation at titanium implants prepared with iso- and anisotropic surfaces of similar roughness: An in vivo study. *Clinical Implant Dentistry and Related Research* **7**, 17-23.
- Grimard, B. A., Hoidal, M. J., Mills, M. P., Mellonig, J. T., Nummikoski, P. V. & Mealey, B. L. (2009) Comparison of clinical, periapical radiograph, and cone-beam volume tomography measurement techniques for assessing bone level changes following regenerative periodontal therapy. *Journal of Periodontology* **80**, 48-55.

- Grondahl, H. G., Grondahl, K. & Webber, R. L. (1983) A digital subtraction technique for dental radiography. *Oral Surgery, Oral Medicine, Oral Pathology* **55**, 96-102.
- Grondahl, K., Grondahl, H. G., Wennstrom, J. & Heijl, L. (1987) Examiner agreement in estimating changes in periodontal bone from conventional and subtraction radiographs. *Journal of Clinical Periodontology* **14**, 74-79.
- Grondahl, K., Sunden, S. & Grondahl, H. G. (1998) Inter- and intraobserver variability in radiographic bone level assessment at Branemark fixtures. *Clinical Oral Implants Research* **9**, 243-250.
- Grunder, U., Gracis, S. & Capelli, M. (2005) Influence of the 3-D bone-to-implant relationship on esthetics. *International Journal of Periodontics & Restorative Dentistry* **25**, 113-119.
- Guerrero, M. E., Jacobs, R., Loubele, M., Schutyser, F., Suetens, P. & van Steenberghe, D. (2006) State-of-the-art on cone beam CT imaging for preoperative planning of implant placement. *Clinical Oral Investigations* **10**, 1-7.
- Gulsahi, A., Paksoy, C. S., Yazicioglu, N., Arpak, N., Kucuk, N. O. & Terzioglu, H. (2007) Assessment of bone density differences between conventional and bone-condensing techniques using dual energy x-ray absorptiometry and radiography. *Oral Surgery Oral Medicine Oral Pathology Oral Radiology & Endodontics* **104**, 692-698.
- Hahn, J. (1999) Clinical uses of osteotomes. *Journal of Oral Implantology* **25**, 23-29.
- Hall, J. & Lausmaa, J. (2000) Properties of a new porous oxide surface on titanium implants. *Applied Osseointegration Research* **1**, 5-8.

- Hall, J., Miranda-Burgos, P. & Sennerby, L. (2005) Stimulation of directed bone growth at oxidized titanium implants by macroscopic grooves: an in vivo study. *Clinical Implant Dentistry & Related Research* **7 Suppl 1**, S76-82.
- Han, C. H., Johansson, C. B., Wennerberg, A. & Albrektsson, T. (1998) Quantitative and qualitative investigations of surface enlarged titanium and titanium alloy implants. *Clinical Oral Implants Research* **9**, 1-10.
- Hansson, S. (1999) The implant neck: smooth or provided with retention elements. A biomechanical approach. *Clinical Oral Implants Research* **10**, 394-405.
- Hashimoto, K., Arai, Y., Iwai, K., Araki, M., Kawashima, S. & Terakado, M. (2003) A comparison of a new limited cone beam computed tomography machine for dental use with a multidetector row helical CT machine. *Oral Surgery Oral Medicine Oral Pathology Oral Radiology & Endodontics* **95**, 371-377.
- Hausmann, E. (2000) Radiographic and digital imaging in periodontal practice. *Journal of Periodontology* **71**, 497-503.
- Hausmann, E., Christersson, L., Dunford, R., Wikesjo, U., Phyto, J. & Genco, R. J. (1985) Usefulness of subtraction radiography in the evaluation of periodontal therapy. *Journal of Periodontology* **56**, 4-7.
- Hausmann, E., Dunford, R., Wikesjo, U., Christersson, L. & McHenry, K. (1986) Progression of untreated periodontitis as assessed by subtraction radiography. *Journal of Periodontal Research* **21**, 716-721.
- Heitz-Mayfield, L. J. (2008) Peri-implant diseases: diagnosis and risk indicators. *Journal of Clinical Periodontology* **35**, 292-304.
- Heitz-Mayfield, L. J. & Huynh-Ba, G. (2009) History of treated periodontitis and smoking as risks for implant therapy. *International Journal of Oral & Maxillofacial Implants* **24 Suppl**, 39-68.

- Henry, P., Tan, A., Allan, B., Hall, J. & Johansson, B. (2000) Removal torque comparison of TiUnite and turned implants in the greyhound dog mandible. *Applied Osseointegration Research* **1**, 15-17.
- Henry, P. J., Laney, W. R., Jemt, T., Harris, D., Krogh, P. H., Polizzi, G., Zarb, G. A. & Herrmann, I. (1996) Osseointegrated implants for single-tooth replacement: a prospective 5-year multicenter study. *International Journal of Oral & Maxillofacial Implants* **11**, 450-455.
- Hermann, J. S., Buser, D., Schenk, R. K. & Cochran, D. L. (2000) Crestal bone changes around titanium implants. A histometric evaluation of unloaded non-submerged and submerged implants in the canine mandible. *Journal of Periodontology* **71**, 1412-1424.
- Hermann, J. S., Schoolfield, J. D., Nummikoski, P. V., Buser, D., Schenk, R. K. & Cochran, D. L. (2001a) Crestal bone changes around titanium implants: a methodologic study comparing linear radiographic with histometric measurements. *International Journal of Oral & Maxillofacial Implants* **16**, 475-485.
- Hermann, J. S., Schoolfield, J. D., Schenk, R. K., Buser, D. & Cochran, D. L. (2001b) Influence of the size of the microgap on crestal bone changes around titanium implants. A histometric evaluation of unloaded non-submerged implants in the canine mandible. *Journal of Periodontology* **72**, 1372-1383.
- Horwitz, J., Zuabi, O. & Peled, M. (2003) Resonance frequency analysis in immediate loading of dental implants. *Refuat Hapeh Vehashinayim* **20**, 80-88.
- Huang, Y.-H., Xiropaidis, A. V., Sorensen, R. G., Albandar, J. M., Hall, J. & Wikesjo, U. M. E. (2005) Bone formation at titanium porous oxide (TiUnite) oral implants in type IV bone. *Clinical Oral Implants Research* **16**, 105-111.

- Huwiler, M. A., Pjetursson, B. E., Bosshardt, D. D., Salvi, G. E. & Lang, N. P. (2007) Resonance frequency analysis in relation to jawbone characteristics and during early healing of implant installation. *Clinical Oral Implants Research* **18**, 275-280.
- Irinakis, T. & Wiebe, C. (2009a) Clinical evaluation of the NobelActive implant system: a case series of 107 consecutively placed implants and a review of the implant features. *Journal of Oral Implantology* **35**, 283-288.
- Irinakis, T. & Wiebe, C. (2009b) Initial torque stability of a new bone condensing dental implant. A cohort study of 140 consecutively placed implants. *Journal of Oral Implantology* **35**, 277-282.
- Ito, K., Gomi, Y., Sato, S., Arai, Y. & Shinoda, K. (2001a) Clinical application of a new compact CT system to assess 3-D images for the preoperative treatment planning of implants in the posterior mandible A case report. *Clinical Oral Implants Research* **12**, 539-542.
- Ito, K., Yoshinuma, N., Yoshinuma, E., Arai, Y. & Shinoda, K. (2001b) Clinical application of a new compact computed tomography system for evaluating the outcome of regenerative therapy: A case report. *Journal of Periodontology* **72**, 696-702.
- Ito, Y., Sato, D., Yoneda, S., Ito, D., Kondo, H. & Kasugai, S. (2008) Relevance of resonance frequency analysis to evaluate dental implant stability: simulation and histomorphometrical animal experiments. *Clinical Oral Implants Research* **19**, 9-14.
- Ivanoff, C. J., Sennerby, L. & Lekholm, U. (1997) Reintegration of mobilized titanium implants: An experimental study in rabbit tibia. *International Journal of Oral and Maxillofacial Surgery* **26**, 310-315.

- Janssen, P. T. M., Palenstein Helderman, W. H. & Aken, J. (1989) The detection of in vitro produced periodontal bone lesions by conventional radiography and photographic subtraction radiography using observers and quantitative digital subtraction radiography. *Journal of Clinical Periodontology* **16**, 335-341.
- Jeffcoat, M. K. (1992) Radiographic methods for the detection of progressive alveolar bone loss. *Journal of Periodontology* **63**, 367-372.
- Jeffcoat, M. K., Page, R., Reddy, M., Wannawisute, A., Waite, P., Palcanis, K., Cogen, R., Williams, R. C. & Basch, C. (1991) Use of digital radiography to demonstrate the potential of naproxen as an adjunct in the treatment of rapidly progressive periodontitis. *Journal of Periodontal Research* **26**, 415-421.
- Jemt, T. & Johansson, J. (2006) Implant treatment in the edentulous maxillae: A 15-year follow-up study on 76 consecutive patients provided with fixed prostheses. *Clinical Implant Dentistry and Related Research* **8**, 61-69.
- Jensen, S. S. & Terheyden, H. (2009) Bone augmentation procedures in localized defects in the alveolar ridge: clinical results with different bone grafts and bone-substitute materials. *International Journal of Oral & Maxillofacial Implants* **24 Suppl**, 218-236.
- Jepsen, S., Ruhling, A., Jepsen, K., Ohlenbusch, B. & Albers, H. K. (1996) Progressive peri-implantitis. Incidence and prediction of peri-implant attachment loss. *Clinical Oral Implants Research* **7**, 133-142.
- Johansson, B., Back, T. & Hirsch, J. M. (2004) Cutting torque measurements in conjunction with implant placement in grafted and nongrafted maxillas as an objective evaluation of bone density: a possible method for identifying early implant failures? *Clinical Implant Dentistry & Related Research* **6**, 9-15.

- Johansson, C. & Albrektsson, T. (1987) Integration of screw implants in the rabbit: a 1-year follow-up of removal torque of titanium implants. *International Journal of Oral & Maxillofacial Implants* **2**, 69-75.
- Jokstad, A., Braegger, U., Brunski, J. B., Carr, A. B., Naert, I. & Wennerberg, A. (2003) Quality of dental implants. *International Dental Journal* **53**, 409-443.
- Jung, R. E., Pjetursson, B. E., Glauser, R., Zembic, A., Zwahlen, M. & Lang, N. P. (2008) A systematic review of the 5-year survival and complication rates of implant-supported single crowns. *Clinical Oral Implants Research* **19**, 119-130.
- Jung, Y. C., Han, C. H. & Lee, K. W. (1996) A 1-year radiographic evaluation of marginal bone around dental implants. *International Journal of Oral & Maxillofacial Implants* **11**, 811-818.
- Jungner, M., Lundqvist, M. & Lundgren, S. (2005) Oxidized titanium implants (Nobel Biocare TiUnite) compared with turned titanium implants (Nobel Biocare mark III) with respect to implant failure in a group of consecutive patients treated with early functional loading and two-stage protocol. *Clinical Oral Implants Research* **16**, 308-312.
- Karmon, B., Kohen, J., Lor, A., Gratciany, Y., Laster, T., Hallel, G. & Karmon, T. (2007) Initial report from a retrospective multi-center study on the SPIRAL implant. In: *Nobel Biocare World Conference*. Las Vegas.
- Kielbassa, A. M., Fuentes, R. M.-d., Goldstein, M., Arnhart, C., Barlattani, A., Jackowski, J., Knauf, M., Lorenzoni, M., Maiorana, C., Mericske-Stern, R., Rompen, E. & Sanz, M. (2009) Randomized controlled trial comparing a variable-thread novel tapered and a standard tapered implant: Interim one-year results. *The Journal of Prosthetic Dentistry* **101**, 293-305.

- King, G. N., Hermann, J. S., Schoolfield, J. D., Buser, D. & Cochran, D. L. (2002) Influence of the size of the microgap on crestal bone levels in non-submerged dental implants: a radiographic study in the canine mandible. *Journal of Periodontology* **73**, 1111-1117.
- Kullman, L., Al-Asfour, A., Zetterqvist, L. & Andersson, L. (2007) Comparison of radiographic bone height assessments in panoramic and intraoral radiographs of implant patients. *International Journal of Oral & Maxillofacial Implants* **22**, 96-100.
- Lachmann, S., Jäger, B., Axmann, D., Gomez-Roman, G., Groten, M. & Weber, H. P. (2006a) Resonance frequency analysis and damping capacity assessment. *Clinical Oral Implants Research* **17**, 75-79.
- Lachmann, S., Laval, J. Y., Jäger, B., Axmann, D., Gomez-Roman, G., Groten, M. & Weber, H. P. (2006b) Resonance frequency analysis and damping capacity assessment. *Clinical Oral Implants Research* **17**, 80-84.
- Lang, N. P., Adler, R., Joss, A. & Nyman, S. (1990) Absence of bleeding on probing. An indicator of periodontal stability. *Journal of Clinical Periodontology* **17**, 714-721.
- Lang, N. P., Berglundh, T., Heitz-Mayfield, L. J., Pjetursson, B. E., Salvi, G. E. & Sanz, M. (2004) Consensus statements and recommended clinical procedures regarding implant survival and complications. *International Journal of Oral & Maxillofacial Implants* **19 Suppl**, 150-154.
- Lang, N. P., Joss, A., Orsanic, T., Gusberti, F. A. & Siegrist, B. E. (1986) Bleeding on probing. A predictor for the progression of periodontal disease? *Journal of Clinical Periodontology* **13**, 590-596.

- Lang, N. P., Wetzel, A. C., Stich, H. & Caffesse, R. G. (1994) Histologic probe penetration in healthy and inflamed peri-implant tissues. *Clinical Oral Implants Research* **5**, 191-201.
- Lascaia, C. A., Panella, J. & Marques, M. M. (2004) Analysis of the accuracy of linear measurements obtained by cone beam computed tomography (CBCT-NewTom). *Dento-Maxillo-Facial Radiology* **33**, 291-294.
- Lazzara, R. J. & Porter, S. S. (2006) Platform switching: a new concept in implant dentistry for controlling postrestorative crestal bone levels. *International Journal of Periodontics & Restorative Dentistry* **26**, 9-17.
- Lekholm, U., Grondahl, K. & Jemt, T. (2006) Outcome of oral implant treatment in partially edentulous jaws followed 20 years in clinical function. *Clinical Implant Dentistry & Related Research* **8**, 178-186.
- Lekholm, U., Gunne, J., Henry, P., Higuchi, K., Linden, U., Bergstrom, C. & van Steenberghe, D. (1999) Survival of the Branemark implant in partially edentulous jaws: a 10-year prospective multicenter study. *International Journal of Oral & Maxillofacial Implants* **14**, 639-645.
- Lekholm, U. & Zarb, G. (1985) Patient selection and preparation. In: *Tissue-integrated Prostheses: Osseointegration in Clinical Dentistry*, (eds.) P. I. Branemark, G. Zarb & T. Albrektsson, pp. 199-209. Chicago: Quintessence.
- Leung, C. C., Palomo, L., Griffith, R. & Hans, M. G. (2010) Accuracy and reliability of cone-beam computed tomography for measuring alveolar bone height and detecting bony dehiscences and fenestrations. *American Journal of Orthodontics and Dentofacial Orthopedics* **137**, S109-S119.
- Lindquist, L. W., Carlsson, G. E. & Jemt, T. (1996) A prospective 15-year follow-up study of mandibular fixed prostheses supported by osseointegrated implants.

- Clinical results and marginal bone loss. *Clinical Oral Implants Research* **7**, 329-336.
- Lindquist, L. W., Rockler, B. & Carlsson, G. E. (1988) Bone resorption around fixtures in edentulous patients treated with mandibular fixed tissue-integrated prostheses. *Journal of Prosthetic Dentistry* **59**, 59-63.
- Lioubavina-Hack, N., Lang, N. P. & Karring, T. (2006) Significance of primary stability for osseointegration of dental implants. *Clinical Oral Implants Research* **17**, 244-250.
- Liu, Y., Olszewski, R., Alexandroni, E. S., Enciso, R., Xu, T. & Mah, J. K. (2010) The validity of in vivo tooth volume determinations from cone-beam computed tomography. *The Angle Orthodontist* **80**, 160-166.
- Loubele, M., Jacobs, R., Maes, F., Denis, K., White, S., Coudyzer, W., Lambrichts, I., van Steenberghe, D. & Suetens, P. (2008) Image quality vs radiation dose of four cone beam computed tomography scanners. *Dentomaxillofac Radiol* **37**, 309-319.
- Ludlow, J. B., Davies-Ludlow, L. E. & Brooks, S. L. (2003) Dosimetry of two extraoral direct digital imaging devices: NewTom cone beam CT and Orthophos Plus DS panoramic unit. *Dento-Maxillo-Facial Radiology* **32**, 229-234.
- Ludlow, J. B., Davies-Ludlow, L. E., Brooks, S. L. & Howerton, W. B. (2006) Dosimetry of 3 CBCT devices for oral and maxillofacial radiology: CB Mercuray, NewTom 3G and i-CAT. *Dento-Maxillo-Facial Radiology* **35**, 219-226.
- Luterbacher, S., Mayfield, L., Bragger, U. & Lang, N. P. (2000) Diagnostic characteristics of clinical and microbiological tests for monitoring periodontal

- and peri-implant mucosal tissue conditions during supportive periodontal therapy (SPT). *Clinical Oral Implants Research* **11**, 521-529.
- Maeda, Y., Miura, J., Taki, I. & Sogo, M. (2007) Biomechanical analysis on platform switching: is there any biomechanical rationale? *Clinical Oral Implants Research* **18**, 581-584.
- Maniatopoulos, C., Pilliar, R. M. & Smith, D. C. (1986) Threaded versus porous-surfaced designs for implant stabilization in bone-endodontic implant model. *Journal of Biomedical Materials Research* **20**, 1309-1333.
- Mardas, N., Chadha, V. & Donos, N. (2010) Alveolar ridge preservation with guided bone regeneration and a synthetic bone substitute or a bovine-derived xenograft: a randomized, controlled clinical trial. *Clinical Oral Implants Research* **21**, 688-698.
- Marmulla, R., Wortche, R., Muhling, J. & Hassfeld, S. (2005) Geometric accuracy of the NewTom 9000 Cone Beam CT. *Dento-Maxillo-Facial Radiology* **34**, 28-31.
- Masuda, T., Yliheikkila, P. K., Felton, D. A. & Cooper, L. F. (1998) Generalizations regarding the process and phenomenon of osseointegration. Part I. In vivo studies. *International Journal of Oral & Maxillofacial Implants* **13**, 17-29.
- Mengel, R., Candir, M., Shiratori, K. & Flores-de-Jacoby, L. (2005) Digital volume tomography in the diagnosis of periodontal defects: An in vitro study on native pig and human mandibles. *Journal of Periodontology* **76**, 665-673.
- Mengel, R., Kruse, B. & Flores-de-Jacoby, L. (2006) Digital volume tomography in the diagnosis of peri-implant defects: An in vitro study on native pig mandibles. *Journal of Periodontology* **77**, 1234-1241.

- Meredith, N. (1998) Assessment of implant stability as a prognostic determinant. *International Journal of Prosthodontics* **11**, 491-501.
- Meredith, N., Alleyne, D. & Cawley, P. (1996) Quantitative determination of the stability of the implant-tissue interface using resonance frequency analysis. *Clinical Oral Implants Research* **7**, 261-267.
- Meredith, N., Book, K., Friberg, B., Jemt, T. & Sennerby, L. (1997) Resonance frequency measurements of implant stability in vivo. A cross-sectional and longitudinal study of resonance frequency measurements on implants in the edentulous and partially dentate maxilla. *Clinical Oral Implants Research* **8**, 226-233.
- Mesa, F., Munoz, R., Noguerol, B., de Dios Luna, J., Galindo, P. & O'Valle, F. (2008) Multivariate study of factors influencing primary dental implant stability. *Clinical Oral Implants Research* **19**, 196-200.
- Misch, K. (1999) Bone density: A key determinant for clinical success. In: *Implant Dentistry*, (ed.) K. Misch, pp. 345-380. St Louis: Mosby.
- Misch, K. A., Yi, E. S. & Sarment, D. P. (2006) Accuracy of cone beam computed tomography for periodontal defect measurements. *Journal of Periodontology* **77**, 1261-1266.
- Mombelli, A. (1999) Prevention and therapy of peri-implant infections. *Proceedings of the Third European Workshop in Periodontology*, 281-303.
- Mombelli, A. (2002) Microbiology and antimicrobial therapy of peri-implantitis. *Periodontology 2000* **28**, 177-189.
- Mombelli, A., van Oosten, M. A., Schurch, E., Jr. & Land, N. P. (1987) The microbiota associated with successful or failing osseointegrated titanium implants. *Oral Microbiology & Immunology* **2**, 145-151.

- Monsour, P. A. & Dudhia, R. (2008) Implant radiography and radiology. *Australian Dental Journal* **53 Suppl 1**, S11-25.
- Morris, H. E., Ochi, S., Crum, P., Orenstein, I. & Plezia, R. (2003) Bone density: its influence on implant stability after uncovering. *Journal of Oral Implantology* **29**, 263-269.
- Mustafa, K., Wroblewski, J., Hulthenby, K., Lopez, B. S. & Arvidson, K. (2000) Effects of titanium surfaces blasted with TiO₂ particles on the initial attachment of cells derived from human mandibular bone. A scanning electron microscopic and histomorphometric analysis. *Clinical Oral Implants Research* **11**, 116-128.
- Natali, A. N., Pavan, P. G., Schileo, E. & Williams, K. R. (2006) A numerical approach to resonance frequency analysis for the investigation of oral implant osseointegration. *Journal of Oral Rehabilitation* **33**, 674-681.
- Ngan, D. C., Kharbanda, O. P., Geenty, J. P. & Darendeliler, M. A. (2003) Comparison of radiation levels from computed tomography and conventional dental radiographs. *Australian Orthodontic Journal* **19**, 67-75.
- Nicopoulou-Karayianni, K., Bragger, U., Burgin, W., Nielsen, P. M. & Lang, N. P. (1991) Diagnosis of alveolar bone changes with digital subtraction images and conventional radiographs. An in vitro study. *Oral Surgery, Oral Medicine, Oral Pathology* **72**, 251-256.
- Nicopoulou-Karayianni, K., Bragger, U. & Lang, N. P. (1997) Subtraction radiography in oral implantology. *International Journal of Periodontics & Restorative Dentistry* **17**, 220-231.
- Nkenke, E., Kloss, F., Wiltfang, J., Schultze-Mosgau, S., Radespiel-Troger, M., Loos, K. & Neukam, F. W. (2002) Histomorphometric and fluorescence microscopic

- analysis of bone remodelling after installation of implants using an osteotome technique. *Clinical Oral Implants Research* **13**, 595-602.
- Noguerol, B., Muñoz, R., Mesa, F., de Dios Luna, J. & O'Valle, F. (2006) Early implant failure. Prognostic capacity of Periotest: retrospective study of a large sample. *Clinical Oral Implants Research* **17**, 459-464.
- Nummikoski, P. V., Steffensen, B., Hamilton, K. & Dove, S. B. (2000) Clinical validation of a new subtraction radiography technique for periodontal bone loss detection. *Journal of Periodontology* **71**, 598-605.
- O'Sullivan, D., Sennerby, L., Jagger, D. & Meredith, N. (2004a) A comparison of two methods of enhancing implant primary stability. *Clinical Implant Dentistry and Related Research* **6**, 48-57.
- O'Sullivan, D., Sennerby, L. & Meredith, N. (2000) Measurements comparing the initial stability of five designs of dental implants: a human cadaver study. *Clinical Implant Dentistry & Related Research* **2**, 85-92.
- O'Sullivan, D., Sennerby, L. & Meredith, N. (2004b) Influence of implant taper on the primary and secondary stability of osseointegrated titanium implants. *Clinical Oral Implants Research* **15**, 474-480.
- Oh, J. S., Kim, S. G., Lim, S. C. & Ong, J. L. (2009) A comparative study of two noninvasive techniques to evaluate implant stability: Periotest and Osstell Mentor. *Oral Surgery Oral Medicine Oral Pathology Oral Radiology & Endodontics* **107**, 513-518.
- Oh, T. J., Yoon, J., Misch, C. E. & Wang, H. L. (2002) The causes of early implant bone loss: myth or science? *Journal of Periodontology* **73**, 322-333.

- Olive, J. & Aparicio, C. (1990) Periotest method as a measure of osseointegrated oral implant stability. *International Journal of Oral & Maxillofacial Implants* **5**, 390-400.
- Orentlicher, G. & Teich, M. (2010) Evolving implant design. The NobelActive implant: discussion and case presentations. *Compendium of Continuing Education in Dentistry* **31**, 66-70.
- Ostman, P. O., Hellman, M. & Sennerby, L. (2008) Immediate occlusal loading of implants in the partially edentate mandible: a prospective 1-year radiographic and 4-year clinical study. *International Journal of Oral & Maxillofacial Implants* **23**, 315-322.
- Ostman, P. O., Hellman, M., Wendelhag, I. & Sennerby, L. (2006) Resonance frequency analysis measurements of implants at placement surgery. *International Journal of Prosthodontics* **19**, 77-83; discussion 84.
- Pantani, F., Botticelli, D., Jr., I. R. G., Salata, L. A., Borges, G. J. & Lang, N. P. (2010) Influence of lateral pressure to the implant bed on osseointegration: an experimental study in dogs. *Clinical Oral Implants Research* **21**, 1264-1270.
- Perren, S. M. (2002) Evolution of the internal fixation of long bone fractures. The scientific basis of biological internal fixation: choosing a new balance between stability and biology. *Journal of Bone & Joint Surgery* **84**, 1093-1110.
- Pham, A. N., Fiorellini, J. P., Paquette, D., Williams, R. C. & Weber, H. P. (1994) Longitudinal radiographic study of crestal bone levels adjacent to non-submerged dental implants. *Journal of Oral Implantology* **20**, 26-34.
- Pharoah, M. J. (1993) Imaging techniques and their clinical significance. *International Journal of Prosthodontics* **6**, 176-179.

- Pinsky, H. M., Dyda, S., Pinsky, R. W., Misch, K. A. & Sarment, D. P. (2006) Accuracy of three-dimensional measurements using cone-beam CT. *Dento-Maxillo-Facial Radiology* **35**, 410-416.
- Pjetursson, B. E., Tan, K., Lang, N. P., Bragger, U., Egger, M. & Zwahlen, M. (2004) A systematic review of the survival and complication rates of fixed partial dentures (FPDs) after an observation period of at least 5 years. *Clinical Oral Implants Research* **15**, 667-676.
- Prosper, L., Redaelli, S., Pasi, M., Zarone, F., Radaelli, G. & Gherlone, E. F. (2009) A randomized prospective multicenter trial evaluating the platform-switching technique for the prevention of postrestorative crestal bone loss. *International Journal of Oral & Maxillofacial Implants* **24**, 299-308.
- Quirynen, M., Naert, I., van Steenberghe, D., Dekeyser, C. & Callens, A. (1992) Periodontal aspects of osseointegrated fixtures supporting a partial bridge. An up to 6-years retrospective study. *Journal of Clinical Periodontology* **19**, 118-126.
- Rabel, A., Kohler, S. G. & Schmidt-Westhausen, A. M. (2007) Clinical study on the primary stability of two dental implant systems with resonance frequency analysis. *Clinical Oral Investigations* **11**, 257-265.
- Rasmusson, L., Meredith, N., Kahnberg, K. E. & Sennerby, L. (1998) Stability assessments and histology of titanium implants placed simultaneously with autogenous onlay bone in the rabbit tibia. *International Journal of Oral & Maxillofacial Surgery* **27**, 229-235.
- Razavi, T., Palmer, R. M., Davies, J., Wilson, R. & Palmer, P. J. (2010) Accuracy of measuring the cortical bone thickness adjacent to dental implants using cone beam computed tomography. *Clinical Oral Implants Research* **21**, 718-725.

- Reddy, M. S. (1992) Radiographic methods in the evaluation of periodontal therapy. *Journal of Periodontology* **63**, 1078-1084.
- Roberts, J. A., Drage, N. A., Davies, J. & Thomas, D. W. (2009) Effective dose from cone beam CT examinations in dentistry. *Br J Radiol* **82**, 35-40.
- Rocci, A., Martignoni, M., Burgos, P. M., Gottlow, J. & Sennerby, L. (2003) Histology of retrieved immediately and early loaded oxidized implants: light microscopic observations after 5 to 9 months of loading in the posterior mandible. *Clinical Implant Dentistry & Related Research* **5 Suppl 1**, 88-98.
- Rodriguez-Ciurana, X., Vela-Nebot, X., Segala-Torres, M., Calvo-Guirado, J. L., Cambra, J., Mendez-Blanco, V. & Tarnow, D. P. (2009a) The effect of interimplant distance on the height of the interimplant bone crest when using platform-switched implants. *International Journal of Periodontics & Restorative Dentistry* **29**, 141-151.
- Rodriguez-Ciurana, X., Vela-Nebot, X., Segala-Torres, M., Rodado-Alonso, C., Mendez-Blanco, V. & Mata-Bugueroles, M. (2009b) Biomechanical repercussions of bone resorption related to biologic width: a finite element analysis of three implant-abutment configurations. *International Journal of Periodontics & Restorative Dentistry* **29**, 479-487.
- Romanos, G. E. (2004) Surgical and prosthetic concepts for predictable immediate loading of oral implants. *Journal of the California Dental Association* **32**, 991-1001.
- Roos-Jansåker, A. M., Lindahl, C., Renvert, H. & Renvert, S. (2006) Nine- to fourteen-year follow-up of implant treatment. Part II: presence of peri-implant lesions. *Journal of Clinical Periodontology* **33**, 290-295.

- Rosa, G. M., Lucas, G. Q. & Lucas, O. N. (2008) Cigarette smoking and alveolar bone in young adults: A study using digitized radiographs. *Journal of Periodontology* **79**, 232-244.
- Ruttimann, U. E., Webber, R. L. & Schmidt, E. (1986) A robust digital method for film contrast correction in subtraction radiography. *Journal of Periodontal Research* **21**, 486-495.
- Sakakura, C. E., Marcantonio, E., Jr., Wenzel, A. & Scaf, G. (2007) Influence of cyclosporin A on quality of bone around integrated dental implants: a radiographic study in rabbits. *Clinical Oral Implants Research* **18**, 34-39.
- Sakakura, C. E., Neto, R. S., Bellucci, M., Wenzel, A., Scaf, G. & Marcantonio, E. (2008) Influence of homeopathic treatment with comfrey on bone density around titanium implants. A digital subtraction radiography study in rats. *Clinical Oral Implants Research* **19**, 624-628.
- Sakoh, J., Wahlmann, U., Stender, E., Nat, R., Al-Nawas, B. & Wagner, W. (2006) Primary stability of a conical implant and a hybrid, cylindrical screw-type implant in vitro. *International Journal of Oral & Maxillofacial Implants* **21**, 560-566.
- Salonen, M. A., Oikarinen, K., Virtanen, K. & Pernu, H. (1993) Failures in the osseointegration of endosseous implants. *International Journal of Oral & Maxillofacial Implants* **8**, 92-97.
- Schlegel, K. A., Kloss, F. R., Kessler, P., Schultze-Mosgau, S., Nkenke, E. & Wiltfang, J. (2003) Bone conditioning to enhance implant osseointegration: an experimental study in pigs. *International Journal of Oral & Maxillofacial Implants* **18**, 505-511.

- Schnitman, P. A., Wohrle, P. S. & Rubenstein, J. E. (1990) Immediate fixed interim prostheses supported by two-stage threaded implants: methodology and results. *Journal of Oral Implantology* **16**, 96-105.
- Schou, S., Holmstrup, P., Jørgensen, T., Stoltze, K., Hjørting-Hansen, E. & Wenzel, A. (2003) Autogenous bone graft and ePTFE membrane in the treatment of peri-implantitis. I. Clinical and radiographic observations in cynomolgus monkeys. *Clinical Oral Implants Research* **14**, 391-403.
- Schropp, L., Kostopoulos, L., Wenzel, A. & Isidor, F. (2005) Clinical and radiographic performance of delayed-immediate single-tooth implant placement associated with peri-implant bone defects. A 2-year prospective, controlled, randomized follow-up report. *Journal of Clinical Periodontology* **32**, 480-487.
- Schrotenboer, J., Tsao, Y. P., Kinariwala, V. & Wang, H. L. (2008) Effect of microthreads and platform switching on crestal bone stress levels: a finite element analysis. *Journal of Periodontology* **79**, 2166-2172.
- Schulte, W. (1988) The new Periotest method. *Compendium of Continuing Education in Dentistry* **12**, 410-415.
- Schulze, D., Heiland, M., Thurmann, H. & Adam, G. (2004) Radiation exposure during midfacial imaging using 4- and 16-slice computed tomography, cone beam computed tomography systems and conventional radiography. *Dento-Maxillo-Facial Radiology* **33**, 83-86.
- Schulze, R. K. W., Berndt, D. & d'Hoedt, B. (2009) On cone-beam computed tomography artifacts induced by titanium implants. *Clinical Oral Implants Research* **21**, 100-107.

- Sennerby, L. & Meredith, N. (1998) Resonance frequency analysis: measuring implant stability and osseointegration. *Compendium of Continuing Education in Dentistry* **19**, 493-498.
- Sennerby, L., Persson, L. G., Berglundh, T., Wennerberg, A. & Lindhe, J. (2005) Implant stability during initiation and resolution of experimental periimplantitis: An experimental study in the dog. *Clinical Implant Dentistry and Related Research* **7**, 136-140.
- Sennerby, L., Thomsen, P. & Ericson, L. E. (1992) A morphometric and biomechanic comparison of titanium implants inserted in rabbit cortical and cancellous bone. *International Journal of Oral & Maxillofacial Implants* **7**, 62-71.
- Seong, W. J., Conrad, H. J. & Hinrichs, J. E. (2009) Potential damage to bone-implant interface when measuring initial implant stability. *Journal of Periodontology* **80**, 1868-1874.
- Sherrard, J. F., Rossouw, P. E., Benson, B. W., Carrillo, R. & Buschang, P. H. (2010) Accuracy and reliability of tooth and root lengths measured on cone-beam computed tomographs. *American Journal of Orthodontics and Dentofacial Orthopedics* **137**, S100-S108.
- Shin, Y. K., Han, C. H., Heo, S. J., Kim, S. & Chun, H. J. (2006) Radiographic evaluation of marginal bone level around implants with different neck designs after 1 year. *International Journal of Oral & Maxillofacial Implants* **21**, 789-794.
- Sim, C. P. C. & Lang, N. P. (2010) Factors influencing resonance frequency analysis assessed by Osstell™ mentor during implant tissue integration: I. Instrument positioning, bone structure, implant length. *Clinical Oral Implants Research* **21**, 598-604.

- Slade, G. D., Spencer, A. J. & Roberts-Thomson, K. F. (2007) Australia's dental generations: the National Survey of Adult Oral Health 2004–06. pp. 119-120. Canberra: Australian Institute of Health and Welfare.
- Smith, D. E. & Zarb, G. A. (1989) Criteria for success of osseointegrated endosseous implants. *The Journal of Prosthetic Dentistry* **62**, 567-572.
- Soballe, K., Brockstedt-Rasmussen, H., Hansen, E. S. & Bunger, C. (1992a) Hydroxyapatite coating modifies implant membrane formation. Controlled micromotion studied in dogs. *Acta Orthopaedica Scandinavica* **63**, 128-140.
- Soballe, K., Hansen, E. S., H, B. R., Jorgensen, P. H. & Bunger, C. (1992b) Tissue ingrowth into titanium and hydroxyapatite-coated implants during stable and unstable mechanical conditions. *Journal of Orthopaedic Research* **10**, 285-299.
- Stavropoulos, A. & Wenzel, A. (2007) Accuracy of cone beam dental CT, intraoral digital and conventional film radiography for the detection of periapical lesions. An ex vivo study in pig jaws. *Clinical Oral Investigations* **11**, 101-106.
- Steffensen, B., Pasquali, L. A., Yuan, C., Wood, R. C., Schoolfield, J. D. & Kornman, K. S. (1989) Correction of density changes caused by methodological errors in CADIA. *Journal of Periodontal Research* **24**, 402-408.
- Stratemann, S. A., Huang, J. C., Maki, K., Miller, A. J. & Hatcher, D. C. (2008) Comparison of cone beam computed tomography imaging with physical measures. *Dento-Maxillo-Facial Radiology* **37**, 80-93.
- Strietzel, F. P., Nowak, M., Kuchler, I. & Friedmann, A. (2002) Peri-implant alveolar bone loss with respect to bone quality after use of the osteotome technique: results of a retrospective study. *Clinical Oral Implants Research* **13**, 508-513.

- Sullivan, D. Y., Sherwood, R. L., Collins, T. A. & Krogh, P. H. (1996) The reverse-torque test: a clinical report. *International Journal of Oral & Maxillofacial Implants* **11**, 179-185.
- Summers, R. B. (1994) A new concept in maxillary implant surgery: the osteotome technique. *Compendium* **15**, 152.
- Szmukler-Moncler, S., Salama, H., Reingewirtz, Y. & Dubruille, J. H. (1998) Timing of loading and effect of micromotion on bone-dental implant interface: review of experimental literature. *Journal of Biomedical Materials Research* **43**, 192-203.
- Tabassum, A., Meijer, G. J., Wolke, J. G. & Jansen, J. A. (2009) Influence of the surgical technique and surface roughness on the primary stability of an implant in artificial bone with a density equivalent to maxillary bone: a laboratory study. *Clinical Oral Implants Research* **20**, 327-332.
- Tarnow, D. P., Emtiaz, S. & Classi, A. (1997) Immediate loading of threaded implants at stage 1 surgery in edentulous arches: ten consecutive case reports with 1- to 5-year data. *International Journal of Oral & Maxillofacial Implants* **12**, 319-324.
- Teerlinck, J., Quirynen, M., Darius, P. & van Steenberghe, D. (1991) Periotest: an objective clinical diagnosis of bone apposition toward implants. *International Journal of Oral & Maxillofacial Implants* **6**, 55-61.
- Terakado, M., Hashimoto, K., Arai, Y., Honda, M., Sekiwa, T. & Sato, H. (2000) Diagnostic imaging with newly developed ortho cubic super-high resolution computed tomography (Ortho-CT). *Oral Surgery Oral Medicine Oral Pathology Oral Radiology & Endodontics* **89**, 509-518.

- Thompson, W. D. & Walter, S. D. (1988) A reappraisal of the kappa coefficient. *Journal of Clinical Epidemiology* **41**, 949-958.
- Toback, G. A., Brunsvold, M. A., Nummikoski, P. V., Masters, L. B., Mellonig, J. T. & Cochran, D. L. (1999) The accuracy of radiographic methods in assessing the outcome of periodontal regenerative therapy. *Journal of Periodontology* **70**, 1479-1489.
- Todescan, F. F., Pustiglioni, F. E., Imbronito, A. V., Albrektsson, T. & Gioso, M. (2002) Influence of the microgap in the peri-implant hard and soft tissues: a histomorphometric study in dogs. *International Journal of Oral & Maxillofacial Implants* **17**, 467-472.
- Tolstunov, L. (2006) Dental implant success-failure analysis: a concept of implant vulnerability. *Implant Dentistry* **15**, 341-346.
- Tricio, J., Laohapand, P., van Steenberghe, D., Quirynen, M. & Naert, I. (1995) Mechanical state assessment of the implant-bone continuum: a better understanding of the Periotest method. *International Journal of Oral & Maxillofacial Implants* **10**, 43-49.
- Trisi, P., Perfetti, G., Baldoni, E., Berardi, D., Colagiovanni, M. & Scogna, G. (2009) Implant micromotion is related to peak insertion torque and bone density. *Clinical Oral Implants Research* **20**, 467-471.
- Truhlar, R. S., Orenstein, I. H., Morris, H. F. & Ochi, S. (1997) Distribution of bone quality in patients receiving endosseous dental implants. *Journal of Oral & Maxillofacial Surgery* **55**, 38-45.
- Turkylmaz, I., Avci, M., Kuran, S. & Ozbek, E. N. (2007) A 4-year prospective clinical and radiological study of maxillary dental implants supporting single-

- tooth crowns using early and delayed loading protocols. *Clinical Implant Dentistry and Related Research* **9**, 222-227.
- van Steenberghe, D., Jacobs, R., Desnyder, M., Maffei, G. & Quirynen, M. (2002) The relative impact of local and endogenous patient-related factors on implant failure up to the abutment stage. *Clinical Oral Implants Research* **13**, 617-622.
- Van Steenberghe, D., Quirynen, M. & Naert, I. (1999) Survival and success rates with oral endosseous implants. *Proceedings of the Third European Workshop in Periodontology*, 242-254.
- van Steenberghe, D., Tricio, J., Naert, I. & Nys, M. (1995) Damping characteristics of bone-to-implant interface; A clinical study with the Periotest device. *Clinical Oral Implants Research* **6**, 31-39.
- Vandamme, K., Naert, I., Geris, L., Vander Sloten, J., Puers, R. & Duyck, J. (2007) Influence of controlled immediate loading and implant design on peri-implant bone formation. *Journal of Clinical Periodontology* **34**, 172-181.
- Vela-Nebot, X., Rodriguez-Ciurana, X., Rodado-Alonso, C. & Segala-Torres, M. (2006) Benefits of an implant platform modification technique to reduce crestal bone resorption. *Implant Dentistry* **15**, 313-320.
- Vigolo, P. & Givani, A. (2009) Platform-switched restorations on wide-diameter implants: a 5-year clinical prospective study. *International Journal of Oral & Maxillofacial Implants* **24**, 103-109.
- Wagenberg, B. & Froum, S. J. (2010) Prospective study of 94 platform-switched implants observed from 1992 to 2006. *International Journal of Periodontics & Restorative Dentistry* **30**, 9-17.
- Wakoh, M., Nishikawa, K., Otonari, T., Yamamoto, M., Harada, T., Sano, T., Yajima, Y. & Ooguro, T. (2006) Digital subtraction technique for evaluation of peri-

- implant bone change in digital dental imaging. *Bulletin of Tokyo Dental College* **47**, 57-64.
- Wang, D., Nagata, M. J., Bell, M., de Melo, L. G. & Bosco, A. F. (2010) Influence of microgap location and configuration on peri-implant bone morphology in nonsubmerged implants: an experimental study in dogs. *International Journal of Oral & Maxillofacial Implants* **25**, 540-547.
- Webber, R. L., Ruttimann, U. E. & Heaven, T. J. (1990) Calibration errors in digital subtraction radiography. *Journal of Periodontal Research* **25**, 268-275.
- Weber, H.-P., Crohin, C. C. & Fiorellini, J. P. (2000) A 5-year prospective clinical and radiographic study of non-submerged dental implants. *Clinical Oral Implants Research* **11**, 144-153.
- Weber, H. P., Buser, D., Fiorellini, J. P. & Williams, R. C. (1992) Radiographic evaluation of crestal bone levels adjacent to nonsubmerged titanium implants. *Clinical Oral Implants Research* **3**, 181-188.
- Weng, D., Nagata, M. J., Bell, M., Bosco, A. F., de Melo, L. G. & Richter, E. J. (2008) Influence of microgap location and configuration on the periimplant bone morphology in submerged implants. An experimental study in dogs. *Clinical Oral Implants Research* **19**, 1141-1147.
- Wennerberg, A., Albrektsson, T., Johansson, C. & Andersson, B. (1996) Experimental study of turned and grit-blasted screw-shaped implants with special emphasis on effects of blasting material and surface topography. *Biomaterials* **17**, 15-22.
- Wenzel, A., Warrer, K. & Karring, T. (1992) Digital subtraction radiography in assessing bone changes in periodontal defects following guided tissue regeneration. *Journal of Clinical Periodontology* **19**, 208-213.

- Winter, W., Mohrle, S., Holst, S. & Karl, M. (2010) Parameters of implant stability measurements based on resonance frequency and damping capacity: A comparative finite element analysis. *International Journal of Oral & Maxillofacial Implants* **25**, 532-539.
- Woo, B. M. S., Zee, K. Y., Chan, F. H. Y. & Corbet, E. F. (2003) In vitro calibration and validation of a digital subtraction radiography system using scanned images. *Journal of Clinical Periodontology* **30**, 114-118.
- Wrixon, A. D. (2008) New ICRP recommendations. *Journal of Radiological Protection* **28**, 161-168.
- Xiropaidis, A. V., Qahash, M., Lim, W. H., Shanaman, R. H., Rohrer, M. D., Wikesjo, U. M. E. & Hall, J. (2005) Bone-implant contact at calcium phosphate-coated and porous titanium oxide (TiUnite)-modified oral implants. *Clinical Oral Implants Research* **16**, 532-539.
- Zhang, Y., Zhang, L., Zhu, X. R., Lee, A. K., Chambers, M. & Dong, L. (2007) Reducing metal artifacts in cone-beam CT images by preprocessing projection data. *International Journal of Radiation Oncology Biology Physics* **67**, 924-932.