

UDC 616.53-008-031.84

<https://doi.org/10.26641/2307-0404.2021.1.228005>**I.V. Odintsova,
A.D. Diudiun****THE USE OF EXTEMPORAL DOSAGE
FORM WITH PYROCTONE OLAMINE
IN THE COMPLEX TREATMENT OF PATIENTS
WITH SEBORRHEIC DERMATITIS**

SE «Dnipropetrovsk medical academy of Health Ministry of Ukraine»
Department of Skin and Venereal Diseases
V. Vernadsky str., 9, Dnipro, 49044, Ukraine
ДЗ «Дніпропетровська медична академія МОЗ України»
Кафедра шкірних та венеричних хвороб
(зав. – д.м.н. проф. А.Д. Дюдюн)
e-mail: inna_setrine@ukr.net

Цитування: Медичні перспективи. 2021. Т. 26, № 1. С. 191-196
Cited: Medicni perspektivi. 2021;26(1):191-196

Key words: seborrheic dermatitis, *Malassezia* spp., Complex treatment, pyrocton olamine
Ключові слова: себорейний дерматит, *Malassezia* spp., комплексне лікування, піроктон оламін
Ключевые слова: себорейный дерматит, *Malassezia* spp., комплексное лечение, пироктон оламин

Abstract. The use of extemporal dosage form with pyroctone olamine in the complex treatment of patients with seborrheic dermatitis. Odintsova I.V., Diudiun A.D. The purpose of the work is to evaluate the efficacy and tolerance of extemporal dosage form with pyroctone olamine in the local treatment of patients with seborrheic dermatitis. Under our supervision there were 78 patients with seborrheic dermatitis aged 18 to 57 years. The average age of the patients was 29.5 ± 2.1 years. Comprehensive treatment of patients with seborrheic dermatitis in both groups depended on the severity of clinical manifestations, the duration of the disease, and information on the effectiveness of previous therapy. For external treatment of the main group of patients with seborrheic dermatitis, an extemporaneously prepared gel with pyrocton olamine was used. Local treatment of patients in the comparison group consisted of the appointment of 1% cream of clotrimazole. An analysis of the results shows good therapeutic, microbiological effectiveness and good tolerance of extemporaneously prepared gel with pyrocton olamine in the complex treatment of patients with seborrheic dermatitis. The period for resolving the clinical manifestations of seborrheic dermatitis among patients in the main group was 2.5 ± 0.1 days shorter compared with patients in the comparison group. The intensity of clinical manifestations in patients with seborrheic dermatitis of the main group decreased twice on the second day of complex treatment. In control patients with comparative seborrheic dermatitis, similar therapeutic efficacy was achieved on the fourth to fifth day. Long-term results of the study showed that the recurrence of the disease among patients of the main group was 5 (6.4%), and in patients of in the comparison group was 14 (17.9%). Clinical studies have shown good therapeutic efficacy and tolerance of the extemporal gel with pyroctone olamine in the complex treatment of patients with seborrheic dermatitis, which gives reason to recommend this dosage form for wider use in the practice of dermatovenerologists.

Реферат. Застосування екстемпоральної лікарської форми з піроктон оламіном у комплексному лікуванні хворих на себорейний дерматит. Одінцова І.В., Дюдюн А.Д. Мета роботи - дати оцінку ефективності та переносимості екстемпоральної лікарської форми з піроктон оламіном для місцевого лікування хворих на себорейний дерматит. Під нашим спостереженням знаходилися 78 хворих на себорейний дерматит у віці від 18 до 57 років. Середній вік пацієнтів становив $29,5 \pm 2,1$ року. Комплексне лікування хворих на себорейний дерматит обох груп залежало від ступеня прояву клінічних симптомів, тривалості захворювання і відомостей про ефективність раніше проведеної терапії. Для зовнішнього лікування основної групи хворих на себорейний дерматит застосовували екстемпорально приготований гель з піроктон оламіном. Місцеве лікування хворих групи порівняння складалося з призначення 1% крему клотримазол. Аналіз отриманих результатів показує хорошу терапевтичну, мікробіологічну ефективність і хорошу переносимість екстемпорально приготованого гелю з піроктон оламіном у комплексному лікуванні хворих на себорейний дерматит. Період розрешення клінічних проявів себорейного дерматиту серед хворих основної групи був на $2,5 \pm 0,1$ дня коротше порівняно з хворими групи порівняння. Інтенсивність клінічних проявів у хворих на себорейний дерматит основної групи знизилась у два рази вже на другий день комплексного лікування. У хворих на себорейний дерматит порівняльної групи досягти подібної терапевтичної ефективності вдалося на четвертий та п'ятий день. Віддалені результати проведеного дослідження показали, що рецидив захворювання серед хворих основної групи виник у 5 (6,4%), а серед пацієнтів групи порівняння – 14 (17,9%) пацієнтів.

Висновки. Клінічне дослідження показало хорошу терапевтичну ефективність і переносимість екстемпорального гелю з піроктон оламіном у комплексному лікуванні хворих на себорейний дерматит, що дає підставу рекомендувати цю лікарську форму для більш широкого застосування в практиці лікарів-дерматовенерологів.

Seborrheic dermatitis is one of the most common chronic inflammatory diseases, accompanied by a change in the quantitative and qualitative sebum composition, which contributes to the impairment of microbial landscape of skin and activity of saprophytic microorganisms. In seborrheic dermatitis the pathological process in the form of erythematous-squamous rashes is localized on hairy part of the scalp and trunk which anatomically have a large number of sebaceous glands. The most frequent localization of the pathological process is the scalp, nasolabial folds, eyebrows, as well as skin of the chest and back. The seborrheic dermatitis incidence ranges from 1 to 3% of the total population and is diagnosed in more than 10% of dermatological patients [1, 6, 8, 14].

Clinical manifestations of seborrheic dermatitis are the appearance of well-defined erythematous-squamous rashes mainly on the scalp, often accompanied by various subjective sensations. With the disease progression, the pathological process covers the entire hairy part to the border with smooth skin [1, 4, 5, 12].

The cause and development mechanisms of seborrheic dermatitis are multifaceted and not completely studied. In modern literature, such mechanisms of occurrence and development of seborrheic dermatitis as genetic predisposition, the role of microbial agents, immune and endocrine disorders, pathological conditions of autonomic nervous system, gastrointestinal tract pathology, lipid metabolism disorders etc. are presented [1, 5, 7, 13].

One of the main pathogenetic mechanisms of seborrheic dermatitis is the *Malassezia* activation with the formation of complex microbial associations. *Malassezia* is a formation leader of fungi and microorganisms associations in the lesions with seborrheic dermatitis. *Malassezia*, in association with other bacteria, acquires an increased intrinsic virulence, which contributes to the increased virulence of other microorganisms. Formed fungi and microorganisms associations lead to an inflammatory process with the formation of various clinical manifestations of seborrheic dermatitis. The activation of opportunistic pathogenic microorganisms on the skin in seborrheic dermatitis is evidenced by the higher contamination frequency of the affected scalp areas with *S. capitis*, *Micrococcus* spp., *Acinetobacter* spp. etc. [6, 8, 9, 10].

Therefore, local treatment of seborrheic dermatitis should be directed to the use of dosage forms with antifungal and anti-inflammatory properties.

Complex treatment of seborrheic dermatitis should be aimed at eliminating disease signs, eliminating concomitant symptoms, especially patient's subjective feelings and maintaining long-term remission [4, 8, 11].

In this work, we set the following purpose: to evaluate the efficacy and tolerance of an extemporal dosage form with pyroctone olamine for the local treatment of patients with seborrheic dermatitis.

MATERIALS AND METHODS OF RESEARCH

Under our supervision there were 78 patients with seborrheic dermatitis aged 18 to 57 years. The average age of the patients was 29.5 years. Among the examined patients with seborrheic dermatitis, there were 53 men (67.9%), 25 women (32.1%).

The pathological process was localized only on hairy part of the scalp in 43 (55.1%) patients observed, and in 35 (44.9%) patients seborrheic process also spread to other skin areas. The duration of the disease ranged from 1 to 15 years.

All patients with seborrheic dermatitis, who were under our supervision, underwent the following examination methods: carefully collected disease anamnesis with taking into account patient's subjective feelings, skin examination, general and biochemical blood tests, general urinalysis [4].

The material for microscopic and bacteriological methods of the study were swabbings from the affected areas of the skin of patients with seborrheic dermatitis.

Patients were consulted by doctors of related specialties with the implementation of advisory recommendations.

The patients were divided into two similar groups – the main and the control.

The complex treatment of patients with seborrheic dermatitis in both groups depended on the severity of clinical manifestations, the disease duration, and information about the effectiveness of previous therapy. Antihistamines were prescribed for severe itching.

Local treatment in the comparison group consisted of the appointment of 1% clotrimazole cream.

For external treatment of the main group patients with seborrheic dermatitis, an extemporaneously prepared gel was used. The gel contains: pyroctone olamine (octopyrox) 1.0; demineralized naftalan 5.0; sodium carboxymethyl cellulose 3.0; glycerol 10.0; propylene glycol 20.0; tween 80 2.0; water (purified) up to 100.0 [8].

The analysis of the data received was carried out with application of the program product Statistica 6.1. (StatSoftInc., serial NAGAR909E415822FA). The difference in indices with $p < 0.05$ considered as probable one. To identify the relationships between the indices, Friedman's nonparametric variance analysis with the definition of χ^2 was used. The coupling between indices was considered significant if χ^2 value exceeded the critical one ($\chi^2 = 3.84$) [2, 3].

RESULTS AND DISCUSSION

Among the examined patients with seborrheic dermatitis, in 45 (57.7%) patients oily seborrhea was revealed.

A mixed form of seborrheic dermatitis was revealed in 23 (29.5%) patients. It manifested itself in a moderate sebum secretion increase on the face and skin of the trunk with the appearance of separate comedones and acne-like rashes.

The dry form of seborrheic dermatitis was in 10 (12.8%) patients under our supervision. A dry form of seborrheic dermatitis was characterized by a sebum secretion decrease and the presence of scales of a different size and number. Most often, the pathological condition was developed in the occipital-temporal area, then it spread to the entire scalp surface. In our opinion, the low frequency of dry form of seborrheic dermatitis is due to the fact that patients with an insignificant clinical manifestation of the disease very rarely seek specialized medical care.

In most of the patients observed, a combination of several factors was established, such as the presence of foci of chronic infection, hormonal disorders (especially changes in the physiological balance of estrogens and androgens), vegetative-dystonic dysfunction, changes in the enzymatic activity of the organs of the gastrointestinal tract and liver, this creates conditions for which the body loses the ability to control the reproduction of yeast-like fungi and their virulence.

Seborrheic dermatitis most often begins during puberty. Dermatitis had a long course with frequent relapses, mainly in the autumn-winter period and was associated with the diet disorder. The duration of the dermatosis course in 29 cases (37.2%) was up to 6 years. In 49 (62.8%) patients observed, the seborrheic dermatitis course was more than 6 years. The disease occurrence in 45 (57.7%) patients was associated with the onset of puberty. We could not indicate the cause of dermatosis in 33 (42.3%) patients. The patients described the disease occurrence as an increased skin oiliness and the periodic appearance of inflammatory elements in the seborrheic zones. The exacerbation of the pathological process was associated with the cold season as well as non-compliance with the diet or with the

nutrition peculiarities. A small amount of women observed associated the first manifestations of seborrheic dermatitis with the menstrual cycle formation.

Bacteriological and microscopic examination of the sampling material from the affected skin areas of seborrheic dermatitis patients revealed *Malassezia* spp. in 69 cases (88.5%).

The highest density of yeast-like fungi was on the skin in areas rich in sebaceous glands. These include the scalp, face, periauricular area, central areas of chest and back, genital area. *Malassezia* fungi prefer to colonize these areas due to their lipophilic properties. The *Malassezia furfur* species is unable to synthesize lipids, it needs an exogenous source of fatty acids, which are important both as an energy source and for metabolic processes, in particular membrane synthesis. The presence of saturated and unsaturated free fatty acids is necessary for the yeast-like *Malassezia* fungi full functioning. The main source of lipids for *Malassezia* spp. on human skin are triglycerides and free fatty acids produced by the sebaceous glands as well as cholesterol and cholesterol esters obtained in the process of keratinization and corneocytes destruction.

Among the causal mechanisms for the development of seborrheic dermatitis, an important role is played by the reproduction of opportunistic microorganisms against the background of an altered normal microbial biocenosis of the skin.

Among other microorganisms that were identified during the examination of our patients, one should point out: *St. Capitis* at 54 (79.5%), *St. Epidermidis* – 42 (53.8%), *Micrococcus* spp. 23 (29.5%), *Acinetobacter* spp. 12 (15.4%). *St. Aureus*, *St. Capitis*, *St. Hominis*, *St. cohnii*, *St. Xylosus* in the affected areas were found less (Fig. 1).

The complex treatment of most of the patients we observed was well tolerated. Adverse reactions were observed only in three patients with seborrheic dermatitis. Thus, two patients after applying 1% clotrimazole cream and one more after applying extemporal gel complained of the appearance of feeling of constriction and insignificant subjective sensations (of an indefinite nature) at the site of application of the local dosage form. The adverse reaction was unstable and resolved within 15-20 minutes without prescribing additional treatment. In the course of the treatment, there was a positive trend in the development of the pathological condition. However, a more pronounced therapeutic effect was found with the prescribing of an extemporal gel. Among the patients of the main group, the period of clinical manifestations resolution was by 2.5 ± 0.1 days shorter than in the patients of the comparison group.

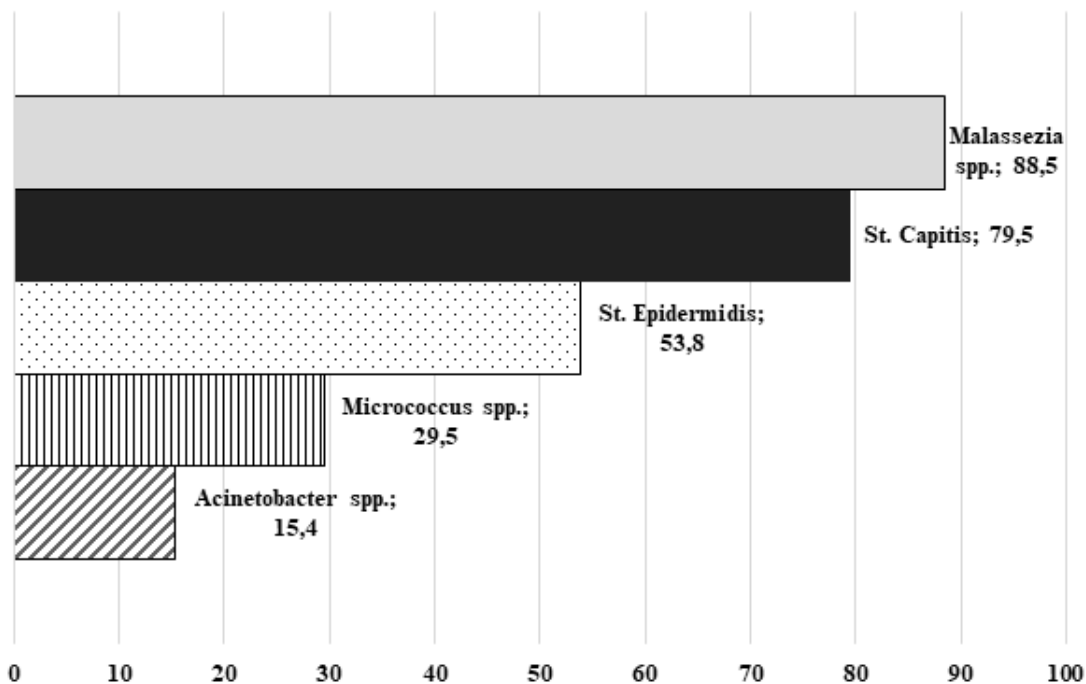


Fig. 1. The frequency of detecting microorganisms in microbiological examinations (%)

Microscopic and bacteriological detection of *Malassezia* spp. from the affected skin areas of seborrheic dermatitis patients after local treatment was higher among patients of the comparison group. Thus, *Malassezia* spp. was found in 2 (5.1%) patients of the main and 9 (23.1%) of the control group. After the therapy of the affected skin areas,

other microorganisms were detected in 12 (15.4%) patients of the comparison and in 3 (3.9%) patients of the main group.

Long-term results of the study have shown that the disease recurrence among patients of the main group was in 5 cases (6.4%), among patients in the comparison group – in 14 (17.9%) (Fig. 2).

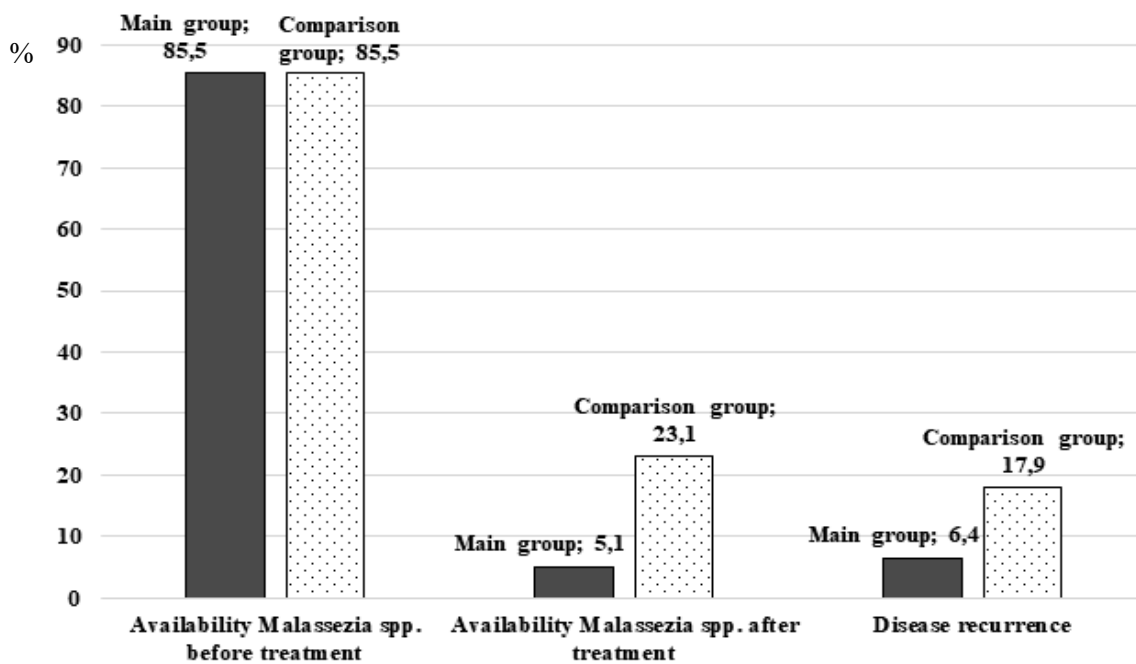


Fig. 2. Results of complex treatment of patients with seborrheic dermatitis (%)

Thus, the ongoing clinical study on the efficacy and tolerance of the extemporal gel for the local treatment of patients with seborrheic dermatitis has shown a good therapeutic effect, along with a good tolerance, in the complex treatment of the observed patients.

CONCLUSIONS

Considering a good therapeutic efficacy and tolerance of the extemporal gel with pyroctone olamine

in the complex treatment of patients with seborrheic dermatitis gives a good reason to recommend this dosage form for wider use in the practice of dermatovenerologists.

Conflict of interests. The authors declare no conflict of interest.

REFERENCES

1. Albanova VI, Kalinina OV. [Seborrhea dermatitis of the scalp: the role of Malassezia]. *Advances in medical mycology*. 2016;14:11-14. Russian.
2. Antomonov MYu. [Mathematical processing and analysis of biomedical data]. 2017. p. 578 Russian.
3. Ivchenko GI, Medvedev YuI. [Introduction to Mathematical Statistics. "Statistics knows everything"]. URSS. 2017. p. 608. ISBN 978-5-9710-4535-9. Russian.
4. Kamyshnikov VS. [Clinical laboratory research methods]. MEDpress-inform; Kyiv. 2020;736:210. Russian.
5. Narozhna MV. [Rozladi intestinal microflora in patients with seborrheic dermatitis]. *Dermatovenerology. Cosmetology. Sexopathology* 2016;1-4:246-51. Ukrainian.
6. Odintsova IV, Dyudyun AD, Gladyshev VV, Polion NM. [Seborrheic dermatitis i Malassezia spp]. *Dermatology and Venereology* 2019;3:31-33. Ukrainian. doi: <https://doi.org/10.33743/2308-1066-2019-3-31-33>
7. Olisova OYu. [Pathogenesis and treatment of seborrheic dermatitis]. *Dermatovenerology and dermatocosmetology*. 2016;1-2:38-42. Russian. Available from: <https://www.umedp.ru/upload/iblock/97c/kelual.pdf>.
8. Solodovnik SA, Gladyshev VV, Dyudyun AD, Lisyanskaya AP. [Preparation of ointments for rapid absorption of piroctone olamine with speech in the mind of a pharmacy. Information sheet]. 2019;210. Kyiv. Russian.
9. Sanders MGH, Pardo LM, Ginger RS, Kiefte-de Jong JC, Nijsten T. Association between diet and seborrheic dermatitis: A cross-sectional study. *J Invest Dermatol*. 2019;139:108-14. doi: <https://doi.org/10.1016/j.jid.2018.07.027>
10. Clark GW, Pope SM, Jaboori KA. Diagnosis and treatment of seborrheic dermatitis. *Am Fam Physician*. 2015;91:185-90. Available from: <https://www.aafp.org/afp/2015/0201/p185.html>
11. De Souza Leao Kamamoto C, Sanudo A, Hasun KM, Bagatin E. Low dose oral isotretinoin for moderate to severe seborrhea and Seborrheic dermatitis: a randomized comparative. trial. *Int J Dermatol* 2017;56:80-85. doi: <https://doi.org/10.1111/ijd.13408>
12. Mameri ACA, Carneiro S, Mameri LMA, Telles da Cunha JM, Ramos-E-Silva M. History of seborrheic dermatitis: conceptual and clinico-pathologic evolution. *Skinmed*. 2017;15:187-94.
13. Karakadze MA, Hirt PA, Wikramanayake TC. The genetic basis of seborrheic dermatitis: a review. *J Eur Acad Dermatol Venereol*. 2018;32:529-36. doi: <https://doi.org/10.1111/jdv.14704>
14. Moreno-Vázquez K, Calderón L, Bonifaz A. *Dermatitis seborreica. Actualización Dermatol Rev Mex*. 2020;64(1):39-49. Available from: <https://www.mediagraphic.com/pdfs/derrevmex/rmd-2020/rmd201f.pdf>.

СПИСОК ЛІТЕРАТУРИ

1. Альбанова В. И., Калинина О. В. Себорейный дерматит волосистой части головы: роль Malassezia. *Успехи медицинской микологии*. 2016. № 14. С. 11-14.
2. Антомонов М. Ю. Математическая обработка и анализ биомедицинских данных, 2017. 578 с.
3. Ивченко Г. И., Медведев Ю. И. Введение в математическую статистику. *Статистика знает все УРСС*. 2017. 608 с. ISBN 978-5-9710-4535-9.
4. Камышников В. С. Клинические лабораторные методы исследования. Киев: МЕДпресс-информ, 2020. 736 с.
5. Нарожна М. В. Розлади мікрофлори кишечника у больных себорейним дерматитом. *Дерматовенерология. Косметология. Сексопатология* 2016. № 1-4. С. 246-251.
6. Одинцова И. В., Дюдюна А. Д., Гладышев В. В., Полион Н. М. Себорейный дерматит b Malassezia spp. *Дерматология и венерология*. 2019. №3. С. 31-33. DOI: <https://doi.org/10.33743/2308-1066-2019-3-31-33>
7. Олисова О. Ю. Патогенез и лечение себорейного дерматита. *Дерматовенерология и дерматокосметология* 2016. № 1-2. С. 38-42. URL: <https://www.umedp.ru/upload/iblock/97c/kelual.pdf>
8. Солодовник С. А., Гладышев В. В., Дюдюна А. Д., Лисянська А. П. Приготування мазей для швидкого проникнення із діючою речовиною піроктонного оламіна в умовах аптеки. *Інф. лист № 210*. Київ. 2019.
9. Association between diet and seborrheic dermatitis: A cross-sectional study / M. G. H. Sanders et al. *J Invest Dermatol*. 2019. Vol. 139. P. 108-114. DOI: <https://doi.org/10.1016/j.jid.2018.07.027>
10. Clark G. W., Pope S. M., Jaboori K. A. Diagnosis and treatment of seborrheic dermatitis. *Am*

Fam Physician. 2015. Vol. 91. P. 185-190.
URL: <https://www.aafp.org/afp/2015/0201/p185.html>

11. De Souza Leao Kamamoto C., Sanudo A., Hassun K. M., Bagatin E. Low dose oral isotretinoin for moderate to severe seborrhea and Seborrheic dermatitis: a randomized comparative. trial. *Int J Dermatol.* 2017. Vol. 56. P. 80-85. DOI: <https://doi.org/10.1111/ijd.13408>

12. History of seborrheic dermatitis: conceptual and clinico-pathologic evolution / A. C. A. Mameri et al. *Skinmed.* 2017. Vol. 15. P. 187-194.

13. Karakadze M. A., Hirt P. A., Wikramanayake T. C. The genetic basis of seborrheic dermatitis: a review. *J Eur Acad Dermatol Venereol.* 2018. Vol. 32. P. 529-36. DOI: <https://doi.org/10.1111/jdv.14704>

14. Moreno-Vázquez K., Calderón L., Bonifaz A. Dermatitis seborreica. *Actualización Dermatol Rev Mex.* 2020. enero-febrero. (Vol. 64, No. 1). P. 39-49. URL: <https://www.medigraphic.com/pdfs/derrevmex/rmd-2020/rmd201f.pdf>.

Стаття надійшла до редакції
23.09.2020

