



Aalborg Universitet

AALBORG UNIVERSITY  
DENMARK

## A novel case of neonatal severe hyperparathyroidism successfully treated with a type II calcimimetic drug

Leunbach, T. L.; Hansen, A. T.; Madsen, M.; Cipliene, R.; Christensen, P. S.; Schou, A. J.

*Published in:*  
Bone Reports

*DOI (link to publication from Publisher):*  
[10.1016/j.bonr.2021.100761](https://doi.org/10.1016/j.bonr.2021.100761)

*Creative Commons License*  
CC BY-NC-ND 4.0

*Publication date:*  
2021

*Document Version*  
Publisher's PDF, also known as Version of record

[Link to publication from Aalborg University](#)

*Citation for published version (APA):*

Leunbach, T. L., Hansen, A. T., Madsen, M., Cipliene, R., Christensen, P. S., & Schou, A. J. (2021). A novel case of neonatal severe hyperparathyroidism successfully treated with a type II calcimimetic drug. *Bone Reports*, 14, [100761]. <https://doi.org/10.1016/j.bonr.2021.100761>

### General rights

Copyright and moral rights for the publications made accessible in the public portal are retained by the authors and/or other copyright owners and it is a condition of accessing publications that users recognise and abide by the legal requirements associated with these rights.

- ? Users may download and print one copy of any publication from the public portal for the purpose of private study or research.
- ? You may not further distribute the material or use it for any profit-making activity or commercial gain
- ? You may freely distribute the URL identifying the publication in the public portal ?

### Take down policy

If you believe that this document breaches copyright please contact us at [vbn@aub.aau.dk](mailto:vbn@aub.aau.dk) providing details, and we will remove access to the work immediately and investigate your claim.



## Case Report

# A novel case of neonatal severe hyperparathyroidism successfully treated with a type II calcimimetic drug

T.L. Leunbach<sup>a,b,\*</sup>, A.T. Hansen<sup>c</sup>, M. Madsen<sup>a</sup>, R. Cipliene<sup>a</sup>, P.S. Christensen<sup>a</sup>, A.J. Schou<sup>b,d</sup>

<sup>a</sup> Department of Pediatrics, Aalborg University Hospital, Reberbansgade 15, 9000 Aalborg, Denmark

<sup>b</sup> H.C. Andersen Children's Hospital, Odense University Hospital, Sdr. Boulevard 29, 5000 Odense, Denmark

<sup>c</sup> Department of Clinical Biochemistry, Aalborg University Hospital, Reberbansgade 15, 9000 Aalborg, Denmark

<sup>d</sup> Steno Diabetes Center Odense, Odense University Hospital, Sdr. Boulevard 29, 5000 Odense, Denmark



## ARTICLE INFO

## Keywords:

Neonatal severe hyperparathyroidism  
Symptomatic hypercalcemia  
Compound heterozygosity  
Type II calcimimetics

## ABSTRACT

We report a boy with hypercalcemia due to neonatal severe hyperparathyroidism (NSHPT) caused by a compound heterozygous mutation in the calcium sensing receptor (CaSR) managed successfully on a type II calcimimetic drug. The hypercalcemia was temporarily treated by hyperhydration, bisphosphonate and calcium depleted milk. At 29 days of age cinacalcet was introduced. The starting dose was 0.5 mg/kg/day and was subsequently titrated to the point of efficacy (5.2 mg/kg/day) when a persuasive reduction in parathyroid hormone and calcium concentrations was observed. We propose a trial of type II calcimimetics in newborns with NSHPT irrespective of the genetic mutation and advocate that residual functionality of the CaSR predict the drug efficacy.

## 1. Background

Neonatal severe hyperparathyroidism (NSHPT) is a rare autosomal recessive disease caused by homozygous or compound heterozygous inactivating mutations in the calcium sensing receptor (CaSR) gene located at chromosome 3q21.1 (Hannan et al., 2016). More than 25 CaSR mutations have been associated with NSHPT (Hannan et al., 2016). The CaSR gene encodes a 1078-amino acid plasma membrane G-protein-coupled receptor with seven transmembrane domains, that is mainly expressed in the parathyroid glands, the kidneys and bone (Allgrove, 2015). Many inactivating CaSR mutations cluster in the extracellular calcium-binding domain of the protein (Hannan et al., 2012) causing a higher set point for sensing of extracellular calcium plasma levels and regulation of parathyroid hormone (PTH) secreted from the parathyroid glands (Hannan et al., 2016).

Patients with NSHPT typically present in the neonatal period with nausea, failure to thrive, lethargy and poor muscle tone accompanied with considerable elevation of total calcium levels between 5 and 8 mmol/L (Glaudo et al., 2016). The symptomatic hypercalcemia is associated with clinical features of osteopenia, fractures and resultant

respiratory distress (Stokes et al., 2017). If left untreated the condition may cause developmental delay or at worst be fatal (Hannan et al., 2016; Stokes et al., 2017). Acute management aims at controlling the severe hypercalcemia with hyperhydration, diuretics, bisphosphonates, and calcium depleted milk (Hannan et al., 2018). The duration of these medical strategies is short term, lasting up to 2–3 weeks (Murphy et al., 2016; Sun et al., 2018).

Previously, parathyroidectomy has been practiced to obtain a long-lasting effect in patients with NSHPT as treatment with cinacalcet has been ineffective (Murphy et al., 2016; Garcia Soblechero et al., 2013; Atay et al., 2014; Capozza et al., 2018; Ahmad et al., 2017; Savas-Erdeve et al., 2016) except in two cases (Sun et al., 2018; Gulcan-Kersin et al., 2020). Cinacalcet has, however, been effective in curtailing symptomatic hypercalcemia at lower calcium concentrations (2.8–3.2 mmol/L) as seen in neonatal hyperparathyroidism (NHPT) caused by heterozygous CaSR mutations (Glaudo et al., 2016; Fisher et al., 2015; Reh et al., 2011; Forman et al., 2019; Gannon et al., 2014). Cinacalcet is a type II calcimimetic drug that induces a conformational change in the CaSR making it more sensitive to calcium and also enhance mutant receptor biosynthesis and expression leading to suppression of PTH levels and increased

**Abbreviations:** NSHPT, neonatal severe hyperparathyroidism; CaSR, calcium sensing receptor; PTH, parathyroid hormone; NHPT, neonatal hyperparathyroidism; RR, reference range; FHH, familial hypocalciuric hypercalcemia; AD, admission day; C-PAP, continuous positive airway pressure.

\* Corresponding author at: Odense University Hospital, Sdr. Boulevard 29, 5000 Odense, Denmark.

**E-mail addresses:** [tileun@rn.dk](mailto:tileun@rn.dk) (T.L. Leunbach), [anette.tarp.hansen@dadlnet.dk](mailto:anette.tarp.hansen@dadlnet.dk) (A.T. Hansen), [mette.madsen@rn.dk](mailto:mette.madsen@rn.dk) (M. Madsen), [raci@rn.dk](mailto:raci@rn.dk) (R. Cipliene), [p.christensen@rn.dk](mailto:p.christensen@rn.dk) (P.S. Christensen), [anders.joergen.schou@rsyd.dk](mailto:anders.joergen.schou@rsyd.dk) (A.J. Schou).

<https://doi.org/10.1016/j.bonr.2021.100761>

Received 15 December 2020; Received in revised form 21 February 2021; Accepted 1 March 2021

Available online 4 March 2021

2352-1872/© 2021 The Authors.

Published by Elsevier Inc.

This is an open access article under the CC BY-NC-ND license

(<http://creativecommons.org/licenses/by-nc-nd/4.0/>).

renal calcium excretion (Hannan et al., 2018).

## 2. Objective

To describe the first case of NSHPT with a compound heterozygous CaSR mutation successfully managed long term on cinacalcet treatment.

## 3. Case

An 11-day old boy was referred to our pediatric department due to lethargy and weight loss of 14%. He was born by a multigravida woman by spontaneous vaginal delivery at gestational age 40 weeks after an uncomplicated pregnancy. The parents were unrelated Caucasians. The mother had noted the boy was drowsier compared to previous siblings from an earlier marriage. The boy was increasingly apathic without awakening during feeding and consequently failure to thrive ensued. Clinically the boy had mild sub- and intercostal recessions, he had a floppy muscle tone and the neonatal reflexes were difficult to elicit. He had a large soft anterior fontanelle extending into the forehead, and he appeared mildly dehydrated with a prolonged capillary response of three seconds.

Initial blood samples showed mild respiratory acidosis (pH 7.25, pCO<sub>2</sub> 8.9 kPa, base excess +1 mmol/L), a very high concentration of PTH of 67.4 pmol/L (reference range (RR) 0.7–9.4), a pH corrected ionized calcium ion of 3.00 mmol/L (RR 1.18–1.32), and hypophosphatemia 0.82 mmol/L (RR 1.36–2.26). Magnesium was 1.37 mmol/L (RR 0.50–1.10), alkaline phosphatase was increased 608 U/L (RR 55–425) and 25-hydroxyvitamin D was 46 pmol/L (50–160). The first urine was sampled on admission day (AD) two after hyperhydration and loop diuretics had been started. Urine calcium:creatinine ratio was relatively low (3.71 mmol/mmol), but yet above levels that were sampled later during loop diuretic free periods.

The father informed that he had a calcium disease, which was confirmed from his medical files to be familial hypocalciuric hypercalcemia (FHH). The mother was unaware of any calcium problems in her family. The results of her blood samples obtained the following morning showed a mildly increased concentration of calcium 1.34 mmol/L (RR 1.18–1.32) and PTH 9.5 pmol/L (RR 1.3–7.6). Based on the clinical findings, near normal 25-hydroxyvitamin D level and parental bloods, we suspected NSHPT on a background of a compound heterozygous CaSR mutation in the boy. This was genetically confirmed on AD ten. Two missense mutations both located in exon 7 were identified. One was paternally inherited (p.Cys582Tyr (G>A)) and one was later identified to be of maternal inheritance (p.Pro682Leu (C>T)).

An X-ray examination of the ribcage and thighbones showed generalized skeletal demineralization and irregular broad metaphysis (Fig. 1).

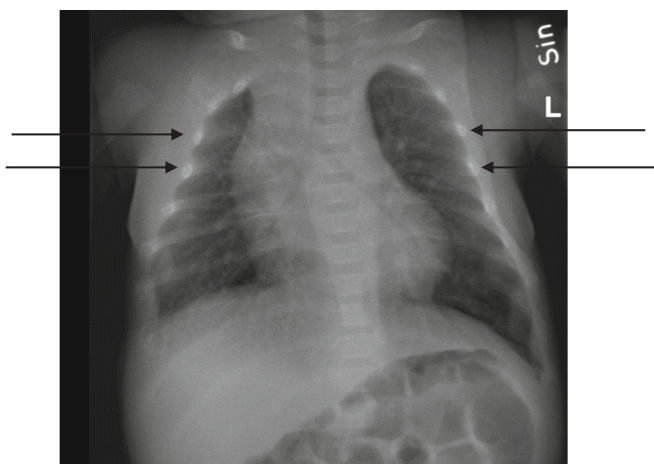


Fig. 1. X-ray with arrows indicating generalized skeletal demineralization.

Cerebral and kidney ultrasound scans on AD two did not show any calcifications. A thyroid ultrasound scan on day two was normal without enlarged parathyroid glands.

The boy was treated with hyperhydration (intravenous 0.9% saline/5% glucose and formula; in total 300 mL/kg/day) and pamidronate (0.5 mg/kg) on three consecutive days resulting in a reduction of the calcium level but with rebound hyperparathyroidism (PTH 177.9 pmol/L) (Fig. 2). Calcium depleted formula was started on AD four. To gain time, whilst discussions of long-term management took place, the boy had further infusions with pamidronate (Fig. 2). As the efficacy of bisphosphonates diminished and ionized calcium started to rise, cinacalcet was introduced at a low dose (0.5 mg/kg/day) administered on two daily doses on AD 29. Cinacalcet dose was slowly increased until a sufficient effect was seen on calcium and PTH concentrations (Fig. 2). At this point in time normal formula was introduced again (day 40). The cinacalcet tablets were crushed and suspended in water before administration. Compelling evidence of efficacy was seen when the cinacalcet dose was 5.2 mg/kg/day divided on three daily doses. The dose was further increased to 8.5 mg/kg/day. We never experienced any significant or clinically relevant hypocalcemia, and the boy did not show any signs of gastrointestinal side effects or other adverse events.

Due to poor muscle tone and softening of the bones that lead to respiratory problems necessitating support with nasal-continuous positive airway pressure (CPAP) and nasogastric tube feeding, the boy was in the neonatal intensive care department for three months. He was discharged to our outpatient setting when he turned four months old. He has been weaned of nasal-CPAP, he is bottle fed, and only his motor development is delayed at now age eight months.

## 4. Discussion

We describe the first case with a compound heterozygous CaSR mutation successfully managed on cinacalcet. Acute treatment with hyperhydration, diuretics and bisphosphonates (Stokes et al., 2017; Sun et al., 2018; Ahmad et al., 2017) was successful in achieving a serum calcium within a safe range, but exact titration was challenging as demonstrated by fluctuating calcium concentrations repeatedly dropping below the RR. We also witnessed significant rebound hyperparathyroidism after normalization of serum calcium explained by the higher set point, at which calcium inhibits PTH in NSHPT (Reh et al., 2011). Both measures emphasize that acute treatment is a temporary rescue plan (Gulcan-Kersin et al., 2020). Lastly, long-term use of bisphosphonates in children remains unknown (Sun et al., 2018).

At the time we treated this boy only one case with a homozygous mutation (NSHPT) (Sun et al., 2018) and four cases with heterozygous CaSR mutations (neonatal hyperparathyroidism) (Fisher et al., 2015; Reh et al., 2011; Forman et al., 2019; Gannon et al., 2014) had been successfully treated with cinacalcet. Recently another homozygous CaSR mutation displaying NSHPT has been reported to respond to cinacalcet (Gulcan-Kersin et al., 2020). Other described cases have not responded well, and have required parathyroidectomy (Murphy et al., 2016; Garcia Soblechero et al., 2013; Atay et al., 2014; Capozza et al., 2018; Ahmad et al., 2017; Savas-Erdeve et al., 2016).

Osteopenia at the time of parathyroidectomy increases the risk of hungry bone disease characterized by hypocalcemia, hypophosphatemia and hypomagnesemia due to excessive bone remineralization (Atay et al., 2014; Capozza et al., 2018). Hypocalcemia after parathyroidectomy due to postoperative hypoparathyroidism is more commonly described however (Stokes et al., 2017; Murphy et al., 2016; Capozza et al., 2018; Ahmad et al., 2017). Obtaining normal and stable calcium concentrations with active vitamin D, 25-hydroxyvitamin D and calcium supplements is difficult and necessitates frequent biochemical monitoring (Murphy et al., 2016; Ahmad et al., 2017; Di Maio et al., 2018). On the longer-term renal imaging to monitor for the potential development of nephrocalcinosis is necessary (Hannan et al., 2018; Di Maio et al., 2018). Hypoparathyroidism during a lifetime also carries a

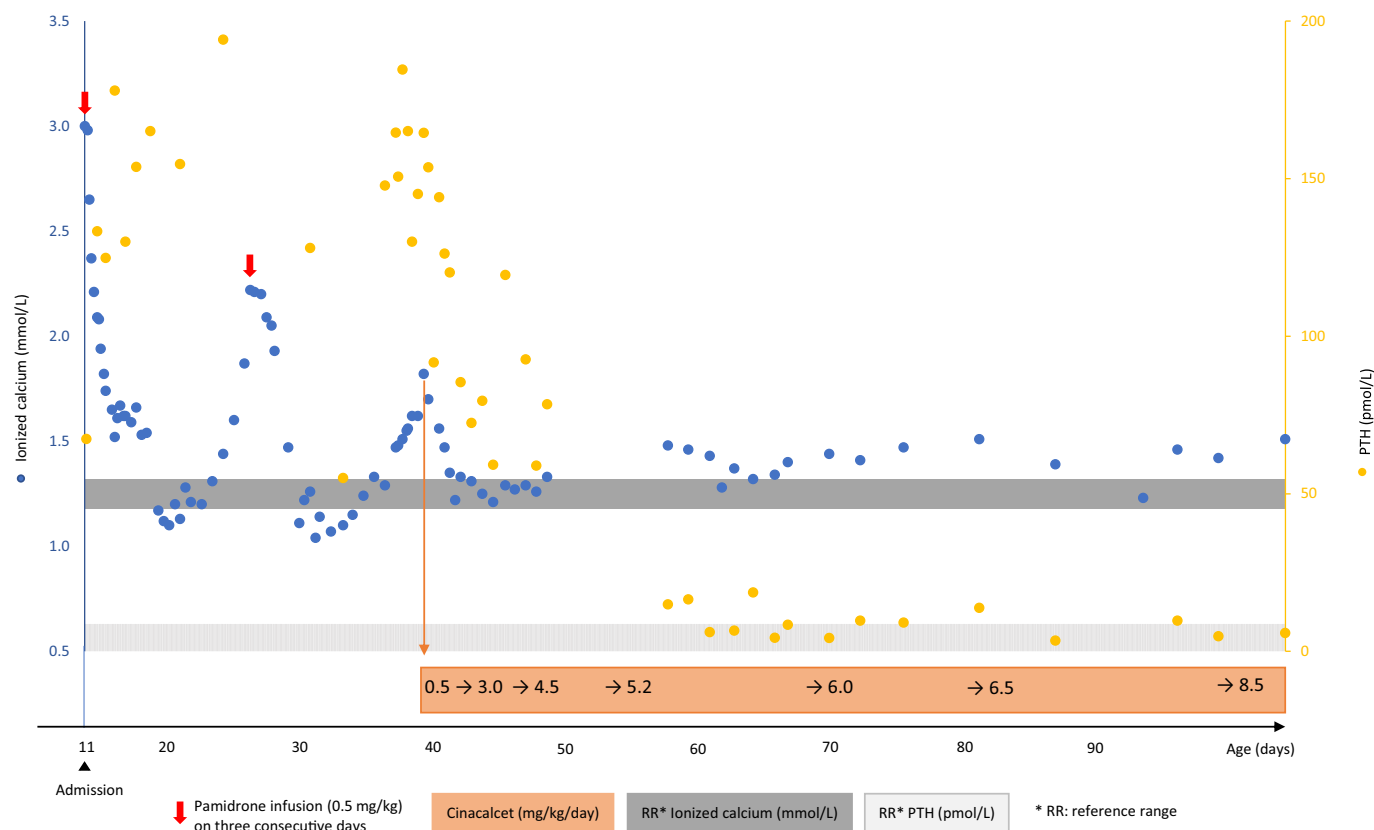


Fig. 2. Bloods and interventions during the course of treatment.

risk of reduced bone remodeling (Di Maio et al., 2018). The effect of cinacalcet, which enhances the sensitivity to calcium at the CaSR by allosteric activation resulting in normalization of calcium and suppression of PTH, mimics a more physiological response and likely does not impose the same adverse effects (Hannan et al., 2018). Long term use however, has not been described in children.

Cinacalcet responsive cases with NHPT had heterozygous variants in the extracellular CaSR region in an area with predilection for mutational hotspots (Hannan et al., 2016; Fisher et al., 2015; Reh et al., 2011; Forman et al., 2019; Gannon et al., 2014). Cinacalcet responsive cases with NSHPT had genetic variants that did not truncate the CaSR protein and its ability to couple with downstream signaling proteins (Hannan et al., 2018; Sun et al., 2018; Gulcan-Kersin et al., 2020) opposed to unresponsive cases (Hannan et al., 2018; Murphy et al., 2016; Garcia Soblechero et al., 2013; Atay et al., 2014; Capozza et al., 2018; Ahmad et al., 2017; Savas-Erdeve et al., 2016). The proportion of nonsense or frameshift mutations leading to truncated proteins are much higher in NSHPT compared to heterozygous cases (>40% vs 10%) (Hannan et al., 2012). Thus, chances of efficacy using cinacalcet would expectedly be higher when only a single allele is mutated. The variability of response to cinacalcet is not fully understood (Murphy et al., 2016). Two cases with the same CaSR mutation did not display the same response, and possibly unidentified genetic modifiers play a role (Murphy et al., 2016; Wilhelm-Bals et al., 2012). Compound heterozygosity likely display a conformational change in the CaSR with preserved binding sites likely explaining the efficacy of cinacalcet in our case. Future functional studies of CaSR variants may be able to elucidate this further.

Inactivating mutations of the CaSR are characterized by a gene dosage effect and more commonly, when a single allele is affected, a milder and often asymptomatic variant, FHH, occurs (Hannan et al., 2016; Glaudo et al., 2016; Lietman et al., 2009). The background for the severe case presentations when only a single allele is affected is not fully understood, but allelic imbalance, a dominant-negative effect of the

CaSR mutations in the wildtype-CaSR, maternal vitamin D deficiency or paternally inherited mutations (sensing a normal maternal calcium level as low) have been suggested to play a role (Hannan et al., 2016; Glaudo et al., 2016). In our case the father had symptoms and therefore knowledge of his condition, and we speculate if this affected the initial clinical picture due to the mother's milder phenotype with near normal calcium concentrations. Progression to more a more benign condition in heterozygous cases has been described (Murphy et al., 2016; Garcia Soblechero et al., 2013; Gulcan-Kersin et al., 2020). So far, our compound heterozygous boy remains well on a stable dose of cinacalcet.

Cinacalcet has a dose-dependent effect on PTH regulation (Gannon et al., 2014; Vahe et al., 2017). It appears that the effective dose varies between cases (Table 1) (Forman et al., 2019). We titrated cinacalcet whilst monitoring calcium and PTH levels, and when the dose was increased to 5.2 mg/kg/day, we employed a three daily dosing regimen (Fig. 2). The dose was further increased to 8.5 mg/kg/day after which calcium and PTH remained stable.

## 5. Conclusion

NSHPT is a life-threatening state of hypercalcemia that requires acute action to normalize calcium concentrations. Acute medical management has transient effect, and definite treatment with surgery is not uncomplicated. The effect of cinacalcet appears to depend on the remaining functionality of the CaSR. On this basis, we suggest a trial of cinacalcet in cases with NSHPT or severe NHPT irrespective of the nature of the CaSR mutation to assess the efficacy of the drug on an individual basis (Reh et al., 2011; Forman et al., 2019; Gannon et al., 2014).

## Contributors' statement

Leunbach TL: Drafted the initial manuscript, reviewed and revised the manuscript, cared for patient.

**Table 1**  
NSHPT (homozygous) and NHPT (heterozygous) cases treated with cinacalcet.

Case report	Genetic mutation	Age at presentation	Presenting total Ca mmol/L (RR)	Ionized Ca mmol/L (RR)	Presenting PTH pmol/L (RR)	Cinacalcet mg/kg/d (DD <sup>a</sup> )	Cinacalcet mg/m <sup>2</sup> /d	Starting age	Psychomotor delay
Cinacalcet responsive cases									
Fisher et al. (2015)	R185Q (c.554G>A) heterozygous-de novo dominant negative	11 months	3.45 (2.1–2.6)	NA <sup>b</sup>	8 (1.0–6.8)	2.4–7.4 (2–4 DD)	NA	13 months	Yes
Fisher et al. (2015)	R185Q (c.554G>A) heterozygous-de novo dominant negative	Day 26	3.3 (2.1–2.6)	NA	21 (1.0–6.8)	1.68–2.7 (3 DD)	NA	4 months	No
Reh et al. (2011)	R185Q (c.554G>A) heterozygous-de novo dominant negative	Day 7	3.1 (2.25–2.75)	NA	70 (1–7.5)	4 (2 DD)	20.0	23 days	No
Forman et al. (2019)	R185Q (c.554G>A) heterozygous-de novo dominant negative	Day 3	3.3 (RR NA)	NA	99 (RR NA)	0.5–5.0	7.3–112.5	7 days	No
Gannon et al. (2014)	R185Q (c.554G>A) heterozygous-paternal dominant negative	Day 2	3.23 (2.33–2.74)	1.99 (1.0–1.17)	122 (<6.4)	0.4–9.6 (3 DD)	6–202	36 days	No
Wilhelm-Bals et al. (2012) <sup>c</sup>	p.R69H (c.206G>A) homozygous	Week 1	8.25 (2.20–2.52)	NA	95 (1.2–6.4)	30–60/90 mg on intermittent days	NA	6 years	Yes
Sun et al. (2018)	p.I18K (c.242T>A) homozygous	Day 7	6.01 (2.10–2.55)	NA	100 (1.5–7.2)	NA (2 DD)	30–45	72 days	No
Gulcan-Kersin et al. (2020)	p.G613E (c.1836G>A) homozygous	Day 1	3.60 (2.25–2.75)	2.10 (1.15–1.30)	158.3 (1.6–6.9)	NA	20–160 (3–4 DD)	2 days	No
Current case	Compound heterozygous (p.Cys582Tyr (G>A)) (p.Pro682Leu(C>T)).	Day 11	NA	3.24 (1.18–1.32)	67 (0.7–9.4)	0.2–5.5 (3 DD)	1–22	29 days	Motor delay at 8 months. No impression of cognitive delay.
Cinacalcet non-responsive cases									
Capozza et al. (2018)	IVS5+1G>A c.1608+1G>A Splice site-skipped Exon 5 Homozygous	Day 8	7.18 (2.15–2.95)	NA	49.3 (0.7–3.9)	0.4–4	NA	Within first month of life	NA
Ahmad et al. (2017)	IVS4-19 (c.1378-2A>G) Homozygous	2 months	5.6 (2.10–2.55)	NA	153.9 (1.1–6.9)	4 (2 DD)	NA	2 months	No
Murphy et al. (2016)	p.R69H (c.206G>A) homozygous	4 days	9.2 (2.10–2.55)	>5	91.99 (1.59–6.9)	0.4–8.5	6–143	18 days	NA
Atay et al. (2014)	p.M74Ifs*24 (c.222_226delGATAT) homozygous	21 days	4.75 (2.10–2.62)	NA	116.2 (1.0–5.5)	NA	30–90 (2DD)	28 days	No
García Soblechero et al. (2013)	p.R465Lfs*9 (c.1392_1404delI13) homozygous	23 days	5.8 (2.15–2.58)	3.69 (1.00–1.20)	54.9 (1.6–6.9)	NA	10–25	2 months	No
Savas-Erdeve et al. (2016)	p.R544* (C.1630C>T) homozygous	12 days	4.85 (2.25–2.75)	NA	269 (1.6–6.9)	NA	10–25	29 days	No

<sup>a</sup> DD: divided doses.

<sup>b</sup> NA: not available.

<sup>c</sup> This patient had sub-total parathyroidectomy in the first year of life prior to cinacalcet.

Hansen AT: Reviewed and revised the manuscript, responsible for biochemistry.

Madsen M: Reviewed and revised the manuscript, cared for patient.

Cipiline R: Reviewed and revised the manuscript, cared for patient.

Christensen PS: Reviewed and revised the manuscript, cared for patient.

Schou AJ: Reviewed and revised the manuscript, consulted during patient care.

#### Declaration of competing interest

All authors have nothing to disclose.

#### Acknowledgements

None.

#### Funding source

This research did not receive any grant from funding agencies in the public, commercial, or not-for-profit sectors.

#### References

- Ahmad, N., Bahasan, M., Al-Ghamdi, B.A.A., Al-Enizi, H.F., Al-Zahrani, A.S., 2017. Neonatal severe hyperparathyroidism secondary to a novel homozygous CASR gene mutation. *Clin. Cases Mineral Bone Metab.* 14 (3), 354–358.
- Allgrove, J., 2015. Physiology of calcium, phosphate, magnesium and vitamin D. *Endocr. Dev.* 28, 7–32.



- Atay, Z., Bereket, A., Haliloglu, B., Abali, S., Ozdogan, T., Altuncu, E., et al., 2014. Novel homozygous inactivating mutation of the calcium-sensing receptor gene (CASR) in neonatal severe hyperparathyroidism-lack of effect of cinacalcet. *Bone*. 64, 102–107.
- Capozza, M., Chinellato, I., Guarnieri, V., Di Lorgi, N., Accadia, M., Traggiai, C., et al., 2018. Case report: acute clinical presentation and neonatal management of primary hyperparathyroidism due to a novel CaSR mutation. *BMC Pediatr.* 18 (1), 340.
- Di Maio, S., Soliman, A.T., De Sanctis, V., Kattamis, C.C., 2018. Current treatment of hypoparathyroidism: theory versus reality waiting guidelines for children and adolescents. *Acta Biomed* 89 (1), 122–131.
- Fisher, M.M., Cabrera, S.M., Imel, E.A., 2015. Successful treatment of neonatal severe hyperparathyroidism with cinacalcet in two patients. *Endocrinol. Diabetes Metab. Case Rep.* 2015, 150040.
- Forman, T.E., Niemi, A.K., Prahald, P., Shi, R.Z., Nally, L.M., 2019. Cinacalcet therapy in an infant with an R185Q calcium-sensing receptor mutation causing hyperparathyroidism: a case report and review of the literature. *J. Pediatr. Endocrinol. Metab.* 32 (3), 305–310.
- Gannon, A.W., Monk, H.M., Levine, M.A., 2014. Cinacalcet monotherapy in neonatal severe hyperparathyroidism: a case study and review. *J. Clin. Endocrinol. Metab.* 99 (1), 7–11.
- García Soblechero, E., Ferrer Castillo, M.T., Jimenez Crespo, B., Dominguez Quintero, M. L., Gonzalez, Fuentes C., 2013. Neonatal hypercalcemia due to a homozygous mutation in the calcium-sensing receptor: failure of cinacalcet. *Neonatology* 104 (2), 104–108.
- Glaudo, M., Letz, S., Quinkler, M., Bogner, U., Elbelt, U., Strasburger, C.J., et al., 2016. Heterozygous inactivating CaSR mutations causing neonatal hyperparathyroidism: function, inheritance and phenotype. *Eur. J. Endocrinol.* 175 (5), 421–431.
- Gulcan-Kersin, S., Kirkgoz, T., Eltan, M., Rzayev, T., Ata, P., Bilgen, H., et al., 2020. Cinacalcet as a first-line treatment in neonatal severe hyperparathyroidism secondary to calcium sensing receptor (CaSR) mutation. *Horm. Res. Paediatr.* 93 (5), 313–321.
- Hannan, F.M., Nesbit, M.A., Zhang, C., Cranston, T., Curley, A.J., Harding, B., et al., 2012. Identification of 70 calcium-sensing receptor mutations in hyper- and hypocalcaemic patients: evidence for clustering of extracellular domain mutations at calcium-binding sites. *Hum. Mol. Genet.* 21 (12), 2768–2778.
- Hannan, F.M., Babinsky, V.N., Thakker, R.V., 2016. Disorders of the calcium-sensing receptor and partner proteins: insights into the molecular basis of calcium homeostasis. *J. Mol. Endocrinol.* 57 (3), R127–R142.
- Hannan, F.M., Olesen, M.K., Thakker, R.V., 2018. Calcimimetic and calcilytic therapies for inherited disorders of the calcium-sensing receptor signalling pathway. *Br. J. Pharmacol.* 175 (21), 4083–4094.
- Lietman, S.A., Tenenbaum-Rakover, Y., Jap, T.S., Yi-Chi, W., De-Ming, Y., Ding, C., et al., 2009. A novel loss-of-function mutation, Gln459Arg, of the calcium-sensing receptor gene associated with apparent autosomal recessive inheritance of familial hypocalcaemic hypercalcemia. *J. Clin. Endocrinol. Metab.* 94 (11), 4372–4379.
- Murphy, H., Patrick, J., Baez-Irizarry, E., Lacassie, Y., Gomez, R., Vargas, A., et al., 2016. Neonatal severe hyperparathyroidism caused by homozygous mutation in CASR: a rare cause of life-threatening hypercalcemia. *Eur. J. Med. Genet.* 59 (4), 227–231.
- Reh, C.M., Hendy, G.N., Cole, D.E., Jeandron, D.D., 2011. Neonatal hyperparathyroidism with a heterozygous calcium-sensing receptor (CASR) R185Q mutation: clinical benefit from cinacalcet. *J. Clin. Endocrinol. Metab.* 96 (4), E707–E712.
- Savas-Erdeve, S., Sagsak, E., Keskin, M., Magdelaine, C., Lienhardt-Roussie, A., Kurnaz, E., et al., 2016. Treatment experience and long-term follow-up data in two severe neonatal hyperparathyroidism cases. *J. Pediatr. Endocrinol. Metab.* 29 (9), 1103–1110.
- Stokes, V.J., Nielsen, M.F., Hannan, F.M., Thakker, R.V., 2017. Hypercalcemic disorders in children. *J. Bone Miner. Res.* 32 (11), 2157–2170.
- Sun, X., Huang, L., Wu, J., Tao, Y., Yang, F., 2018. Novel homozygous inactivating mutation of the calcium-sensing receptor gene in neonatal severe hyperparathyroidism responding to cinacalcet therapy: a case report and literature review. *Medicine (Baltimore)* 97 (45), e13128.
- Vahe, C., Benomar, K., Espiard, S., Coppin, L., Jannin, A., Odou, M.F., et al., 2017. Diseases associated with calcium-sensing receptor. *Orphanet. J. Rare Dis.* 12 (1), 19.
- Wilhelm-Bals, A., Parvex, P., Magdelaine, C., Girardin, E., 2012. Successful use of bisphosphonate and calcimimetic in neonatal severe primary hyperparathyroidism. *Pediatrics.* 129 (3), e812–e816.