

The Role of Ventriculoatrial Shunts for The Shunts Placement in Modern Medicine : A Case Report

Adhitya Rahadi Yudhadi¹, Christian Ariono Budiwaluyo², Nobuhito Morota³, Satoshi Ihara³, Kyoji Tsuda³

¹Department of Neurosurgery, DR.Slamet Hospital, Garut, West Java, Indonesia

²Department of Neurosurgery, Mandaya Royal Hospital Puri, Tangerang, Banten, Indonesia

³Department of Neurosurgery, Tokyo Metropolitan Children's Medical Centre, Tokyo, Japan

Abstract

Introduction: Although Ventriculoatrial (VA) shunt is one of the oldest solution for hydrocephalus, after the recognition of serious complication and operative difficulties, VA shunt procedure has fallen into disrepute. Since 1970s, most of neurosurgeons has changed their practice from VA shunt to ventriculoperitoneal (VP) shunt. It provides a prolong relief of intracranial pressure and easy to be performed. However, shunt revision may still be expected due to shunt infection, obstruction, migration and so on. When the peritoneum is precluded and no more available owing to the intra-abdominal adhesions, local sepsis and scarring from the previous surgery, VA shunt can be one of the choices to do the shunt revision. Whenever laparotomy for VP shunt has high possibility of serious complications and operative difficulties due to preexisting peritoneal complication, VA shunt can be a safe and effective alternative in the neurosurgeon's armamentarium for the cerebrospinal fluids (CSF) drainage.

Case Report: In this case report, we described a case of premature 6-month-old baby boy with hydrocephalus, whose abdominal cavity had the previous history of peritonitis and stoma placement.

Result: Because his abdominal condition excluded placement of a distal catheter for VP shunt, VA shunt was planned as alternative procedure for VP shunt.

Conclusion: Role of VA shunt in the era of modern neurosurgery is also discussed based on the literature review.

Keyword: Pediatric, Hydrocephalus; Shunt Revision; Ventriculoperitoneal shunt, Ventriculoatrial shunt

Introduction

Hydrocephalus is a neuropathological disorder where the cerebrospinal fluid (CSF) of the ventricle or subarachnoid space in the brain are being accumulated causing the enlarged ventricle and increased intracerebral pressure. The golden standard for the treatment is a CSF diversion (shunt procedure) nowadays [1]. Other procedure such as Endoscopy Third Ventriculostomy (ETV), and Choroid Plexus Cauterization (CPC) are emerging as new modality of the hydrocephalus treatment in selected cases, especially in the developing countries.[2]

Since the invention of the first implantable shunt valve by Nulsen and Spitz almost 50 years ago, there have been innumerable innovations and new designs of the

*Corresponding author at: Department of Neurosurgery, DR.Slamet Hospital, Garut, West Java, Indonesia

shunt equipment to treat hydrocephalus [3]. Many sites, including the atrium, bladder, pleural cavity, peritoneal cavity, and also ureter, have been mentioned for the distal catheter implantation of CSF shunts. Among them, ventriculoperitoneal (VP) shunt is the most common and popular surgical procedure, surpass ventriculoatrial (VA) shunts [4]. In general, any shunt procedures are prone to shunt revision due to shunt infection, obstruction, migration and so on. When it happened in VP shunt but the condition of peritoneal cavity was judged suboptimum to performed the VP shunt revision, VA shunt can be an option for continuous the CSF drainage process of hydrocephalus [4][5][6]

VA shunt is provided to transfer CSF from the cerebral ventricle into the right atrium of the heart. However, VA shunt is regarded technically more demanding than VP shunt and the complications could be life threatening. The intraoperative appropriate vein selection and exact shunt placement are important to reduce shunt complications associated with VA shunt. [4][7]

We report a case of VA shunt in an infant who had preexisting peritoneal complications which precluded placement of VP shunt. Role of VA shunt in the era of modern neurosurgery is also discussed based on the literature review.

Case Report

A 6-month-old baby boy who was born at 23 week's gestation with body weight of 598 grams was referred to Tokyo Metropolitan Children's Hospital for the treatment of hydrocephalus. His previous history showed ileum perforation due to meconium ileus developed soon after the birth and a gastric stoma was placed after a surgical treatment for peritonitis. The baby also accompanied with intraventricular hemorrhage (Papile grade 3 in both sides) which had been conservatively managed by lumbar puncture, followed by placement of a CSF reservoir at the age of 2 months old. As the body weight increased, CSF diversion is scheduled. Since the abdominal cavity which had the previous history of peritonitis and surgery was excluded from distal catheter placement, VA shunt was planned.

The baby underwent VA shunt placement using a programmable valve (Codman Hakim, USA). During the surgery, the proximal catheter was inserted in the right anterior horn. The distal catheter was appropriately position in the atrium of the heart from the external jugular vein. The internal jugular vein which commonly used in VA shunt was unusually narrow to insert a distal catheter. The insertion of the distal catheter was performed by a pediatric thoracic surgeon under the ultrasonography guidance. A chest x-ray was taken to confirm the position of the distal catheter before the end of surgery (Figure 1). The patient fully recovered after the surgery without complications.

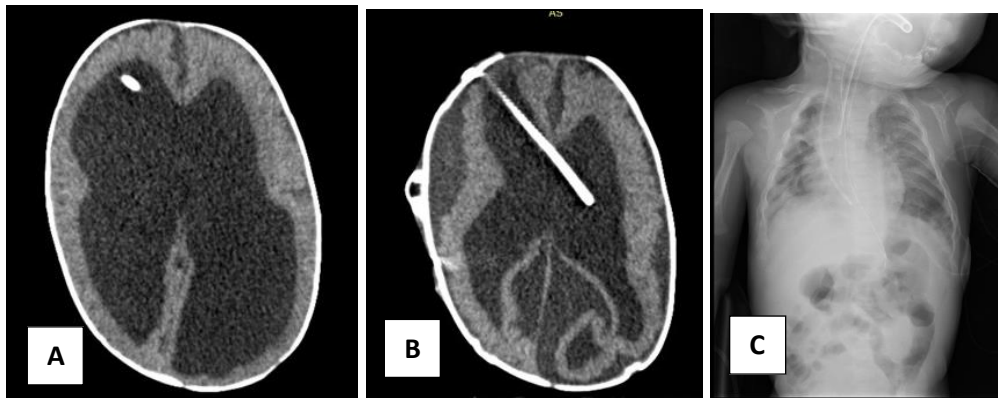


Figure 1. Patient's Imaging. (A) Pre-operative CT Scan; (B) Post-operative CT Scan; (C) Post-operative chest X-Ray.

Discussion

Cerebral shunts are commonly used to treat hydrocephalus, the abnormal accumulation of CSF that cause the ventricle of the brain became swelling [1]. In patient with hydrocephalus, CSF can be drained from the ventricular system to various cavities in the body. The location of the shunt is determined by the neurosurgeon based on the case, and distal end of the catheter can be located in various place regarding the route used by the neurosurgeon. [1][8]

The peritoneal cavity is still the most preferred site for inserting distal catheter during the continuous CSF diversion procedure in hydrocephalus [9]. The VP Shunt provides a prolonged relief of intracranial pressure and relatively easy to perform with failure rates of 30-40% at 1 year and 50% at 2 years in pediatric patients [5]. However, shunt revision may still be expected due to shunt infection, obstruction, and migration [5]. The CSF pseudocyst, like the one that reported by Kim et al in 1995 can also be one of the causes for shunt revision in the future [6]

Variety of abdominal pathologies render the peritoneal cavity a suboptimal location for the CSF diversion. The risk of abdominal complication associated with VP shunt is 25%, and incidence of bowel perforation is 0.1-0.7% [10]. Burks et al in 2017 in their study reported revealed that patients undergoing shunt operations within 2 weeks after abdominal surgery were at increased risk for shunt failure when compared with those who had not had abdominal surgery.[11]

When the peritoneum is precluded and no more rooms available owing to the intra-abdominal adhesions, local sepsis and scarring from the previous surgery, VA shunt can be one of the choices for the shunt revision. In 2015, based on their study, Akhtar suggested that despite VP shunt being the most preferred method; there is a notable patient population that remains where the VA shunt is needed. However, we

still have to understand that these procedure may not be easily used in infants and toddlers.[12]

Ventriculoatrial shunt placement enables CSF to flow from the cerebral ventricular system to the atrium of the heart. VA shunt became popular after the introduction of the Spitz-Holter valve in early 1950 and Dr. Pudenz reported his first successful case of 3-month-old female baby in 1955 [3][13]. However, after the recognition of serious complication like pulmonary hypertension, thrombosis, infection, and operative difficulties, in 1970s, VA shunt were generally avoided and become the alternative procedure if the VP shunt is not indicated [4]. In 2016, Ratliff reported there are 2 associated factors which resulted the decline of VA shunt : 1) a significant morbidity and mortality rate due to thromboembolic complications and infections, and 2) an increased revision rate, particularly in children. [7]

VA shunt approach may cause potentially life threatening complications, including mechanical failure of shunt system, atrial or major venous thrombosis with associated pulmonary embolism, pulmonary hypertension, cor pulmonale, and septicemia was reported in the literature [13]. Clark et al reported in his study at 2016 that from 38 patients, the survival rate for post VA shunt placement in 6-month, 1-year, and 2-year were 53, 43, and 27% respectively. Blockage was the commonest reason for shunt failure (68%) and twenty-two patients required at least 1 shunt revision (58%). There were 3 death, of which were shunt related.[14]

Several techniques have been described to reduce complications and achieve improved success rate in the atrial catheter replacement. It is important to place the shunt through an appropriate vein into the atrium. In 2002, Chuang et al reported the use of percutaneous VA placement with real-time transesophageal echocardiogram monitoring. They claimed that the procedure can be used less invasively, accurately, quickly and safely. Ultrasonography-guided VA shunting has also been described [15]. The authors suggested that the procedure could reduce complications by providing the correct placement of the cardiac end of the catheter without using fluoroscope or an X-ray.[4]

From surgical view point, techniques of how to insert a distal catheter in VA shunt has long been controversial, especially for those in infants and toddlers. Many discussions of the conventional surgical procedure that involves placing the distal catheter into the atrium via the facial or internal jugular vein were described. [4]

In our case report, VA shunt was performed because the history of ileum perforation that developed soon after the birth and a stoma placement precluded the use of abdominal cavity from placement of distal catheter of VP shunt. VA shunt was the

choice of CSF diversion under cooperation with a thoracic pediatric surgeon. The distal catheter was inserted to the atrium of the heart through the right external jugular vein instead of the commonly used internal one because of its narrow caliber. Ultrasonographic guidance was useful for inserting the distal catheter to the vein. As a result, the hydrocephalus was successfully treated without complications.

VA shunt are one of the oldest method to CSF drainage for infant and children with hydrocephalus, however, it may have a treatable life-threatening complications. Radiographic or ultrasonographic examination, and also cooperation with other division like thoracic surgery may have prevented all these complication and improved outcomes with collaborative study. Therefore, reasons, complications and outcomes should be clearly stated.

Conclusion

Despite associated possible life-threatening complications, VA Shunt still remains an indispensable procedure for treating hydrocephalus in the era of modern neurosurgery in the 21st century. Whenever surgical indication for VP shunt is suboptimum due to abdominal complications, VA shunt could be a candidate of surgical choice. With caution and recognition of serious complications, and utilizing recent advancement of variety of medical technologies, VA shunt would be a safe and effective alternative in the neurosurgeon's armamentarium for the treatment of hydrocephalus.

References

- [1]. Drake, J. M.; Kestle, J. R. W.; Tuli, S. 2000. "CSF shunts 50 years on - past, present and future". *Child's Nervous System*. 16 (10-11): 800-4.
- [2]. Warf BJ. 2005. *Comparison of Endoscopic Third Ventriculostomy Alone And Combined With Choroid Plexus Cauterization In Infants Younger Than 1 Year Of Age : A Prospective Study In 550 African Children*. *Journal of Neurosurgery*. 103: 475-481.
- [3]. Drygas J, Haines SJ. 2008. *Ventriculoatrial Shunting*. In: Goodrich JT. *Neurosurgical Operative Atlas: Second Edition*. Thieme Medical Publisher, Inc. New York. Page 34-39
- [4]. Erdogan H., Altun A., Kuruoglu E., Kaya A.H., Dagainar A. *Difficulties Of Distal Catheter Insertion Of Ventriculoatrial Shunting In Infants And Little Children*. *Journal of Turkish Neurosurgery*. 2017. 21304-17.2

- [5]. Hanak BW, Bonow RH, Harris CA, Browd SR. 2017. *Cerebrospinal Fluid Shunting Complication in Children*. Journal of Pediatric Neurosurgery. 56(6) 381-400.
- [6]. Hamid R et al. 2014. *Post Ventriculoperitoneal Shunt Abdominal Pseudocyst : Challenge Based In Management*. Asian Journal of Neurosurgery. 12(1): 13-16.
- [7]. Yavuz C. Et al. *Reason, Procedures, And Outcomes In Ventriculoatrial Shunts : A Single-Center Experience*. Surgical Neurology International. 2013. 04: 10.
- [8]. Ratliff M, Unterberg A, Bachli H. *Ventriculo-Biopleural Shunt As Last Resort In A 4-Year-Old Child In Whom A VP And VA Shunt Failed*. Journal of Neurosurgery Pediatrics. 2016. 17:285-288.
- [9]. Kim Y.J. *Percutaneous Insertion Of Distal Catheter During Ventriculo_Atrial Shunts. A Simple And Reliable Method*. Journal of Korean Neurosurgery Society. 2007. 41: 429-431.
- [10]. Guthe SP, Pravin S, Darade P, Velho V. 2018. *Silent Migration Of Ventriculoperitoneal Shunt Per Anus In A Child : Management And Review of Literature*. Asian Journal of Neurosurgery. 13(2): 446-448.
- [11]. Burks JD, Conner AK, Briggs RG, Glenn CA, Bonney PA et al. 2017 *Risk Failure In Pediatric Ventriculoperitoneal Shunts Placed After Abdominal Surgery*. Journal of Neurosurgery Pediatrics. 02:1-7
- [12]. Akhtar N, Khan AZ, Yousaf M. 2015. *Experience And Outcome Of Ventriculoatrial Shunt : A Multi Centre Study*. Journal Ayub Med Coll Abbottabad. 27:817-820.
- [13]. Konar SK, Maiti TK, Bir SC, Kalakoti P, Nanda A. *Robert H Pudenz (1911-1998) and Ventriculoatrial Shunt : Historical Perspective*. Journal of World Neurosurgery. 2015. 84(5): 1437-1440.
- [14]. Clark DJ, Chakraborty A, Roebuck DJ, Thompson DNP. 2016. *Ultrasound Guided Placement Of The Distal Catheter In Pediatric Ventriculoatrial Shunts-An Appraisal Of Efficacy And Complications*. Journal of Child Nervous Systems. 32:1219-1225
- [15]. Chuang HL, Chang CN, Hsu JC. 2002. *Minimally Invasive Procedure For Ventriculoatrial Shunt-Combining A Percutaneous Approach With Real-Time Transesophageal Echocardiogram Monitoring: Report Of Six Cases*. Chang Gung Med J. 25:62-66.