



Surgery of Left Temporal Region Arachnoid Cyst with Neuroendoscopy: A Case Report

Yudi Yuwono Wiwoho^{1,2}, Danu Rolian¹, Bismo Nugroho¹, Syaiful Ichwan¹, Wawan Mulyawan²

¹Neurosurgery Department, Dr.Suyoto Hospital, Rehabilitation Center, Ministry of Defence of the Republic of Indonesia

²Neurosurgery Department, Indonesian Airforce Hospital Dr. Esnawan Antariksa, Halim Perdanakusuma Jakarta, Indonesia

Abstract

Introduction: Today, the development of minimally invasive neurosurgery technique, has become a choice of treatment for many neurosurgical disease. Dr.Suyoto Hospital, Rehabilitation Center, Ministry of Defence of the Republic of Indonesia and Indonesian Airforce Hospital Dr. Esnawan Antariksa, Halim Perdanakusuma, Jakarta, Indonesia, has responsibility in public health services for military and civilian community. This paper has an objective to share experience in giving treatment with intracranial neuroendoscopy technique for patient with left temporal region arachnoid cyst.

Case Report: Case Report 1 : Girl, 17 years old, with headache. There was no neurological deficit, and from brain CT Scan, there was a cystic lesion at the left temporal region. The diagnosis was arachnoid cyst. She performed neuroendoscopic cystotomy and insertion of Omay reservoir. After surgery, she had no headache, and there were no post-operative complications. Histopatology finding was arachnoid cyst. From follow up of brain CT Scan, there was improvement. We used intracranial neuroendoscopy device from B-Braun Aesculap, Germany, 2015. Case Report 2 : Boy, 8 years old, with seizure and headache. There was no neurological deficit, and from brain CT Scan, there was a cystic lesion at the left temporal region. The diagnosis was arachnoid cyst. He performed neuroendoscopic cystotomy and insertion of Omay reservoir.

Dicussion: After surgery, he had no headache and also had no seizure, and there were no post-operative complications. Histopatology finding was arachnoid cyst. From follow up of brain CT Scan, there was improvement. We used intracranial neuroendoscopy device from B-Braun Aesculap, Germany, 2015.

Conclusion: Intracranial neuroendoscopy technique can be applied for the treatment of many special and selective neurosurgical diseases, including arachnoid cyst. In this patient, intracranial neuroendoscopy had good result. We still need more many of cases for determine the success rate of this intracranial neuroendoscopy technique statistically

Keyword: Intracranial Neuroendoscopy, Arachnoid Cyst, Cystotomy, Omay Reservoir

Introduction

Today, the development of minimally invasive neurosurgery technique, has become a choice of treatment for many neurosurgical disease Dr.Suyoto Hospital, Rehabilitation Center, Ministry of Defence of the Republic of Indonesia and Indonesian Airforce Hospital Dr. Esnawan Antariksa, Halim Perdanakusuma, Jakarta, Indonesia, has responsibility in public health services for military and civilian community. Therefore, to make better quality of neurosurgical health services, Dr. Suyoto Hospital and Indonesian Airforce Hospital Dr. Esnawan Antariksa, has provide minimally invasive neurosurgery services, including intracranial neuroendoscopy technique as a

*Corresponding author at: Neurosurgery Department, Dr.Suyoto Hospital, Rehabilitation Center, Ministry of Defence of the Republic of Indonesia

choice of treatment of many special and selective neurosurgical diseases. This paper has an objective to share experience in giving treatment with intracranial neuroendoscopy technique for patient with left temporal region arachnoid cyst.

Case Report

Case 1

Girl, 17 years old, with headache. There was no neurological deficit, and from brain CT Scan, there was a cystic lesion at the left temporal region (Figure 1 and 2). The diagnosis was arachnoid cyst. We performed neuroendoscopic cystotomy and insertion of Omayya reservoir (Figure 3). After surgery, she had no headache, and there were no post-operative complications. Histopatology finding was arachnoid cyst (Figure 4). From follow up of brain CT Scan, there was improvement (Figure 5 and 6). We used intracranial neuroendoscopy device from B-Braun Aesculap, Germany, 2015.

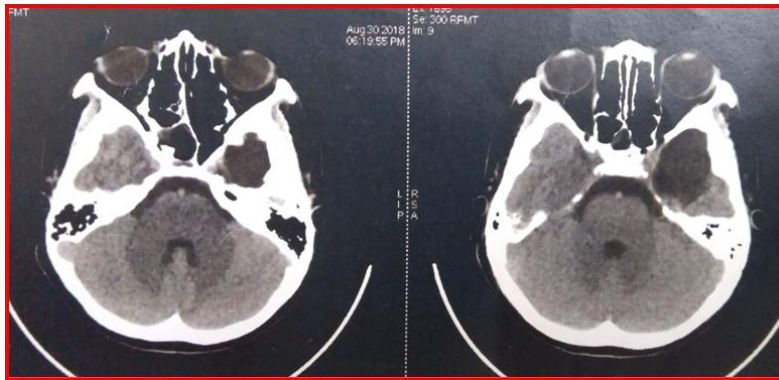


Figure 1. Axial view of preoperative head CT scan of the patient 1

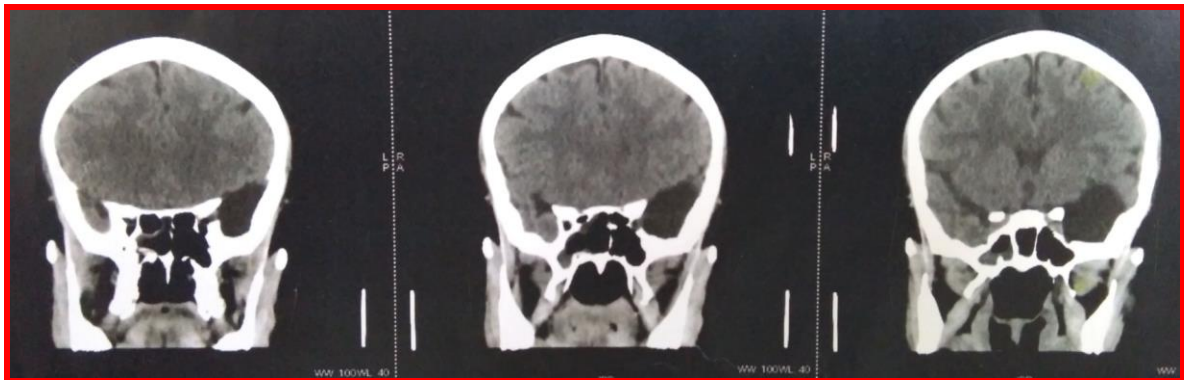


Figure 2. Coronal view of preoperative head CT scan of the patient 1

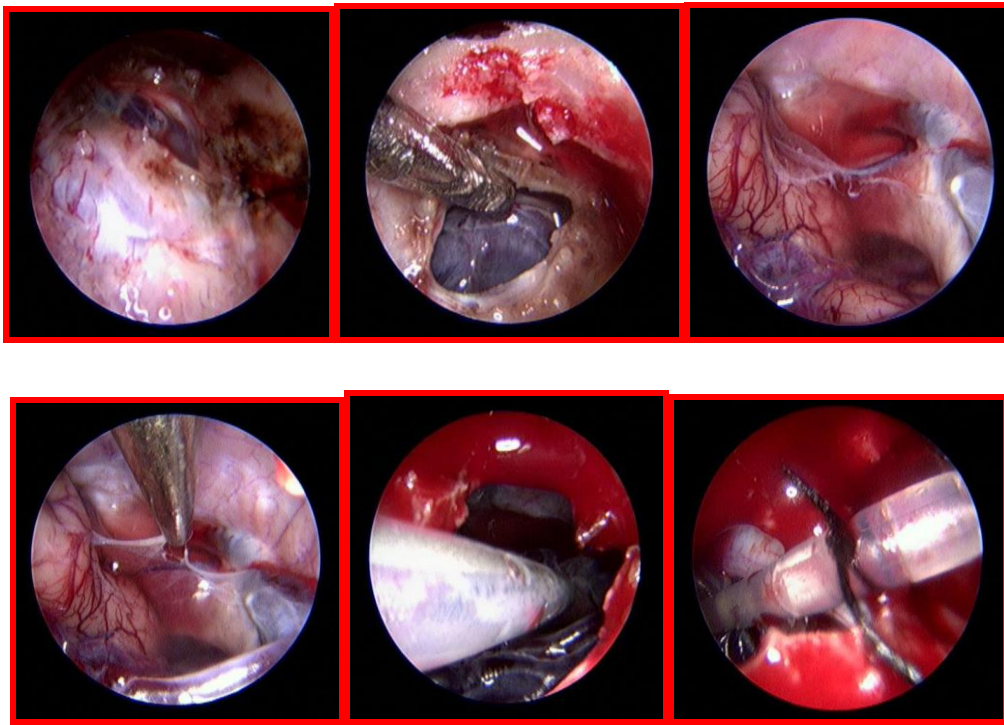


Figure 3. Intraoperative image of the patient 1

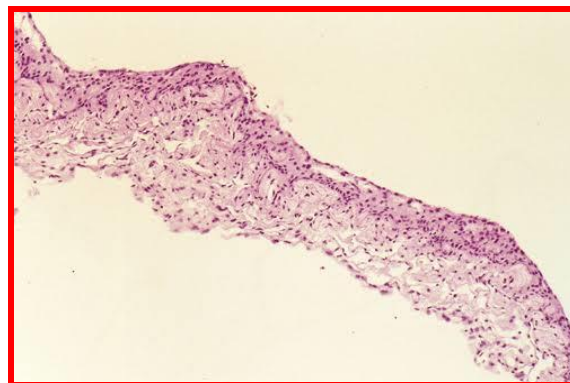


Figure 4. Histopathology result of the patient 1

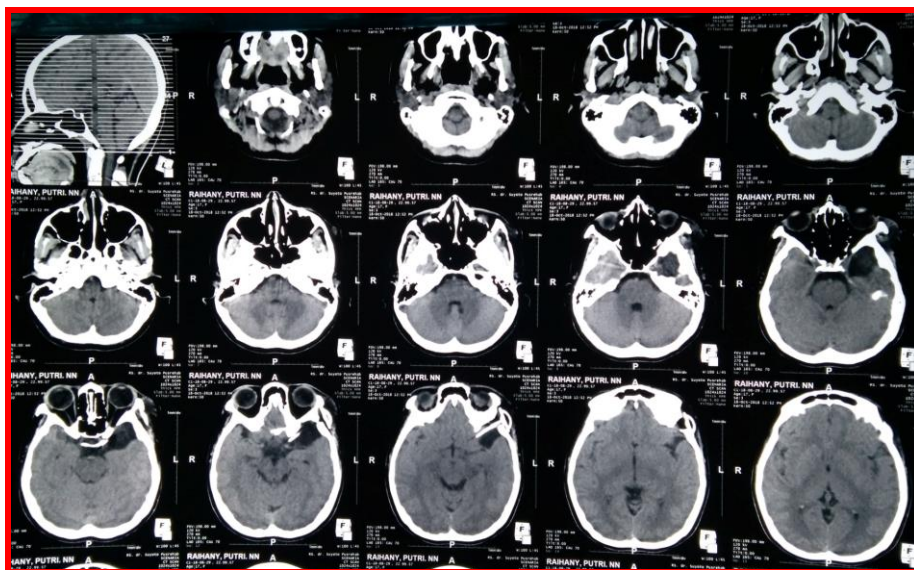


Figure 5. Axial view of postoperative head CT scan of patient 1

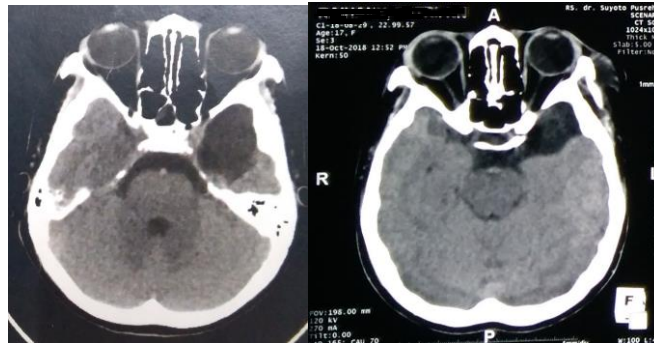

Figure 6. Improvement after surgery showed from preoperative and postoperative CT scan of patient 1

Case 2

Boy, 8 years old, with seizure and headache. There was no neurological deficit, and from brain CT Scan, there was a cystic lesion at the left temporal region. The diagnosis was arachnoid cyst. He performed neuroendoscopic cystotomy and insertion of Omay reservoir (Figure 7). After surgery, he had no headache and also had no seizure, and there were no post-operative complications. Histopathology finding was arachnoid cyst (Figure 8). From follow up of brain CT Scan, there was improvement (Figure 9). We used intracranial neuroendoscopy device from B-Braun Aesculap, Germany, 2015.

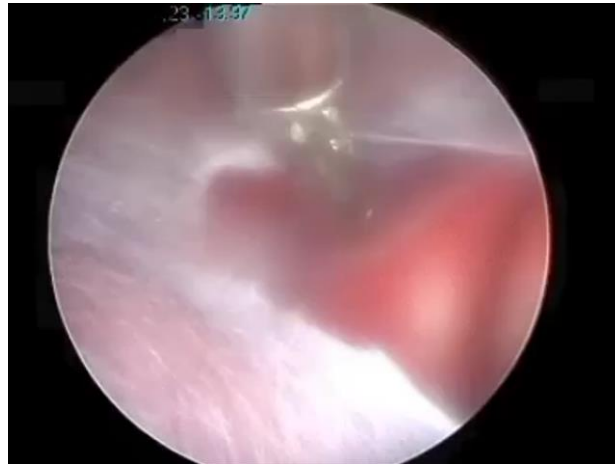

Figure 7. Intraoperative image of the patient 2

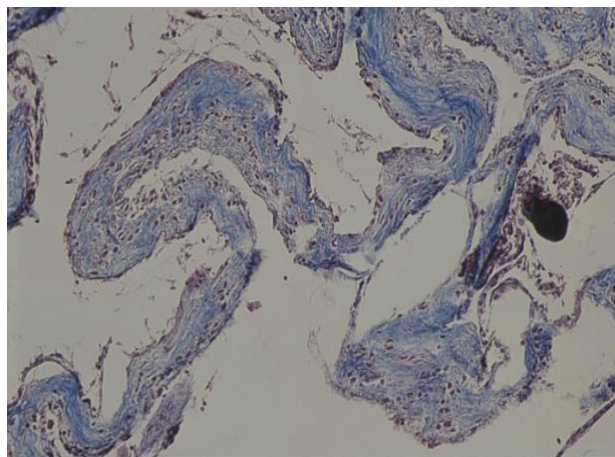


Figure 8. Histopathology result of the patient 2

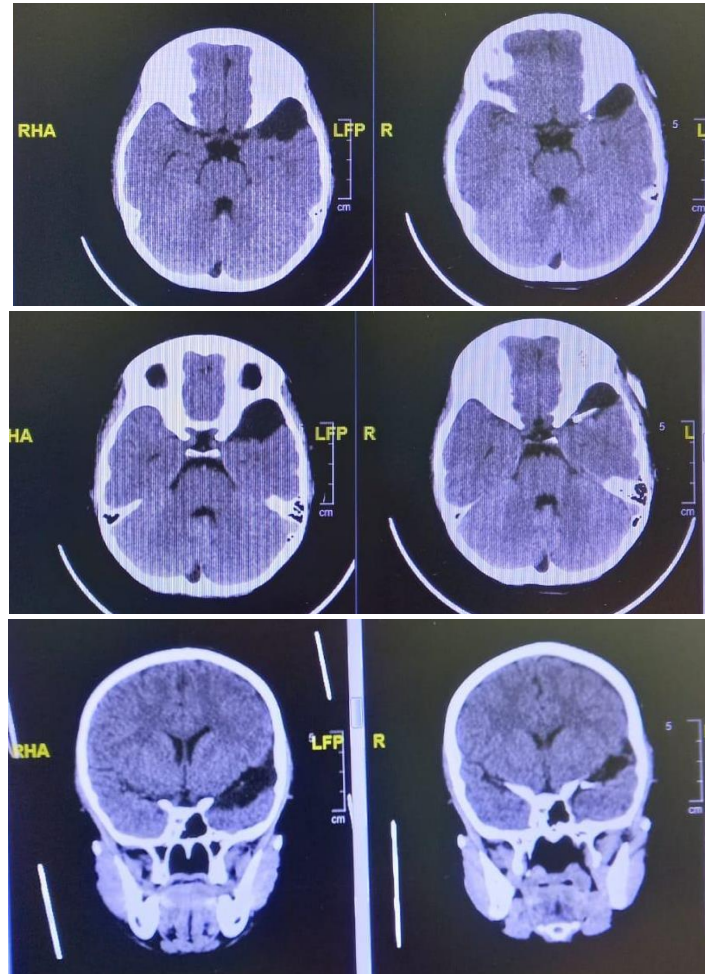


Figure 9. Improvement after surgery showed from preoperative (left) and postoperative (right) CT scan of patient 2

Discussion

Arachnoid cyst is benign, non-neoplastic, extra-axial lesion. Intra-arachnoid lesions filled with fluid similar to or exactly like cerebrospinal fluid. Male to female ratio is 2 : 1. Arachnoid cyst : 60% to 80% discovered in children. [1]

Classification of arachnoid cyst are primary arachnoid cyst such as congenital cyst, loculated, compartmentalized, or freely communicating with the surrounding CSF cisterns. Secondary arachnoid cyst are result of another condition : meningitis, trauma, or hemorrhage[1]

signs of previous inflammatory changes are gliosis or hemosiderin. cyst fluid may be xanthochromic, proteinaceous, or hemorrhagic. Epidemiology location 90% found in supratentorial space. Pathology appearance the appearance of arachnoid cyst are membranes of the cyst (delicate, filmy, translucent), islands of mesenchymal cells, meningoepithelial cell positive for epithelial membrane antigen (EMA), underlying cortex is usually normal. [2]

Distinguishing features of the arachnoid cyst wall versus a normal arachnoid membrane : [3]

- Split of the arachnoid layer at the margin of the cyst
- The increased thickness of the collagen layer
- The absence of the cobweb-like trabeculations of normal arachnoid

Embryology result from abnormal embryologic development of the subarachnoid space in 15 weeks gestation. Precursor from meninx primitive, or perimedullary mesh, precursor to the pia mater and arachnoid. The rhombic roof ruptures, CSF pulses through this mesh, and the pia mater and arachnoid separate incompletely [3]

Clinical presentation : [4]

- Headache : local mass effect
- High intracranial pressure (ICP)
- Hydrocephalus
- Asymptomatic throughout life
- Infants : macrocephaly, enlarged tense fontanelle, splayed sutures with irritability, failure to thrive, and developmental delay

Imaging : [5]

- Plain radiographs : nonspecific thinning and deformity of the adjacent bone
- Angiograms : show shifts of the adjacent vasculature and venous phase
- Prenatal ultrasound has detected arachnoid cysts as early as 13 weeks gestation. sonolucent with enhanced transmission of the ultrasound beam through the collection and are thus hypoechogenic to surrounding brain
- CT scan : sharply circumscribed, smoothly marginated lesions. Arachnoid cyst walls are so thin that they are not visible on CT and not enhance, whereas the walls of cystic tumors may be visible. The fluid of an arachnoid cyst is identical to CSF
- MRI : better detection of smaller cysts and cysts adjacent to bony structures

Treatment alternative: [6]

- Conservative : asymptomatic patients
- Surgery : Middle fossa arachnoid cysts, chronic subdural hemorrhage , increased ICP or hydrocephalus → Craniotomy for cyst excision and fenestration , shunt placement and neuroendoscopic management

Both patients have signs of raised intracranial pressure, such as headache and in patient 2 has also sign of seizure. The working diagnosis is arachnoid cyst according to symptoms and appearance from head ct scan, and it has confirmed from histopathological findings. [6]

They was performed neuroendoscopic cystotomy, in order to release the intracranial pressure, and placing the omaya reservoir into the base of the cyst , to anticipating in case there is recurrency of the cyst, so we can aspirate the CSF fluid from the cyst in neurosurgery clinic, no need to repeat the surgery. After surgery both patients have improvement in clinical and radiological aspects (as seen in clinical follow up and serial ct scan), because the intracranial pressure has return to normal value. [5] [6]

The advantage of neuroendoscopy technique are : [3] [4]

- Small incision of skin
- Minimal bleeding and minimal invasive surgery

- Shortening duration of surgery
- Shortening of LOS (length of stay) in hospital
- Better and faster of wound healing

Neuroendoscopic pearls : [6]

- Familiarize with the scope system
- Good intraoperative anatomic knowledge
- Good assistant
- Surgeon's eye must never leave the monitor/screen
- Never achieve new techniques or skills that could compromise patient's outcome
- Do not venture into a new technique/modification until the basic approach is mastered
- If in doubt, always get second opinion/consult a senior

Conclusion

Intracranial neuroendoscopy technique can be applied for the treatment of many special and selective neurosurgical diseases, including arachnoid cyst. In both patients, intracranial neuroendoscopy had good result. We still need more many of cases for determine the success rate of this intracranial neuroendoscopy technique statistically.

References

- [1]. Lorenz M, Niedermaier N, Lowitzsch K. Arachnoid cyst and tension headache: symptom or accidental finding? *Schmerz (Berlin, Germany)* 2002; 16:304–307.
- [2]. Wester K. Peculiarities of intracranial arachnoid cysts: location, sidedness, and sex distribution in 126 consecutive patients. *Neurosurgery* 1999; 45:775.
- [3]. Cincu R, Agrawal A, Eiras J. Intracranial arachnoid cysts: current concepts and treatment alternatives. *Clin Neurol Neurosurg* 2007; 109:837–843.
- [4]. Choi JW, Lee JY, Phi JH, et al. Stricter indications are recommended for fenestration surgery in intracranial arachnoid cysts of children. *Child's Nervous System* 2014; 31:77–86.
- [5]. Kandenwein J, Richter H-P, Börm W. Surgical therapy of symptomatic arachnoid cysts—an outcome analysis. *Acta Neurochir* 2004; 146:1317–1322.
- [6]. Lange M, Oeckler R. Results of surgical treatment in patients with arachnoid cysts. *Acta Neurochir* 1987; 87:99–104.