

# Patent foramen ovale and wake-up stroke

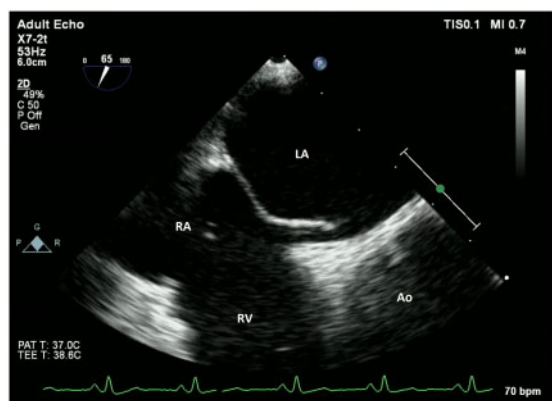
Robert M.A. van der Boon \*, Marcel L. Geleijnse , and Arend F.L. Schinkel 

Department of Cardiology, Erasmus Medical Center Rotterdam, 's-Gravendijkwal 230, 3015 CE, Rotterdam, The Netherlands

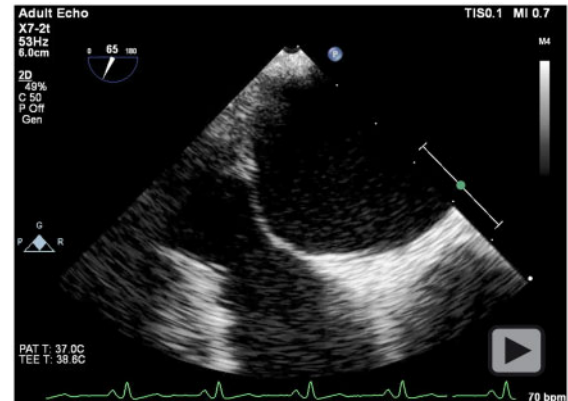
Received 17 October 2020; first decision 12 November 2020; accepted 22 December 2020

A 53-year-old male patient with no medical history except for overweight (body mass index 29.1 kg/m<sup>2</sup>) presented to the emergency room with an altered mental state. The patient had gone to bed in normal state and was found by his wife snoring and unable to wake. At arrival, his Glasgow Coma Scale was 9 (E2M5V2), and he demonstrated severe agitation upon further physical examination. The latter showed no clinical signs of venous thrombo-embolism. Emergency computed tomography (CT) angiography showed normal anatomy of the cerebral arteries without significant carotid artery disease. Additional perfusion CT showed recent ischaemia of the thalamus extending into the mesencephalon. Due to delay, the patient was ineligible for thrombolysis and was treated with platelet inhibition and admitted to the stroke unit. Prolonged monitoring demonstrated no arrhythmias and a normal transthoracic echocardiogram. The patient was referred for transoesophageal echocardiography to rule out a

cardiac source of embolism which was performed under sedation due to the heavy gag reflex of the patient. In resting conditions, the inter-atrial septum seemed to be intact. However, upon snoring the inter-atrial septum became increasingly mobile revealing a patent foramen ovale (PFO, [Figure 1](#); [Video 1](#)). Right to left shunting was confirmed with the administration of agitated saline ([Figure 2](#); [Video 2](#)). Hence, snoring (essentially the combination of the Müller and Valsalva manoeuvre) may lead to a right to left shunt in case of PFO. Our patient had an uneventful recovery with medical treatment consisting of antiplatelet therapy, a statin and referral for polysomnography. Although conflicting and scant clinical information is available on the association between obstructive sleep apnoea and wake-up stroke, the combination should trigger healthcare providers to search for a possible PFO.<sup>1–3</sup> Transoesophageal echocardiography is a valuable diagnostic tool and should be considered in these cases.



**Figure 1** Short-axis view in the mid-oesophageal position showing the right and left atrium (RA/LA), right ventricle (RV), and aortic valve (Ao). During snoring (increase of right atrial pressure), the inter-atrial septum becomes increasingly mobile revealing a patent foramen ovale.



**Video 1** Short-axis view in the mid-oesophageal position showing the right and left atrium (RA/LA), right ventricle (RV), and aortic valve (Ao). During snoring (increase of right atrial pressure), the inter-atrial septum becomes increasingly mobile revealing a patent foramen ovale.

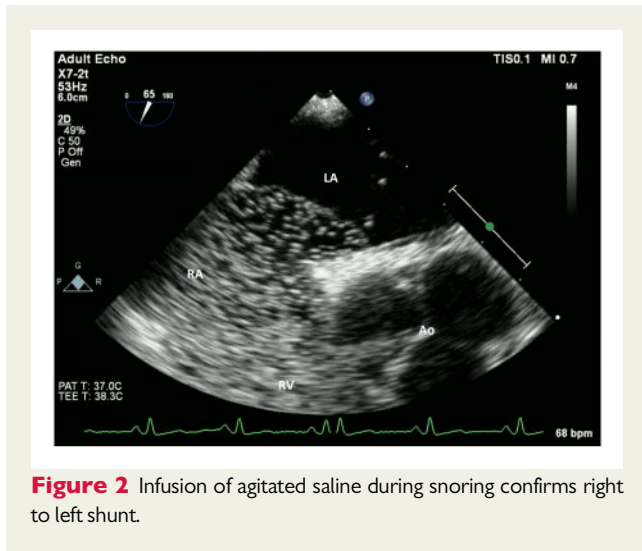
\* Corresponding author. Tel: +31650033213, Email: [r.vanderboon@erasmusmc.nl](mailto:r.vanderboon@erasmusmc.nl)

Handling Editor: Luca Arcari

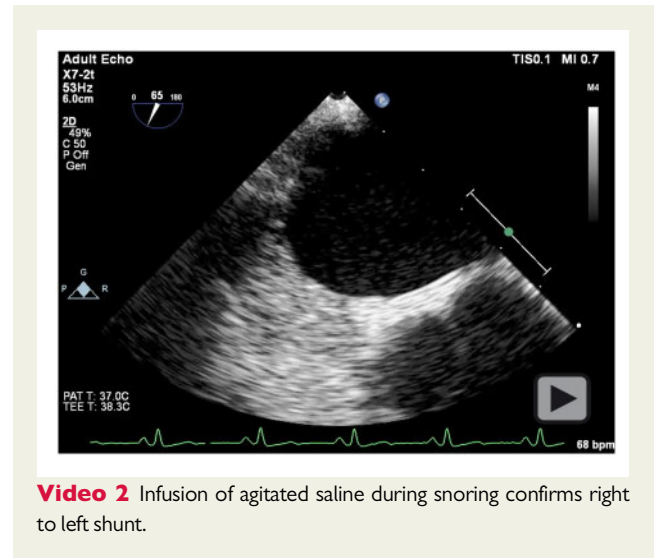Peer-reviewers: Domenico Filomena and Giulia Elena Mandoli

© The Author(s) 2021. Published by Oxford University Press on behalf of the European Society of Cardiology.

This is an Open Access article distributed under the terms of the Creative Commons Attribution Non-Commercial License (<http://creativecommons.org/licenses/by-nc/4.0/>), which permits non-commercial re-use, distribution, and reproduction in any medium, provided the original work is properly cited. For commercial re-use, please contact [journals.permissions@oup.com](mailto:journals.permissions@oup.com)



**Figure 2** Infusion of agitated saline during snoring confirms right to left shunt.



**Video 2** Infusion of agitated saline during snoring confirms right to left shunt.

**Consent:** The author's confirm that written consent for submission and publication of this case report including image(s) and associated text has been obtained from the patient's next of kin in line with COPE guidance.

**Conflict of interest:** None declared.

**Funding:** None declared.

## References

1. Guchlerner M, Kardos P, Liss-Koch E, Franke J, Wunderlich N, Bertog S et al. PFO and right-to-left shunting in patients with obstructive sleep apnea. *J Clin Sleep Med* 2012;**08**:375–380.
2. Ciccone A, Proserpio P, Roccatagliata DV, Nichelatti M, Gigli GL, Parati G et al. Wake-up stroke and TIA due to paradoxical embolism during long obstructive sleep apnoeas: a cross-sectional study. *Thorax* 2013;**68**:97–104.
3. Tur S, de la Pena M, Vives B, Martinez AB, Gorospe A, Legarda I et al. Sleep apnea syndrome and patent foramen ovale: a dangerous association in ischemic stroke? *Sleep Med* 2016;**25**:29–33.