




# Structure and Function of the Vocal Cords after Airway Reconstruction on Magnetic Resonance Imaging

Bernadette B. L. J. Elders, MD ; Marieke M. Hakkesteegt, PhD; Pierluigi Ciet, MD, PhD ;  
Harm A. W. M. Tiddens, MD, PhD; Piotr Wielopolski, PhD; Bas Pullens, MD, PhD 

**Objectives/Hypothesis:** Dysphonia is a common problem at long-term follow-up after airway surgery for laryngotracheal stenosis (LTS) with major impact on quality of life. Dysphonia after LTS can be caused by scar tissue from initial stenosis along with anatomical alterations after surgery. There is need for a modality to noninvasively image structure and function of the reconstructed upper airways including the vocal cords to assess voice outcome and possible treatment after LTS. Our objective was to correlate vocal cord structure and function of patients after airway reconstruction for LTS on static and dynamic magnetic resonance imaging (MRI) to voice outcome.

**Study Design:** Prospective cohort study.

**Methods:** Voice outcome was assessed by voice questionnaires ((pediatric) Voice Handicap Index (p)VHI) and the Dysphonia Severity Index (DSI). Postsurgical anatomy, airway lumen, and vocal cord thickness and movement on multiplanar static high-resolution MRI and dynamic acquisitions during phonation was correlated to voice outcome.

**Results:** Forty-eight patients (age 14.4 (range 7.5–30.7) years) and 11 healthy volunteers (15.9 (8.2–28.8) years) were included. Static MRI demonstrated vocal cord thickening in 80.9% of patients, correlated to a decrease in DSI (expected odds 0.75 [C.I. 0.58–0.96]  $P = .02$ ). Dynamic MRI showed impaired vocal cord adduction during phonation in 61.7% of patients, associated with a lower DSI score (0.65 [C.I. 0.48–0.88]  $P = .006$ ).

**Conclusions:** In LTS patients, after airway reconstruction MRI can safely provide excellent structural and functional detail of the vocal cords correlating to DSI, with further usefulness expected from technical refinements. We therefore suggest MRI as a tool for extensive imaging during LTS follow-up.

**Level of evidence:** 3

**Key Words:** Pediatrics, laryngotracheal stenosis, voice, dysphonia, magnetic resonance imaging.

*Laryngoscope*, 00:1–7, 2021

## INTRODUCTION

Laryngotracheal stenosis (LTS) is a rare disease of the pediatric upper airways.<sup>1</sup> Severe cases often need treatment with either a laryngotracheal reconstruction (LTR) or a cricotracheal resection (CTR) through open neck surgery.<sup>2</sup> In LTR, the stenosis is enlarged with autologous cartilage grafts with (double stage, ds) or without (single stage, ss) a period of stenting, while in CTR (part of) the cricoid and/or trachea is resected

followed by a primary anastomosis.<sup>2</sup> Earlier outcome reports have mainly focused on the success rate of surgical airway repair, with up to 95% of patients relieved of their tracheal cannula.<sup>3</sup> However, surgery can result in respiratory and vocal sequelae, which can have a major impact on quality of life at long-term follow-up.<sup>4,5</sup>

Studies focusing on these sequelae show dysphonia and poor voice-related quality of life in over 75% of pediatric patients after airway reconstruction for LTS.<sup>4–9</sup> Dysphonia in these patients possibly results from the initial stenosis at the level of the vocal cords and/or the cricoarytenoid joints, as well as from the airway surgery itself, which can result in scarring and disruption of the laryngeal framework. The placement of a posterior cartilage graft can cause a closure defect of the posterior glottis and scarring in that area, while a full laryngofissure can cause disruption of the anterior commissure.<sup>10</sup>

The current gold standard to visualize the vocal cords is videostroboscopy, but downsides are that the images obtained are 2D and nonquantitative and tissue cannot objectively be characterized. Recent advances in computed tomography (CT) and magnetic resonance imaging (MRI) make it possible to noninvasively image structure and function of the pediatric upper airways including the vocal cords.<sup>11–16</sup> However, no studies have been conducted to see if static and dynamic MR images of the vocal cords correspond to vocal function.

This is an open access article under the terms of the Creative Commons Attribution-NonCommercial License, which permits use, distribution and reproduction in any medium, provided the original work is properly cited and is not used for commercial purposes.

From the Department of Pediatric Pulmonology and Allergology (B.B.L.J.E., P.C., H.A.W.M.T.), Erasmus Medical Centre - Sophia Children's Hospital, Rotterdam, The Netherlands; Department of Radiology and Nuclear Medicine (B.B.L.J.E., P.C., H.A.W.M.T., P.W.), Erasmus Medical Centre, Rotterdam, The Netherlands; and the Department of Otorhinolaryngology and Head and Neck Surgery (M.M.H., B.P.), Erasmus Medical Centre, Sophia Children's Hospital, Rotterdam, The Netherlands.

Additional supporting information may be found in the online version of this article.

Editor's Note: This Manuscript was accepted for publication on January 04, 2021.

This research is funded by "Stichting Vrienden van het Sophia."

There is no conflict of interest to report.

Send correspondence to B. Pullens, Paediatric Otorhinolaryngologist, Erasmus MC- Sophia Children's Hospital, Wytemaweg 80, 3015 CN, Rotterdam, The Netherlands. E-mail: b.pullens@erasmusmc.nl

DOI: 10.1002/lary.29399

Therefore, we used static and dynamic MRI to image the vocal cords of patients in the long-term follow-up after open airway surgery for pediatric LTS, and correlated these MRI findings to voice parameters. We hypothesized that poor voice outcome would correlate to altered vocal cord structure and function on MRI.

## METHODS

All patients from the LTS outpatient follow-up clinic were approached to participate in this study. Inclusion criteria were as follows: history of congenital or acquired LTS and history of LTR or CTR between 1994 (start of airway reconstructions at our institution) and 2018. Exclusion criteria were as follows: age below 6 years, inability to undergo/follow MRI instructions, current severe lung infection, oxygen usage, and presence of a tracheal cannula. Healthy volunteers without airway, vocal, or pulmonary comorbidities were included to give an impression of the healthy upper airways on MRI. Patients and healthy volunteers were not matched for age and gender. The study was approved by the local medical ethics committee (MEC2018-013) and written informed consent was obtained from all study participants. Anatomical data were previously reported.<sup>17</sup>

### Clinical Status

The following data were collected from the electronic patient file: acquired or congenital stenosis, Cotton-Myer Grade of stenosis,<sup>18</sup> location of stenosis (posterior glottis/subglottis/both), tracheal cannula before repair (Yes/No), type of reconstruction (ss-LTR/ds-LTR/CTR, including use of anterior and/or posterior cartilage graft), and age at reconstruction.

### (Pediatric) Voice Handicap Index

To assess voice-related quality of life, all parents of patients younger than 16 years were asked to fill out the validated pediatric Voice Handicap Index (pVHI), while patients of 16 years and older filled out the VHI independently.<sup>19-21</sup> The (p)VHI includes questions on the functional (F), physical (P), and emotional (E) effects of dysphonia on daily life. In addition, the pVHI includes a question on the talkativeness of the child (0: quiet

listener; to 7: very talkative) and a visual analogue scale (VAS) on voice quality (0: normal voice, to 10: severely affected voice). A higher (p)VHI score represents a worse voice-related quality of life. Due to a difference in maximum scores between the pVHI and VHI, scores are also presented as a percentage of the maximum score (pVHI: percentage of 28 (F), 36 (P), 28 (E), and 92 (total score); VHI: a percentage of 40 (F, P, E) and 120 (total score)).

### Dysphonia Severity Index

Voice quality of patients and healthy volunteers was measured using the Dysphonia Severity Index (DSI), recorded with a head microphone and audio interface (Focusrite Scarlett Solo, United Kingdom), and the analysis was performed using the PRAAT software (version 6.0, University of Amsterdam, The Netherlands).<sup>22</sup> The DSI consists of the highest frequency (Hz), lowest intensity (dB), maximum phonation time (MPT)(s), and jitter (%). We used a head microphone, with a smaller mouth-to-microphone distance compared to a table microphone as used in the original study,<sup>23</sup> therefore we applied a translational factor of  $-7.5$  dB on the lowest intensity. Total score was calculated according to the original formula, with a lower score representing a worse voice.<sup>22</sup>

### Magnetic Resonance Imaging Protocol

A 30-min upper airways MRI protocol was developed and performed on a 3T scanner (Discovery MR750, GE Healthcare, Milwaukee, WI, USA) using a dedicated and flexible 6 channel carotid coil (Machnet B.V., Rhoden, The Netherlands and Flick Engineering B.V., Winterswijk, The Netherlands).<sup>24</sup> The MRI protocol has previously been published.<sup>17</sup> Briefly, the protocol consisted of static two-dimensional (2D) morphological sequences with high in-plane resolution in three planes ( $0.5 \times 0.5$  (in plane)  $\times 2$  mm (slice thickness)) and 2D and 3D dynamic sequences with a temporal resolution of 330 ms. The dynamic sequences consisted of 2D axial sequences during trained manoeuvres of inspiration and “AAA” phonation separately, and a 3D cine-MRI during a manoeuvre of 2 s inspiration followed by 6 s “AAA” phonation. These sequences were repeated until at least one of the (2D or 3D) manoeuvres was performed correctly.

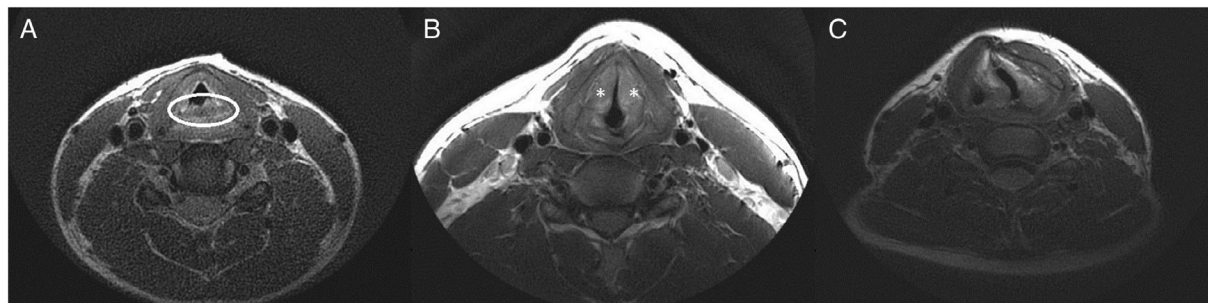


Fig. 1. Example of the magnetic resonance imaging analysis of the static images showing (A) arytenoid prolapse, (B) vocal cord thickening, and (C) vocal cord deviation.

Image analysis was performed using Advantage Windows Server (version 2.0, GE Healthcare, Milwaukee, WI, USA) as follows (Fig. 1, online supplement 1):

Morphology assessment consisted of the presence of arytenoid prolapse defined as protrusion of these structures into the airway lumen, altered positioning of the vocal cords defined as deviation from the normal triangular shape between the anterior commissure and the vocal cords, and/or vocal cord thickening. Vocal cord thickness was measured as diameters at three consecutive levels from posterior (at the level of the arytenoids) to anterior (at the level of the anterior commissure). Furthermore, the total square area of the vocal cords was measured. Airway lumen area and anterior–posterior and transversal diameters were measured between the vocal cords. Area and diameter measurements were corrected for height in meters.

Tissue characterization assessment consisted of the evaluation of T2-weighted images on the presence of tissue thickening and/or hyperintense signal, as signs of fibrosis, edema, or a combination of both.<sup>17</sup>

Dynamic assessment consisted of the evaluation of correct performance of vocal manoeuvres, defined as any form of vocal cord adduction during phonation on 2D dynamic images, and as any vocal cord movement on 3D dynamic images. Images were evaluated by scoring completeness of vocal cord adduction (complete/incomplete) and symmetry (symmetrical/ asymmetrical) and by quantitative measurement of the residual area between the vocal cords during phonation. In case 2D dynamic manoeuvres were not performed correctly, no area measurements were performed.

The first observer (B.E.) performed measurements twice on 12 randomly selected MRIs to assess intraobserver variability. Interobserver reproducibility of measurements was tested by reanalyzing 12 MRIs by a researcher trained in evaluating upper airways MRI.

## Statistics

Data analysis was performed using SPSS Statistics (version 25, IBM SPSS, Chicago, IL, USA). Data are presented as mean  $\pm$  SD or median (range or interquartile range). Patients and healthy volunteers were compared using the parametric *t*-test for normally distributed data and the Mann–Whitney *U* test for non-normally distributed data. Correlations were tested with the Pearson's rho (*r*) for normally distributed, Spearman's rho (*r<sub>s</sub>*) for not normally distributed data, and binary logistic regression for categorical data, for all correlations the uncorrected (p)VHI outcome was used. Intracorrelation and intercorrelation were calculated with the intraclass correlation coefficient. Correction for multiple testing was not performed and a significance level of 0.05 is assumed.

## RESULTS

Patient and healthy volunteer characteristics are presented in Table I. Forty-eight patients and 11 healthy volunteers were included with a mean age of 14.4 (range 7.5–30.7) and 15.9 (range 8.2–28.8) years.

Total score was higher for the pVHI than for the VHI, with highest (most impaired) items scored being the functional and physical subscale for the pVHI and the physical and emotional subscale for the VHI (Table II). Parents of patients younger than 16 years scored significantly worse on the functional and nonsignificantly worse on the physical subscale, compared to patients of 16 years and older.

Patients showed a significantly lower total DSI score than healthy volunteers ( $-2.6 \pm 2.4$  vs.  $0.68 \pm 2.9$ ,  $P < .001$ ), showing a decreased function on all parameters but lowest intensity (online supplement 2).

## Magnetic Resonance Imaging

In summary, static imaging showed vocal cord thickening in the majority of patients (80.9%).<sup>17</sup> In 12 patients (25.5%), signs of fibrosis located at the vocal cords were seen; in 6 patients (12.8%), signs of edema located at the vocal cords were seen; and in 9 patients (19.1%), a combination of fibrosis and edema was seen. Furthermore, impaired vocal cord movement was seen on dynamic MRI in 34 patients (72.3%) and none of the healthy volunteers. The most frequent finding was incomplete adduction of the vocal cords during phonation ( $n = 29$ , 61.7%). Eleven patients (23.4%) showed unilateral impaired vocal cord movement. Thirty-five patients and nine healthy volunteers had correctly performed 2D dynamic images available for quantitative analyses, showing a nonsignificant larger residual area between the vocal cords during phonation, and significantly less change in lumen area between inspiration and phonation in patients compared to healthy volunteers.<sup>17</sup>

For the current study, we executed additional measurements on vocal cord thickening, showing an increase in vocal cord diameters, but no increase in vocal cord area. Patients showed collapse of the supraglottic and subglottic region in 59.6% and 21.3%, respectively, during phonation. Conversely, only 30% of healthy volunteers showed collapse of the supraglottic and none showed collapse of the subglottic region during phonation. MRI findings are summarized in online supplement 3, Figure 2 shows a still of a 2D dynamic sequence of a patient.

## Correlations

Correlations between patient characteristics and the residual lumen area between the vocal cords during phonation as seen on MRI are presented in online supplement 4. The presence of glottic scarring prior to airway reconstruction did not correlate to the area between the vocal cords during phonation on MRI. Furthermore, vocal cord lumen area during phonation on MRI was not correlated to the type of airway reconstruction. Nor did the type of cartilage grafts (anterior and/or posterior) placed have an effect on dynamic MRI findings; however, in our cohort few patients had only one graft.

Correlations between MRI findings and voice outcome are presented in Table III. The presence of vocal cord thickening on MRI was significantly correlated to a decrease in total DSI score but not (p)VHI. No

Table I.  
Patient and Healthy Volunteers Characteristics.

	Patients (n = 48)	Volunteers (n = 11)	P value
Age at MRI (years)	14.4 (range 7.5–30.7)	15.9 (range 8.2–28.8)	.92
Gender (% female)	52.1	36.4	.37
Weight (kg)	45.2 (IQR 34.5–62.3)	60.8 (IQR 31.6–74.0)	.34
Height (meter)	1.6 (IQR 1.4–1.7)	1.7 (IQR 1.4–1.8)	.34
Type of stenosis (%)	Congenital 6.3 Acquired 93.8		
Cotton-Myer grade of stenosis (%)			
Grade I	8.3		
Grade II	31.3		
Grade III	56.3		
Grade IV	4.2		
Location of stenosis (%)	Posterior glottis 22.9 Subglottis 35.4 Posterior glottis and subglottis 41.7		
Tracheal cannula before repair (%)	79.2		
Type of reconstruction (%)	ss-LTR 87.5 ds- LTR 4.2 CTR 8.3		
Type of graft (%*)	Anterior 4.7 Posterior 9.3 Both 86.0		
Age at reconstruction (years)	2.2 (IQR 1.1–4.5)		
Years since reconstruction	11.5 ± 4.6		

Data are presented as percentage, mean ± standard deviation or median (range or interquartile range).

\*Percentage within the ss- and ds-LTR group.

CTR = cricotracheal resection; ds-LTR = double-stage laryngotracheal reconstruction; IQR = interquartile range; ss-LTR = single-stage laryngotracheal reconstruction.

Table II.  
(Pediatric) Voice Handicap Index.

	pVHI, n = 31; 64.6%	VHI, n = 17; 35.4%	
Talkativeness	4.3 ± 1.9	–	–
Functional	10.6 ± 6.0	6.6 ± 5.0	*P < .001
Physical	37.9 ± 21.5 12.0 (7.0–18.0)	16.5 ± 12.5 6.0 (1.0–4.0)	.07
Emotional	33.3 (19.4–50.0) 4.0 (1.0–9.0)	15.0 (2.5–35.0) 5.0 (1.0–12.0)	.86
Voice quality (VAS)	14.3 (3.6–32.1) 3.8 ± 3.0	12.5 (2.5–30.0) –	–
Total score	28.2 ± 17.5 33.7 (16.3–41.3)	21.6 ± 18.0 14.2 (7.1–23.8)	*P = .02

The subscales talkativeness and voice quality (VAS) were only scored in the pVHI. Data are presented as percentage or mean ± standard deviation, (sub) scores presented as a percentage of maximum amount of points scores are in italic.

\*P < .05.

VAS = Visual Analogue Scale; VHI = Voice Handicap Index.

correlations between tissue characterization and DSI nor (p)VHI were found. The presence of incomplete vocal cord adduction on MRI was strongly correlated to a decrease in DSI score. The degree of adduction impairment, expressed as the residual lumen area between the vocal cords during phonation, was significantly correlated to total DSI, but did not have an effect on (p)VHI score. Sub-analyses between the degree of vocal cord adduction and

DSI score showed that a bigger area between the vocal cords during phonation was significantly correlated to an increase in jitter subscore ( $r = 0.31$ ,  $P = .04$ ), but none of the other subscores (MPT  $r = -0.09$ ,  $P = .58$ , highest frequency  $r = -0.16$ ,  $P = .30$ , lowest intensity  $r = -0.05$ ,  $r = 0.73$ ). The presence of supra- or subglottic collapse during phonation on MRI did not have an effect on DSI or (p)VHI.

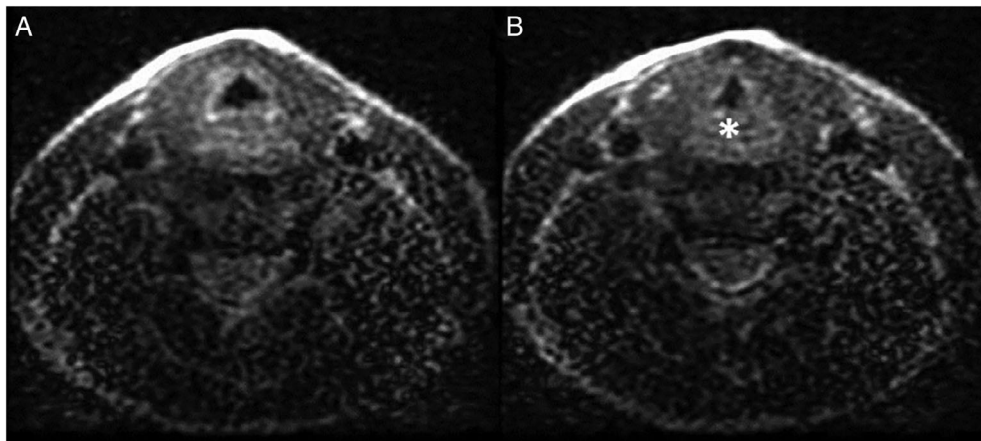


Fig. 2. Axial 2D dynamic image of the upper airways of a patient with a history of acquired LTS, post ss-LTR with an anterior and posterior graft during inspiration (A) showing complete abduction of the vocal cords and phonation (B) showing decreased lumen but incomplete closure of the vocal cords with prolapse of the arytenoids (asterisk). LTR, laryngotracheal reconstruction; LTS, laryngotracheal stenosis

Table III.  
Correlations between MRI, and (p)VHI and DSI.

	pVHI (n = 31)	VHI (n = 17)	DSI (n = 59)
<b>Static MRI</b>			
Vocal cord thickening	1.96 (0.90–1.03); <i>P</i> = .22	1.00 (0.93–1.06); <i>P</i> = .88	0.75 (0.58–0.96); <b><i>P</i> = .02</b>
Abnormal vocal cord positioning	1.01 (0.94–1.09); <i>P</i> = .73	1.04 (0.98–1.10); <i>P</i> = .22	0.79 (0.61–1.04); <i>P</i> = .09
Arytenoid prolapse	1.01 (0.96–1.06); <i>P</i> = .62	0.98 (0.93–1.04); <i>P</i> = .49	0.88 (0.71–1.08); <i>P</i> = .21
Presence of fibrosis	1.04 (0.99–1.09); <i>P</i> = .17	0.97 (0.92–1.03) <i>P</i> = .29	0.95 (0.74–1.21) <i>P</i> = .66
Presence of edema	1.05 (0.99–1.100); <i>P</i> = .10	1.05 (0.98–1.12); <i>P</i> = .16	0.90 (0.69–1.17); <i>P</i> = .42
<b>Dynamic MRI</b>			
Incomplete vocal cord adduction	1.04 (0.98–1.10); <i>P</i> = .16	0.95 (0.89–1.01); <i>P</i> = .12	0.65 (0.48–0.88); <b><i>P</i> = .006</b>
Supraglottic collapse	1.03 (0.98–1.09); <i>P</i> = .25	0.98 (0.95–1.04); <i>P</i> = .48	0.93 (0.77–1.13); <i>P</i> = .48
Subglottic collapse	1.03 (0.97–1.09); <i>P</i> = .37	1.00 (0.92–1.08); <i>P</i> = .90	0.91 (0.71–1.17); <i>P</i> = .46
Unilateral vocal cord movement	1.00 (0.95–1.06); <i>P</i> = .95	1.00 (0.95–1.07); <i>P</i> = .12	0.97 (0.71–1.33); <i>P</i> = .84
Area between the vocal cords during phonation	<i>r</i> = -0.15; <i>P</i> = .51	<i>r</i> = -0.46; <i>P</i> = .12	<i>r</i> = -0.31; <b><i>P</i> = .04</b>

Data are presented as expected odds (confidence interval) or correlation coefficient (*r*). *P* values in bold are significant (<.05). DSI = Dysphonia Severity Index; MRI = magnetic resonance imaging; (p)VHI = pediatric Voice Handicap Index.

Intravariability and intervariability analyses showed good to excellent consistency for all static and dynamic MRI measurements, except for the presence of complete abduction or adduction (online supplement 5).

## DISCUSSION

This is the first study correlating MRI of the vocal cords to voice outcome in patients after airway reconstruction for LTS. Our findings show good correlation between MRI and DSI and hereby show the potential of MRI to image the vocal cords in a non-invasive and quantitative matter. In addition, we confirm the impact of consecutive altered anatomy and fibrosis of the vocal tract leading to dysphonia in the post-LTS population.

The gold standard to evaluate the vocal tract is videostroboscopy.<sup>2</sup> An important downside, however, is that the data obtained is nonquantified. In the current study, on static images, we were able to quantify both

vocal cord thickening correlated to DSI outcome, as well as areas and diameters at the level of the vocal cords. Quantitative analyses revealed increased vocal cord diameters in the majority of patients but no increase in total vocal cord area, implicating thickening and shortening of the vocal cords. This is possibly related to altered laryngeal architecture after surgery, extensive scarring of the larynx, or the loss of vocal cord tension following surgery, all leading to dysphonia in LTS patients after airway reconstruction.

We could easily visualize and score impaired vocal cord movement on dynamic MRI in almost all patients from the age of 7 years and above. Previous studies have shown MR imaging of nonsedated children to be possible from the age of 6 years.<sup>12</sup> The vocal cord movement was evaluated by both subjective scoring and quantitative measurements. The quantitative measurements of vocal cord lumen areas were better reproducible than scoring completeness of vocal cord abduction and adduction, since

it proved challenging to subjectively score vocal cord movement in combination with thickening and deviation of the vocal cords. Conversely to videostroboscopy, we were not able to visualize vocal cord vibrations with dynamic MRI, since it has a temporal resolution of 330 ms. This is a major downside of the MRI when compared to videostroboscopy. Whether this results in missed diagnosis of clinically relevant dysphonia in this patient population should be focused on in future research.

An important benefit of imaging methods such as CT and MRI is the ability to visualize the vocal cords in a three-dimensional plane, therefore less influenced by the strongly altered anatomy such as severe supraglottic collapse.<sup>15,16,25</sup> Supraglottic constriction during phonation is a common compensatory mechanism in patients with dysphonia, but can also be a sign of architectural distortion after LTS repair.<sup>10,26,27</sup> We could identify supraglottic collapse on MRI in the majority of our patients, and in contrast to videostroboscopy, the presence of supraglottic collapse did not limit the visualization of the vocal cords or the assessment of vocal cord movement.

An imaging modality of the vocal cords that can distinguish between fibrosis, edema, and inflammation could aid the airway surgeon greatly. However, to date, this is not possible. MRI could possibly overcome this limitation with T1- and T2-weighted imaging, based on water content of tissue, and diffusion weighted imaging (DWI), based on free movement of hydrogen molecules corresponding to cellular swelling or increased tissue density.<sup>28,29</sup> Although in our previous study tissue alterations on T2-weighted imaging correlated to impaired vocal cord movement on MRI, we did not find a correlation between tissue alterations on and DSI nor (p)VHI in the current study. Therefore, MRI seems not yet sensitive enough to identify clinically relevant tissue alterations of the vocal cords. Further protocol refinement is needed to improve MRI capability to detect inflammation and will be the aim of future research.

The majority of imaging studies of the vocal cords has been done using CT.<sup>15,16,25</sup> The most important downside of CT compared to MRI is exposure to, albeit low, ionizing radiation.<sup>16</sup> Comparison studies between dynamic CT and MRI have never been reported, but our MRI study shows excellent identification of the anatomical structures, and thereby closure defects of the vocal cords, comparable to previous CT studies. Besides, MRI is known to be superior over CT in terms of identification of soft tissue structures, and might therefore better identify various structures of the larynx such as the arytenoids and true and false vocal cords.<sup>12</sup> In addition, although vocal cord dynamics have been imaged on MRI before, this has never been done in the current population and this is the first study making a comparison to voice outcome.<sup>13,14,25</sup>

In our study population, MRI findings correlated best to voice outcome measured by DSI. The DSI is an objective voice measurement, but can entail limitations in case of severe dysphonia. Examples of this are type II and III voice signals influencing jitter outcome.<sup>30</sup> Although this was also present in our population, our

jitter outcomes were within the expected range and the DSI also significantly differed from healthy volunteers on other subscales. Therefore, we do not believe that this has impacted the correlations found in the current study.

The limited correlations between MRI findings and voice-related quality of life on (p)VHI are most likely because these are subjective measurements investigating only the burden and not the severity of dysphonia. We also found parents reporting a worse voice-related quality of life compared to patients. This is in line with previous quality of life research, also in LTS patients, where parents tend to score lower quality of life compared to patients.<sup>31,32</sup> The difference in voice-related quality of life between parents and patients was not observed for the emotional subscore. Patients reported a high impact of dysphonia on the emotional quality of life, represented by questions such as “I am tense when talking to others because of my voice” and “People seem irritated by my voice”.<sup>33</sup> These findings are in line with our clinical experience, where patients mainly complain of the increased burden of dysphonia on their social life during adolescence. This emphasizes the importance of long-term follow-up of dysphonia after airway reconstruction for LTS, and shows that attention should be paid to voice-related quality of life and differences between patient and parent reporting.<sup>4</sup>

The most important strength of this study is that it is the first study correlating MRI findings in patients after airway reconstruction for LTS to voice outcome. A weakness of this study is the small study population, with limited patients having undergone a CTR and almost all patients having undergone placement of a posterior cartilage graft during LTR. This might have led to a lack of correlation between voice outcome and MRI findings, and clinical parameters such as type of surgery or type of cartilage grafts placed and MRI findings. However, these findings also emphasize the complex and multifactorial relationship between post-surgical LTS and dysphonia. On the one hand, dysphonia is caused by the presurgical anatomy such as glottic involvement of the stenosis. On the other hand, both LTR and CTR can cause dysphonia in itself. In LTR, the placement of anterior and, more importantly posterior cartilage grafts can prevent complete abduction and adduction of the vocal cords.<sup>2,10,20,27</sup> In CTR, the removal of the cricothyroid muscle can cause dysphonia complaints.<sup>2,10,34</sup> Another limitation of this study is the lack of comparison between MRI and the current gold standard to image the vocal cords, videostroboscopy. Comparison between these two modalities was not the primary aim of our research but will be the subject of follow-up research. In addition, due to the experimental character of our research, we did not have reference values of our quantitative measurements available.

In conclusion, this is the first study comparing MRI of the vocal cords to voice outcome in patients after airway reconstruction for LTS. Our MRI protocol can safely and feasibly image the vocal cords in children from the age of 7 years on and can easily be adopted in all institutions. MRI has the additional benefit of extensive anatomical imaging of the upper airways without ionizing-



radiation. Further technical refinements such as protocol improvement will contribute to the usefulness of MRI for imaging of the upper airways. In addition, future research should focus on direct comparison between different modalities to evaluate the voice. Our study suggests MRI as a tool for extensive imaging of upper airways' structure and function in the follow-up of LTS patients.

## Acknowledgments

The authors would like to acknowledge Eleni Rosalina Andrinopoulou for the statistical support on the article and Wytse van den Bosch for his help with the inter-observer analysis.

## Author contributions

B.E. contributed to the design of the work, data collection and analysis, drafted the manuscript, and gave final approval to the manuscript; M.H. contributed to the design of the work and data collection, critically revised the manuscript, and gave final approval to the manuscript; P.C. contributed to the design of the work, data analysis, critically revised the manuscript, and gave final approval to the manuscript; H.T. contributed to the design of the work, critically revised the manuscript, and gave final approval to the manuscript; P.W. contributed to the design of the work, critically revised the manuscript, and gave final approval to the manuscript; B.P. contributed to the design of the work and data analysis, critically revised the manuscript, and gave final approval to the manuscript.

## REFERENCES

1. Jefferson ND, Cohen AP, Rutter MJ. Subglottic stenosis. *Semin Pediatr Surg* 2016;25:138–143.
2. Monnier P. *Pediatric Airway Surgery Management of Laryngotracheal Stenosis in Infants and Children*. Berlin, Heidelberg: Springer Berlin Heidelberg; 2011.
3. Pullens B, Hoeve LJ, Timmerman MK, van der Schroeff MP, Joosten KF. Characteristics and surgical outcome of 98 infants and children surgically treated for a laryngotracheal stenosis after endotracheal intubation: excellent outcome for higher grades of stenosis after SS-LTR. *Int J Pediatr Otorhinolaryngol* 2014;78:1444–1448.
4. Pullens B, Hakkesteegt M, Hoeve H, Timmerman M, Joosten K. Voice outcome and voice-related quality of life after surgery for pediatric laryngotracheal stenosis. *Laryngoscope* 2017;127:1707–1711.
5. Pullens B, Pijnenburg MW, Hoeve HJ, et al. Long-term functional airway assessment after open airway surgery for laryngotracheal stenosis. *Laryngoscope* 2016;126:472–477.
6. Cohen W, Wynne DM, Lloyd S, Townsley RB. Cross-sectional follow-up of voice outcomes in children who have a history of airway reconstruction surgery. *Clin Otolaryngol* 2018;43:645–651.
7. Baker S, Kelchner L, Weinrich B, et al. Pediatric laryngotracheal stenosis and airway reconstruction: a review of voice outcomes, assessment, and treatment issues. *J Voice* 2006;20:631–641.
8. de Alarcon A. Voice outcomes after pediatric airway reconstruction. *Laryngoscope* 2012;122:S84–S86.

9. Geneid A, Pakkasjarvi N, Aherto A, et al. Outcomes of early infancy laryngeal reconstruction on health- and voice-related quality of life. *Int J Pediatr Otorhinolaryngol* 2011;75:351–355.
10. Kelchner LN, Miller CK. Current research in voice and swallowing outcomes following pediatric airway reconstruction. *Curr Opin Otolaryngol Head Neck Surg* 2008;16:221–225.
11. Zacharias SR, Weinrich B, Brehm SB, et al. Assessment of vibratory characteristics in children following airway reconstruction using flexible and rigid endoscopy and Stroboscopy. *JAMA Otolaryngol Head Neck Surg* 2015;141:882–887.
12. Elders B, Hermelijn SM, Tiddens H, Pullens B, Wielopolski PA, Ciet P. Magnetic resonance imaging of the larynx in the pediatric population: a systematic review. *Pediatr Pulmonol* 2019;54:478–486.
13. Baki MM, Menys A, Atkinson D, et al. Feasibility of vocal fold abduction and adduction assessment using cine-MRI. *Eur Radiol* 2017;27:598–606.
14. Ahmad M, Dargaud J, Morin A, Cotton F. Dynamic MRI of larynx and vocal fold vibrations in normal phonation. *J Voice* 2009;23:235–239.
15. Bergeron M, Fleck RJ, Middlebrook C, et al. Preliminary assessment of dynamic voice CT in post-airway reconstruction patients. *Otolaryngol Head Neck Surg* 2018;159:516–521.
16. Bergeron M, Fleck RJ, Zacharias SRC, Tabangin ME, de Alarcon A. The value of dynamic voice CT scan for complex airway patients undergoing voice surgery. *Ann Otol Rhinol Laryngol* 2019;128:885–893.
17. Elders B, Ciet P, Tiddens H, van den Bosch W, Wielopolski P, Pullens B. MRI of the upper airways in children and young adults: the MUSIC study. *Thorax* 2021;76:44–52.
18. Myer CM 3rd, O'Connor DM, Cotton RT. Proposed grading system for subglottic stenosis based on endotracheal tube sizes. *Ann Otol Rhinol Laryngol* 1994;103:319–323.
19. Zur KB, Cotton S, Kelchner L, Baker S, Weinrich B, Lee L. Pediatric voice handicap index (pVHI): a new tool for evaluating pediatric dysphonia. *Int J Pediatr Otorhinolaryngol* 2007;71:77–82.
20. Veder L, Pullens B, Timmerman M, Hoeve H, Joosten K, Hakkesteegt M. Reliability and validity of the Dutch pediatric voice handicap index. *Int J Pediatr Otorhinolaryngol* 2017;96:15–20.
21. Hakkesteegt MM, Wieringa MH, Gerritsma EJ, Feenstra L. Reproducibility of the Dutch version of the voice handicap index. *Folia Phoniatr Logop* 2006;58:132–138.
22. Wuyts FL, De Bodt MS, Molenberghs G, et al. The dysphonia severity index: an objective measure of vocal quality based on a multiparameter approach. *J Speech Lang Hear Res* 2000;43:796–809.
23. De Bodt MS, Wuyts FL, Van de Heyning PH, Croux C. Test-retest study of the GRBAS scale: influence of experience and professional background on perceptual rating of voice quality. *J Voice* 1997;11:74–80.
24. Zhang Q, Coolen BF, van den Berg S, et al. Comparison of four MR carotid surface coils at 3T. *PLoS One* 2019;14:e0213107.
25. Faust RA, Remley KB, Rimell FL. Real-time, cine magnetic resonance imaging for evaluation of the pediatric airway. *Laryngoscope* 2001;111:2187–2190.
26. de Alarcon A, Brehm SB, Kelchner LN, Meinzen-Derr J, Middendorf J, Weinrich B. Comparison of pediatric voice handicap index scores with perceptual voice analysis in patients following airway reconstruction. *Ann Otol Rhinol Laryngol* 2009;118:581–586.
27. Kelchner LN, Weinrich B, Brehm SB, Tabangin ME, de Alarcon A. Characterization of supraglottic phonation in children after airway reconstruction. *Ann Otol Rhinol Laryngol* 2010;119:383–390.
28. Wang J, Takashima S, Takayama F, et al. Head and neck lesions: characterization with diffusion-weighted echo-planar MR imaging. *Radiology* 2001;220:621–630.
29. Chavhan GB, Alsabban Z, Babyn PS. Diffusion-weighted imaging in pediatric body MR imaging: principles, technique, and emerging applications. *Radiographics* 2014;34:E73–E88.
30. Titze IR, Liang H. Comparison of Fo extraction methods for high-precision voice perturbation measurements. *J Speech Hear Res* 1993;36:1120–1133.
31. Eiser C, Varni JW. Health-related quality of life and symptom reporting: similarities and differences between children and their parents. *Eur J Pediatr* 2013;172:1299–1304.
32. Pullens B, Dulfer K, Buysse CM, Hoeve LJ, Timmerman MK, Joosten KF. Long-term quality of life in children after open airway surgery for laryngotracheal stenosis. *Int J Pediatr Otorhinolaryngol* 2016;84:88–93.
33. Jacobson BH, Johnson A, Grywalski C, et al. The voice handicap index (VHI). *Am J Speech Lang Pathol* 1997;6:66–70.
34. Clunie GM, Kinshuck AJ, Sandhu GS, Roe JWG. Voice and swallowing outcomes for adults undergoing reconstructive surgery for laryngotracheal stenosis. *Curr Opin Otolaryngol Head Neck Surg* 2017;25:195–199.