






SEVERE CALCIUM ONE SOLUTION

 **DUAL-ACTION**  **VERSATILE**  **PROVEN**



ONLY THE DIAMONDBACK 360[®]
CORONARY ORBITAL ATHERECTOMY
SYSTEM BRINGS IT ALL TOGETHER

Vascular complications with a plug-based vascular closure device after transcatheter aortic valve replacement: Predictors and bail-outs

Maarten P. van Wiechen MD  | Herbert Kroon MD  | Thijmen W. Hokken MD |
 Joris F. Ooms MD  | Marjo J. de Ronde-Tillmans  | Joost Daemen MD, PhD  |
 Peter P. de Jaegere MD, PhD | Nicolas M. Van Mieghem MD, PhD

Department of Cardiology, Erasmus University Medical Center, Rotterdam, Netherlands

Correspondence

Nicolas M. Van Mieghem MD, PhD,
 Department of Interventional Cardiology,
 Thoraxcenter, Erasmus MC, Office Nt 645, Dr
 Molewaterplein 40 3015 GD Rotterdam,
 Netherlands.
 Email: n.vanmieghem@erasmusmc.nl

Abstract

Background: The MANTA vascular closure device (VCD) is dedicated to large bore access closure and associated with favorable results in selected study populations. Anatomical predictors for access site complications are lacking.

Aim: To evaluate MANTA in a real-world population and identify predictors for vascular complications.

Methods: All patients undergoing transfemoral transcatheter aortic valve replacement (TAVR) between January 2016 and May 2020 with MANTA closure were included. Baseline characteristics were collected, pre-procedural computed tomography and post-deployment femoral angiograms were analyzed for anatomical differences. The primary endpoint was a composite of access site related major and minor vascular complications at 30 days follow-up according to the VARC-2 definitions. Secondary endpoints included bleeding, time to hemostasis, procedural length and incomplete arteriotomy closure or arterial occlusion by angiography. A Cox proportional hazards model was used to compare all-cause mortality for patients with and without an access site complication.

Results: The 512 patients underwent TAVR with MANTA access closure. Median age was 80 (IQR 75–85), 53% was male, median BMI was 26.4 kg/m² (IQR 23.4–29.7). Access site related major- or minor vascular complication occurred in 20 (4%) and 23 (4%) of patients respectively. Median time to hemostasis was 42 s (IQR 28–98). Post deployment angiogram showed an occlusion in 24 patients (5%), incomplete closure in 60 patients (12%) or both in three patients (1%). Of these 87 patients, 36 (41%) had a vascular complication. Femoral artery diameter (OR 0.70 [0.53–0.93]), low- (OR 3.47 [1.21–10.00]) and high (OR 2.43 [1.16–5.10]) arteriotomies were independent predictors for vascular complications.

Conclusion: In this contemporary TAVR population, access-site related complications occurred in 8% of patients and were mainly due to percutaneous closure device failure. Small artery diameter and off-target punctures were independent predictors.

This is an open access article under the terms of the Creative Commons Attribution-NonCommercial-NoDerivs License, which permits use and distribution in any medium, provided the original work is properly cited, the use is non-commercial and no modifications or adaptations are made.

© 2021 The Authors. *Catheterization and Cardiovascular Interventions* published by Wiley Periodicals LLC.

KEYWORDS

aortic valve disease, mechanical circulatory support, percutaneous intervention, vascular complications

1 | INTRODUCTION

Transcatheter aortic valve replacement (TAVR) is a valuable treatment option for patients with severe aortic stenosis across the entire surgical risk spectrum.¹⁻⁶ Over the past decade, transcatheter heart valve (THV) design iterations, increased operator experience and centralization of care in heart valve centers of excellence have decreased incidences of vascular complications after TAVR.^{7,8} Nonetheless, major vascular complications remain relevant with a 2-15% incidence depending on the patient profiles at risk.^{3,5,6,9} The majority of these complications involve the large bore sheath access site or ipsilateral iliac artery and include vessel rupture, perforation, occlusion, dissection and pseudo-aneurysms.^{10,11} Vascular complications are not benign and could form a limitation for younger patients undergoing TAVR, considering their more active lifestyles.

MANTA (Teleflex, Wayne, PA, USA) is a plug-based VCD, dedicated to large bore vascular closure. It consists of a poly-lactic glycolic toggle within the artery attached to a bovine collagen plug, exterior to the vessel wall, which is tampered down by a stainless steel lock.¹² After TAVR and endovascular aneurysm repair MANTA has been shown to be safe and effective: major vascular complications occurred in 1.9-4.2% of cases and median time to hemostasis varied from 19-24 s.^{13,14} However, these trials were performed in highly selected populations and do not per se reflect the contemporary TAVR population with a high burden of peripheral vascular disease and morbid obesity.

Goal of the present study was to evaluate safety and efficacy of MANTA closure in a contemporary TAVR population and to identify predictors for access site vascular complications.

2 | METHODS

2.1 | Study population and investigational device

All patients who had MANTA closure of the femoral artery after TAVR in the Erasmus University Medical Center from January 2016 until May 2020 were included. Patients were discussed by the local multidisciplinary heart team and consented to data collection upon their first outpatient visit. All data were prospectively collected and stored in an anonymized secured database. The study was conducted in accordance with the principles of the Declaration of Helsinki and did not fall under the scope of the Medical Research Involving Human Subjects Act per Institutional Review Boards' review.

MANTA mode of operations is described elsewhere.¹² In brief, prior to large sheath insertion the distance of the subcutaneous tract to the vessel wall is measured with a dedicated sizing tool. At the end of the

procedure, the large sheath is exchanged for a dedicated MANTA sheath to receive the toggle-plug assembly. The entire unit is then removed up to the predetermined arteriotomy depth and the puncture site is sandwiched between the toggle and plug, which are connected through a radiopaque stainless-steel lock. MANTA is available in a 14 Fr and 18 Fr version for 10-14F and 14-22F outer diameter sheaths respectively.¹²

2.2 | Study procedures

All patients underwent preprocedural planning with multislice CT-scanning. The 3mensio (Pie Medical, Maastricht, NL) software was used to analyze the iliofemoral arterial tree, including minimal diameter and calcifications.

Femoral punctures were ultrasound guided: the femoral bifurcation was identified and the actual puncture was obtained in real-time in a segment of the common femoral artery without anterior wall calcification. Of note, no micropuncture technique was involved. During MANTA-deployment target activated clotting time (ACT) was <200 s and systolic blood pressure < 160 mmHg. Nitrates and protamine were used per operator's discretion. After MANTA deployment, a selective femoral angiogram via radial or contralateral femoral arterial access was made under a 30° oblique projection to ensure hemostasis and rule out vascular occlusions.

All post-deployment angiograms were analyzed off-line, the first image after deployment was scored for angiographical success, irrespective of maneuvers performed thereafter. Angiographical success was defined as good flow towards the superficial and deep femoral artery and absence of any extravasation or vascular occlusion. Cases that were equivocal were double-read. Of note, no angiographical success does therefore not per se equal a vascular complication (e.g., most often manual compression would suffice). Additionally, CAAS software (PIE medical, Maastricht, NL) was used to measure the length between the bifurcation and arteriotomy (puncture height) as identified by the radiopaque stainless steel lock of the MANTA device. (Figures 1).

2.3 | Outcomes and definitions

All patients had follow-up visits at 30 days, 1 year and 3 years post TAVR. Adverse events were classified according to Valve Academic Research Consortium-2 (VARC-2) definitions.¹⁵

Calcification of the common femoral artery (CFA) was scored according to longitudinal and circumferential calcium distribution (either none, < 1 cm and < 180°, > 1 cm and < 180° or > 180°). The sheath to femoral artery ratio (SFAR) was defined as the ratio between the minimal diameter of the iliofemoral trajectory by the maximum outer

FIGURE 1 Measuring puncture height using CAAS software. The distance between A and A' was measured in centimeters. Left: puncture above the bifurcation. The radiopaque lock marks where the MANTA was deployed. Right, puncture at the height of the bifurcation [Color figure can be viewed at wileyonlinelibrary.com]

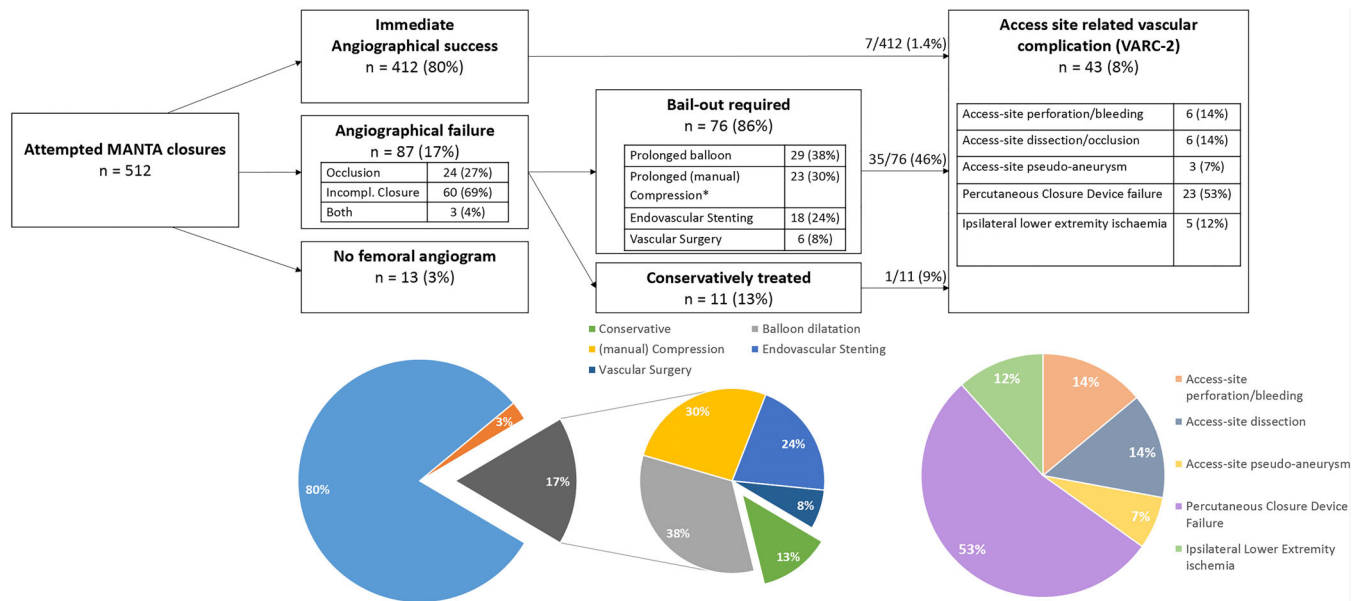
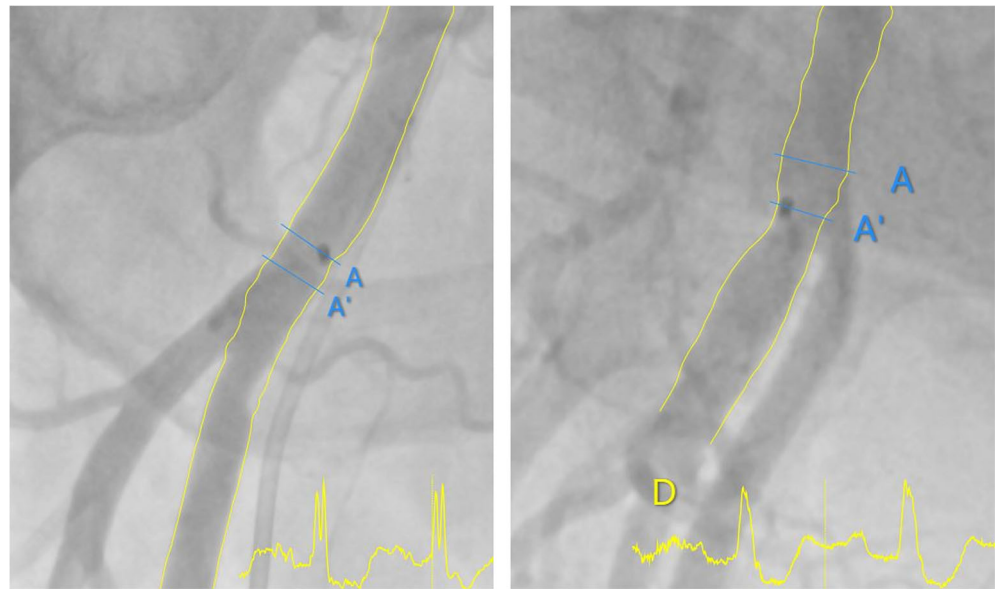


FIGURE 2 Angiographical findings, bail-outs and vascular complications with MANTA. VASC-2, valve academic research consortium-2; VCD, vascular closure device [Color figure can be viewed at wileyonlinelibrary.com]

diameter of the sheath according to the manufacturer. Puncture height was expressed categorically: below the bifurcation, between the bifurcation and 2 cm above and higher than 2 cm. The MANTA-dedicated 8 Fr puncture location dilator was used to measure the length of the subcutaneous track from skin to arteriotomy.

2.4 | Statistical analysis

All descriptive are presented as mean and standard deviation or as median and interquartile range depending on normality; normality was assessed through Shapiro-Wilks test. Categorical variables are presented

as counts and percentages. To compare all-cause mortality at 1 year follow-up for patients with and without an access site complication we performed a Cox proportional hazards model including age and surgical risk (STS-PROM). We reported hazard ratio and 95% confidence interval.

To identify anatomical predictors for clinically relevant vascular complications, we performed multivariate logistic regression with covariates that were based on clinical perspective and had $p < .010$ on univariate analysis. We looked at THV design rather than SFAR considering the use of expandable delivery sheaths. Predictors are described as odds ratio with 95% confidence intervals. All statistical analyses were performed using SPSS version 25.0 (IBM Corporation, Chicago, Illinois).

3 | RESULTS

3.1 | Study population and characteristics

From January 2016 until May 2020, 830 patients underwent transfemoral TAVR of whom 284 (34%) had large bore access closure with double ProGlide (Abbott Vascular, Abbott Park, Illinois) and 512 (62%) with MANTA.

Thirty-day follow-up was complete in all patients. 53% of patients were male, median age was 80 years (IQR 75–85) and median body mass index was 26 kg/m² (IQR 23–30). Median Society of Thoracic Surgeons' score was 3.3% (IQR 2.1–5.4). There was a trend towards smaller

minimal diameter in the access-site complications group (7.1 ± 1.5 vs. 7.5 ± 1.3 , $p = .10$) but no difference in calcification severity in the CFA. Punctures in the access-site complications group were higher above the bifurcation than the reference group (median puncture height 2.3 cm (IQR 1.2–3.7) vs. 1.6 cm (IQR 0.9–2.7), $p = .01$) (Table 1).

3.2 | Clinical outcomes

The primary composite endpoint of any access site related vascular complication occurred in 43 of 512 patients (8%). A major access-site related vascular complication occurred in 20 (4%) of patients: five

TABLE 1 Baseline and procedural characteristics

	Overall n = 512	No access-site complication n = 469	Access-site complication n = 43	p value
Age (years)	80 [75–85]	80 [75–85]	80 [76–85]	.94
Male gender	272 (53)	254 (54)	18 (42)	.17
Body mass index (kg/m ²)	26.4 [23.4–29.7]	26.3 [23.4–29.7]	27.7 [24.5–30.8]	.16
Creatinin (mmol/L)	95 [76–118]	95 [76–118]	102 [82–127]	.24
Hypercholesterolemia	298 (58)	272 (58)	26 (60)	.67
Hypertension	365 (71)	331 (71)	34 (79)	.32
Type 1 or 2 diabetes	151 (29)	139 (30)	12 (28)	.88
Peripheral artery disease	148 (29)	138 (29)	10 (23)	.50
Minimal diameter access site (mm)	7.4 ± 1.3	7.5 ± 1.3	7.1 ± 1.5	.10
Calcification common femoral artery				.35
• None	101 (20)	94 (20)	7 (16)	
• Mild (≤ 1 cm, $\leq 180^\circ$)	207 (40)	192 (41)	15 (35)	
• Moderate (> 1 cm, $\leq 180^\circ$)	86 (17)	75 (16)	11 (26)	
• Severe ($> 180^\circ$)	109 (21)	99 (21)	10 (23)	
European system for cardiac operative risk evaluation II (%)	3.3 [1.9–5.8]	3.3 [1.9–5.8]	3.4 [1.9–5.9]	.87
Society of Thoracic Surgeons' score (%)	3.3 [2.1–5.4]	3.2 [2.1–5.4]	3.6 [2.2–6.1]	.54
Sheath size	16 [14–16]	16 [14–16]	16 [14–16]	.39
Valve used				.35
• Acurate neo	47 (9)	41 (9)	6 (14)	
• Evolut R	110 (21)	101 (22)	9 (21)	
• Evolut pro	112 (22)	106 (23)	6 (14)	
• Lotus edge	46 (9)	39 (8)	7 (16)	
• Sapien 3	195 (38)	180 (38)	15 (35)	
• Jenavalve	2 (0)	2 (0)	0 (0)	
Valve size	26 [25–29]	26 [25–29]	26 [25–27]	.14
Puncture height (cm) ^a	1.7 [0.9–2.8]	1.6 [0.9–2.7]	2.3 [1.2–3.7]	.01
Depth vessel (cm)	5.0 [4.5–6.0]	5 [4.5–6.0]	5.5 [4.5–6.0]	.37
ACT before closure (s)	197 ± 40	196 ± 40	202 ± 50	.42
Systolic BP before closure (mmHg)	134 [120–146]	134 [120–146]	134 [125–150]	.61

Note: Categorical variables are presented as numbers (percentage), continuous variables are presented as median [IQR] or mean ± SD.

Abbreviations: ACT, activated clotting time; BP, blood pressure.

^aOnly punctures above femoral bifurcation.

TABLE 2 Angiographical and clinical outcomes (< 30 days)

Angiographical and clinical outcomes	n = 512
Major vascular complication	33 (6)
• Access site related	20 (4)
Minor vascular complication	44 (9)
• Access site related	23 (4)
Life-threatening bleeding	17 (3)
• Access-site related	5 (1)
Major bleeding	17 (3)
• Access-site related	15 (3)
Minor bleeding	30 (6)
• Access-site related	18 (4)
RBC transfusion	
• 0 units	452 (88)
• 1 unit	17 (3)
• 2 units	27 (5)
• ≥3 units	16 (3)
Median time to hemostasis (s) ^a	42 [28–98]
Median procedural length (min) ^b	66 [50–87]
Angiographical findings	
• Success	412 (80)
• Occlusion	24 (5)
• Incomplete closure	60 (12)
• Occlusion and incomplete closure	3 (1)
• No femoral angiogram	13 (3)

Note: Categorical variables are presented as numbers (percentage), continuous variables are presented as median [interquartile range].

^aData available in 363/512 of cases.

^bData available in 481/512 of cases.

patients had an access-site perforation leading to a life-threatening or major bleeding, eight patients had percutaneous closure device failure leading to life-threatening or major bleeding, five patients had ipsilateral lower extremity ischemia, one patient had a dissection of the superficial femoral artery requiring vascular surgery and one patient had a pseudo-aneurysm that required vascular surgery. A minor access-site related vascular complication occurred in 23 (4%): one patient had an access-site hematoma, 15 patients had percutaneous closure device failure, five patients had an access-site dissection/occlusion and two patients had a pseudo-aneurysm.(Supplementary Table 1).

Median time to hemostasis was 42 s (IQR 28–98). A histogram showing the distribution is available in the supplementary section.

Access site bleeding occurred in 38 of 512 patients (7%). Access site bleedings were life-threatening, major or minor in 1%, 3% and 4% of cases respectively. Red blood cell transfusion was required in 11% of patients: 3% of patients required 1 unit of red blood cells, 5% required 2 units and 3% required more than 3 units of red blood cells (Table 2, Figure 2).

In patients with an access-site related complication 35 (81%) had prolonged hospitalization (> 5 days) and 30-day mortality was 7%. Adjusted for age and surgical risk, during the first year of follow up there was no difference in all-cause mortality between patients with and without an access-site complication (adjusted HR 1.55 [0.61–3.93], p = .36).

3.3 | Angiographical findings and bail-outs

Post-deployment femoral angiography was done in 97% of cases, which confirmed angiographical success in 412 (80%). Nonetheless, seven cases that had unremarkable angiograms had a clinically relevant vascular complication afterwards: three patients had late percutaneous closure device failure presumably due to late dislocation of collagen and/or toggle (one

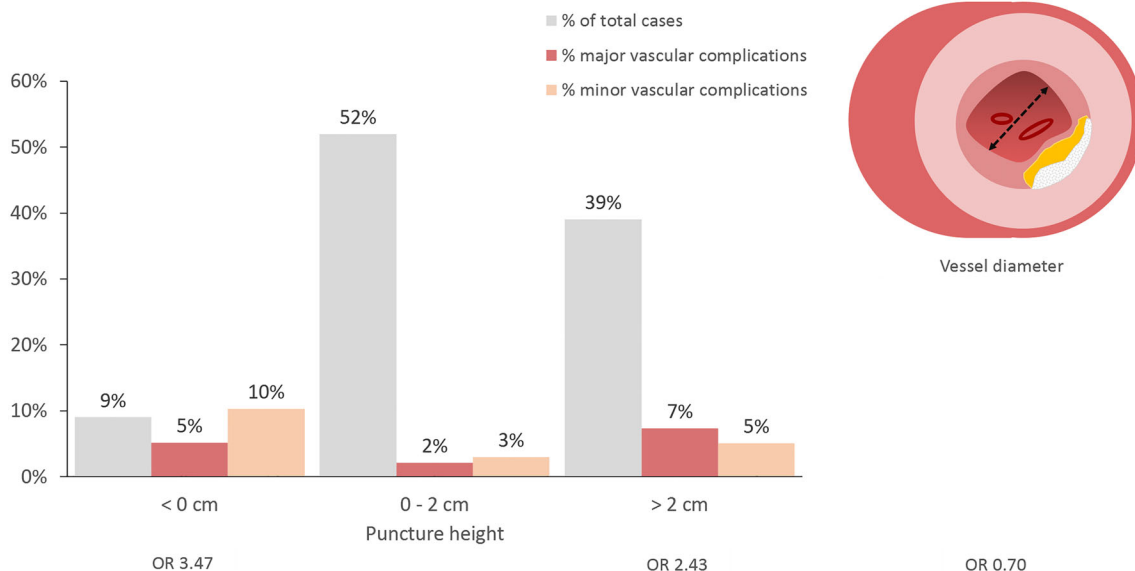


FIGURE 3 Predictors for vascular complications after MANTA deployment. Both off-target punctures and smaller caliber vessel were independent predictors for access site related vascular complications. OR – Odds ratio [Color figure can be viewed at wileyonlinelibrary.com]

required surgery, one required a covered stent and one required prolonged manual compression), two patients had a pseudo-aneurysm, one patient had a sheath related injury prior to VCD-deployment and one patient had a late occlusion of the common femoral artery requiring vascular surgery.

Of the 87 abnormal angiograms, 24 (27%) had an occlusion, 60 (69%) had incomplete arteriotomy closure and 3 (4%) had both. An abnormal femoral angiogram required either no additional action ($n = 11$, 13%); prolonged manual compression ($n = 23$, 30%); balloon angioplasty ($n = 29$, 38%); endovascular stenting ($n = 18$, 24%) or vascular surgery ($n = 6$, 8%). There was one patient that had incomplete arteriotomy closure on angiography that was initially conservatively treated but later developed a pseudo-aneurysm that required a thrombin-injection. In total 36 out of 87 (41%) patients with an abnormal angiogram had a VARC-2 defined vascular complication at 30 days follow-up. In the entire cohort unplanned vascular surgery was required in 8 (1.5%) patients and unplanned endovascular stenting in 20 (3.9%) patients.

3.4 | Predictors

Multivariate logistic regression showed that smaller minimal diameter of the femoral artery (OR 0.81 95%-CI [0.54–0.99]; $p = .015$), punctures on- or below the bifurcation (OR 3.47, 95-% CI [1.21–10.00]; $p = .02$) and high punctures >2 cm above the bifurcation (OR 2.43, 95-% CI [1.16–5.10]; $p = .02$) were independent predictors of access-site related vascular complications.(Figure 3, Table 3).

There was no difference in the complication rate over time when comparing the first 171 consecutive cases with cases 171–344 and 344–512. (6% vs. 8% vs. 11%, $p = .39$).

4 | DISCUSSION

Our real-world experience with MANTA in a TAVR cohort of 512 patients involved standardized use of multislice computed tomography prior to the procedure, ultrasound-guided arterial access and femoral angiography post MANTA deployment. The main findings can be summarized as follows¹: Access site related vascular complications with MANTA occurred in 8% of cases (4% major vascular complications) and were mainly due to percutaneous closure device failure.² Unplanned vascular surgery and covered stenting were required in 1.5% and 3.9% respectively.³ Femoral artery occlusion appeared in 5% of cases, and was typically resolved by balloon dilatation.⁴ Small femoral artery diameter and high or low punctures independently predicted vascular complications with MANTA.

4.1 | In perspective

MANTA is a plug based VCD and compares favorably to suture based closure techniques. Our 8% overall and 4% major access site complication rates are lower or similar to what was reported for double

TABLE 3 Clinical- and anatomical predictors for access-site related vascular complications (VARC-2) $n = 512$

Variable	Univariate			Multivariate		
	OR	95% CI	<i>p</i> value	OR	95% CI	<i>p</i> value
ACT at closure (per s increase)	1.00	[1.00–1.01]	.42			
BMI (per kg/m ² increase)	1.04	[0.98–1.10]	.17			
Femoral artery diameter (per mm increase)	0.81	[0.62–1.04]	.10	0.70	[0.53–0.93]	.01
Female sex	1.64	[0.87–3.09]	.13			
Moderate to severely calcified CFA (none/mild as reference)	1.57	[0.84–2.94]	.16			
Puncture height						
• 0–2 cm	1.00					
• < 0 cm (0–2 cm as reference)	3.42	[1.20–9.75]	.02	3.47	[1.21–10.00]	.02
• > 2 cm (0–2 cm as reference)	2.67	[1.29–5.56]	.01	2.43	[1.16–5.10]	.02
Systolic blood pressure at closure (per mmHg increase)	1.00	[0.99–1.02]	.94			
THV design						
• Evolut R 26–29	1.00					
• Evolut pro 26–29/R 34 (Evolut R as ref)	0.54	[0.19–1.55]	.25			
• Sapien3 (Evolut R as ref)	0.82	[0.34–2.02]	.67			
• Lotus edge (Evolut R as ref)	1.77	[0.60–5.24]	.30			
• Acurate neo (Evolut R as ref)	1.45	[0.47–4.45]	.52			
Vessel depth	1.10	[0.88–1.37]	.39			

Note: Univariate- and multivariate logistic regression for access-site related vascular complications (according to VARC-2).

Abbreviations: ACT, activated clotting time; BMI, Body Mass Index; CI, confidence interval; CFA, Common femoral artery; THV, transcatheter heart valve; OR, odds ratio.

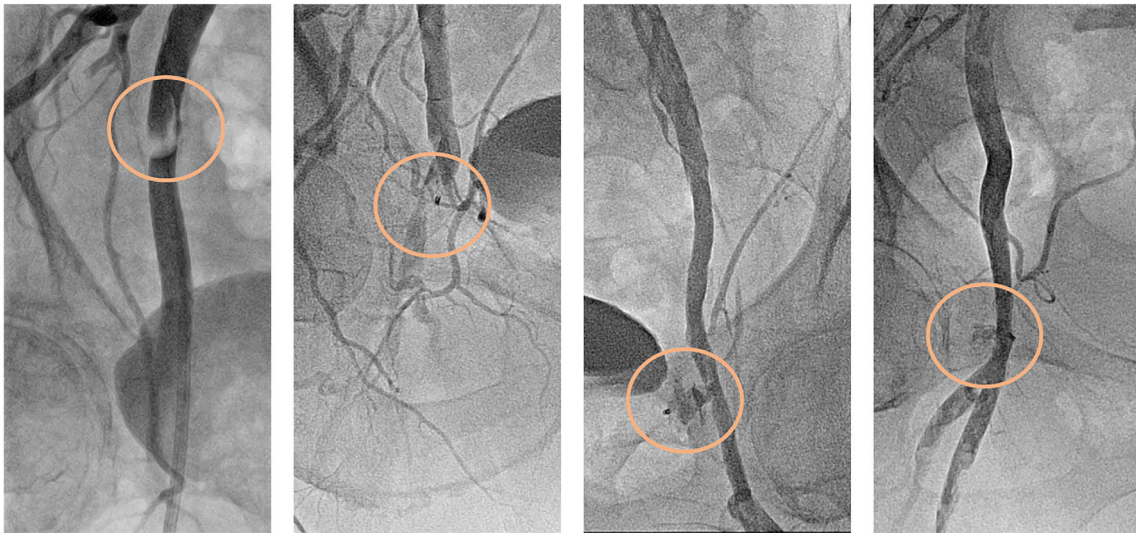


FIGURE 4 Possible findings on post-deployment femoral angiogram. From left to right: dissection, occlusion, incomplete hemostasis with large amount of leakage, incomplete hemostasis with small amount of leakage [Color figure can be viewed at wileyonlinelibrary.com]

ProGlide in the CONTROL registry (19.9% overall and 1.9% major vascular complications).¹¹ Compared to previous retrospective analyses with MANTA, that showed an incidence of access site related vascular complication ranging from 9% - 14%, our 8% is at the lower bound of the spectrum.¹⁶⁻¹⁸ Of note, the all-comers nature of this study implied stretching of the boundaries as illustrated by the vessel diameter and BMI that ranged outside the manufacturer instructions for use. In perspective to the selected populations of the CE Mark- and IDE trial that showed median time to hemostasis of 19 and 24 s and incidence of major vascular complications of 1.9% and 4.2%, our 4% major vascular access complication rate and median time to hemostasis of 42 s attest to good MANTA performance beyond a selective trial setting.^{13,14} Compared to the PRAGMATIC registry, we reported a much lower vascular complication rate after TAVR (8% vs. 27%), still percutaneous closure device failure remains the main cause of access site complications.¹⁰

4.2 | Angiographical confirmation

The systematic angiographic control revealed incomplete closure or transient occlusion in up to 20% of cases that were most often solved by (manual) compression or ballooning. (Figure 4) Bail out maneuvers with MANTA are limited and distinct from suture based techniques as there is no safety wire to re-insert a sheath or accommodate another VCD in case of percutaneous closure device failure. Bail-outs include (manual or mechanical) compression, prolonged balloon dilatation, the use of hemostatic matrix, endovascular stents and vascular surgery. The use of a balloon to occlude the aorta for uncontrollable retroperitoneal bleeding can serve as a bridge to vascular surgery and is of potential life-saving value, but was not needed in our series.¹⁹

In this trial, unplanned vascular surgery and covered stenting was required in 1.5% and 3.9% respectively. Endovascular stenting of the

CFA comes at a risk of restenosis, stent fracture and precludes the use of the CFA for future access.^{20,21} Notably, bail-out use of endovascular stents was reported in 2.5–9.6% of cases in studies on suture-based closure devices.^{11,22,23}

4.3 | Arteriotomy location and vessel caliber

The radiopaque stainless steel lock of the MANTA device allowed to accurately measure the exact puncture location on the femoral angiogram. Both low (i.e., at or below the femoral bifurcation) (OR 3.47, $p = .02$) and high (> 2 cm above the femoral bifurcation) (OR 2.43, $p = .02$) punctures were predictors for clinically relevant vascular complications and should be avoided at all cost. Due to MANTA's intra-arterial design, it is prone for vascular occlusions when deployed in the superficial or deep femoral artery. High punctures have high risk for retroperitoneal bleeds and are non-compressible against the femoral head. MANTA closure should therefore be avoided in punctures above the epigastric artery or below the femoral bifurcation. Arguably, in the context of atherosclerotic disease and calcium, ultrasound guidance may drive operators to higher puncture sites that may be free of disease but less prone to manual compression.²⁴ A study by Pitta et al. suggested that a puncture technique based on anatomical landmarks was off target in 13% of cases and associated with vascular complications.²⁵ Therefore, we believe ultrasound guided access should be the method of choice to grant a view appreciation of the femoral bifurcation, calcium distribution and needle entry. Angiographical confirmation after ultrasound guided access may prove a valuable confirmatory double check, particularly in obese patients.

Apart from suboptimal puncture location, small vessel caliber was associated with access site complications (OR 0.73 [0.54–0.99], $p = .04$), this is in line with previous findings, where an SFAR threshold >1.05 predicted a higher rate of major vascular complications.²⁶

5 | LIMITATIONS

This is a retrospective analysis with inherent selection bias, the decision for MANTA was per operators discretion, therefore during the observational period also suture-based closures were applied. The dataset captured the entire experience following its introduction. Furthermore, the technology was applied beyond the boundaries of prior prospective trials to help understand its potential in different anatomical phenotypes. The fact that we saw a stable complication rate over time suggests that the adoption of a plug-based closure concept that is mainstream for small bore closure is relatively straightforward with large bore arteriotomies. A large randomized trial comparing MANTA with suture based closure should add more perspective to the relative pro and cons for the respective closure techniques overall and in particular settings such as small caliber vessels, obesity, calcifications and sex.

6 | CONCLUSION

Access site related vascular complications with MANTA occur in 8% of patients after TAVR and remain driven by percutaneous closure device failure. Femoral angiograms should confirm VCD success post deployment. Small caliber vessel and high or low punctures were independently associated with access site complications.

CONFLICTS OF INTEREST

Nicolas Van Mieghem received research grants and advisory fees from Abbott, Boston Scientific, Edwards, Essential Medical/Teleflex, Medtronic, PulseCath BV. All other authors declared no conflict of interest regarding the publication of this manuscript.

DATA AVAILABILITY STATEMENT

The data that support the findings of this study are available from the corresponding author upon reasonable request.

ORCID

Maarten P. van Wiechen  <https://orcid.org/0000-0001-6026-8605>

Herbert Kroon  <https://orcid.org/0000-0003-1866-5855>

Joris F. Ooms  <https://orcid.org/0000-0001-7881-7609>

Marjo J. de Ronde-Tillmans  <https://orcid.org/0000-0003-1744-3265>

Joost Daemen  <https://orcid.org/0000-0001-8628-1410>

REFERENCES

- Leon MB, Smith CR, Mack M, et al. Transcatheter aortic-valve implantation for aortic stenosis in patients who cannot undergo surgery. *N Engl J Med.* 2010;363(17):1597-1607.
- Leon MB, Smith CR, Mack MJ, et al. Transcatheter or surgical aortic-valve replacement in intermediate-risk patients. *N Engl J Med.* 2016;374(17):1609-1620.
- Mack MJ, Leon MB, Thourani VH, et al. Transcatheter aortic-valve replacement with a balloon-expandable valve in low-risk patients. *N Engl J Med.* 2019;380(18):1695-1705.
- Popma JJ, Adams DH, Reardon MJ, et al. Transcatheter aortic valve replacement using a self-expanding bioprosthesis in patients with severe aortic stenosis at extreme risk for surgery. *J Am Coll Cardiol.* 2014;63(19):1972-1981.
- Popma JJ, Deeb GM, Yakubov SJ, et al. Transcatheter aortic-valve replacement with a self-expanding valve in low-risk patients. *N Engl J Med.* 2019;380(18):1706-1715.
- Reardon MJ, Van Mieghem NM, Popma JJ, et al. Surgical or Transcatheter aortic-valve replacement in intermediate-risk patients. *N Engl J Med.* 2017;376(14):1321-1331.
- Rahhab Z, Ramdat Misier K, El Faquir N, et al. Vascular complications after Transfemoral Transcatheter aortic valve implantation: a systematic review and meta-analysis. *Struct Heart.* 2020;4(1):62-71.
- Vemulapalli S, Carroll JD, Mack MJ, et al. Procedural volume and outcomes for Transcatheter aortic-valve replacement. *N Engl J Med.* 2019;380:2541-2550.
- Genereux P, Webb JG, Svensson LG, et al. Vascular complications after transcatheter aortic valve replacement: insights from the PARTNER (placement of AoRTic TraNscathetER valve) trial. *J Am Coll Cardiol.* 2012;60(12):1043-1052.
- Van Mieghem NM, Tchetché D, Chieffo A, et al. Incidence, predictors, and implications of access site complications with transfemoral transcatheter aortic valve implantation. *Am J Cardiol.* 2012;110(9):1361-1367.
- Barbashi IM, Barbanti M, Webb J, et al. Comparison of vascular closure devices for access site closure after transfemoral aortic valve implantation. *Eur Heart J.* 2015;36(47):3370-3379.
- van Gils L, Daemen J, Walters G, et al. MANTA, a novel plug-based vascular closure device for large bore arteriotomies: technical report. *EuroIntervention.* 2016;12(7):896-900.
- Krajcer Z, Wood DA, Strickman N, et al. Pivotal Clinical Study to Evaluate the Safety and Effectiveness of the MANTA Vascular Closure Device During Percutaneous EVAR and TEVAR Procedures. *Journal of Endovascular Therapy.* 2020;27(3):414-420. <http://dx.doi.org/10.1177/1526602820912224>.
- Wood DA, Krajcer Z, Sathananthan J, et al. Pivotal clinical study to evaluate the safety and effectiveness of the MANTA percutaneous vascular closure device. *Circ Cardiovasc Interv.* 2019;12(7):e007258.
- Kappetein AP, Head SJ, Genereux P, et al. Updated standardized endpoint definitions for transcatheter aortic valve implantation: the valve academic research Consortium-2 consensus document. *Eur Heart J.* 2012;33(19):2403-2418.
- Hoffmann P, Al-Ani A, von Lueder T, et al. Access site complications after transfemoral aortic valve implantation - a comparison of Manta and ProGlide. *CVIR Endovasc.* 2018;1(1):20.
- Biancari F, Romppanen H, Savontaus M, et al. MANTA versus ProGlide vascular closure devices in transfemoral transcatheter aortic valve implantation. *Int J Cardiol.* 2018;263:29-31.
- Moriyama N, Lindström L, Laine M. Propensity-matched comparison of vascular closure devices after transcatheter aortic valve replacement using MANTA versus ProGlide. *EuroIntervention.* 2019;14(15):e1558-e1565. <http://dx.doi.org/10.4244/eij-d-18-00769>.
- Stannard A, Eliason JL, Rasmussen TE. Resuscitative endovascular balloon occlusion of the aorta (REBOA) as an adjunct for hemorrhagic shock. *J Trauma.* 2011;71(6):1869-1872.
- Sarkadi H, Berczi V, Kollar A, et al. Safety, clinical outcome, and fracture rate of femoropopliteal stenting using a 4F compatible delivery system. *Eur J Vasc Endovasc Surg.* 2015;49(2):199-204.
- Thiney PO, Millon A, Boudjelit T, Della Schiava N, Feugier P, Lermusiaux P. Angioplasty of the common femoral artery and its bifurcation. *Ann Vasc Surg.* 2015;29(5):960-967.
- Ott I, Shivaraju A, Schaffer NR, et al. Parallel suture technique with ProGlide: a novel method for management of vascular access during transcatheter aortic valve implantation (TAVR). *EuroIntervention.* 2017;13(8):928-934.

23. Barbanti M, Capranzano P, Ohno Y, et al. Comparison of suture-based vascular closure devices in transfemoral transcatheter aortic valve implantation. *EuroIntervention*. 2015;11(6):690-697.
24. Seto AH, Abu-Fadel MS, Sparling JM, et al. Real-time ultrasound guidance facilitates femoral arterial access and reduces vascular complications: FAUST (femoral arterial access with ultrasound trial). *JACC Cardiovasc Interv*. 2010;3(7):751-758.
25. Pitta SR, Prasad A, Kumar G, Lennon R, Rihal CS, Holmes DR. Location of femoral artery access and correlation with vascular complications. *Catheter Cardiovascular Interv*. 2011;78(2):294-299.
26. Hayashida K, Lefevre T, Chevalier B, et al. Transfemoral aortic valve implantation new criteria to predict vascular complications. *JACC Cardiovasc Interv*. 2011;4(8):851-858.

SUPPORTING INFORMATION

Additional supporting information may be found online in the Supporting Information section at the end of this article.

How to cite this article: van Wiechen MP, Kroon H, Hokken TW, et al. Vascular complications with a plug-based vascular closure device after transcatheter aortic valve replacement: Predictors and bail-outs. *Catheter Cardiovasc Interv*. 2021;1-9. <https://doi.org/10.1002/ccd.29506>