



**VICTORIA UNIVERSITY**  
MELBOURNE AUSTRALIA

*Early Detection of Diabetic Eye Disease Through Deep Learning Using Fundus Images*

This is the Published version of the following publication

Sarki, Rubina, Ahmed, Khandakar and Zhang, Yanchun (2020) Early Detection of Diabetic Eye Disease Through Deep Learning Using Fundus Images. EAI Endorsed Transactions on Pervasive Health and Technology, 6 (22). ISSN 2411-7145

The publisher's official version can be found at  
<https://eudl.eu/doi/10.4108/eai.13-7-2018.164588>  
Note that access to this version may require subscription.

Downloaded from VU Research Repository <https://vuir.vu.edu.au/42000/>

## Early Detection of Diabetic Eye Disease through Deep Learning using Fundus Images

Rubina Sarki\*, Khandakar Ahmed and Yanchun Zhang

Victoria University, Melbourne, Australia

### Abstract

**INTRODUCTION:** Diabetic eye disease (DED) is a group of eye problems that can affect diabetic people. Such disorders include diabetic retinopathy, diabetic macular edema, cataracts, and glaucoma. Diabetes can damage your eyes over time, which can lead to poor vision or even permanent blindness. Early detection of DED symptoms is therefore essential to prevent escalation of the disease and timely treatment. Research difficulties in early detection of DEDs can so far be summarized as follows: changes in the eye anatomy during its early stage are often untraceable by the human eye due to the subtle nature of the features, where large volumes of fundus images put tremendous pressure on scarce specialist resources, making manual analysis practically impossible.

**OBJECTIVES:** Therefore, methods focused on deep learning have been practiced to promote early detection of DEDs and address the issues currently faced. Despite promising, highly accurate identification of early anatomical changes in the eye using Deep Learning remains a challenge in wide-scale practical application.

**METHODS:** We present conceptual system architecture with pre-trained Convolutional Neural Network combined with image processing techniques to construct an early DED detection system. The data was collected from various publicly available sources, such as Kaggle, Messidor, RIGA, and HEI-MED. The analysis was presented with 13 Convolutional Neural Networks models, trained and tested on a wide-scale imagenet dataset using the Transfer Learning concept. Numerous techniques for improving performance were discussed, such as (i) image processing, (ii) fine-tuning, (iii) volume increase in data. The parameters were recorded against the default Accuracy metric for the test dataset.

**RESULTS:** After the extensive study about the various classification system, and its methods, we found that creating an efficient neural network classifier demands careful consideration of both the network architecture and the data input. Hence, image processing plays a significant role to develop high accuracy diabetic eye disease classifiers.

**CONCLUSION:** This article recognized specific work limitations in the early classification of diabetic eye disease. First, early-stage classification of DED, and second, classification of DR, GL, and DME using a method that causes permanent blindness afterward. Lastly, this study was intended to propose the framework for early automatic DED detection of fundus images through deep learning addressing three main research gaps.

Received on 11 September 2019; accepted on 29 April 2020; published on 19 May 2020

**Keywords:** Deep learning, Diabetic eye disease, Image classification, Transfer learning

Copyright © 2020 Rubina Sarki *et al.*, licensed to EAI. This is an open access article distributed under the terms of the Creative Commons Attribution license (<http://creativecommons.org/licenses/by/3.0/>), which permits unlimited use, distribution and reproduction in any medium so long as the original work is properly cited.

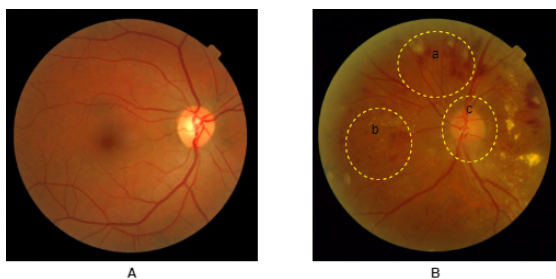
doi:10.4108/eai.13-7-2018.164588

### 1. Introduction

For more than fifty years the World Health Organization (WHO) has published general guidelines for

\*Corresponding author. Email: [rubinas2512@gmail.com](mailto:rubinas2512@gmail.com)

diabetic detection and classification. In 2017, approximately 425 million people worldwide developed diabetes, according to the International Diabetes Federation (IDF) statement. By 2045 the corresponding number will increase to 692 million [1]. Diabetes' medical, social, and economic complications are huge public health problems, and diabetes is the fourth-largest cause of death in the world [2]. Symptoms of diabetes can be seen in different parts of the body including the human eye's retina, causing irregular development of the blood vessels, degradation of the optic nerve due to intraocular pressure and formation of hard exudates near the macula region shown in Fig.???. Detection of these anatomical changes by means of fundus photograph acquired challenges which are follows;



**Figure 1.** (A) Normal retinal image and (B)retinal image with diabetic eye disease; (a) blood vessel rupture; (b) exudates formation in macular edema; (c) optic nerve damage

The continuous expansion of the patient's medical information, such as fundus images, is creating a new challenge in diagnostics, treatment and surveillance. Manual extraction of features from a large volume of fundus images and the discovery of beneficial learning information from these images results in a loss of time between detection and treatment. Ophthalmologists often take days to study normal images. Ophthalmologists also take days to review typical images [3]. A further downside of an ophthalmologist's manual fundus retinal image analysis and DED evaluation may not always achieve accurate results. As the greatest specialist and professional ophthalmologist, may not be able to track very small changes in eye anatomy. Early signs of DED diagnosis are required at this point in time to reduce patient vision loss and provide early treatment. Therefore automated DED detection techniques are necessary to address this problem.

Over the last few decades, efforts have been made to develop robust computer-based DED analytics systems using image processing methods and machine learning approaches [4–6]. Though non-DED and DED binary classification using deep learning has achieved strong accuracies in validity. Whereas non-DED and mild-DED (early stage) binary classification as well as multi-stage(mild, moderate and severe)

classification from colour fundus images are still an open problem[7, 8]. We focus our research primarily on exploring the research gaps in developing an early DED diagnosis (non-DED and mild-DED) classification system based on deep learning, and designing a framework. Throughout our literature review it is noted that none of the preceding studies address the early detection of diabetic eye disease i.e. diabetic retinopathy, glaucoma, diabetic macular edema and cataract in a single system together. Several research studies[9–19] have been identified aimed at classifying stages of an individual diabetic eye disease i.e normal to severe. In our research study we aimed to develop a single classification system for DED. It is understood that early DED identification with one process is a very important aspect. Seeing the lesions in a specific area or region of eye anatomy can provide specific treatment for the most affected target region of the eye.

**Research Challenges.** Deep Neural Network model uses advance mathematical activity to process pixel value in the image [7] where training is performed by integrating the network with diverse examples, as opposed to solid rule-based programming underlying the traditional methodologies[20]. Convolutional Neural Network (CNN) has been thoroughly explored in the DED domain of Deep Learning [9, 11, 12, 14, 21, 22], surpassing previous methodologies namely the recognition of images[12]. Neural networks seek to learn the profound features to identify the sophisticated dimension of mild DED[11]. Regardless, work on detection of DED using deep learning persistently addresses high performance in severe cases, while mild detection of DED remains an open challenge on the other. Our study questions formulated as follows on the way to achieving these aims:

1. How the quality and quantity of the fundus images influence the accuracy of the deep learning techniques.
2. How the transfer learning method can be effective in detecting the mild DED features and improving the accuracy.
3. How to develop the better, deep learning models that will deliver promising DED results.

## 2. Literature Review

Diabetic eye disease leads to blindness and its prevalence is set to rise continuously. Group of DED damage eye retina at its various parts. Severe DED is the main cause of blindness among adults aged 20-70 years. Glaucoma is the main leading cause in the group of DED which causes irreversible blindness. Diabetic retinopathy (DR) can be classified as non-proliferative DR (NPDR) and proliferative DR (PDR).

Specific DR Features can define the different stages. The following are the three subclasses of NPDR as well as PDR. Mild NPDR, Moderate NPDR, Severe NPDR, and PDR [23]. Gulshan et al.[24] proposed a DL algorithm for detection of DR. They yielded a result in two validation set of 1748 and 9963 images. The algorithm had the sensitivity of 90.3% and 87.0% and 98.1% and specificity of 98.5% respectively. Vahadane et al.[25] proposed a system to detected DME in optical coherence tomography scans using deep convolutional neural network (CNN). Their method achieved 96.43% of precision, 89.45% of recall and 0.9281 of F1-score. Prentas et al. [26] present a fusion based on CNN and landmark detection for detection of exudates. They obtained 0.78  $F_1$  measure. Otalora et al. [27] introduces a CNN model with a label efficient which uses gradient length. Automated segmentation of exudates and other features using ten layers of CNN employed by Tan et al. [28]. Their system used 149 images for training and another 149 images for testing which yielded 0.8758 and 0.7158 of sensitivity for exudates and dark lesions. Chai et al. [29] in their work the used DL model with retinal images for automatic diagnosis of glaucoma. They used Multi-branch neural network (MB-NN) model to obtain the features. The achieved the 0.9151 of accuracy, 0.9233 of sensitivity and 0.9090 of specificity. Li et al. [30] developed a DL method for detecting non-glaucoma and glaucoma based on visual fields (VFs). Their CNN based algorithm achieved 0.876 of accuracy, 0.826 of specificity and 0.932 sensitivity. Raghavendra et al. [23] proposed an 18 layers CNN framework for glaucoma diagnosis. They evaluated their model with 589 normal and 837 glaucoma images, in which the obtained 98.13% of accuracy, 98% of sensitivity and 98.3% of specificity.

### 3. Contributions

Originally, this section begins with discussing scientific contribution that this proposal seeks to achieve by identifying holes in current techniques for detecting early diabetic eye disease using medical images and describing its practical benefits.

#### 3.1. Contribution to Knowledge

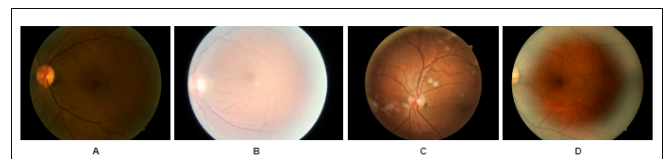
In this section we discuss various research limitations that academic researchers have been unable to resolve in previous studies on identification of diabetic eye disease. To improve the performance of deep learning techniques for early detection of diabetic eye disease, profound work is still needed. Following issue are discussed below;

*Dataset:* The availability of retinal fundus data set; *Image Pre – processing:* Implementation of the Image pre-processing techniques to enhance the quality and quantity of the available images; *Transfer Knowledge:*

Early DED detection through pre-trained CNN models (Transfer learning algorithms) using fundus images *Robust CNN Model:* Early DED detection through deep learning using fundus images.

**Data Collection.** For this study, images were acquired from publicly available datasets. Messidor and Kaggle data set were used to acquire DR images. Both the data set contains labelled colour fundus images of DR. Authors such as Franklin et al. [31], Gargeya et al. [32] and Ghosh et al. [33] have used kaggle and messidor dataset. Similarly, colour fundus images of GI were obtained from (RIGA) retinal fundus images for glaucoma analysis data set[34]. RIGA data set is composed of three different sources (i) Messidor, (ii) Bin Rushed and (iii) Margrabi Eye centre. Al Ghamdi et al. [35] have used RIGA dataset in their study. Finally, fundus images for DME were acquired from Hamilton Eye Institute Macular Edema Data set (HEI-MED). Authors in Li et al. [36] used HEI-MED data set in their study. Data set information and their respective link is shown in Table 1. Unfortunately, cataract data set are not publicly available. Authors namely Zhang et al. in [37] mention that they collected cataract data set from Beijing Tongren Eye Center of Beijing Tongren Hospital. These images were graded into four classes; normal, mild, moderate and severe. This data set is not publicly available.

**Image pre-processing.** Pre-processing of the image for extractions of features is critical for improving the performance. Also found that the fundus images available to the public consist of low fidelity data, and the fundus images taken with different fundus cameras, which causes variability in quality. The noise in the publicly available fundus images can be observed in Fig 2



**Figure 2.** The example of publicly available data-set (Kaggle Data). (A) under exposure fundus image; (B) over exposure fundus image; (C) unrelated artifacts and (D) blurriness

Limited data is another problem that needs to be addressed. A wide set of data is required to train a deep learning architecture. If the size of the data-set training is low it may not yield sufficient accuracy performance. This problem can be solved by applying methods of data augmentation such as cropping, rotating to varying degrees and mirroring images. Another approach for ensuring accuracy is to extract the same label data from a different source. For example, the number of normal

Table 1. Available Data-set and their Links

DED	Data-set	Description	Link
DR	<i>Kaggle</i>	This Data-set consists of 35,126 training images and 53,576 testing images. In total 88,702 images. The images in data set are label with DR stages	<a href="https://www.kaggle.com/c/diabetic-retinopathy-detection/data">https://www.kaggle.com/c/diabetic-retinopathy-detection/data</a>
	<i>Messidor</i>	This data-set contain 1200 fundus images in total. These images were obtain by three ophthalmological branch in France. This data set contain labeled DR stages	<a href="https://www.adcis.net/en/Download-Third-Party/Messidor.html">https://www.adcis.net/en/Download-Third-Party/Messidor.html</a>
GI	<i>RIGA</i>	This data-set contains images from three different sources; 1)MESSIDOR: This data-set consist of 460 original images and 460 images were marked manually by six different ophthalmologist. Therefore, total of 3220 marked images. 2)Bin Rushed: This data-set contains 195 original images and 195 images were marked by six different ophthalmologist. Thus in total of 1365 images. 3)Magrabi Eye center: This data-set contains 95 original images and 95 images marked by six different ophthalmologist. These data-set contain 665 images in total.	<a href="https://deepblue.lib.umich.edu/data/concern/data_sets/3b591905z?locale=en">https://deepblue.lib.umich.edu/data/concern/data_sets/3b591905z?locale=en</a>
DME	<i>HEI-MED</i>	This data-set is obtain from Hamilton Eye Institute Macular Edema Data-set (HEI-MED) This data-set contains 169 testing and training images which can be use for the detection of exudates and DME.	<a href="https://github.com/lgiancaUTH/HEI-MED">https://github.com/lgiancaUTH/HEI-MED</a>

Legend: DED - Diabetic Eye Disease; DR - Diabetic Retinopathy; GI - Glaucoma, DME - Diabetic Macular Edema; RIGA - Retinal Fundus Images for Glaucoma Analysis ; HEI-MED - Hamilton Eye Institute Macular Edema Dataset

Kaggle image set label ( $K_0$ )images can be combined with the normal Messidor image set label number ( $M_0$ ). Likewise, the number of Kaggle image set mild label ( $K_1$ ) images can be compared with the number of subtle Messidor image set label ( $M_1$ ).

$$K_0 \cup M_0 = x : \forall x \in K_0 \text{ or } \forall x \in M_0 \quad (1)$$

Similary,

$$K_1 \cup M_1 = x : \forall x \in K_1 \text{ or } \forall x \in M_1 \quad (2)$$

Therefore, to increase the data set range, we can input  $K_0 \cup M_0$  and  $K_1 \cup M_1$  number of images.

**Transfer Knowledge.** Several pre-trained Convolutional Neural Network (CNN) architectures are available in the field of deep learning specifically for object identification; *VGG16*, *VGG19*, *ResNet50*, *InceptionV3*, *InceptionResNetV2*, *Xception*,

*MobileNET*, *MobileNETV2*, *DenseNet121*, *DenseNet169*, *DenseNet201* *NASNetMobile*, and *NASNetLarge*. The top layers of these architectures can be retrained for extraction and classification of the features with the target function (normal / mild diabetic eye disease images). In the case of limited training data, the idea of the transfer of knowledge from source task to target task may be useful. Nevertheless, in terms of improving classification efficiency, this pre-trained architecture is not appropriate for medical images such as animals, food, vehicle, etc. Therefore above mention architectures will be retrained with fundus images of diabetic eye disease and produce individual result. Ultimately, amongst all, the top-performing architecture will be picked.

**Developing robust CNN model.** CNN's classification of normal / severe DED has already shown some promising results but normal / mild is still an open

challenge. Bearing in mind the problem of overfitting, One solution could be to increase computational power by increasing the size of the network. Another approach might be object centred recognition such as blood vessels, optic discs, macular field. Object-oriented detection is more powerful than all image-based detection.

### 3.2. Statement of Significance

Our preliminary work on early detection of DEDs will also have a clear practical significance, as will academic participation. There have been numerous academic research conducted to diagnose different stages of diabetic retinopathy (normal, NPDR and PDR) using deep learning methods [9, 11, 12]. Similarly, other researchers have identified various stages (normal to severe) of glaucoma using deep learning techniques [13–16]. Deep learning has also been used to diagnose signs of diabetic macular edema and cataracts [17–19]. Our work aims at examining, classifying and detecting all forms of DEDs in one method. In addition, we plan to develop a system that will detect the early stage of all types of DED.

## 4. Methodology and Conceptual Framework

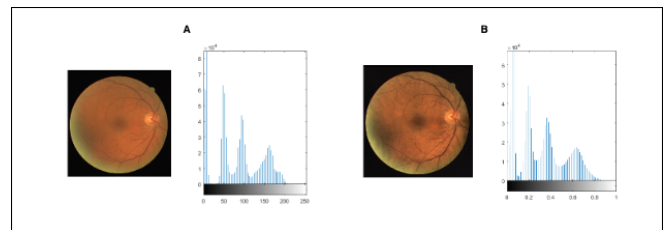
The conceptual framework and methodology used to build early DED detection system were explained in this section. We assume that the use of these methodologies would improve the efficiency of early DED detection of healthy retina and mild DED from the fundus pictures. The steps to shape a conceptual framework would be defined as follows;

### 4.1. Image pre-processing

Retinal image pre-processing is crucial because this process enhance the image for better visualization. The brief summary of the pre-processing methods that we will strive to use in our research is given below.

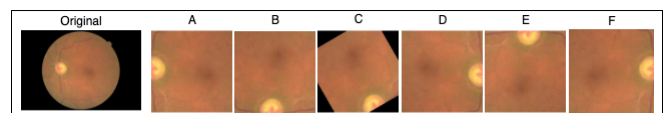
**Image Enhancement.** Green Channel Extraction is employed to extract green band from RGB of an image. Green channel of an image provides more insight information from the image. In our work, contrast enhancement with CLAHE (Contrast Limited Adaptive Histogram Equalization) shown in Fig 3 is used to improve the contrast of the images. After improvement of the contrast, correction of the illumination is applied to increase the brightness and luminance of the image. Finally, remove noise from an image, using Gaussian filtering to make it smoother.

**Image Augmentation.** Image Augmentation is a technique which can be used to artificially expand the size of a training dataset by creating updated image versions in the dataset [38]. Training deep learning models of the



**Figure 3.** Contrast Limited Adaptive Histogram Equalization enhances contrast; (A) before and (B) after CLAHE application.

neural network on more data can result in more skillful models, and the augmentation techniques can generate image variations that can improve the ability of the fit models to generalise what they have learned to new images. Image augmentation produces training images artificially by different processing methods or combinations of multiple processing, such as random rotation, resized, turns, mirror, shear and flips etc Fig 4. Manipulations of Geometric transformations in an image were performed using Keras *ImageDataGenerator* class.



**Figure 4.** Examples of augmentation performed in Mild DR fundus images; Original; (A) Crop; (B) Rotate 90°; (C) Rotate 120°; (D) Rotate 180°; (E) Rotate 270°; (F) Mirror

**Region of Interest.** A region of interest (ROI) is a section of an image on which you would like to perform another operation. In many applications the concept of an ROI is commonly used. For example, In early diabetic retinopathy, blood vessel walls in your retina weaken. Smaller bulges (microaneurysms) protrude from the smaller vessel walls, often discharge blood and fluid into the retina. Larger retinal vessels can become irregular in diameter and begin to dilate. An axon (nerve fibres) will start to swell in the retina. Therefore, the blood vessels of a retina may be defined on an image, for the purpose of measuring the early changes in the eye retina. The contrast enhancement is achieved through the CLAHE. Subsequently, the background of the image has been excluded by the average filter subtraction of the image. The binarisation threshold level is calculated using Isodata technique [39] and the smaller components are finally removed by taking into account the size of each component connected Fig 5.

Likewise, the most important ROI for detecting GI and DME is optic disc and macular area. Therefore the region of interest can be used to train the system instead of training on the whole retinal image.

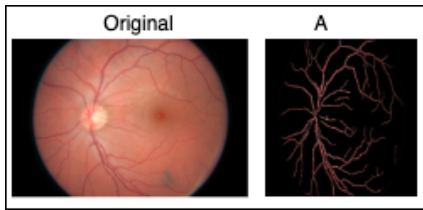


Figure 5. Region of Interest; (A) blood vessel segmentation of the original image

#### 4.2. Analysis of diabetic eye disease using deep learning approaches

This section addresses DED detection strategies focused on deep learning (DL). Deep learning is the extension of machine learning which derive features from multiple layers. The word “deep” here refers to the breadth of the network within the framework of deep learning. In this section firstly, training and testing data set are collected. Further, pre-processing techniques are applied to the data set to make image features more clearer. For feature extraction and classification this pre-processed images are forwarded to the DL model. In DL output of the previous layer pass it into the next layer as input. Lastly, the top or the last layer produces the result. Various studies employed deep learning methods for detecting DR, G1 and DME. In our study, we aim to use deep learning-based transfer learning and own build deep learning for classification of DED.

**Deep learning using Transfer Learning.** Krizhevsky et.al. in [40] proposed a CNN architecture with more than 60 million parameters. Learning so many parameters from a few hundred training images might not produce the desired outcome. The key idea of transfer learning is that the network’s internal layers should serve as a specific extractor that can pre-train in the source task and retrain the target task. Adopting the pre-trained model is an effective optimization technique, as well as improving classification for fewer data sets. The CNNs’ first layer learns common characteristics such as texture, edges and pattern. The top layer, covers the central component of the images, such as haemorrhages or lesions. Knowledge transfer has grown as a new framework in recent years to address the problem of insufficient data on training. The study’s overall goal is to improve the performance of early DR detection of Mild DR from fundus images through an empirical review of various techniques for improving classification. The related priorities can be as follows;

- Compare 13 CNN systems that use Transfer Learning concept;
- fine-tuning assessments and its effect on performance of models [41];

- Optimizer selection effect on performance of the models;
- data augmentation and contrast enhancement evaluation techniques on Mild DR detection task for further classification enhancement.

The high-level process pipeline is illustrated in Fig 6 to demonstrate the steps that have proceeded.

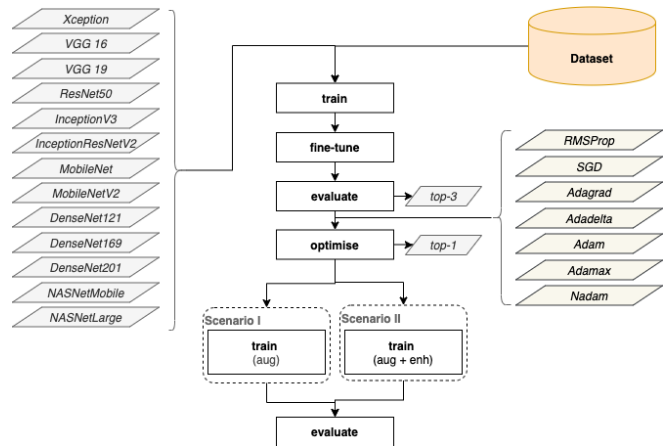


Figure 6. System for the detection of Diabetic Eye Disease

**Deep learning using own build CNN architecture.** Due to its high level of performance across many types of data Deep Learning is becoming a very common subset of machine learning. Creating a convolution neural network (CNN) is a great way to use deep learning to identify images. Python’s Keras library makes it fairly easy to build a CNN. The computers use pixels to view images. Convolutions use this to assist in the recognition of images. For instance, in an image a certain group of pixels can indicates some pattern or an edge. This is used by Convolutions to help recognition of images. The definition of a convolution is as follows:

$$(f * g)(t) \stackrel{\text{def}}{=} \int_{-\infty}^{\infty} f(t - \tau)g(\tau)d\tau$$

Where,  $f$  and  $g$  convolution is written as  $f * g$ , with operating system  $*$  denotes that each image pixel multiply by a weight and then filter by dot product. Although the symbol  $t$  is used, does not need to represent the time domain. In this context, however, the convolution can be defined as a weighted average of the function  $f(\tau)$  at the moment  $t$  when the weighting is given by  $g(\tau)$  simply shifted by quantity  $t$ . The design does not change itself too much from these measures. Once the size values have been set, the zero padding and the output calculate the convolution and store the measured values in a cache so that they can be used for back propagation again.

## 5. Conclusion

This paper identified two research gaps in the automatic detection of diabetic eye disease. First, early stage identification of DED, and second, identification of DR, GL, and DME using one method that causes permanent blindness afterwards. These research gaps are described with the perspective of three different aspects, namely, datasets, image preprocessing techniques, and DL-based classification techniques. In this analysis, many publicly available DED datasets have been explored and published. Such as, Kaggle, Messidor, RIGA and HEI-MED dataset were most widely used for the identification of diabetic eye diseases. In this study we addressed the weakness of the publicly available data set and how image pre-processing techniques can be used to fix it. Techniques such as extraction of green channels and enhancement of contrasts using CLAHE have produced better contrast. To prevent over-fitting and neutralize the data disparity, data augmentation was used. To create a robust early DED detection system ROI like blood vessels, optic disc and macular region was also been extracted. In deep learning, convolutional neural network architecture is considered to be the most used classification method for the detection of disease using medical images. This study introduces a deep learning-based paradigm on two research issues in the field of early detection of diabetic eye disease. We see this work as providing a deeper understanding of the field of DED detection techniques. Finally, this analysis is considered to be useful for researchers working in the field of detecting diabetic eye disease.

## References

- [1] FOROUHI, N.G. and WAREHAM, N.J. (2019) Epidemiology of diabetes. *Medicine* 47(1): 22–27.
- [2] TABISH, S.A. (2007) Is diabetes becoming the biggest epidemic of the twenty-first century? *International Journal of health sciences* 1(2): V.
- [3] SILBERMAN, N., AHRlich, K., FERGUS, R. and SUBRAMANIAN, L. (2010) Case for automated detection of diabetic retinopathy. In *2010 AAAI Spring Symposium Series*.
- [4] CHEUNG, C.Y., TANG, F., TING, D.S.W., TAN, G.S.W. and WONG, T.Y. (2019) Artificial intelligence in diabetic eye disease screening. *The Asia-Pacific Journal of Ophthalmology* 8(2): 158–164.
- [5] VAMSI, P. and CHAHUAN, A. (2020) Machine learning based hybrid model for fault detection in wireless sensors data. *EAI Endorsed Transactions on Scalable Information Systems* 7(24).
- [6] SARKER, I.H., FARUQUE, M.F., ALQAHTANI, H. and KALIM, A. K-nearest neighbor learning based diabetes mellitus prediction and analysis for ehealth services .
- [7] POPLIN, R., VARADARAJAN, A.V., BLUMER, K., LIU, Y., MCCONNELL, M.V., CORRADO, G.S., PENG, L. *et al.* (2018) Prediction of cardiovascular risk factors from retinal fundus photographs via deep learning. *Nature Biomedical Engineering* 2(3): 158.
- [8] LAM, C., YI, D., GUO, M. and LINDSEY, T. (2018) Automated detection of diabetic retinopathy using deep learning. *AMIA Summits on Translational Science Proceedings* 2018: 147.
- [9] MATEEN, M., WEN, J., SONG, S., HUANG, Z. *et al.* (2019) Fundus image classification using vgg-19 architecture with pca and svd. *Symmetry* 11(1): 1.
- [10] SANKAR, M., BATHI, K. and PARVATHI, R. (2016) Earliest diabetic retinopathy classification using deep convolution neural networks. pdf. *Int. J. Adv. Eng. Technol* 10: M9.
- [11] PRATT, H., COENEN, F., BROADBENT, D.M., HARDING, S.P. and ZHENG, Y. (2016) Convolutional neural networks for diabetic retinopathy. *Procedia Computer Science* 90: 200–205.
- [12] WANG, Z. and YANG, J. (2018) Diabetic retinopathy detection via deep convolutional networks for discriminative localization and visual explanation. In *Workshops at the Thirty-Second AAAI Conference on Artificial Intelligence*.
- [13] HAGIWARA, Y., KOH, J.E.W., TAN, J.H., BHANDARY, S.V., LAUDE, A., CIACCIO, E.J., TONG, L. *et al.* (2018) Computer-aided diagnosis of glaucoma using fundus images: A review. *Computer methods and programs in biomedicine* 165: 1–12.
- [14] CHEN, X., XU, Y., WONG, D.W.K., WONG, T.Y. and LIU, J. (2015) Glaucoma detection based on deep convolutional neural network. In *2015 37th annual international conference of the IEEE engineering in medicine and biology society (EMBC)* (IEEE): 715–718.
- [15] ORLANDO, J.I., PROKOFYEVA, E., DEL FRESNO, M. and BLASCHKO, M.B. (2017) Convolutional neural network transfer for automated glaucoma identification. In *12th international symposium on medical information processing and analysis* (International Society for Optics and Photonics), 10160: 101600U.
- [16] AL GHAMDI, M., LI, M., ABDEL-MOTTALEB, M. and SHOUSHA, M.A. (2019) Semi-supervised transfer learning for convolutional neural networks for glaucoma detection. In *ICASSP 2019-2019 IEEE International Conference on Acoustics, Speech and Signal Processing (ICASSP)* (IEEE): 3812–3816.
- [17] ZHANG, H., NIU, K., XIONG, Y., YANG, W., HE, Z. and SONG, H. (2019) Automatic cataract grading methods based on deep learning. *Computer methods and programs in biomedicine* 182: 104978.
- [18] PRATAP, T. and KOKIL, P. (2019) Computer-aided diagnosis of cataract using deep transfer learning. *Biomedical Signal Processing and Control* 53: 101533.
- [19] ZHOU, Y., LI, G. and LI, H. (2019) Automatic cataract classification using deep neural network with discrete state transition. *IEEE transactions on medical imaging* .
- [20] GARDNER, G., KEATING, D., WILLIAMSON, T.H. and ELLIOTT, A.T. (1996) Automatic detection of diabetic retinopathy using an artificial neural network: a screening tool. *British journal of Ophthalmology* 80(11): 940–944.
- [21] AHN, J.M., KIM, S., AHN, K.S., CHO, S.H., LEE, K.B. and KIM, U.S. (2019) Correction: A deep learning model for the detection of both advanced and early glaucoma using fundus photography. *PLoS one* 14(1): e0211579.



- [22] SAHLSTEN, J., JASKARI, J., KIVINEN, J., TURUNEN, L., JAANIO, E., HIETALA, K. and KASKI, K. (2019) Deep learning fundus image analysis for diabetic retinopathy and macular edema grading. *Scientific reports* **9**(1): 1–11.
- [23] RAGHAVENDRA, U., FUJITA, H., BHANDARY, S.V., GUDIGAR, A., TAN, J.H. and ACHARYA, U.R. (2018) Deep convolution neural network for accurate diagnosis of glaucoma using digital fundus images. *Information Sciences* **441**: 41–49.
- [24] GULSHAN, V., PENG, L., CORAM, M., STUMPE, M.C., WU, D., NARAYANASWAMY, A., VENUGOPALAN, S. *et al.* (2016) Development and validation of a deep learning algorithm for detection of diabetic retinopathy in retinal fundus photographs. *Jama* **316**(22): 2402–2410.
- [25] VAHADANE, A., JOSHI, A., MADAN, K. and DASTIDAR, T.R. (2018) Detection of diabetic macular edema in optical coherence tomography scans using patch based deep learning. In *2018 IEEE 15th International Symposium on Biomedical Imaging (ISBI 2018)* (IEEE): 1427–1430.
- [26] PRENTAŠIĆ, P. and LONČARIĆ, S. (2016) Detection of exudates in fundus photographs using deep neural networks and anatomical landmark detection fusion. *Computer methods and programs in biomedicine* **137**: 281–292.
- [27] OTÁLORA, S., PERDOMO, O., GONZÁLEZ, F. and MÜLLER, H. (2017) Training deep convolutional neural networks with active learning for exudate classification in eye fundus images. In *Intravascular Imaging and Computer Assisted Stenting, and Large-Scale Annotation of Biomedical Data and Expert Label Synthesis* (Springer), 146–154.
- [28] TAN, J.H., FUJITA, H., SIVAPRASAD, S., BHANDARY, S.V., RAO, A.K., CHUA, K.C. and ACHARYA, U.R. (2017) Automated segmentation of exudates, haemorrhages, microaneurysms using single convolutional neural network. *Information sciences* **420**: 66–76.
- [29] CHAI, Y., LIU, H. and XU, J. (2018) Glaucoma diagnosis based on both hidden features and domain knowledge through deep learning models. *Knowledge-Based Systems* **161**: 147–156.
- [30] LI, F., WANG, Z., QU, G., QIAO, Y. and ZHANG, X. (2018) Visual field based automatic diagnosis of glaucoma using deep convolutional neural network. In *Computational Pathology and Ophthalmic Medical Image Analysis* (Springer), 285–293.
- [31] GROUP, E.T.D.R.S.R. *et al.* (1991) Grading diabetic retinopathy from stereoscopic color fundus photographs—an extension of the modified airle house classification: Etdrs report number 10. *Ophthalmology* **98**(5): 786–806.
- [32] FRANKLIN, S.W. and RAJAN, S.E. (2014) Computerized screening of diabetic retinopathy employing blood vessel segmentation in retinal images. *biocybernetics and biomedical engineering* **34**(2): 117–124.
- [33] GARGEYA, R. and LENG, T. (2017) Automated identification of diabetic retinopathy using deep learning. *Ophthalmology* **124**(7): 962–969.
- [34] ZHANG, J. and CHEN, P.H. (2018) Medical imaging 2018: Imaging informatics for healthcare, research, and applications. In *Society of Photo-Optical Instrumentation Engineers (SPIE) Conference Series*, **10579**.
- [35] GHOSH, R., GHOSH, K. and MAITRA, S. (2017) Automatic detection and classification of diabetic retinopathy stages using cnn. In *2017 4th International Conference on Signal Processing and Integrated Networks (SPIN)* (IEEE): 550–554.
- [36] LI, G., ZHENG, S. and LI, X. (2017) Exudate detection in fundus images via convolutional neural network. In *International Forum on Digital TV and Wireless Multimedia Communications* (Springer): 193–202.
- [37] ZHANG, L., LI, J., HAN, H., LIU, B., YANG, J., WANG, Q. *et al.* (2017) Automatic cataract detection and grading using deep convolutional neural network. In *2017 IEEE 14th International Conference on Networking, Sensing and Control (ICNSC)* (IEEE): 60–65.
- [38] LI, H., WANG, Y., WANG, H. and ZHOU, B. (2017) Multi-window based ensemble learning for classification of imbalanced streaming data. *World Wide Web* **20**(6): 1507–1525.
- [39] EL-ZAART, A. (2010) Images thresholding using isodata technique with gamma distribution. *Pattern Recognition and Image Analysis* **20**(1): 29–41.
- [40] KRIZHEVSKY, A., SUTSKEVER, I. and HINTON, G.E. (2012) Imagenet classification with deep convolutional neural networks. In *Advances in neural information processing systems*: 1097–1105.
- [41] AGGARWAL, A., CHAUHAN, A., KUMAR, D., MITTAL, M. and VERMA, S. Classification of fake news by fine-tuning deep bidirectional transformers based language model .