

We are IntechOpen, the world's leading publisher of Open Access books Built by scientists, for scientists

5,300

Open access books available

130,000

International authors and editors

155M

Downloads

Our authors are among the

154

Countries delivered to

TOP 1%

most cited scientists

12.2%

Contributors from top 500 universities



WEB OF SCIENCE™

Selection of our books indexed in the Book Citation Index
in Web of Science™ Core Collection (BKCI)

Interested in publishing with us?
Contact book.department@intechopen.com

Numbers displayed above are based on latest data collected.
For more information visit www.intechopen.com



Chapter

Leading Wrist Injuries in a Golfing Population. Golf Swing Biomechanics a Significant Cause of Pathology

Conor P. O'Brien

Abstract

Golf participation has increased significantly over the past 50 years. Injury rates have mirrored this increase with amateur and elite golfers suffering a similar injury incidence to rugby players. The upper limb is the second most common anatomical site of injury in this population. Wrist injury and specifically the ulnar side of the leading wrist is the most prevalent. Leading wrist injuries affect the tendons, fibrocartilage, bones and neural structures that are located on the ulnar side of the wrist and hand as well as the soft tissue aponeurosis and bony and ligamentous canals that traverse the wrist joint. The most commonly injured lateral wrist structure is the Extensor Carpi Ulnaris tendon. This is particularly liable to injury due to the forces placed on it during the golf swing. Other structures on the medial side of the leading wrist associated with golf related injury and pathology include Triangular Fibrocartilage, the hamate bone, the bony canals through which the nerves travel, as well as the flexor aponeurosis and Flexor Carpi Ulnaris tendon. Risk injury to the medial aspect of the leading wrist is increased by the newer golfing theories and techniques which endeavour to create increase golf club head speeds by storing greater energy by a phenomenon called “lag”. Lag results in greater speed as the club head releases at impact but results in injury to the medial wrist anatomical structures. Swing biomechanics, and their alteration and augmentation are a major factor in medial wrist injury. Diagnosis of these pathologies requires careful history and examination, as well as the use of radiology and electrodiagnostic medicine to confirm the pathology and degree. Treatment is targeted to the specific disability. Classical treatments are mostly employed and usually involve rest and anti-inflammatory treatments. Newer therapies such as Platelet Rich Plasma injection and Deep Oscillation therapy have proven beneficial. Splinting is often employed on return to play. Early diagnosis and cessation of the offending activity often allays the need for surgery. The rhyme that “minutes to diagnosis means weeks to recovery” is particularly apt for medial wrist golf injuries. Surgery will be required in long standing or chronic cases. Return to play, unlike many sports injuries, will require careful golf biomechanical assessment and alteration in swing dynamics. The objective of this chapter is to identify how the new biomechanical manipulation of the wrist and specifically the leading wrist has resulted in increased injuries to this anatomical structure. The type of injury, diagnosis and treatment is discussed in detail. Club head speed is generated through a combination of improved golf club equipment, golf payer fitness and manipulation of the golf club by the left wrist resulting in increased golf club lag and torque which all contribute to wrist injuries.

Keywords: golf injury, leading wrist/swing biomechanics, Tenosynovitis, Carpal Tunnel Syndrome, ECU Tendon, Tendinitis, Tendinosis, hook of Hamate, Guyon's Canal Syndrome, Dupuytren's contracture, Flexor Carpi Ulnaris tendon, Nerve Entrapment

1. Introduction

Golf participation has exploded in the past 2 decades. In the early part of the century, it was calculated that Golf is played by over 55 million people throughout the world. In 2018 there were 38,864 golf courses in 290 of the world's 449 countries [1]. Golf has a particular traditional home in Great Britain and Ireland with 494 courses populating the island of Ireland. The majority of golfers reside in America, where over 23.4 million golfers were recorded in the USA in 2018. This had risen to 34.2 million by January 2021, with 9 million participating in golf at ranges and using indoor simulators. There are approximately one million individuals playing golf twice a week in England and have done so for the past five years [1, 6].

The Golf Industry is an \$84 billion economic engine that drives nearly 2 million jobs in the USA producing a total economic output in California alone of \$15.1bn in 2019.

Golf is both a recreational pastime and a competitive sporting pursuit. Golf started to thrive as a spectator sport in the 1920's and boomed in earnest in the 1960's with the arrival of live golf on TV. Its charm and allure might be the lack of age and gender barriers. Fundamentally, it is a game of skill and guile requiring some athletic ability.

The rise in popularity of golf is multifactorial. Golf as a sport has a dedicated viewing population unlike many sports and many non-golfers happily enjoy the trials and travails of professional golfers which appear on TV channels on a weekly basis. In many ways a 4 day professional sporting event is like a drama or soap opera with villains and heroes in equal measure performing on perfectly manicured fairways. Golf is peculiar in spawning a dedicated TV channel, The Golf Channel, watched by millions of viewers on a weekly basis. The recent pandemic delayed Masters played in Augusta, Georgia, USA in the Autumn of 2020 which had a viewership of over 15 million. The exercise associated with golf is of great health benefit [2] providing the perfect physiological work out to sustain health and longevity [3].

Golf too may be considered the perfect exercise for improving health and longevity. Recent recommendations have suggested that the perfect exercise would involve aerobic activity intermingled with resistance activity and anaerobic activity [3]. It is reported that this exercise prescription positively affects all cause and specific cause mortality in American adults. It appears that carrying or pushing golf clubs around an 18-hole course provides an almost perfect exercise prescription [2]. The association of golf participation and improved physical health and mental well-being and the contribution to increased life expectancy has prompted a number of experts to recommend policy makers encourage golf as a beneficial pastime [4].

The worldwide reach of golf and its ability to transcend barriers of age, race and gender and its general appeal has seen the reintroduction of golf to the 2016 Olympic Games.

In parallel with increased participation, injury rates among golfers have also increased. Research has suggested that almost 7 in 10 amateurs and 9 in 10 professionals will suffer a golf-related injury at least once in a lifetime of golf participation [5].

2. Golf injury incidence

Increased participation, just short of a million people play golf twice a month in England for the past 5 years [6] has resulted in increased injury rates more

frequently in elite golfers. [7] Annual Injury incidences of between 2 and 4% are reported among golfers. Put more simply a golfer can expect to sustain an injury for every 100 hours of golf participation with an overall incidence rate of injury of 15.8 injuries per 100 golfers and with a range of 0.36 to 0.60 injuries per 1,000 hours per person. 46.2% of injuries are reportedly sustained during the golf swing, and injury is most likely to occur at the point of ball impact (23.7%) [8]. Golf carries a significant injury rate with levels exceeding other non- contact sports. Perhaps golf is in fact a contact sport, with contact being made with turf and ball through a metal implement, frequently in a ferocious and repetitive manner.

There is a significant variation in the incidence and type of injury suffered by amateur or recreational golfers in comparison to their professional counterparts. In a review of over a thousand amateur golfers, the survey confirmed that more than 60% of amateur golfers sustained one or more golf related injuries over the course of their playing career. The injury rate was higher in the over 50 year old amateur with a 65% injury rate in comparison to the under 50 group, which had an injury incidence of 58% [9]. There was a slightly higher incidence of injury at 67.5% among single figure handicappers rather than their double-digit colleagues. A typical injury resulted in the amateur golfer missing five weeks of playing time [5–7].

More than 80% of professional golfers report a golf-related injury at some point in their career. It is estimated that between 10% and 33% of professional golfers are actually playing while they are carrying an injury during their professional career. Most professional golfers will experience 2 significant golf-related injuries during their career. Over a career, 9 weeks for professional men and 3 weeks for professional women are lost due to injury. On returning from injury more than 50% of professional golfers are compromised by their injury and often play through pain [10–12].

Recent research has indicated that general exercise has an injury rate of 5.3 per 1,000 persons, golf having a similar injury rate to rugby at 1.5 per 1000 persons [13]. The injury rate is significant but the over-arching benefits of playing golf outweigh the risks, particularly to physical and mental well-being [2, 3].

3. Types of golf injury

All golfers are prone to injury. Amateur golfers have a lifetime incidence of injury ranging from 25.2% to 67.7%. Professionals golfers have higher rates between 31% to 88.5% over a lifetime.

Many studies on golf injuries have found that low back injuries account for 15.2% to 34% of all golf injuries, followed by injuries to the elbow (7% to 27%) and shoulder (4% to 19%). The wrist accounts for 10% of all golf injuries. In professional golf, wrist injury incidence has been reported to be up to 54% (7), the leading wrist being most commonly compromised [14].

The change in the injury profile is associated with increased playing hours as well as the nature of golf. Newer golf clubs with composite heads and lighter shafts have allowed the golfer to swing faster in the constant and increasing race by club manufacturers to achieve greater distance.

The majority of golf injuries are referred to as “over-use injuries” caused by the repeated action of swinging the golf club and hitting the golf ball and turf. This activity not only takes place on the golf course where the average long shot golf rate is 40 to 50 swings per round but also on the practice tee and driving range where 100’s of balls are hit. Lighter clubs and the availability of golfing practice facilities have also impacted the increased injury rate. Specific risk factors for overuse golf injuries are age, ability, and swing mechanics [15].

4. Overuse injuries

Overuse injuries affecting the musculoskeletal system are caused by repetitive trauma which result in micro trauma to soft tissue structures such as tendons, muscles ligaments as well as bones. The factors pertaining to these overuse injuries can be divided simply into: 1) Intrinsic causes; 2) Extrinsic causes.

1. **Intrinsic** risk factors can be modifiable or non-modifiable. Modifiable factors in golfers would include fitness, skill level and patterns of practice session. One of the major issues for a golfer is that often he or she is their own coach. In many cases this type of practice reinforces an intrinsic mistake in the swing biomechanics rather than corrects the imperfection. In these cases, “practice makes permanent rather than perfect”. Non-modifiable factors would include age, gender and body morphology, general health and joint or spine pathology. Quality of practice and play is always preferable to quantity. In golfers a faulty grip is frequently a fundamental flaw leading to overuse injury.
2. **Extrinsic** factors include the conditions a golfer is exposed to. These include equipment and coaching. If either is inappropriate injuries will result. All golf coaches should take golf biomechanics, prior injury and skill level into account. Practicing in the cold or when not warmed up will increase the risk of injury. Training error is a frequent culprit. Failure to warm up, hitting too many balls, hard surfaces, inappropriate equipment or an alteration in swing mechanics can all result in excessive loading and injury. This coupled with insufficient or inadequate recovery time, (golfers frequently play when injured) causes inflammation to tissues and injuries. A trained PGA golf professional will ensure that these common mistakes are avoided, however, most golfers are their own coaches and training errors mixed with other extrinsic and intrinsic issues result in injury.

Swing mechanic and alteration in technique on the quest for greater distance off the tee are probably the greatest causes of overuse injuries in the modern golfing population.

4.1 Physics of a Golf swings

The golf swing is a means of transferring energy to a stationary ball. The energy is transferred to the ball which then travels down the fairway.

The modern golf swing can be broken up into a number of components (**Figure 1**):

- Set-up
- Back swing
- Transition
- Down swing
- Impact
- Follow-through

The function of the golf swing is to apply the face of the golf club in a consistent, stable and square fashion allowing force to be impacted onto the golf ball from the club face producing linear momentum which is transmitted to the ball. The force applied to the ball is a function of the mass of the object (golf club) and its velocity

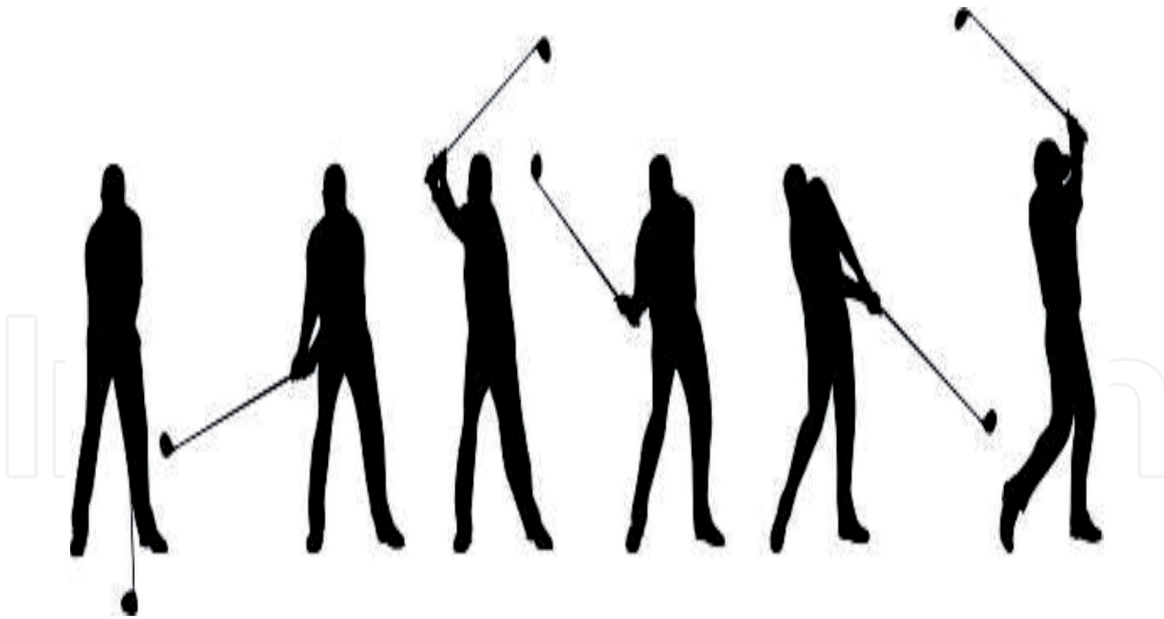


Figure 1.
The phases of a golf swing.

(mass \times velocity = momentum). The rules of golf remove the first variable [the mass of the club), the second element has amused and exercised golf teachers and technologists for centuries.

At first look the conundrum of a golf swing appears simple. However, it involves a number of complex laws of physics:

1. Newtons 3rd Laws of Motion
2. Potential and Kinetic Energy Transfer
3. Circular motion and its constituent parts

4.1.1 Newton's 3rd law of motion

In the first instance energy is transmitted from the golf club to the golf ball based on Newton's 3rd Law of Motion i.e. The Law of Action and Reaction.

One object exerts a force on a second object, the second object exerts an equal opposite force on the first object. As club hits ball it applies force causing it to go in motion. In return, the ball also applies a reciprocal and equal force back to the club. This force slows your club down. The interplay of these actions and reactions result in a golf ball flying towards a target. Not all the energy is transmitted to the ball, with some being diverted up the club to the wrist. This is further increased by imperfect or missed shots.

During a golf swing energy is transferred between both potential and kinetic. The back swing creates kinetic energy which is converted into stored or potential energy at the top of the swing and then converted back to kinetic energy on the down swing. This happens because of the law of conservation of energy.

4.1.2 Energy transfer

Potential Energy (PE) is stored energy. It is energy an object possesses due to its position or the arrangements of its parts. This potential or stored energy is created at the top of the golf swing.

$$PE = \text{mass} \times \text{gravity} \times \text{height}. \quad (1)$$

Hence the higher the hands and the club head from the ball the greater the stored energy in the swing.

Kinetic Energy (KE) is energy that occurs when an object is in motion.

This is the energy created by the golf club descending towards the golf ball.

$$KE = 1/2 \text{mass} \times \text{velocity squared.} \quad (2)$$

The Law of Conservation of Energy states that: Energy is neither created nor destroyed, it is conserved. Hence the back swing creates kinetic energy at the top of the swing. This is stored as Potential energy during the transition phase and then transferred back to kinetic energy on the down swing before it is transmitted to the golf ball at impact.

4.1.3 Circular motion of a golf swing

Unlike other ball hitting sports such as cricket, hurling, tennis and baseball the golf swing is a circular motion attacking a stationary object, the golf ball.

The circular motion is subject to other physic parameters:

- Double pendulum Effect
- Centipetal forces
- Torque

4.1.3.1 The double pendulum effect

A physical pendulum is a solid object that swings back and forth on a pivot under the influence of gravity. The golfer has 2 anchors, the shoulder and the wrists. In a golf swing, the connection between arms and club creates a double pendulum effect. The arms make up one pendulum that pivots around the shoulders, while the club makes a second pendulum that pivots around the wrists, which acts as the pivot. The two pendulums can swing independently but work together to make the swing feel effortless.

4.1.3.2 Centripetal force

Centripetal Force is a force that makes an object move in a curved motion, like a rollercoaster hugging the curve around a loop. The golf club swinging in an arc from the shoulder to the ball. The hands hold the club and prevent it flying off in a straight line, in a centrifugal fashion. In essence the golfer pulls the wrists and club handle inward while swinging the golf club and golf head outward.

The faster the club curves and the bigger the arc in a golf swing (radius) the greater the force of the club on the ball, and the farther the golfer should be able to hit the ball.

$$\text{Centripetal Force} = \text{mass} \times \text{velocity}^2 / \text{radius.} \quad (3)$$

$$\text{Centripetal Force} = \text{weight of club} \times \text{swing speed}^2 / \text{swing arc.} \quad (4)$$

The mass and velocity are also a function of gravity.

4.1.3.3 Torque

In physics Torque is a measure of the force that can cause an object to rotate about an axis. It is a rotating force in a circular motion as opposed to a simple force which causes an object to accelerate linearly. Torque is the force that causes an object to acquire angular acceleration in a golf swing.

Torque is the rotating force in circular motion as you swing back, coiling your body, and then start the downswing. This creates the stored or potential energy at the top of the swing. If you hold the club and prevent it releasing on the down swing you increase this stored energy. The hands and wrists are resisting the angular acceleration of the golf club. Increased torque and stored energy are ultimately released by the club face at the bottom of the swing.

$$\text{Torque} = \text{Force} \times \text{distance.} \quad (5)$$

These elements of classical physics have fascinated golfers who seek greater distance in their golf shots. The mass dynamics and weight of golf clubs and their structure are subject to the rules of golf (1) and can be considered a constant. Velocity is the variable element.

Golfers have pondered on this singular element for centuries. Swinging faster or manipulating the club in the down swing through releasing the club later will add greater speed. Similarly firing the right side of the body or manipulating the club face through the hands remain the other options available to the golfer seeking greater distance. Each augmentation compromises the leading wrist and are associated with injury.

5. Biomechanics of the modern golf swing

Modern biomechanics techniques have allowed a clear understanding of the physical requirements of the body for the execution of a golf swing. Simply put, a golf club made up of a stick or shaft attached to a heavier head hits a ball towards a target by swinging the stick.

The motion involves a complex manipulation of shaft and club by the golfer to promote maximum force on the ball in an effort to propel the ball towards a target. Once described by Winston Churchill as "a game whose aim is to hit a very small ball into an even smaller hole with weapons singularly ill-designed for the purpose".

The golf club exerts a force on the golf ball by creating a greater force on the down swing which is transferred to the ball. This force is a function on the mass of the club and the speed it is travelling at. This in turn is a function of the distance travelled to the ball and gravity. Extra speed can be generated by the double pendulum affect. Holding the wrist angle for as long as possible in the down swing increases stored energy by a concept referred to as lag. As the stored energy is released in the down swing at 30 degrees the club is released towards the ball greater speed is created. This results in a greater force being applied to the ball.

Newton's second law of motion, the acceleration of an object is dependent upon both force and mass. Thus, if the colliding objects have unequal mass, they will have unequal accelerations as a result of the contact force that results during the collision.

Newton's laws of motion are naturally applied to collisions between the golf club and the golf ball. In this collision both ball and club experience forces that are equal in magnitude and opposite in direction.

The force experienced by the club head is equal to the force experienced by the golf ball.

The forces upon the ball and club head are equal, but accelerations are unequal due to the size of the two objects at the moment of contact or collision. In simple terms club head and ball experience equal forces, yet the ball experiences a greater acceleration due to its smaller mass.

Golfers are well aware of this and refer to it as the “Smash Factor”. This relates to the amount of energy transferred from the club head to the golf ball. The more efficiently energy is transferred the greater the acceleration. Smash Factor is ball speed divided by club speed.

The higher the smash factor the better the energy transfer. A golf swing of 100mph and a smash factor of 1.5 would create a ball speed of 150 mph. This can be affected by a number of other elements such as club lift and grip size, but ultimately the greater the club head speed the greater the Smash Factor and the further the ball travels. Hence for the same 100 mph club, a ball speed of 10mph speed difference will affect ball distance. A 10 mph in ball speed equates to a 20-yard increase in distance hitting a driver.

The upshot of Newton’s laws of motion and the golf swing are simple. The greater the force applied to the smaller golf ball by the bigger golf club, the greater the acceleration, and the further a ball will travel. The acceleration of the club is produced by two pendulums working in concert i.e. the shoulder element and the wrist element.

6. Biomechanics of the leading wrist

The leading wrist is placed on the upper golf grip and the trailing wrist on the lower element. Both hands are joined together by either interlocking or overlapping the index finger of the leading and small fifth finger of the trailing hand.

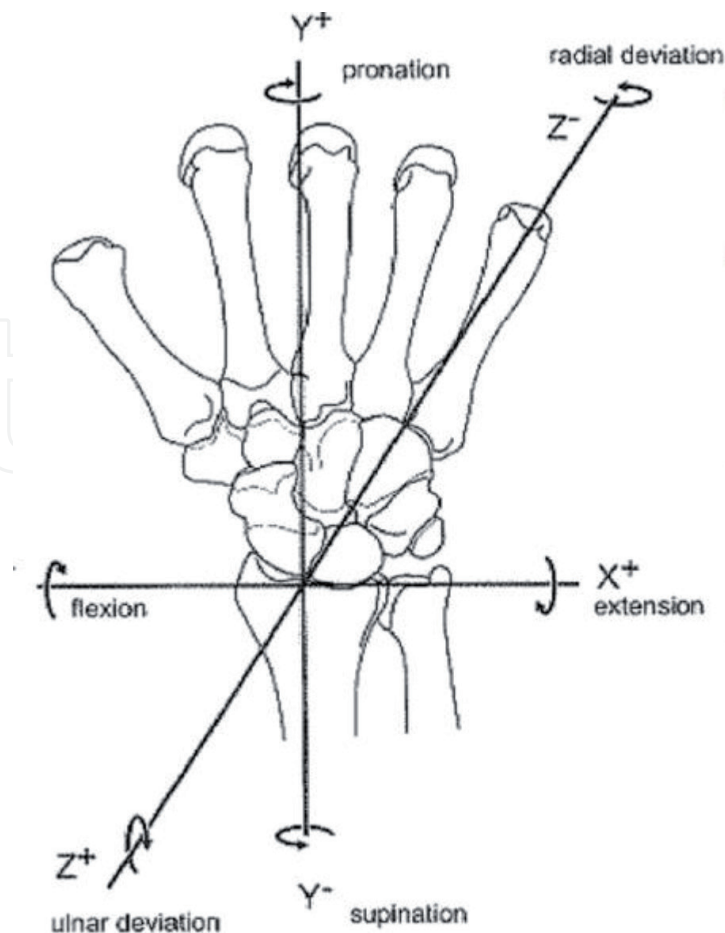


Figure 2.
Directions of leading wrist motion during a golf swing.

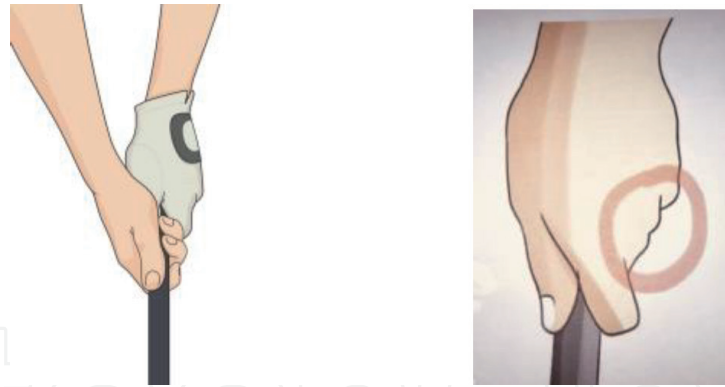


Figure 3. Classic left-hand grip showing less than one and a half knuckles (left) and a strong left-hand grip showing 3 or more knuckles (right).

The leading wrist is placed in different anatomical positions to achieve a consistent contact on the golf ball. Each phase of the golf swing puts specific stresses and strains on the leading wrist and hand, which can result in different types of injuries [16–18].

There are 3 basic wrist motions during the golf swing. They are subtle and subject to significant variation [19] of motions from player to player (**Figure 2**).

- Ulnar/Radial Deviation
- Flexion/Extension
- Supination/Pronation

At address the leading wrist is positioned in an ulnar deviated flexed position. It is pronated in strong grips (showing 3 or more knuckles), supinated in weak grips (showing one or less knuckles), (**Figure 3**) Classical teaching advises a neutral grip showing 1.5 or 2 knuckles.

In the back swing the leading wrist travels into a radial deviated, flexed and pronated position.

In the down swing the leading wrist travels into an ulnar deviated, supinated and extended position.

7. Leading wrist ulnar/radial deviation in the golf swing

At address, the leading wrist is usually held in ulnar deviation of the order of 17%.

During the backswing, the left wrist transitions to a radial deviated position and then travels back to the ball transitioning again from radial to a predominant ulnar deviated position at impact (**Figure 4**).

Modern golf coaches often teach their pupils to hold the wrist in a radial deviated position for as long as possible on the down swing. This is referred to as a cocked position (**Figure 5**). When held in this position stored energy is increased. This cocked or radial deviated wrist position is created by maintaining an angle between the shaft and the left forearm in the downswing. The longer the wrists can maintain this angle, the greater the lag and resulting stored energy. This referred to “lag” as the club head is lagging behind the shaft caused by the wrist position, which is called wrist torque by golf teachers (**Figure 6**).

This manoeuvre is based on research which has shown that greater club head speed is achieved if an active wrist torque is applied to the club during the latter

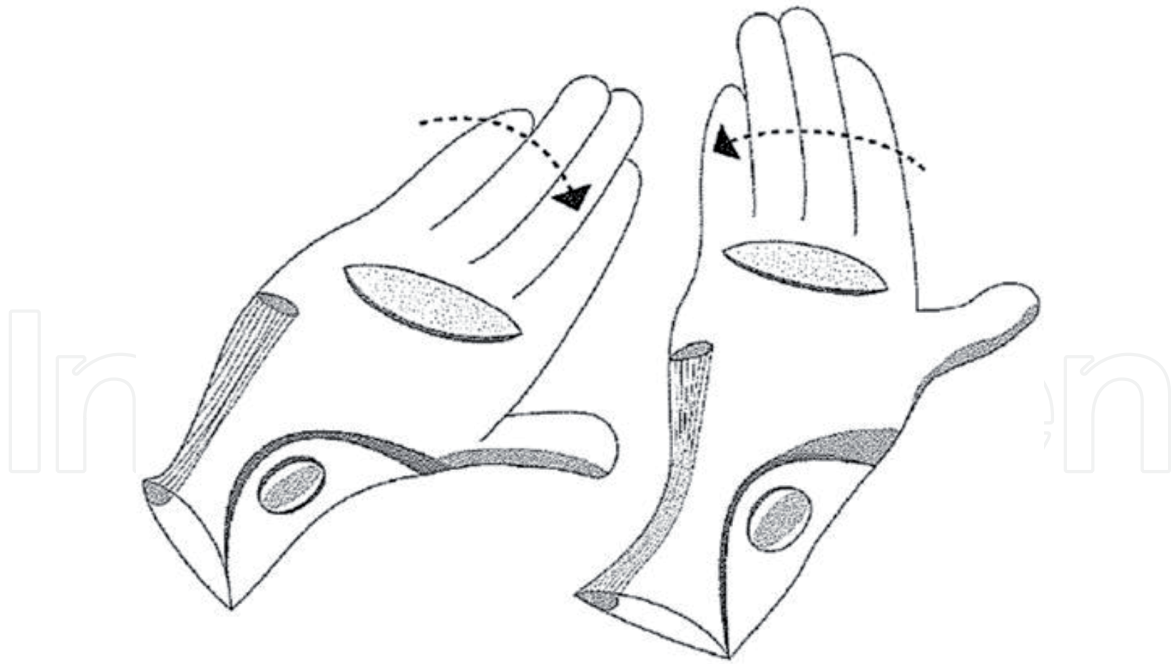


Figure 4.
Leading wrist ulnar deviation at address and impact (right) and radial deviation at the top of the back swing (left).

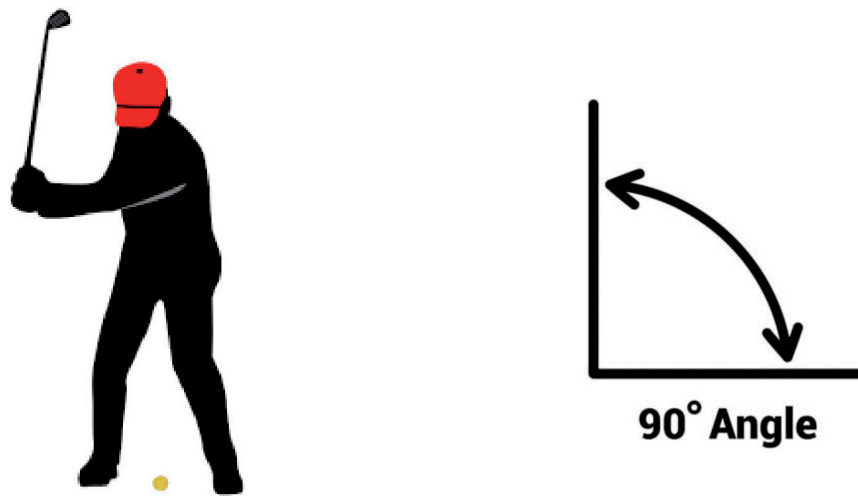


Figure 5.
The angle between the shoulder, wrist and club head is maintained close to a right angle in the down swing to 30 degrees below the horizontal line through the shoulder joint, at which point the hands are released.



Figure 6.
The leading wrist in a flexed and radial deviated position maintains the angle between club shaft and arm to the bottom of the down swing, resulting in the head of the club “lagging” behind the hands storing energy.

stages of the downswing [19]. To produce a club head speed of 100 miles per hour, the optimal timing of the activation of wrist torque occurs when the arm segment is at approximately 30° below the horizontal line through the shoulder joint [20].

Therefore, significant timing of the shot is required to manoeuvre in releasing club head back square to the ball. This requires a careful return of the leading wrist from radial to ulnar deviation prior to impact.

8. Leading wrist flexion/extension in the golf swing

Flexion/Extension motion of the leading wrist is a significantly individual watermark of every swing. Elite golfers also vary dramatically from player to player.

Classical golf swing teaching suggests that the wrist is placed in a neutral or slightly extended position at address (**Figure 7**).

At the top of the back swing it stays in a neutral flexion/extension pattern. This referred to as "square at the top".

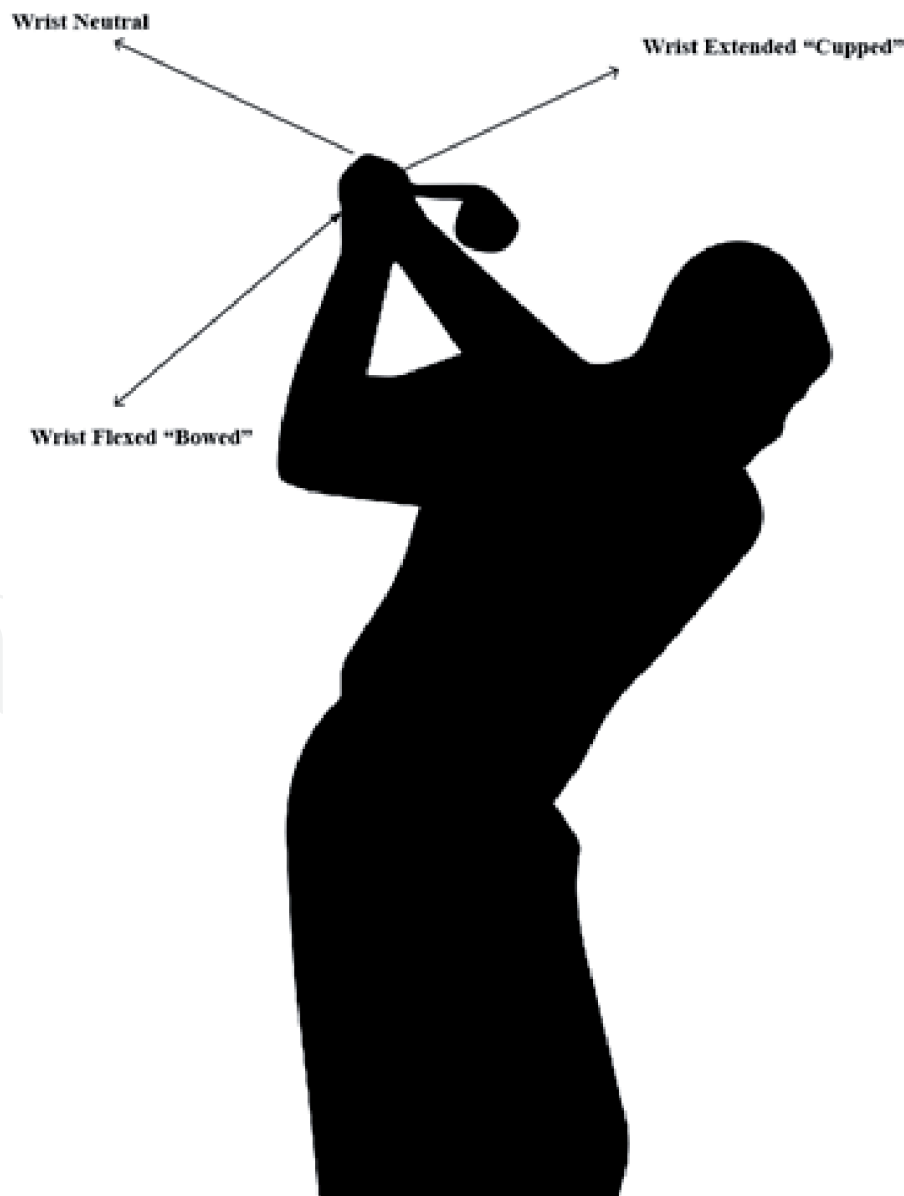

Figure 7.
Wrist positions at the top of the Back swing.

In classical teaching the leading wrist descends in the down swing to the ball in a flexed position in which it impacts the ball. Not everyone follows this teaching.

9. Figure leading wrist flexion on down swing and impact

Consistent players such as Jack Nicklaus was “square at the top” for most of his career. Ben Hogan placed his leading wrist in an extended or “cupped” position (**Figure 7**) at the top of his swing before transitioning to a flexed position at impact. This has been replicated by current touring pro Mathew Perry and is seen as a way of avoiding placing hook spin on the ball. Dustin Johnson is in a more extreme flexed or “bowed” position (**Figure 7**) at the top of the swing and maintains that position on the down swing using the large trunk muscles to return the club face square to the ball at impact. This move has been followed by many golfers looking for extra distance.

10. Leading wrist pronation/supination in the golf swing

Classical golf teaching used the wrist and hands to generate club head speed at impact. In the back swing the leading wrist pronated turning the back of the leading wrist and forearm to face towards the sky at the top of the backswing. At the top of the back swing the 1st row of carpal bones are held in a pronated position at the top of the swing. During this downswing phase the leading wrist is adjusting back towards a neutral position, with the 1st carpal row of bones traversing from a bowed, pronated position towards supination. The leading wrist rotates towards supination and continues in this motion through impact where the palm of the leading wrist motions to face towards the sky in the follow through phase.

At impact the club head makes contact with the ball and the leading wrist accelerates allowing the leading wrist to unhinge into further supination in a whip-like motion, the right hand frequently rolling over the left hand and wrist thus creating extra club head speed at impact. This move is referred to as “rolling the wrists” at impact.

These pronation and supination motions are not commonly seen in modern golfers. These “handsy” moves are considered to be inconsistent. They are regularly seen in good wind players who need to manipulate the face of the golf club in relation to changing wind directions. The majority of modern elite players and coaches tend to manipulate the radial, ulnar and flexion and extension motions.

11. Elite golfers at the top of the back swing

There are many versions of the wrist flexion/extension pattern in modern golf swings, ultimately returning the leading wrist to a flexed position at impact. Each technique creates greater swing speeds and allows individual players square the club face at impact. All place varying degrees of stress on the leading wrist. These can be summarised into 3 patterns employed by leading professional golfers [21]. All have one thing in common; a flexed wrist at square club face at impact, the body moving at speed providing the acceleration to square the club face.

11.1 Flex and maintain

John Rahm has a weaker grip or neutral grip at address showing 1 and ½ knuckles in his leading hand. He flexes his wrist at the top of the swing and maintains that

flexed position on the down swing and rotates his body to square up the club face at impact.

11.2 Flex, flex and rotate

Dustin Johnson has a stronger grip at address showing 3 knuckles with his wrist held in flexion. At the top of the swing he further flexes his leading wrist. On the way down he turns his body aggressively to square up the club face at impact.

11.3 Extend and flex

Matt Wolff has a weak to neutral grip at address, extends his wrist at the top of the swing and with great skill and co-ordination rapidly converts his lead wrist to a flexed position on the down swing before he releases the club face into a square position at impact.

Bryson De Chambeau who is considered the longest hitter on the PGA tour has very specific statistics [22].

11.4 Flexion/extension

13 degree of flexion at address, 11 degrees of extension at the top of the swing and 20 degrees of flexion at impact.

11.5 Ulnar/radial deviation

20 degrees of ulnar deviation at address, 14 degrees of radial deviation at the top of the swing and 15 degrees of ulnar deviation at impact.

12. The effect of wrist manipulation on the medial aspect of the leading wrist

At impact the golf ball, club and ground collide resulting in a counter force that is transmitted up the shaft of the club to the wrist and hands which are on the golf club grip. The majority of golf injuries occur on the downswing and at impact [23].

The golf swing requires complex movement of many components of the body. The co-ordination of muscle sequencing is particularly important and is noted to be the most efficient in the elite golfer. The manipulation of the leading wrist has been a source of a crusade for many golfers as they seek the perfect golf swing. The leading wrist has the ability of storing the kinetic energy which is released at impact, thus resulting in greater power delivery to the ball and greater accuracy [20–24], but it comes at a cost.

With a late hit, skilful golfers apply torque to the leading wrist in an effort to store more energy prior to impact with the golf ball. This stored energy by holding the leading wrist in a forced flexed and ulnar deviated position throughout the first part of the down swing could be considered a compensatory methodology and an effort to compensate for faulty swing mechanics. This may be a purist view, however, the manipulation of the wrist to improve stored energy prior to impact places further extreme pressure onto the leading wrist and particularly the lateral aspect of the wrist. The rapid transitions from a radial deviated, flexed pronated position through a relatively neutral position at impact and onwards to a supinated and ulnar deviated position is the cause of trauma to this anatomical location.

Many skilled golfers manipulate the club face with the hand and wrists as the face of the club impacts with the golf ball. These subtle variations impart different

spins onto the golf ball affecting its flight and trajectory as it seeks its target on the green. A “hold off” shot imparts a left to right spin on the ball in a right-handed golfer. This is achieved by holding the left wrist firm (holding it off) at impact, preventing the natural supination of the left wrist as it transitions to impact and the follow through phase of the swing. Resisting this natural movement places great stresses on the medial structures of the left wrist which are activated to resist this natural anatomical motion.

Golfers who have quiet hands and wrists during the golf swing rarely sustain wrist injuries. Wrist manipulation may be a trade off between distance and injury.

13. Anatomical site of injuries in elite and professional golfers

The anatomical site and specific location also varies between professional and elite golfers and their amateur counterparts. There are also gender differences. For professional male golfers, the most frequently injured site is the low back at 25% of injuries, with the left wrist accounting for 16% and the left shoulder accounting for 11%. Among female professionals, the most commonly injured site is the left wrist (in 31% of cases) and the low back in 22% of cases. In general terms, therefore, the leading wrist is the most commonly affected structure among professional and elite golfers with a combined incidence of 37%, the low back at 24%, the shoulder at 10%, the elbow at 7%, the knee at 7%, the ankle and foot at 5% and the neck at 3% [25].

14. Anatomical site of injuries for amateur golfers

In amateur golfers, the low back is the most commonly injured site with an incidence in males of 36%, the elbow causing injuries in 33% of cases, the wrist or hand 21% and the shoulder 11% with the knee accounting for only 9% of injuries. In female amateur golfers, the elbow is the most commonly injured anatomical site at 36% of all female injuries, the low back accounts for 27% of injuries, the shoulder 16% and the wrist and hand 15%, the knee accounting for only 11% of injuries. When combining the data, it suggests that the most commonly injured site for amateur golfers is the lumbar spine accounting for 35% of all injuries, whereas the wrist or hand is the most common location for elite or professional golf injuries.

15. Cause and pattern of injury in elite and amateur golfer

There is also a difference between amateur and professional golf injury aetiology. In amateur golfers, excessive play or practice, direct trauma from hitting the ground or an object during a golf swing are common causes. The most common cause, however, in amateur golfers, and particularly high handicap golfers, is injuries that result from poor swing mechanics [24–26]. Professional and elite golfers are particularly prone to overuse injuries due to repeated and repetitive swinging of a golf club. This can be further complicated by alteration in swing techniques. The changes and improvement in golf equipment, with lighter shafts and composite heads on drivers and fairway metals, have also contributed to increased swing speeds. This, in association with alteration in swing techniques, can make the elite golfer more prone to injuries. In simple terms, the sheer number of swings that an elite golfer takes every week is a multiple of that of an amateur golfer. It would not be uncommon for

a professional golfer to hit two or three hundred golf balls on a daily basis. This is a combination of practice, warm up and almost daily playing schedule.

16. Upper limb injuries in a golfer

The upper limb is the most commonly injured anatomical site in elite golfers. An injury site can be devastating for the competitive amateur golfer, or the professional golfer, as it can result in time away from the game, as damage to shoulder, elbow or wrist makes coordinated swinging of a golf club difficult and occasionally impossible. The majority of golf injuries are overuse injuries of the wrist flexor or extensor tendons. However, the remainder of the shoulder joint accounts for between 4% and 19% of all golf injuries with similar rates among the professional and amateur players. Elbow injuries account for 7% to 27% of all golf injuries. Amateur golfers frequently injure this structure with reports as high as 33% in comparison to professionals whose injury rate for the elbow is 7% injuries [25–28].

17. Shoulder injuries

The shoulder itself is made up of three bones, namely the humerus, the scapula and the clavicle. The rotator cuff is made up of four different muscles: the supraspinatus, infraspinatus, subscapularis and biceps muscles. Each muscle is intimately involved in the golf swing and is liable to injury. Outside of the rotator cuff, the strong deltoid muscle stabilises the shoulder and is an essential component in creating normal shoulder abduction during the golf swing. The pectoral muscles are also particularly involved in the golf swing in both the takeaway and downswing motion. The latissimus dorsi muscle is also a critical muscle for the initiation of the downswing. Each structure can be injured directly or in combination during the golf swing and this joint accounts for 10% of professional injuries and 12% of amateur golf-related injuries.

Elbow injuries are particularly common among amateur golfers where they account for a third of all injuries but less than 10% in the professional ranks. The elbow joint is a hinge joint formed between the humerus, the radius and the ulna. It can only be flexed and extended. During the golf swing it also pronates and supinates. Extensor and flexor tendons are inserted to the elbow. The extensor apparatus is located on the outside or lateral aspect of the elbow and the extensor tendon can frequently be injured. This injury is known as a tennis elbow but is in fact more common in the golfing population than its counterpart, the golfer's elbow. The flexor tendon is inserted into the inside or medial aspect of the elbow and inflammation of this area is referred to as a medial epicondylitis or Golfer's elbow. Unusually, a tennis elbow is more common than a golfer's elbow in the golfing population.

Other tendons can also be injured around the elbow and the triceps tendon can be injured directly due to trauma from poor impact with the ground or from overuse. In cases of chronic medial epicondylitis, the ulnar nerve can be compromised resulting in pins and needles into the 4th and 5th digit of the hand. In cases of poor playing technique, the supinator muscle can become inflamed. This lies just below the elbow joint. The radial nerve runs through this structure and if the muscle becomes hypertrophied or injured it can result in local entrapment of the radial nerve. This often results in sensory alteration in the 1st webspace of the hand and weakness in wrist extension. When the radial nerve and its branch (the posterior interosseous nerve) become involved the condition can mimic tennis elbow. In these instances, surgical release of the nerve is often required. This condition is often

referred to as “resistant tennis elbow” as the symptoms mimic the classical tennis elbow which is inflammation of the extensor tendon.

18. Functional anatomy of the wrist joint

The bony wrist joint [Figure 8] is made up of the articulation of the distal radius and ulna bones with the carpal bones. The carpal bones are arranged in two rows, the 1st or proximal row and the second or distal row.

The proximal row comprises of the scaphoid, lunate triquetrum and trapezoid bones.

The second carpal row consists of the pisiform, trapezium capitate and hamate bones.

The first row of bones is a more mobile articulation in comparison to the second row which acts as one. The scaphoid communicates through both rows.

There are 3 axes of motion at the wrist joint; Flexion/Extension; Ulnar/Radial deviation; Pronation/Supination (see Figure 2). According to the “link” concept of wrist biomechanics a chain of communication exists between the radius, lunate and capitate bones, with the head of the capitate bone acting as the centre of rotation. The proximal row in the form of the lunate can act as an intercalated unit as it has no direct tendon attachment. The distal row of carpal bones act as a complete unit. The scaphoid bridges both rows. When the wrist is in ulnar deviation the scaphoid is pushed into extension, and radial deviation pushes it into flexion.

The bones are held together in a lattice of extrinsic and intrinsic wrist ligaments.

The extensor tendons at the level of the wrist are divided into six extensor compartments (Figure 9) that are designated by Roman numerals from lateral to medial:

- i. Extensor pollicis brevis, abductor pollicis longus.
- ii. Extensor carpi radialis longus, extensor carpi radialis brevis.

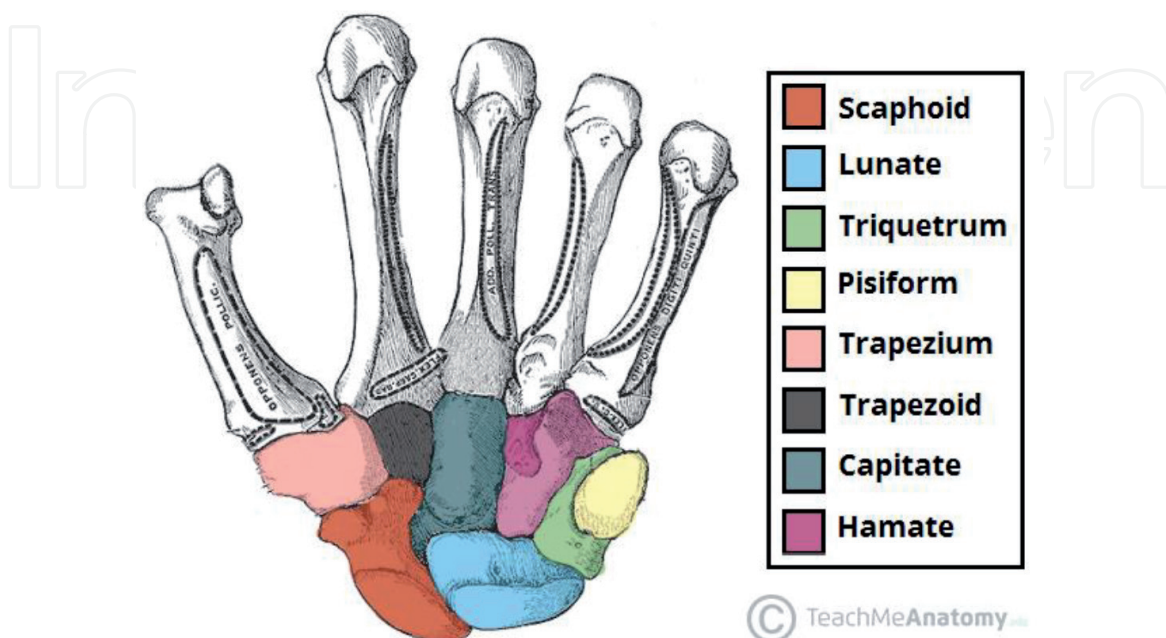


Figure 8.
Bony anatomy of the wrist, showing the 2 carpal rows.

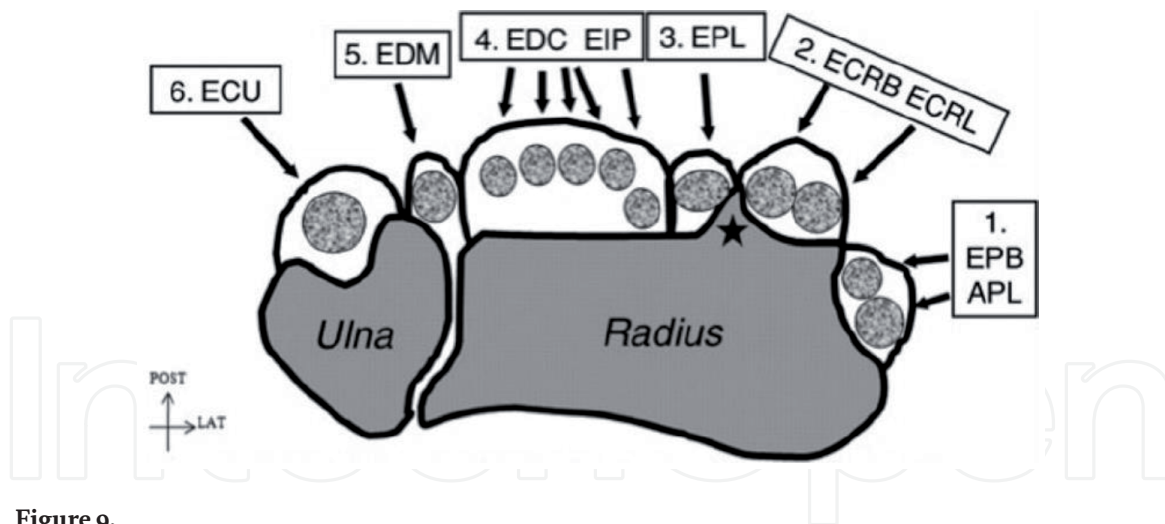


Figure 9.
The 6 extensor compartment of the wrist joint.

- iii. Extensor pollicis longus.
- iv. Extensor digitorum, extensor indicis
- v. Extensor digiti minimi
- vi. Extensor Carpi Ulnaris

The 6th compartment is the most compromised during the golf swing. The first extensor compartment is most affected in skiing, fishing and racket sports with a common occurrence of De Quervain's Tenosynovitis.

The flexor tendons of the wrist are divided into two main structures: 1) the flexor digitorum profundus (FDP) and the flexor digitorum superficialis (FDS) tendons.

FDP tendons help bend the index, middle, ring, and small fingers at the fingertip joint. FDS tendons help flexes the index, middle, ring, and small fingers at the middle finger joint. 9 of these flexor tendons travel into the wrist through the carpal tunnel. Each of the flexor tendons perform an important function in gripping the golf club in a consistent fashion to allow a natural swing of the club.

19. Wrist injuries in golf

Wrist injuries are common [25–27] and particularly prevalent in elite golfers [28, 64].

Golfers who sustain injuries to their wrist regularly fail to rest after practice sessions and do not allow adequate time for soft tissue recovery and adaptation after a heavy practice session. It is not uncommon for an elite golfer to hit balls every day. Enthusiastic amateurs can be seen hitting “buckets” of balls in an effort to groove a repetitive swing. A standard bucket of balls in a driving range contains 50 to 60 balls when a round of golf rarely exceeds 40 full shots. This simple training error often under pins wrist injuries.

These wrist injuries are often extended and exacerbated by “playing through the pain” which must always be discouraged. This behaviour is most prevalent in men who outweigh injuries in female golfers by 2 to 1 [12, 27]. This area is also more frequently affected in the professional ranks as the golf swing is a means of income, much in the same way as other manual occupations such as painters and decorators [29] suffer from overuse injuries to the upper limb (11). In a 30-person cohort 43%

of hairdressers reported overuse injury symptoms to hands and wrists from their work activity [30].

In golf it is almost impossible to consistently hit a golf ball with an injury to the wrist or hand which is the second most common site for golf injuries and a result of impacting the ball incorrectly due to poor swing mechanics [8–10].

Patterns of injury differ based on level of play and time spent playing or practicing golf. Among golf professionals, the hand/wrist is the most commonly injured upper extremity structure. The elbow is more commonly injured than the wrist in amateur golfers [31].

20. Common leading wrist pathologies in a golfing population

The medial aspect of the leading wrist in a golfer is particularly prone to injury due to the forces and stress applied to this location during the modern golf swing. The most common structure to be injured is the Extensor Carpi Ulnaris tendon and its tendon sheath and sub-sheath.

Extensor Carpi Ulnaris (ECU) tendinitis & tendinosis.

ECU tendon Subluxation.

Triangular Fibro-cartilage injury.

Hook of Hamate injury.

Guyon's Canal Syndrome.

Carpal Tunnel Syndrome.

Dupuytren's contracture.

Flexor Carpi Ulnaris tendon.

Proximal entrapment of the ulnar nerve.

Proximal entrapment of the median nerve.

20.1 Extensor carpi ulnaris tendon Injuries in golfers

The extensor carpi ulnaris tendon (**Figure 10**) originates from the lateral epicondyle of the humerus and the dorsal surface of the ulna, passes through the groove dorsally at the ulnar head within a fibro-osseous tunnel of extensor retinaculum in the 6th compartment (**Figure 11**). It has its own tendon sub-sheath for its stabilisation there and inserts on the base of the 5th metacarpal medially angled to its position in the groove of ulnar head. It acts to adduct (or ulnar deviate) and extend the wrist joint.

The Extensor Carpi Ulnaris tendon (ECU) is particularly vulnerable to injury in the golfing population because of the complex nature of the golf swing. During the golf swing the leading wrist goes through a complex motion involving ulnar and radial deviation i.e. extension and flexion and pronation and supination. These manoeuvres send forces through the wrist joint culminating with the impact of club on ball (**Figure 1**). The anatomical location of the ECU tendon in the 6th extensor compartment (**Figure 12**) held in a tendon sheath makes it liable to injury due to the excessive tensile loading and subsequent breakdown of the loaded tendon [32, 33]. ECU Tendinopathies, and tendon injuries account for significant time away from sport and lost time in practice and competition [9–11, 34, 35].

20.1.1 Types of ECU tendon injury

ECU tendon injuries come in many varieties and severities but can be simply divided into 3 major categories of injury.

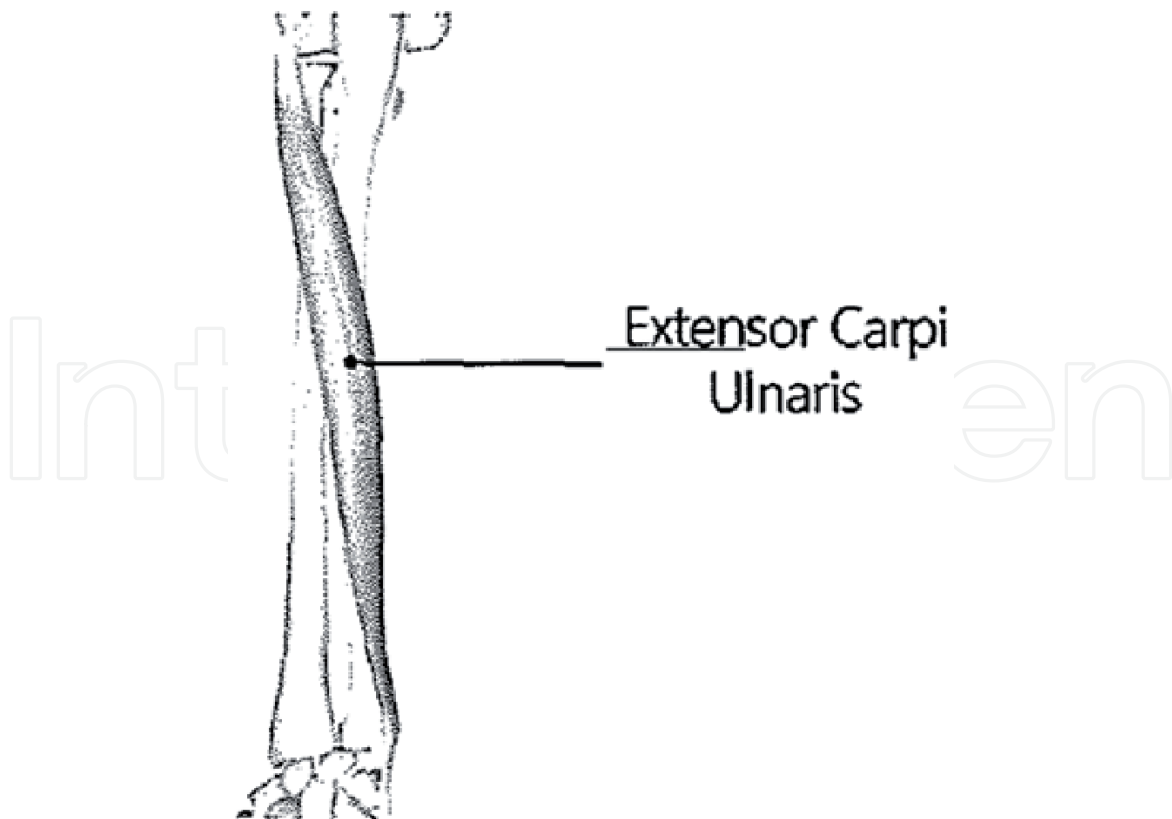


Figure 10.
ECU muscle and tendon origin and insertion.

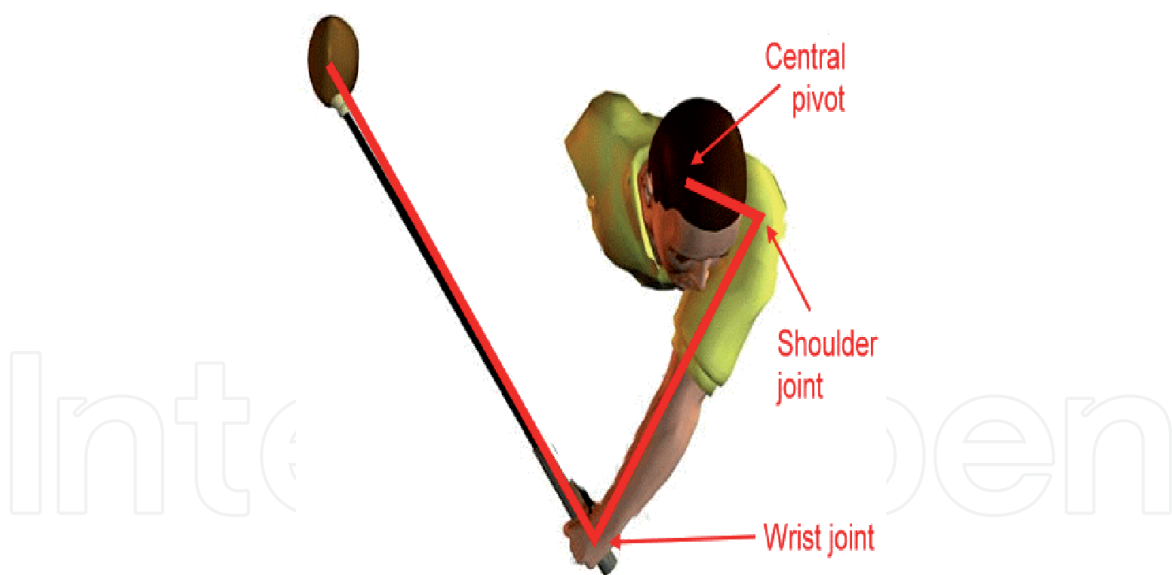


Figure 11.
The double pendulum effect of the golf swing. The first pendulum is the arm acting around the pivot of the shoulder joint and torso. The second pendulum is the golf club acting around the wrist joint.

There are 3 types of injury that occur to the ECU tendon in the golfing population. Each is associated with overuse caused by excessive play and practice accompanied by poor swing technique [36].

1. ECU tenosynovitis or tendinitis
2. ECU Tendinosis
3. ECU Subluxation, (of which there are 3 varieties)

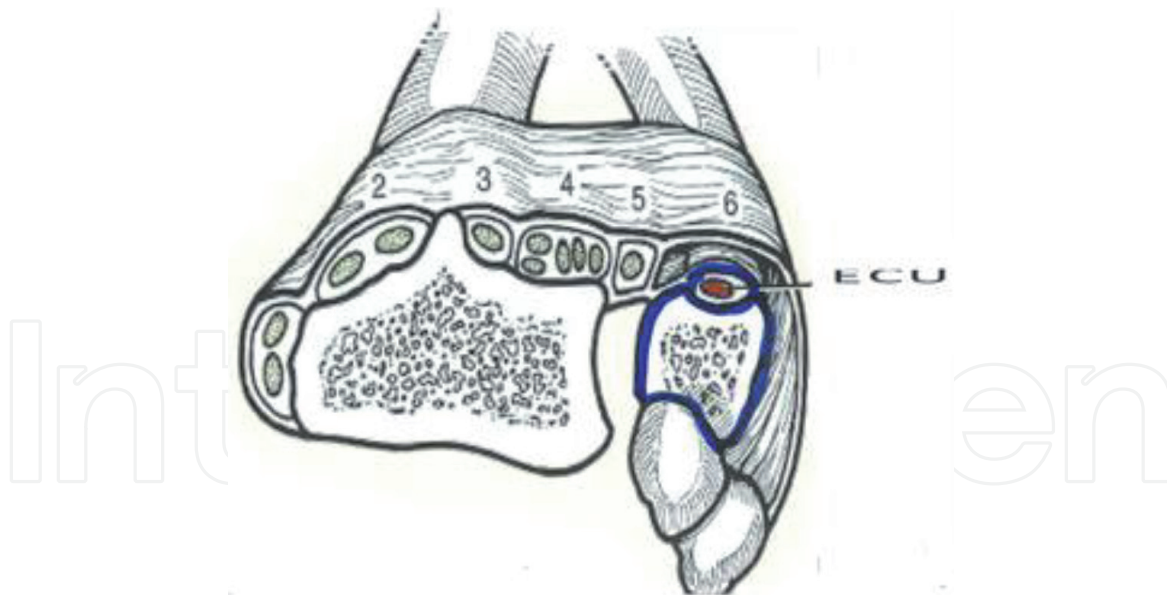


Figure 12.
ECU tendon, tendon sheath and sub sheath in the 6th extensor compartment of the wrist.

Injury to the ECU tendon in the leading wrist of a golfer is common due to the forceful return of the ball as the leading wrist travels from a radial deviated position at the top of the backswing to an ulnar deviated position at impact with the second carpal row transitioning into a supinate position. Injury and subluxation of the ECU tendon are exacerbated by ulnar deviation and supination [37], which is the classical position of the leading wrist at impact during a golf swing. Hence the frequency of this injury in golfers.

20.1.1.1 ECU tendinopathy

Tendinopathy or tendinosis refers to the breakdown of collagen in a tendon. Tendinopathy is often the long consequence of long-term inflammation caused by tendinitis. This causes burning pain in addition to reduced flexibility and range of motion. The collagen loss being a function of tenocyte malfunction secondary to chronic and reoccurring inflammation and injury. ECU tendinopathy occurs over time due to repetitive insults. The Tendinopathy is a pathological adaptive response resulting in degeneration due to the tendon's collagen loss in response to chronic overuse. Loss of function as well as pain on activity are cardinal complaints.

20.1.1.2 ECU tendinitis

Tendinitis is the inflammation of the tendon and results from micro-tears that happen when the musculotendinous unit is acutely overloaded with a tensile force that is too heavy and/or too sudden. ECU tenosynovitis can occur when the extensor retinaculum tears. It can result in mechanical friction between the ECU tendon and the ulnar groove [36, 37]. It usually starts as tendon irritation manifesting as pain and can progress to friction between the tendon and the ulnar groove. In the golf swing the ECU is irritated by the motion to and from ulnar and radial deviation with the wrist in a supinated position. Symptoms include wrist pain and loss of grip strength.

20.1.1.3 ECU tendon subluxation

If the tendon sheath and sub sheath rupture or stretch, the ECU tendon can then migrate to the medial or ulnar side of the wrist. This is caused by a rupture on the

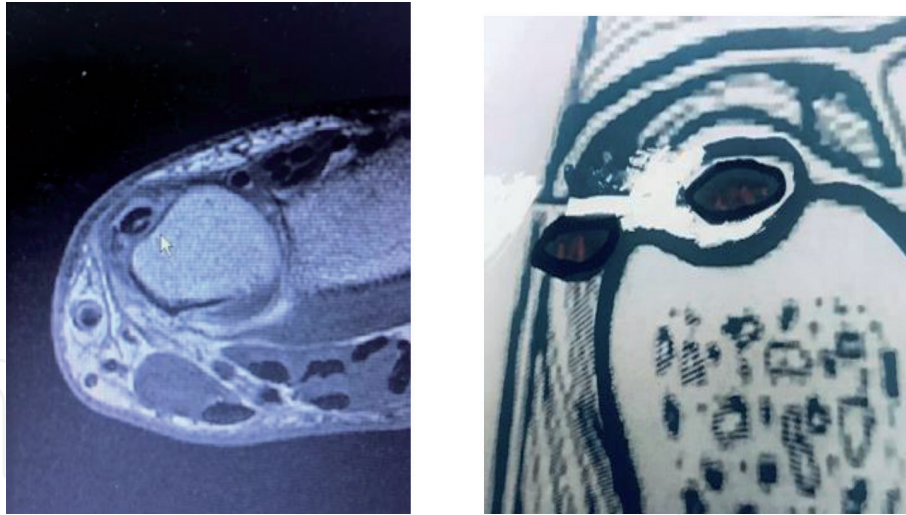


Figure 13.
Axial MR and graphic image of split ECU tendon tear with partial rupture of sub-sheath with medial subluxation of the tendon.

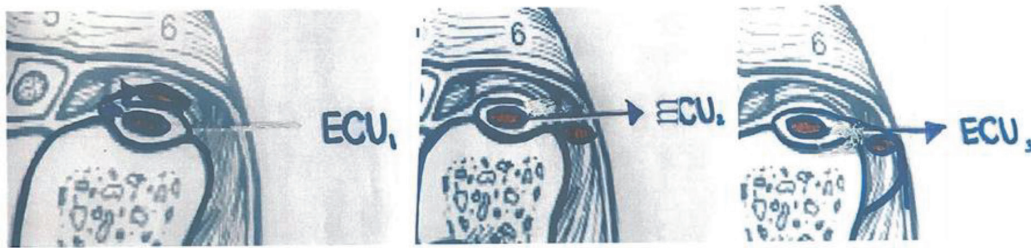


Figure 14.
The 3 types of ECU sub sheath injury resulting in tendon subluxation.

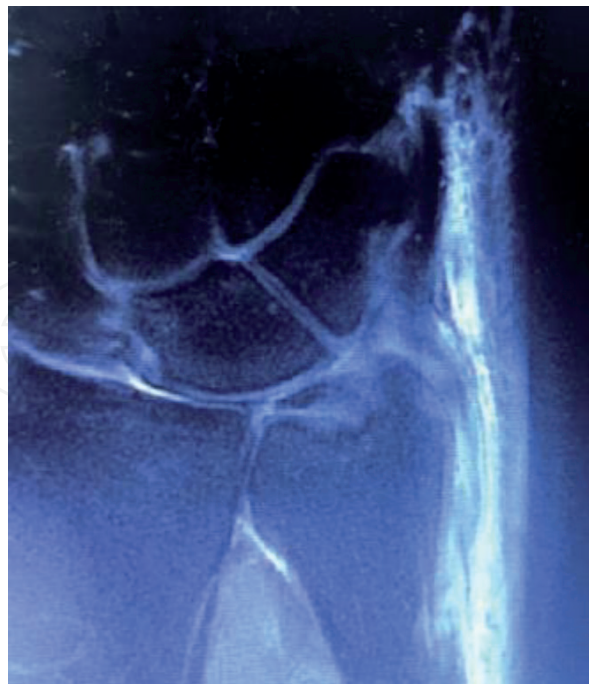


Figure 15.
Coronal MR image showing ECU tear and tenosynovitis.

ulnar or radial side of the tendon sub-sheath, or if the sub-sheath is stretched due to stripping of the periosteum (**Figure 13**). Each type results in subluxation and relocation producing a snapping sensation at the wrist during the golf swing. There are 3 types of ECU tendon sub-sheath injury.

Type 1 (**Figure 14**) rupture occurs on the lateral side of the sub sheath. The tendon subluxes through the radial side of the sheath and returns to rest on the ulnar groove on top of the remaining sheath.

Type 2 (**Figure 14**) rupture occurs on the medial side resulting in a tendon subluxing in an ulnar direction before returning to the ulnar groove without resting on top of the sheath.

Type3 (**Figure 14**) subluxation occurs if the ECU sheath does not rupture but the force causes ulnar periosteum stripping: The ECU sheath pulls the periosteum off the ulna on the ulnar side and forms a false pouch into which the tendon dislocates before relocating back onto the ulnar groove (**Figure 15**).

21. Differential diagnosis of ECU tendon injury in a golfing population

Injury to the ECU tendon is a challenging diagnosis and great care is needed in confirming the pathology. This is in part due to the symptomatology and presentation of injury with players reporting pain on the ulnar aspect of the wrist and hand accompanied by a loss of dexterity and occasionally sensory alteration affecting the fingers. Other conditions to consider in the differential diagnosis include:

- Triangular Fibro-cartilage injury
- Hook of Hamate injury
- Guyon's Canal Syndrome
- Carpal Tunnel Syndrome

21.1 Diagnosis

The diagnosis of ECU tendon pathology in a golfer requires a high index of suspicion as many patients battle on through the pain thereby worsening the pathology. Excluding the other common injuries can be achieved by a combination of careful history, clinical examination and the use of special tests such as Electrodiagnostic Medicine and radiology.

Dynamic ultrasound is very useful in diagnosing and differentiating the type of tendon pathology. It is the ideal tool to confirm a subduing tendon as it observes the subluxation during ulnar and radial deviation and in flexion and extension motion [38]. The direction of subluxation and the type of sub-sheath injury being confirmed by dynamic imaging. In cases of significant subluxation in professional golfers, surgery is often warranted to repair ECU and its supporting structures.

21.2 Treatment

Treatment for these varieties of ECU tendon injury should initially follow the normal treatment for tendinitis such as rest NSAID medication and splinting. Deep Oscillation Therapy has also been shown to be a promising treatment in swelling and symptom reduction [39]. Ultrasound guided injections may also be required in resistant cases. In cases of tendinosis a similar approach is made with the addition of Platelet-Rich Plasma (PRP) injections in resistant cases. This is a minimally invasive surgical alternative that uses components from a patient's own blood to regrow tissue and relieve pain and promotes tendon regeneration by reducing inflammation and promoting the expression of anabolic genes and proteins [40].

Rest and splinting are the cornerstone for treating a subluxing ECU tendon, with regular revaluations with Ultrasound. If the subluxing ECU tendon fails to respond to conservative therapy, surgical reconstruction of the roof of the 6th dorsal extensor compartment using a portion of the flexor carpi ulnaris is performed [41]. Type I subluxation frequently requires surgery.

Return to play will require appropriate alteration in golf grip and swing biomechanics. Therefore, the return to play protocol for this injury in the golfing population should always include an assessment from a registered golf professional. In some instances, customised splinting of the wrist will prevent reoccurrence and allow a golfer return to a bespoke practice regimen. The message of qualitative rather than quantitative practice should be reinforced to avoid a training error reoccurrence, with 30–40 balls a good rule of thumb per practice session.

21.3 Conclusion

Wrist injuries in golf are common and significantly interfere with a player's ability to play and enjoy this common sporting pursuit. The ECU tendon is a frequent cause of wrist pain in the golfer. The sports medicine physician should have a high index of suspicion when dealing with this patient population. A combination of detailed history of injury and golf activity coupled with ultrasound, radiology and electrophysiological evaluation will result in a high diagnostic yield. Treatment should encompass alteration and improvement in golf swing and grip biomechanics as well as any practice or training errors.

22. Other common leading wrist pathologies in a golfing population

22.1 The triangular fibrocartilage injury of the wrist

The triangular fibrocartilage complex (TFCC) (**Figure 16**) is a load-bearing structure between the lunate, triquetrum, and ulnar head. It is a hammock-like structure made up of cartilage and ligaments. It stabilises the bones in the wrist, acts as a shock absorber and enables smooth movements. Forced ulnar deviation and positive ulnar variation are associated with injuries to the TFCC. A “weak” golf grip and swing biomechanics abnormalities makes injury to this structure more common.

The TFCC complex is prone to degeneration and wear-and-tear injuries. Injury occurs when compressive loads are placed on the TFCC during marked ulnar deviation. This occurs in the golf swing when the radial deviation of the wrist at the top

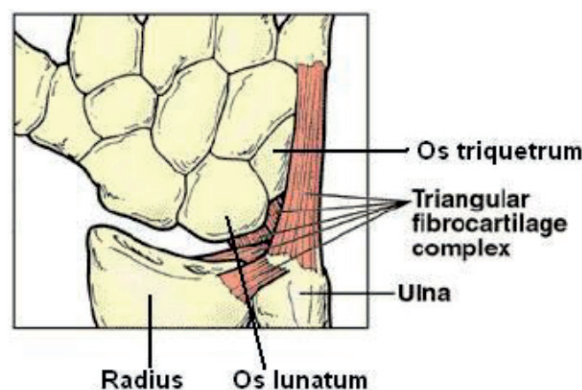


Figure 16.
Triangular fibrocartilage (TFCC).

of the back swing converts into ulnar deviation under significant force at impact. The triangular fibrocartilage disc attachment on the radial side is to hyaline cartilage. This makes the area vulnerable to injury as it is weaker when compared to the ulnar side whose attachment is bony.

Injury to the TFCC can lead to pain, weakness and instability. Patients with TFCC injury will present with ulnar-sided wrist pain that may present with clicking or point tenderness between the pisiform and the ulnar head.

The TFCC can be strained or torn from over-swinging or from “hitting down on the ball”. Hitting out of heavy rough or on hard practice mats are also extrinsic culprits in the development of this injury in the golfing population.

Diagnosis is confirmed by assessment of the sixth extensor compartment. At this location, the TFCC is examined in combination with the ECU tendon. The ECU relies on the TFCC for movement and hence both structures can be injured in combination.

Radiology may reveal avulsion of ulnar styloid, and ulnar variance in cases of the TFCC injury. High-resolution dynamic ultrasound (US) has emerged as a useful and valid tool for the diagnosis of this disorders [36–38].

22.2 Hook of the hamate

The hamate bone (**Figure 17**) is one of the largest carpal bones and is located on the ulnar side of the palm of the hand and forms part of the distal carpal row. It has a protrusion called the “hook of hamate” which with the pisiform bones form the bony boundaries of Guyon’s Canal through which the ulnar nerve enters the wrist joint. Hook fractures can occur from a direct injury to the bone or from an indirect blow that occurs most commonly in sports [42].

In golf, most hook of hamate fractures occur because of the position of the golf club resting on the hook when hitting “down” on the ball, when it is buried in rough or embedded in a divot. These injuries are also common when hitting buckets of balls from a mat at the driving range. Many of the older ranges are built on concrete

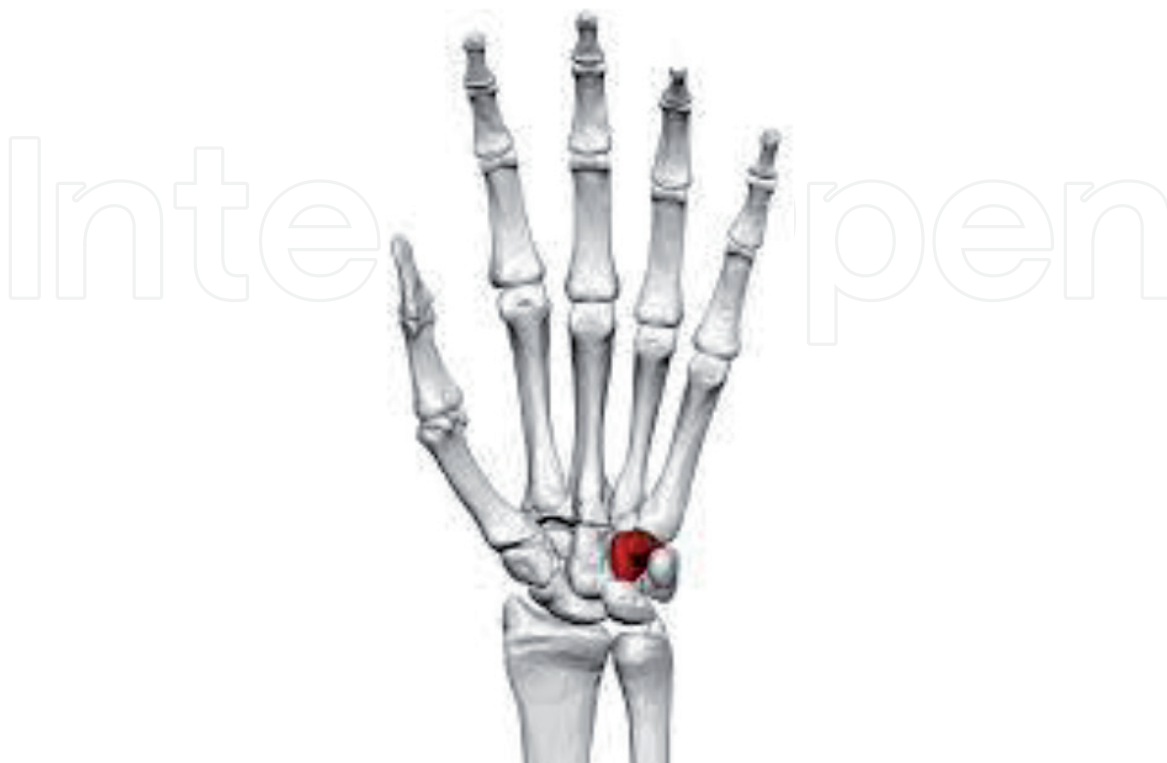

Figure 17.
Hook of the hamate bone.

and injuries occur when the club head stops abruptly on the mat covering the concrete. The force of the impact is conducted through the club shaft and grip into the base of the hand and hamate bone, resulting in injury. That force is transmitted directly to the wrist and can cause a fracture of the hook of the hamate. These injuries occur more commonly in the following wrist [right hand in a right-handed golfer]. While fractures are rare and underreported, they are also frequently misdiagnosed as the initial trauma may seem trivial and present with a working diagnosis of a wrist sprain. Palpation of the hamate with or without ulnar nerve symptoms are cardinal findings. Plain radiology will confirm the diagnosis and conservative treatment such as rest and splinting usually resolves the problem.

22.3 Carpal tunnel syndrome [CTS]

Carpal Tunnel Syndrome (**Figure 18**) is the entrapment of the median nerve and repetitive use of the hands and wrists seen in golf contribute to the development of CTS. Repetitive activity such as golf swinging and practicing can result in flexor tenosynovitis as one or more of the 9 flexor tendons that travel through the Carpal Tunnel in the company of the median nerve become inflamed. Inflammation in the affected tendons in the wrist result in swelling of the sheath. This fluid will compromise the function of the nerve resulting in the symptoms of distal median neuropathy.

Golfers can be difficult to convince that the tingling fingers, numb hands or aching thumb or wrist pain is a result of Carpal Tunnel Syndrome. CTS is considered a disorder that only affects those who do intense repetitive activities all day long at work [43, 44], such as block laying, hairdressing [26] or computer keyboard work. However, in modern society golf driving ranges and facilities are readily available and frequently recreational golfers work harder on their golf than many other vocational pursuits.

Sports, pastimes and hobbies can play a major role in contributing to this repetitive strain induced hand and wrist condition. The repetitive activity causes inflammation to some of the 9 flexor tendons that travel through the Carpal Tunnel. This inflammation results in swelling which ultimately affects the function of the median nerve. CTS diagnosis is made by a combination of electrodiagnostic nerve conduction studies and ultrasound examinations. Treatment of this common condition which affects between 5% and 21% of the population [43–49] involves

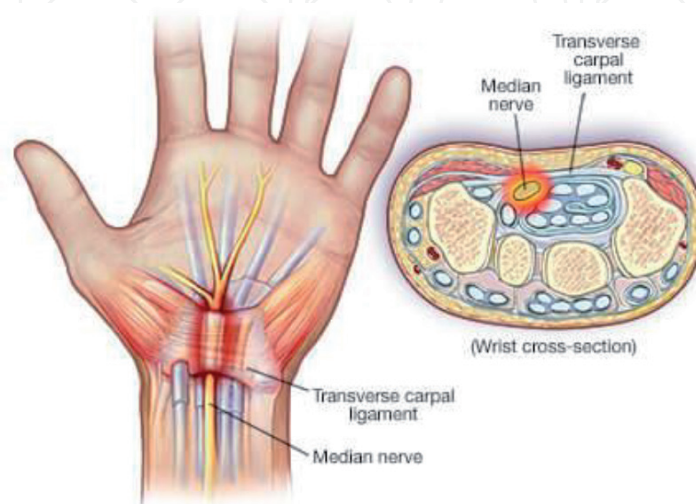


Figure 18.
Carpal tunnel syndrome.

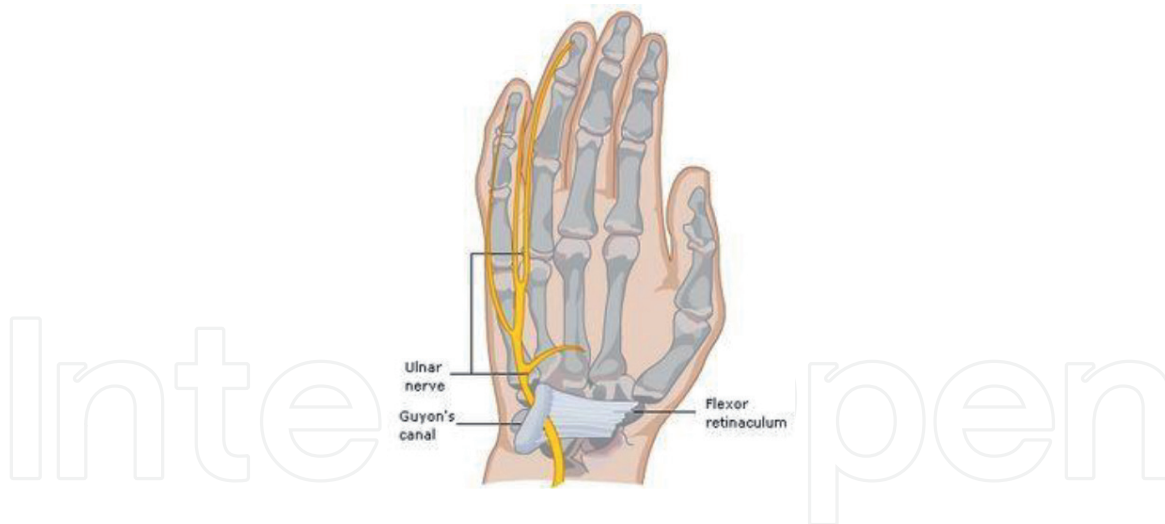


Figure 19.
Guyon's canal syndrome.

a combination of treatments including splinting the wrist, injection therapy and surgery. In the golfer, correction of golf biomechanics and golf club customization are helpful in preventing reoccurrence.

22.4 Guyon's canal syndrome

Guyon's canal syndrome (**Figure 19**) is a condition where there is compression and irritation of the ulnar nerve at the wrist. The ulnar nerve is responsible for strength and sensation on the little finger's side of the fourth finger and the entire fifth finger. Golfers with this condition may present with pain at the base of the wrist, loss of finger function and grip pressure as well as sensory alteration in the 4th and 5th fingers.

The hand may become clumsy when the muscles controlled by the ulnar nerve become weak. Weakness can affect the small muscles in the palm of the hand and the muscle that pulls the thumb into the palm.

Golfers are prone to irritation at Guyon's canal from local trauma to the nerve associated with an improper golf grip and trauma from the butt of the golf club impacting at the base of the wrist [50].

Hard playing surfaces and hitting down on the ball are risk factors.

Diagnosis is made by Electrodiagnostic testing of the distal ulnar nerve. Ultrasound is also used to rule out other space occupying lesions such as a ganglion cyst or schwannoma.

This syndrome is much less common than carpal tunnel syndrome (CTS), yet both conditions can occur at the same time. The numbness by Guyon's syndrome usually spares the thumb, index and long fingers.

23. Less common wrist related pathologies in a golfing population

23.1 Dupuytren's contracture

Dupuytren contracture (**Figure 20b**) is a benign, myeloproliferative progressive disease of the palmar fascia which results in shortening, thickening, and fibrosis of the fascia and aponeurosis of the palm. It results in nodular formation on the palmar fascia which creates fibrosis resulting in one or more fingers become permanently bent in a flexed position. Dupuytren's contracture is caused by progressive

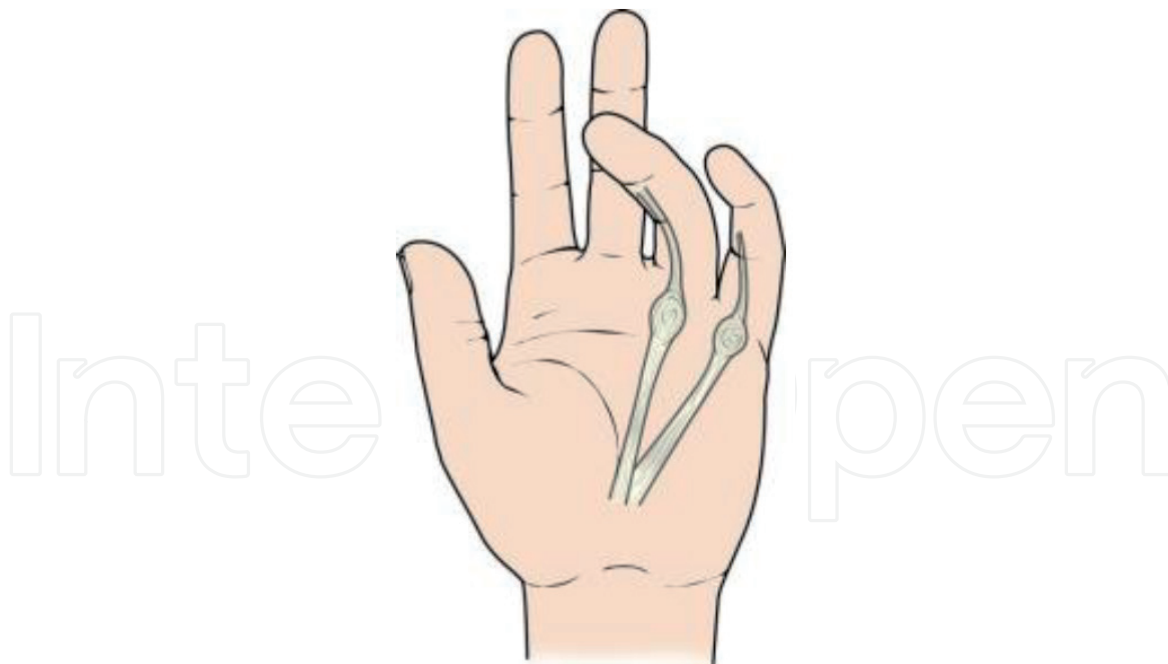


Figure 20.

Dupuytren's contracture caused by shortening, thickening, and fibrosis of the fascia and aponeurosis of the palm, results in nodular formation and a flexion deformity at the 4th and 5th digits, making a consistent grip of a golf club difficult.

thickening and shorting of the palmar fascia. This occurs due to slowly progressing fibrosis in the fascia that results in a flexion deformity at slowly the metacarpophalangeal (MCP) and proximal interphalangeal (PIP) joints usually affecting the 4th and 5th digits. The disease begins in the palm as painless nodules that form along longitudinal lines of tension. The nodules form cords that produce contracture deformities within fascial bands and tissues of the hand.

The disorder has varying pattern of genetic predisposition across different regions and populations and is also known as the Viking disease, and Celtic hand, with 30% of the over 60-year-old male Norwegian population and 20% of a similar British population suffering from this condition [51].

It is expressed in an autosomal dominant fashion. This condition is most commonly seen in populations of Northern European/Scandinavian descent [52]. It is relatively uncommon in Southern European and South American populations. Males are affected by a 2:1 ratio compared to women.

The condition is associated with diabetes, seizure disorders, smoking, alcoholism, HIV, and vascular disease. Ectopic manifestations beyond the hand can be seen in Ledderhose disease of the plantar fascia, Peyronie disease (Dartos fascia of the penis), and Garrod disease (dorsal knuckle pads) [51–53].

Numerous authors going back as far as the 17th century have noted the association between traumatic events and the appearance of Dupuytren's contracture. Initially by Plater in 1614, Goyrand in 1835 and, Guillaume Dupuytren, a French Surgeon in 1833 who the condition is named after [53–56].

Golf has never specifically been cited as a cause of the condition but is a common disability encountered in the older golfer population. The disability causes technical issues gripping and swinging a golf club due to its anatomical location at the base of the wrist and the role of the 4th and 5th digit in gripping a club. Fatigue and hand pain has been reported in elite golfers with this condition and an inability to grip the club consistently.

In a 2017 survey of 504 Dupuytren's sufferers, the Dupuytren's society reported a significant proportion described difficulty golfing due to the pathology. In this

observational study 8% of sufferers without a contracture reported a difficulty, 11% of single hand contracture and 23% of bilateral contracture sufferers reported disfunction while golfing [57].

Up to one-fifth of patients seeking treatment for primary Dupuytren's contracture were reported to suffer from an injury-induced Dupuytren's contracture. It was noted that the injury to the wrist and hand seems to trigger the development of less progressive form Dupuytren's contracture in younger age group [58].

In diagnosing Dupuytren Contracture the clinician needs to distinguish the condition from other diseases of the hand including stenosing flexor tenosynovitis, ganglion cysts, ECU tendon subluxation, Guyon's Canal Syndrome and soft tissue masses. Diabetes, seizure disorders, smoking, alcoholism, HIV, and vascular disease should be considered during a careful history due their association with this condition.

Clinically the condition usually progresses at a slow rate over the course of several years and individuals may not be aware of the condition until it starts to cause functional disability. Pits and grooves in the palm of the hand are an early sign followed by the development of nodules in the medial palm. These nodules are often painless. Pain may be present distally at the knuckles pads of the proximal interphalangeal (PIP) as contracture evolve. The disorder is not always progressive and in at least 50–70% of patients, it may stabilise or even regress.

Investigations include radiology, which is usually normal and serology to out-rule metabolic or infective pathologies which are associated such as Diabetes Mellitus, Alcoholism and HIV infection, if there is a clinical suspicion.

Ultrasound [38] is the diagnostic tool with the highest yield as it confirms the presence of thickening of the palmar fascia and nodule formation.

Treatment includes physical therapy during the early stage of the disease. Some patients may also benefit from a brace to stretch the digits and maintaining range of motion of the fingers is necessary to prevent adhesions. This is particularly important in the golfing population. Corticosteroid injections may be beneficial and should be performed using Ultrasound guidance. Needle aponeurotomy is typically reserved for mild contractures. Collagenase injection which is a relatively new, minimally invasive treatment derived from *Clostridium histolyticum* has shown good initial results. The treatment is not available in all jurisdictions and should only be performed by a hand surgeon who can deal with any potential side effects of this treatment. Surgical fasciectomy is reserved for those cases who have failed conservative therapy and have a persisting disability.

A significant proportion of older golfers suffer from this disability that causes pain, discomfort and impairs the player's ability to consistently grip a golf club, and regularly interferes with the enjoyment of the game. Golf due to trauma may provoke the injury and once present exacerbates the condition. Early identification, finger stretching, as well as the use of topical anti-inflammatory medication assist in reducing symptoms in golfers with mild or non- progressive disease.

Golfers frequently continue to play with this condition. In these instances, the Dupuytren's sufferer should undergo a careful assessment of equipment. Golf shaft weight and grips should be reviewed by a PGA golf professional. In particular, correct or augmented golf grips can facilitate safe and enjoyable golf for the Celtic Hand golfer. Thickening grips can help mitigate overactive hands through the hitting zone thus reducing stress on the palmar aponeurosis. Golf grips come in 4 basic diameters and can be refined by a golf professional by the addition of wraps under the grip, further customising the all-important handle of the golf club. Larger grips also improve shock absorption and reduce transition of force to an already compromised palmar fascia. Small grips result in an increase in grip pressure and a propensity to grip the club in the palm. Holding the club too high across the palm increases the risk of hand injury or the exacerbation of an existing condition. The golfer

should ensure his grip is biomechanically correct and the club is held in the fingers rather than the palm of the hand. This can be achieved by regripping the club in the last three fingers of the leading hand at address, prior to swinging. This helps to stabilise the club at impact and limits the stress on the palm of the hand. These small manageable changes will contribute to lessening the affect that this condition has on recreational and elite golfers.

24. Unusual causes of leading medial wrist injuries in golfers

Rare causes of leading wrist injury in golfers include damage to the Flexor Carpi Ulnaris tendon and proximal entrapment of the ulnar and median nerves, these are rare in golf but are commonly encountered in the general sporting population and among gym users (**Figure 21**).

The Flexor Carpi Ulnaris (FCU) muscle has its origin at the medial epicondyle and it is inserted on the medial side of the wrist into the pisiform, hamate and the base of the 5th metacarpal bone. 5th carpal by a tendinous attachment. The FCU acts as a flexor and ulnar deviator of the wrist. Injury therefore can occur at impact with the ball during the golf swing as the wrist converts into a flexed and ulnar deviated position at impact. In cases of acute trauma, the injury is usually located distally at the level of the pisiform bone insertion. In cases of overuse injuries, the injury is usually proximal to the wrist at the level of the musculotendinous junction. Diagnosis is confirmed by careful palpation of the full length of the tendon. Pain is exacerbated by resisted wrist flexion and ulnar deviation. Ultrasound of the full length of the nerve confirms the diagnosis. The FCU tendon can be also compromised in injuries to the hook pf the hamate bone.

The ulnar nerve can be compromised at the elbow in cases of medial epicondylitis or “golfers elbow”. The ulnar nerve travels through the cubital tunnel prior to entering the ulnar groove as it travels caudally. The cubital tunnel is formed by bone, ligament and muscle.

The tunnel’s ceiling is formed by the cubital retinaculum, a ligament spanning from the medial epicondyle to the olecranon process that is continuous with the fascia connecting the humeral and ulnar heads of the flexor carpi ulnaris (FCU).

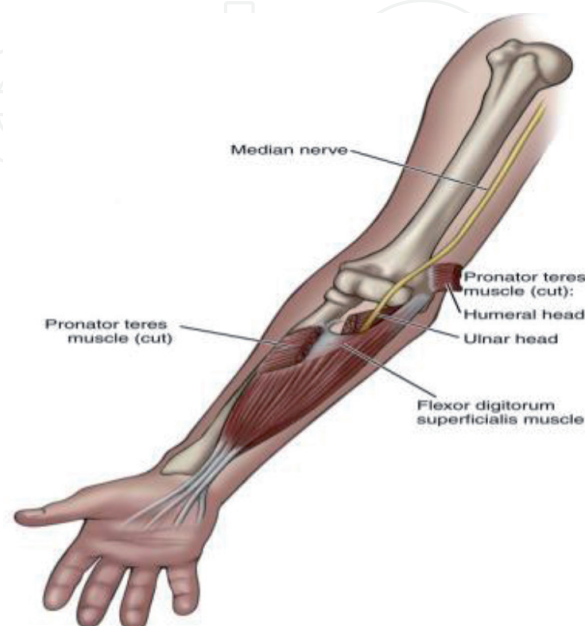


Figure 21.
Proximal entrapment of the median nerve by the pronator Teres muscle.

Injury to these structures or to the flexor tendon insertion at the medial epicondyle can compromise the ulnar nerve resulting in a local irritation or compression of the ulnar nerve, known as Cubital Tunnel Syndrome. Golfers elbow is associated with golf and racket sports. Repetitive activity and holding the elbow in flexion at impact can be aetiological elements in the development of the tendon injury which may be a prequel to the local ulnar nerve irritation. The increased in elbow flexion causes the arcuate ligament to tighten, the FCU to tighten and the ulnar collateral ligament to buckle and encroach into the tunnel compromising the ulnar nerve [59, 60].

This can cause numbness and tingling in the hand and/or ring and little finger, especially when the elbow is bent. Occasionally a player will describe hand pain in the hypothenar eminence when swinging a golf club and weakness when gripping a club and a lack of consistency in golf grip due to muscle weakness in the intrinsic muscles of the hand which receive their innervation from the ulnar nerve.

Diagnosis is made by identifying the clinical signs of an ulnar neuropathy. Electrodiagnostic evaluation with Nerve Conduction Studies and needle EMG. Conservative treatment includes rest and Ultrasound guided injection therapy at the cubital tunnel. In chronic cases surgical release may be required.

Distal median neuropathies can also occur in the golfing population. It is well recognised in racket players [61]. This is referred to as pronator syndrome. The nerve can be compromised at 4 sites in the flexor aspect of the forearm.

The Ligament of Struthers is present in up to 2.7% of the population [62, 63]. Entrapment of the nerve at this site is exacerbated by elbow flexion and extension [63] which is a common manoeuvre in the leading arm of a golfer.

The median nerve travels through the 2 heads of the Pronator muscle just below the elbow joint, and can be compromised at this site. The nerve can also be entrapped by thickening of the bicipital aponeurosis, and finally by the flexor digitorum superficialis. These flexor and pronator muscles are frequently hypertrophied from overuse activities such as repeated golf swinging and practice, particularly in golfers with strong grips (pronated flexed wrists). With this grip the pronator teres muscle has to fire quickly at impact in an effort to square up the club face. The median nerve becoming entrapped at this proximal site. Symptoms are often vague and can suggest a mixed pattern of median and ulnar nerve symptoms. Diagnosis involves electrodiagnostic assessment. Treatment requires rest and alteration in technique and practice protocols. In resistant cases surgery is indicated.

Conclusion

Golf is a centuries old game whose popularity as a sport and entertainment grows exponentially internationally year on year. Increased golf facilities and accessibility have resulted in a world-wide explosion of golf participation. With this, golf related injuries have increased dramatically [64] as experienced and novice golfers alike attempt to imitate the extraordinary feats of distance power and accuracy exhibited by elite golfers who are beamed to out TVs week on week. These players now include 9 million participating at ranges and using indoor simulators [65] who hit “buckets” of balls in a finite period of time without the natural break between shots which occurs in a conventional game of golf. Golf teaching has mirrored these changes as golf is no longer considered a game but a sport, where improvement in performance is an essential component rather than the simple pleasures of walking in the countryside while hitting a ball towards a target in the fresh air. These natural changes in society to become better at this activity have spawned a multitude of teaching facilities in the real world and the cyber world where golfers strive for greater distance and accuracy through strength and conditioning and biomechanics.

Humans are not machines and stress placed on human tissue frequently results in trauma and injury. In the case of the golf swing, sports science and biomechanical advances have improved the performance of golf with the side effect of increased injury, the leading wrist being particularly vulnerable to injury and pathology. The ECU tendon is the most commonly injured leading wrist structure particularly among elite golfers [36, 64]. The sports medicine physician should be aware of this potential and address swing mechanics and the risk reward nature of un-natural motions to the leading wrist in a golfing population to avoid chronic injury, time away from the game [66] and long-term disability.

IntechOpen

IntechOpen

Author details

Conor P. O'Brien
Blackrock Clinic, Blackrock, Co. Dublin, Ireland

*Address all correspondence to: drcob50@gmail.com

IntechOpen

© 2021 The Author(s). Licensee IntechOpen. This chapter is distributed under the terms of the Creative Commons Attribution License (<http://creativecommons.org/licenses/by/3.0>), which permits unrestricted use, distribution, and reproduction in any medium, provided the original work is properly cited. 

References

- [1] Royal & Ancient of St Andrews, Golf around the World ,2019, Edition 3.The R & A St Andrews ,Fife Scotland, KY 169JD
- [2] O'Brien C.P., Recommended physical activity and mortality: a round of golf a day keeps the doctor away BMJ 2020; (Published 12 August 2020) BMJ 2020;370:m3167BMJ 2020
- [3] Zhao M, Veeranki SP, Magnussen CG, Xi B Recommended physical activity and all cause and cause specific mortality in US adults: prospective cohort study. BMJ2020;370:m2031. doi:10.1136/bmj.m2031 pmid:
- [4] Murray A, Junge A, Robinson PG, Bizzini M, Bossert A, Clarsen B, Coughlan D, Cunningham C, Drobny T, Gazzano F, Gill L, Hawkes R, Hospel T, Neal R, Lavelle J, Scanlon A, Schamash P, Thomas B, Voight M, Wotherspoon M, Dvorak A International consensus statement: methods for recording and reporting of epidemiological data on injuries and illnesses in golf. J.Br J Sports Med. 2020 Oct;54(19):1136-1141.
- [5] Zouzias IC, Hendra J, Stodelle J, Limpisvasti O. Golf Injuries: Epidemiology, Pathophysiology, and Treatment. J Am Acad Orthop Surg. 2018 Feb 15;26(4):1
- [6] Lange D Golf Participation in England 2016-2019. Statista, Jan 24 2020
- [7] Robinson P G et al Systematic review of musculoskeletal injuries in professional golfers BJSM January 2019 - Volume 53-1
- [8] Ionnis Z et al Golf Injuries: Epidemiology, Pathophysiology, and Treatment Journal of the American Academy of Orthopaedic Surgeons: February 15, 2018 - Volume 26 - Issue 4 - p 116-123 J Am Acad Orthop Surg 2018 Feb 15;26(4):116-123.
- [9] Gosheger G, Liem D, Ludwig K, Greshake O, Winkelmann W. Injuries and overuse syndromes in golf. Am J Sports Med. 2003 May-Jun;31(3):438-443.
- [10] Hosea T M, Gatt CJ. Back Pain in Golf Clinics in Sports Medicine Volume 15, Issue 1, January 1996, Pages 37-53
- [11] McCarroll J 1996 The frequency of golf injuries Clinics in Sports Medicine, 01 Jan 1996
- [12] Fradkin A J , Finch C F , Sherman C A. Warm-up attitudes and behaviours of amateur golfers Journal of Science and Medicine in Sport Volume 6, Issue 2, June 2003, Pages 210-215
- [13] Sheu Y et al National Health Statistics Reports Number 99 v November 18, 2016 Number 99 v November 18, 2016 U.S. DEPARTMENT OF HEALTH AND HUMAN SERVICES Centers for Disease Control and Prevention National Center for Health Statistics Sports- and Recreation-related Injury Episodes in the United States, 2011-2014 Office of Analysis and Epidemiology
- [14] Campbell D, Campbell R, O'Connor P, Hawkes R. Sports-related extensor carpi ulnaris pathology: a review of functional anatomy, sports injury and management. British journal of sports medicine. 2013;47(17):1105-1111.
- [15] Hawkes R, O Connor P & Campbell D. The prevalence and variety and impact of wrist problems in Elite professional golfers on the European tour BJSM vol 47 issue 17 10.1136/bjsports-2012-091917
- [16] Wiesler E R and Lumsden B, Golf injuries of the upper extremity J Surg Orthop Adv. Spring 2005;14(1):1-7

- [17] Fradkin AJ, Cameron PA, BJ Gabbe BJ. Golf injuries - common and potentially avoidable. *Journal of Science and Medicine in Sport*, Volume 8, Issue 2, June 2005, Pages 163-170
- [18] Theiriault G & LaChance P. Golf injuries. An overview. *Sports Med* 1998 Jul;26(1):43-57.
- [19] C Zheng N, Barrentine S W, Fleisig G S, J. R. Andrews J R. Kinematic Analysis of Swing in Pro and Amateur Golfers. *Int J Sports Med* 2008; 29(6): 487-493
- [20] Springings, E Neal R. The insight into the importance of wrist torque in driving the golf ball, a simulation study. *Journal of applied biomechanics* November 2000 16(4):356-366
- [21] Dahlquest D. Want to start pounding your drives? Learn from the flexed lead wrist of these three pros. *Golf*. Dec 27 2019
- [22] Sutton J, Failes R. Drills to improve wrist mechanics www.Hackmotion.com 8 February 2021
- [23] Lamps M. A. 1975 Maximising the distance of the golf drive, an optimal control study. *Journal of dynamic system, measurement and control*, 4, 362-367
- [24] Foster, L Dr. *Divot's Guide to Golf Injuries: A Handbook for Golf Injury Prevention and Treatment* 2004 Doctor Divot Publishing, Inc ISBN 0974731544
- [25] Gosheger G, Liem D, Ludwig K, Greshake O, Winkelmann W. Injuries and overuse syndromes in golf. *Am J Sports Med*. 2003 May-Jun;31(3):438-443.
- [26] McHardy A, Pollard H, Luo K. One-year follow-up study on golf injuries in Australian amateur golfers. *Am J Sports Med*. 2007 Aug;35(8):1354-1360.
- [27] Cabri J, Sousa J, Kola, P, Barreiros J. Golf related injuries a systemic review. *European Journal of Sports Science* 9.353-366 2009
- [28] Campbell D, Campbell R, O'Connor P, Hawkes R. Sports-related extensor carpi ulnaris pathology: a review of functional anatomy, sports injury and management. *British journal of sports medicine*. 2013;47(17):1105-1111.
- [29] Loew M. Could long term overhead load in painters be associated with rotator cuff lesions. *PLOS One* 2019 June 12; 14(6) e0218484
- [30] Cruz J, Work-related musculoskeletal disorders among the hairdressers, a pilot study Dias- Teixeira. *Advances in Physical Ergonomics and Human Factors* 133-140 2016 Springer
- [31] Batt M A. Survey of golf injuries in Amateur Golfers *BJSM* 26(10:63-65,) 1992
- [32] DiFiori J P et al, Overuse Injuries and Burnout in Youth Sport A Position Statement from the American Medical Society for Sports Medicine, *Clin J Sport Med* Volume 24, Number 1, January 2014
- [33] Waldecker U, Hofmann G, Drewitz S. Epidemiologic investigation of 1394 feet: coincidence of hindfoot malalignment and Achilles tendon disorders. *Foot Ankle Surg Off J Eur Soc Foot Ankle Surg*. 2012;18:119-123.
- [34] Albers IS, Zwerver J, Diercks RL, Dekker JH, Van den Akker-Scheek I. Incidence and prevalence of lower extremity tendinopathy in a Dutch general practice population: a cross sectional study. *BMC Musculoskelet Disord*. 2016;17:16.
- [35] Renstrom P. Sports traumatology today: a review of common current

sports injury problems. *Ann Chir Gynaecol.* 1991;80:81-93.

[36] O'Brien C, "Extensor Carpi Ulnaris Tendon Injuries in Golfers". *EC Orthopaedics* 12.2 (2021): 26-28

[37] Burkhart SS, Wood M D and Linschield R L Post traumatic recurrent subluxation of the Extensor carpi ulnaris tendon 1982 *J Hand Surg.*7,1

[38] Chen I.J., Wang M.T., Chang K.V., Liang H.W. Ultrasonographic images of the hand in a case with early eosinophilic fasciitis. *J. Med. Ultrason.* 2018;45:641-645.

[39] Hausmann M et al. The effectiveness of deep oscillation therapy on reducing swelling and pain in athletes with acute lateral ankle sprains. *Journal of Sports rehabilitation.*2018 Vol 28 issue 8 , p 903-905

[40] Darrow et al., The effect of Platelet Rich Plasma Therapy on unresolved wrist pain. *Orthopaedic and Muscular System: Current Research 2019 Volume 8 Issue 1* 1000268

[41] Halal B, Hand and wrist injuries in Sports Injuries and their treatment. Halal B, King J B and Grange W J Chapman

[42] Hirano K, Inoue G. Classification and treatment of hamate fractures. *Hand Surg.* 2005; 10(2-3):151-7. (A2)

[43] Mediouni Z et al , Carpal tunnel syndrome and computer exposure at work in two large complementary cohorts *PMCID: BMJ Open* 2015 Sep 9;5(9):e008156.

[44] Palmer KT , Carpal tunnel syndrome: The role of occupational factors *Best Pract Res Clin Rheumatol.* 2011 Feb; 25(1): 15-29.

[45] Bekir Enes Demiryurek et al. Prevalence of carpal tunnel syndrome and its correlation with pain amongst female hairdressers *Int J Occup Med*

Environ Health. 2018. 2018 Jan 15;31(3):333-339.

[46] Tanaka S, Wild DK, Seligman PJ, Halperin WE, Behrens VJ, Putz-Anderson V. Prevalence and work-relatedness of self-reported carpal tunnel syndrome among U.S. workers: analysis of the Occupational Health Supplement data of 1988 National Health Interview Survey. *Am J Ind Med.* 1995 Apr;27(4):451-470.

[47] Stevens JC, Sun S, Beard CM, Ofallon WM, Kurland LT. Carpal tunnel syndrome in Rochester, Minnesota, 1961 to 1980. *Neurology.* 1988 Jan;38(1):134-138.

[48] DeKrom M, Knipschild PG, Kester ADM, Thijs CT, Boekkooi PF, Spaans F. Carpal tunnel syndrome – prevalence in the general-population. *J Clin Epidemiol.* 1992 Apr;45(4):373-376.

[49] Atroshi I, Gummesson C, Johnsson R, Ornstein E, Ranstam J, Rosen I. Prevalence of carpal tunnel syndrome in a general population. *JAMA.* 1999 Jul 14;282(2):153-158.

[50] Boylan K et al ,Ulnar neuropathy at Guyon's canal related to improper golf grip technique October 2004 *Muscle and Nerve Conference: 51st Annual Meeting of the AAEM Volume: 30*

[51] Luck, J. Vernon, Dupuytren's Contracture A New Concept of the Pathogenesis Correlated with Surgical Management. *The Journal of Bone & Joint Surgery: June 1959 - Volume 41 - Issue 4 - p 635-664*

[52] Mikkelsen, O. The prevalence of Dupuytren's disease in Norway. A study in a representative population sample of the municipality of Haugesund. *Acta Chir. Scand.* 1978, 138, 695-700. [Google Scholar]

[53] Walthall J, Anand P, Rehman UH. Dupuytren Contracture. *StatPearls [Internet].* 2020 Sep 14.

- [54] Elliot, D.; Ragoowansi, R. Dupuytren's disease secondary to acute injury, infection or operation distal to the elbow in the ipsilateral upper limb a historical review. *J. Hand Surg.* 2005, 30B, 148-156. [Google Scholar] [CrossRef]
- [55] Hueston, J.T. Dupuytren's contracture and specific injury. *Med. J. Aust.* 1968, 1, 1084-1085. [Google Scholar] [CrossRef]
- [56] McFarlane, R.M.; Shum, D.T. A single injury to the hand. In *Dupuytren's Disease: Biology and Treatment*; McFarlane, R.M., McGrouther, D.A., Flint, M.H., Eds.; Churchill Livingstone: Edinburgh, UK, 1990; pp. 265-273. [Google Scholar]
- [57] Eaton C., Charles Eaton
In: Dupuytren, Exercise, General, Sports Dupuytren Research Group, Floor exercises, golf, push-ups, rowing, Sports, weightlifting, yoga. Group Survey Results: Dupuytren, Sports, and Floor Exercises Nov 1, 2017
- [58] Gediminas Samulenas^{1,*}, Rytis Rimdeika^{1,*}, Kęstutis Braziulis¹, Mantas Fomkinas² and Rokas Paškevičius² Dupuytren's Contracture: Incidence of Injury-Induced Cases and Specific Clinical Expression *Medicina* 2020, 56, 323; doi:10.3390/medicina56070323
- [59] Findel W and Stratford J, The role of the cubital tunnel in tardy ulnar palsy. *Clin J Surg*,1: 287-300 ;1958
- [60] Vanderpool SW, Chalmers J, Lamb DW ,Whiston TB: Peripheral compression lesions of the ulnar nerve. *J Bone Joint Surg*,50B, 792-803 ;1968
- [61] Regan WD and Morrey BF
Entrapment Neuropathies about the elbow. In DeLee JC ,Drez D(eds) *Orthopaedic sports medicine* Philadelphia:Saunders 1994 844-859
- [62] Hrdlicka A. Incidence of the supracondylar process in whites and other races. *Am J of Anthropology* 6: 405-406 ; 1923
- [63] Bilge T , Yalman O, Bilge S et al Entrapment neuropathies of the median nerve at the level of the ligament of Struthers *Neurosurg*, 27 (5):787-789 1990
- [64] O'Brien C. ECU tendon Injury in an Elite Golfer. *J Sports Med Orthop Adv.* 2021;1(1):1-4.
- [65] National Golf Foundation <https://www.ngf.org> 2019 Golf Industry report
- [66] O'Brien C Golf Injuries Irish Medical News November 1993