

# Foreign body ingestion and aspiration at a pediatric center in northern Iran

## Original Article

Somayeh Shirkosh<sup>1</sup>  
Naeimeh Nakhjavani<sup>2</sup>  
Mohammadreza Esmaili Dooki<sup>\*3</sup>  
Abbas Hadipour<sup>4</sup>  
Soheil Osia<sup>2</sup>  
Mahmoud Hajiahmadi<sup>4</sup>

1. The Clinical Research Development Unit of Amirkola Children's Hospital, Babol University of Medical Sciences, Babol, IR Iran

**ORCID ID** [orcid.org/0000-0003-1525-7936](https://orcid.org/0000-0003-1525-7936)

2. The Clinical Research Development Unit of Amirkola Children's Hospital, Babol University of Medical Sciences, Babol, IR Iran

3. Non-Communicable Pediatric Diseases Research Center, Health Research Institute, Babol University of Medical Sciences, Babol, IR Iran

**ORCID ID** [orcid.org/0000-0002-0815-4499](https://orcid.org/0000-0002-0815-4499)

4. Non-Communicable Pediatric Diseases Research Center, Health Research Institute, Babol University of Medical Sciences, Babol, IR Iran.

### \* Correspondence:

**Mohammadreza Esmaili Dooki**,  
Non-Communicable Pediatric Diseases Research Center, Department of Pediatric gastroenterology, Amirkola Children's Hospital, Amirkola, Babol, Mazandaran Province, 47317- 41151, Iran.

**E-mail:** [esmaeilidooki@yahoo.com](mailto:esmaeilidooki@yahoo.com)

**Tel:** +98 1132346963

**Fax:** +98 1132346963

**Received:** 10 Dec 2020

**Revised:** 20 Jan 2020

**Accepted:** 14 Feb 2020

## Abstract

**Background:** Aspiration or ingestion of foreign bodies (FBs) is a common health problem leading to hospitalization of children around the world. The purpose of this study was to detect the FBS of aspirated or swallowed in children.

**Methods:** The present cross-sectional descriptive-analytical study was conducted on 77 hospitalized children due to FBs aspirated or swallowed from 2008 to 2013 at Amirkola Children's Hospital. Information including demographic profile, type of FBs and their location, clinical manifestations, treatment used and possible complications were extracted from their medical records, and the data were analyzed.

**Results:** Out of 76 cases, 51 (67.1%) were boys; 47.4% of children were 1-2 years old (mean age  $2.6 \pm 2.2$  years), and 67.1% of the bodies were in the gastrointestinal tract. The most common FBs were foodstuff (42.1%), metallic bodies (39.5%) and non-metallic bodies (18.4%), respectively. The most common symptoms were cough (84%) in respiratory FBs and vomiting (57%) in gastrointestinal FBs. The mean duration of hospitalization was  $74.8 \pm 57.1$  hours in gastrointestinal FBs and  $126.7 \pm 56$  hours in respiratory FBs. There was a significant statistical relationship between location of FBs ( $p=0.000$ ) and type of swallowed or aspirated bodies ( $p=0.041$ ) with the duration of hospitalization. No mortality was observed.

**Conclusions:** Findings show that foodstuffs are the most abundant FBs aspirated or swallowed in children aged 1-2 years. Obviously, educating parents and caregivers to take required care of children, especially while eating in this particular age group, is a key element in reducing such injuries.

**Keywords:** Child, Foreign bodies, Respiratory aspiration, Swallowing

## Citation:

Shirkosh S, Nakhjavani N, Esmaili Dooki MR, et al. Foreign body ingestion and aspiration at a Pediatric Center in northern Iran. *Caspian J Pediatr* March 2020; 6(1): 399-406.

## Introduction

Foreign body injuries are very common in children so that they are the major causes of childhood morbidity and mortality [1]. The main concern about foreign body injuries is that they may be asymptomatic or have nonspecific signs. Foreign body injuries may be confused with a gastrointestinal or respiratory infection. If the injury has no evidence, the lack of specific signs indicating foreign body injury can lead to delayed diagnosis and subsequent increased risk of complications [2]. Foreign bodies may accidentally enter the human body by inhalation, aspiration, ingestion, swallowing or trauma [3]. Swallowing or aspirating the FBs is preventable events. Most FBs are excreted spontaneously through protective reflexes, such as coughing or spitting, or pass through the gastrointestinal tract without complication, but a significant percentage affects the upper gastrointestinal tract [4]. In the event of a delay in diagnosis, airway damage from aspirated or inhaled FBs may lead to severe

complications such as asphyxia, pneumonia, atelectasis and bronchiectasis [5]. On the other hand, if the swallowed FBs in the esophagus are not detected and treated in time, they can lead to complications such as mucosal damage, bleeding, ulcers and esophageal perforation and formation of tracheoesophageal fistula [6]. According to the reports, the age of children and type of FBs are very different. However, most children between the ages of 1 and 3 are the most common victims of foreign body aspiration for reasons such as lack of teeth and poor swallowing, tendency to discover bodies with mouth and play during swallowing, lack of cognitive ability to distinguish between foodstuff and non- foodstuff objects [4]. The most common objects that children put in their mouths are the ones that are sleek and easy to grab including coins, button cells, magnets, screws and small keys [7], which are different according to the age of the child, eating habits and traditions of different communities [8]. Despite advances in the clinical treatment of children with FBs, reducing the risk of complications and death and advancing ways to prevent FBs, recognizing the types of FBs that cause injuries, signs associated with swallowing/inhaling/entering them (which provides early detection of FBs) and side effects related to the characteristics (type, shape and classification) of FBs are critical. However, despite the high incidence of this type of injury, according to studies [9-11], the limited high quality evidence is available about foreign body aspiration [12]. Therefore, further epidemiological studies are needed for each country and region to determine the pattern of this condition to take preventive measures [13]. In this regard, the aim of the current study was to detect respiratory-gastrointestinal FBs in children at Amirkola Children's Hospital, Babol, Iran, from 2008 to 2013.

## Methods

This descriptive-analytical and cross-sectional study was conducted over a 6-year period (January 2008 to December 2013) at Amirkola Children's Hospital. Using a hospital information system, the study examined the medical records of 77 children older than one month, who were hospitalized with a final diagnosis of swallowing or aspiration of a foreign body, and stayed in hospital for at least six hours, or transferred to other more specialized centers due to major injuries, and selected by census method. Outpatient and re-admission cases were excluded from the study to limit the impact of related variables. In

addition, cases with mental retardation or neurological abnormalities and incomplete files were excluded from the study. Detection of foreign body cases was made in the hospital information system according to the International Classification of Diseases, version 10 (ICD-10). Diagnosis of FBs was based on history and physical examination and radiological findings. X-rays of the neck and chest (anterior-posterior and lateral view) were performed to confirm the location and displacement or excretion of foreign objects in the respiratory and gastrointestinal tract. Then, the patients were classified into two groups of respiratory foreign body aspiration and gastrointestinal foreign body swallowing according to the location of foreign body aspiration and swallowing, respectively. In the first group, the aspirated FBs were stuck in the airways from the trachea to the bronchi of the lungs. In the second group of patients, the swallowed FBs were stuck in the gastrointestinal tract from the mouth to the anus. Information including demographic profile, type of FBs and their location, clinical manifestations, hospitalization details, treatment used and possible complications was collected and recorded in an information form. The data were analyzed using SPSS23 software. Descriptive statistics were expressed as frequency and frequency percentage, mean and standard deviation and 95% confidence interval as well as the Chi-square and Pearson correlation tests were used to analyze the data. P value < 0.05 was statistically considered as significant level.

## Results

The results showed that 77 children were hospitalized with the final diagnosis of swallowed or aspirated FBs during this period; one case with mental retardation was excluded from the study. Out of 76 patients, 51 (67.1%) cases were boys. The age of the majority of the injured cases (n=36, 47.4%) was 1-2 years (Table 1). The mean age of the children was 2.6±2.2 years (1 month-12 years). Of these, 51 (67.1%) cases of FBs were in the gastrointestinal tract and 25 (32.9%) ones in the respiratory tract. Of the 51 gastrointestinal FBs, 5 cases (9.8%) previously undergone reconstructive surgery had esophageal atresia (P=0.453). According to the initial graph, out of 51 cases of gastrointestinal foreign body swallowing, 36 cases were (70.5%) in the esophagus, 2 cases (3.9%) in the stomach, 13 cases (25.5%) in the small intestine. Of the 25 cases of aspirated FBs, 17 (68%) were found in the right lung, 5 (20%) in the left lung

and 3 (12%) in both lungs. According to the results of the study, the most common FBs found in children's respiratory and gastrointestinal tract were 32 foodstuff items (42.1%), 30 metallic bodies (39.5%) and 14 non-metallic bodies (18.4%), including plastic of the toy parts, respectively. Among foodstuff FBs, the most common item was grains (n=20, 62.5%). Among the metallic bodies, the most common one was the coin (n=13, 43.3%). In our study, there was a statistically significant relationship between age group and foreign body type ( $p = 0.003$ ). The most common types of FBs were metallic bodies in children <1 year of age and >3 years of age, and foodstuff in children aged 1-2 years (figure 1).

In the majority of cases, 71 cases (93.4%) had no specific treatment at home. Three children (4%) received certain foods such as milk, water or juice. In the remaining two cases (2.6%), a special maneuver was performed to remove the object. The signs and symptoms of FBs are separately shown based on their location in table 2. According to the results of this table, the most common symptom was cough (21 cases) in respiratory foreign body aspiration, and vomiting (29 cases) in gastrointestinal foreign body swallowing. Other symptoms included odynophagia, excessive drooling, stridor, fever due to the pneumonia and gastrointestinal infections and dyspnea, respectively (table 2).

In all cases, rigid bronchoscopy was performed for respiratory foreign body aspiration, and the foreign body was removed. Out of a total of 51 gastrointestinal foreign body swallowing cases, flexible fiberoptic endoscopy was performed in 37 cases (72.5%), and foreign body was removed. Of the remaining 14 cases (27.4%) of gastrointestinal foreign body swallowing, 1 (2%) case was in the stomach and the rest in the small

intestine; the FBs were spontaneously expulsion under patient observation with repeated graphs.

The mean duration of hospitalization was  $74.8 \pm 57.1$  hours in the gastrointestinal foreign body swallowing group (with a minimum of 24 to a maximum of 288 hours) and  $126.7 \pm 56$  hours in the respiratory foreign body aspiration (with a minimum of 48 to a maximum of 240 hours), and there was a statistically significant difference in the duration of hospitalization between two groups. The mean duration of hospitalization was longer in the respiratory group than in the gastrointestinal group. In the present study, there was a significant statistical relationship between the location of FBs ( $p=0.000$ ) and the type of swallowed or aspirated bodies ( $p=0.041$ ) with the duration of hospitalization (figures 2, 3).

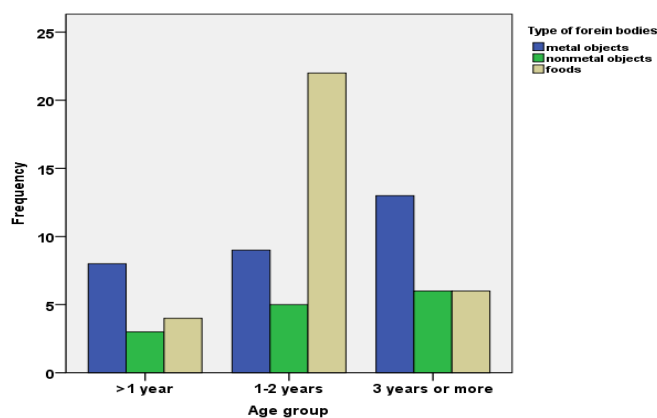
The majority of patients (n=30, 39.5%) were hospitalized for 2 days and some (n=15, 19.7%) for 3 days. The outcomes of respiratory and gastrointestinal injuries caused by FBs in most cases (n=63, 83%) were treatment and discharge of the child. Eight children (10.5%) were discharged before treatment with parental consent. Five cases (6.6%) were transferred into the pediatric intensive care unit (PICU) and discharged after treatment; all 5 cases had respiratory injuries. No mortality was observed.

The duration from the accident to the hospital stay was a minimum of 9 minutes to a maximum of 12.5 hours. The majority of patients (n=39, 51.3%) referred to the hospital 1-6 hours after aspiration or swallowing FBs.

The majority of respiratory and gastrointestinal injuries occurred in the spring (n=25, 32.9%), summer (n=20, 26.3%), autumn (n=18, 23.7%) and winter (n=13, 17.1%), respectively. Of the 25 cases of respiratory and gastrointestinal FBs in the spring, 10 (40%) were during the Nowruz holiday ( $p=0.000$ )

**Table 1. Distribution of FBs cases according to gender and age group**

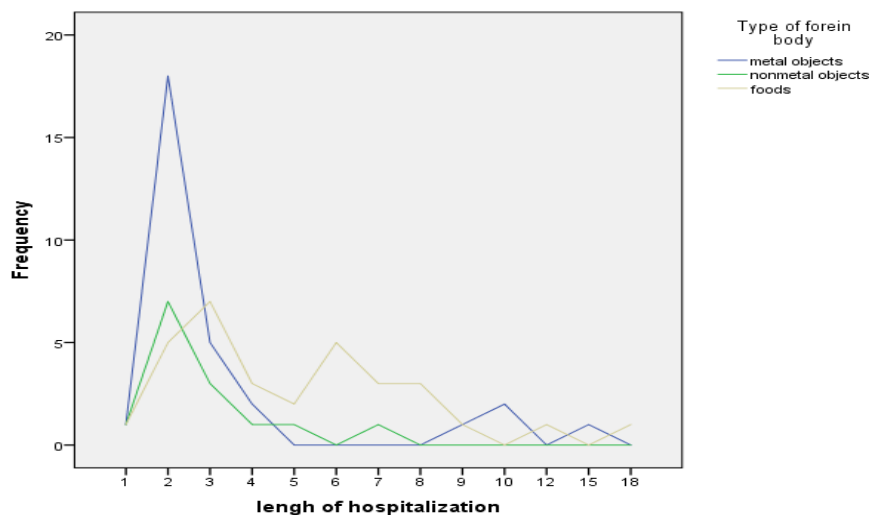
Age	Gender of child		Total	Percentage
	Male	Female		
>1 year	11	4	15	19.7
1-2 years	21	15	36	47.4
3 years or more	19	6	25	32.9
<b>Total</b>	<b>51</b>	<b>25</b>	<b>76</b>	<b>100</b>



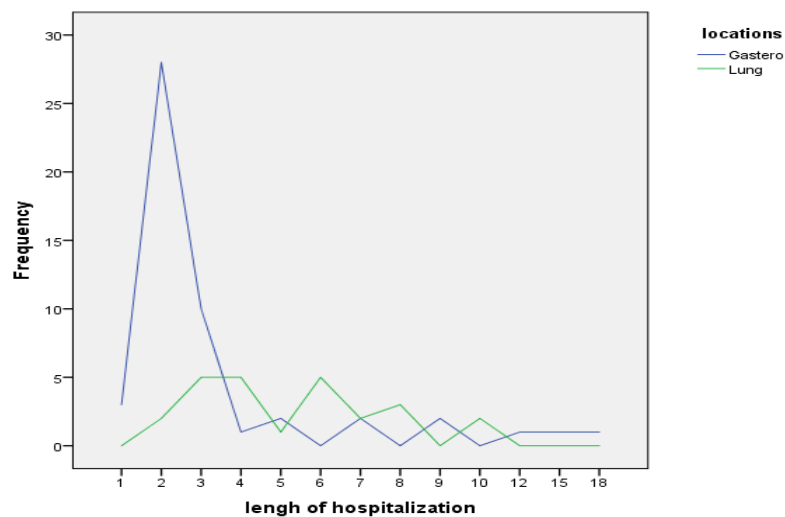
**Figure 1. Age distribution of cases according to type of FBs**

**Table 2. Frequency distribution of signs and symptoms according to the location of FBs**

Symptoms	Respiratory tract	Gastrointestinal tract	Total
Asymptomatic	1	14	15
Cough	21	4	25
Dyspnea	4	-	4
Stridor	5	-	5
Vomiting	1	29	30
Odynophagia	2	7	9
Fever	2	3	5
Excessive drooling	-	9	9



**Figure 2. Distribution of various FBs according to the length of hospital stay**



**Figure 3. Distribution of FBs according to the length of hospital stay**

## Discussion

This study showed that foodstuffs were the most abundant FBs aspirated or swallowed in children aged 1 to 2 years. Also, the incidence rate of FBs' aspiration and ingestion was higher in boys than girls, which is similar to the results of previous

studies [9, 10, 14]. This may be due to the fact that boys are more adventurous and curious during their developmental period compared to girls.

In the present research, the mean age of the children was  $2.6 \pm 2.2$  years. In a study of Patil et al., the mean age of the children was 2.5 years [15]. In a

study of Majola et al., the mean age of the children was 3 years and 6 months <sup>[11]</sup>.

A variety of reasons including social factors (such as parental carelessness, habit of putting objects in the mouth, crying or playing while eating), anatomical factors (such as not having molars) and insufficient swallowing control indicate high incidence of aspiration or swallowing of FBs in this age group <sup>[16]</sup>.

The results of the present study suggested that the majority of cases (67.1%) were gastrointestinal foreign body swallowing and in the esophagus with higher frequency (n=36, 70.5%). In a study of Majola et al., the majority (62.6%) of FBs were in the esophagus <sup>[11]</sup>. In our study, 5 out of 51 gastrointestinal foreign body swallowing cases experienced esophageal atresia, which had previously undergone reconstructive surgery. Despite the lack of significant statistical relationship between esophageal atresia and gastrointestinal foreign body swallowing in our study, the results of several studies <sup>[17-19]</sup> have demonstrated that the structural abnormalities of the gastrointestinal tract such as esophageal atresia, tracheoesophageal fistula undergoing reconstructive surgery are due to impaired peristaltic movements and anastomotic stenosis in the repaired part of the esophagus prone to foreign body obstruction <sup>[17]</sup>.

In the present study, 68% of the FBs found in the lungs were in the right main bronchus. In most studies, among the FBs found in the airways, the majority were in the right lung <sup>[14, 20]</sup>. The reason for this is the anatomical structure of the right main bronchus with a larger diameter and straighter than the trachea.

According to the results of the present study, the most common FBs found in the respiratory and gastrointestinal tract in children were foodstuff, metallic bodies and non-metallic bodies (including plastic, toy parts), respectively. Among foodstuff FBs, the most common ones were grains, and among metallic bodies, the most common ones were coins. In the study of Majola et al., the most common swallowed or aspirated foreign body was coin <sup>[11]</sup>. In a study of Cevik et al., most inorganic FBs in children were coins, beads, needles, toys, and school supplies <sup>[14]</sup>. In a study of Kumar et al., the most common swallowed or aspirated FBs included coins, peanuts and button cells <sup>[21]</sup>.

These findings suggest that the swallowed or aspirated FBs in children vary according to their

eating habits as well as their cultural and socioeconomic status of different communities.

In the ongoing study, the most common symptoms were cough in respiratory foreign body aspiration, and vomiting in gastrointestinal foreign body swallowing. The severity of symptoms depends on the position of the object in gastrointestinal tract, size and type of object, duration of swallowing or aspiration of the object as well as age and size of the child <sup>[22]</sup>.

In a study of Gupta et al. on patients with foreign body obstruction in the gastrointestinal tract, the most common symptoms were swallowing problems, painful swallowing, foreign body sensation and vomiting. In patients with respiratory foreign body aspiration, the most common symptoms were rhonchi, diminished breath sounds and shortness of breath <sup>[9]</sup>. In a study of Nakku et al., the most common symptoms were sudden onset of cough and shortness of breath accompanied by airway foreign body aspiration and vomiting accompanied by foreign body swallowing <sup>[23]</sup>.

In the present research, no specific treatment was performed at home in 93.4% of cases. In a study of Nakku et al., no specific treatment was performed at home in the majority of cases except that one parent/caregiver attempted to perform Heimlich maneuver after the child had swallowed the coin <sup>[23]</sup>. In our study, the parents/caregivers of two cases performed a specific maneuver to exit the foreign body. This may be due to a lack of information from parents and caregivers about their immediate action or fear and anxiety.

The treatment of foreign body obstruction varies according to their location. However, the preferred treatment for foreign body obstruction in the respiratory and gastrointestinal systems is endoscopic foreign body retrieval <sup>[4]</sup>. In our study, rigid bronchoscopy was a therapeutic procedure performed on respiratory tract injuries in all cases. In 72.5% of cases of gastrointestinal tract injuries, the flexible fiberoptic endoscopy was performed, and the object was removed. In the remaining 27.4% of gastrointestinal foreign body swallowing, 1 (2%) was in the stomach and the rest in the small intestine, and the FBs were spontaneously excreted by patient monitoring.

In a study by Majola et al., 62.6% of FBs were subjected to rigid esophagoscopy and 12.1% to rigid bronchoscopy, and 12.1% were spontaneously

excreted [11]. In a study of Truong et al., the bronchoscopy was performed in 91.4% of respiratory foreign body aspiration cases, and esophagoscopy in 93.7% gastrointestinal foreign body swallowing cases [24].

In the present study, the mean duration of hospitalization was  $74.8 \pm 57.1$  hours in gastrointestinal foreign body swallowing group and  $126.7 \pm 56$  hours in respiratory foreign body swallowing group. In the study of Cevik et al., the mean duration of hospitalization was  $103.3 \pm 25.8$  hours for FBs in the gastrointestinal tract and  $126.7 \pm 57.1$  hours for FBs detected in the respiratory tract [14]. Comparison of the mean duration of hospitalization in two studies revealed that the duration of hospitalization was higher in both groups of our study than in the study of Cevik et al. It seems that the reason for this discrepancy may be due to differences in the type of FBs and their side effects. Despite the differences in the mean duration of hospitalization in these two studies, there is a statistically significant relationship between the duration of hospitalization and the location of FBs in both studies. The mean duration of hospitalization was longer in the respiratory group than in the gastrointestinal group ( $p=0.000$ ).

In the current study, the consequence of respiratory and gastrointestinal injuries resulting from FBs in 83% of cases was treatment and discharge of the child. In the study of Cevik et al., 69.7% of cases were discharged within 24 hours [14]. The consequences will certainly vary depending on the type of FBs, location of the object in the respiratory and gastrointestinal tract, duration of swallowing or aspiration of the object, and the age and size of the child.

In our study, the majority of patients (51.3%) went to the hospital between 1 to 6 hour after swallowing or aspirating the FBs. In a study of Gilyoma and Chalya, the majority of patients were referred to centers within 24 hours after swallowing or aspirating the FBs [16]. In a study of Verma et al., 52% of patients went to the hospital within 24 hours after swallowing or aspirating the FBs [25].

It seems that the difference in the time interval depends on the severity of the signs or complications. However, if this interval is short, it is more likely to be successful in detecting and exiting the foreign body and reducing possible complications.

In the present study, the majority of cases of swallowed or aspirated FBs were in the spring with more abundance in late March, while in the study of Cevik et al., most cases were hospitalized in the cold season of the year [14]. It seems that the difference in children's eating habits in different seasons of the year in different societies, which is due to the cultural and economic differences that govern that society, can be one of the reasons for the differences between our findings and other studies. One of the most obvious cultural differences is the consumption of nuts and seeds during the Nowruz holiday in Iran, which coincides with the second half of March.

The present study showed that the respiratory and gastrointestinal injuries caused by foreign body obstruction often occurred in boys aged 1-2 years. The most common of these FBs are foodstuffs, especially grains and metallic materials, often coins. Our findings suggest that the prevention is a key measure to reducing such injuries [26]. The prevention is at three levels: primary, secondary and tertiary [27]. The primary prevention includes educating parents or caregivers about preventing the aspiration or swallowing of FBs, keeping fine bodies out of the reach of children and not leaving children unattended, especially when eating and educating older children [28]. In the secondary prevention, which includes early detection and treatment of injuries, in case of respiratory or gastrointestinal injuries or suspicion, the child should be taken to medical centers as soon as possible. The goal of tertiary prevention is to reduce the complications of already occurred injuries. This level of prevention is fulfilled by providing effective emergency medical care in the form of stabilization and immediate transfer of the injured child to specialized centers, better and timely interventions and care, as well as performing rehabilitation in case of disability in injured children.

One of the most important limitations of this study is the retrospective nature of the research and dependence on the quality of patients' medical records.

## Acknowledgement

Hereby, the authors express gratitude to the Research Centre of Non-Communicable Pediatric Diseases, authorities of Amirkola Children's Hospital

and advisors of the article for assisting us in performing the research.

**Funding:** This article is the result of the research project approved by Non-Communicable Pediatric Diseases Research Center of Babol University of Medical Sciences and supported financially by this university. (Grant Number: 2132).

**Conflict of interest:** None

**Ethical approval:** This study obtained Ethics Committee approval. (Ethical code: MUBABOL.REC.1392.26)

### References:

1. Van As ABS, Yusof AM, Millar AJ, Group SSW. Food foreign body injuries. *Inter J Pediatr Otorhinolaryngol* 2012; 76: S20-5.
2. Passali D, Gregori D, Lorenzoni G, et al. Foreign body injuries in children: a review. *Acta Otorhinolaryngol Italica* 2015; 35(4): 265.
3. Foltran F, Ballali S, Rodriguez H, et al. Inhaled foreign bodies in children: a global perspective on their epidemiological, clinical, and preventive aspects. *Pediatr Pulmonol* 2013; 48(4): 344-51.
4. Rodríguez H, Passali GC, Gregori D, et al. Management of foreign bodies in the airway and oesophagus. *Inter J Pediatr Otorhinolaryngol* 2012; 76: S84-91.
5. Foltran F, Gregori D, Passali D, et al. Toys in the upper aerodigestive tract: evidence on their risk as emerging from the ESFBI study. *Auris Nasus Larynx* 2011; 38(5): 612-7.
6. Teisch LF, Tashiro J, Perez EA, et al. Resource utilization patterns of pediatric esophageal foreign bodies. *J Surg Res* 2015; 198(2): 299-304.
7. Kirkham EN, Kane M, Paul SP. Foreign body ingestion in children. *Community Practitioner* 2015; 88(3): 45-9.
8. Dereci S, Koca T, Serdaroglu F, Akcam MJTAoPTPA. Foreign body ingestion in children. *Turkish archives of pediatrics* 2015; 50(4): 234.
9. Gupta R, Poorey V. Incidence of foreign bodies in aerodigestive tract in vindhya region: our experience. *Indian J Otolaryngol Head Neck Surg* 2014; 66(2): 135-41.
10. Sinikumpu JJ, Serlo W. Confirmed and Suspected Foreign Body Injuries in Children during 2008–2013: A Hospital-Based Single Center Study in Oulu University Hospital 2017; 106(4): 350-5.
11. Majola N, Kong V, Mangray H, et al. An audit of ingested and aspirated foreign bodies in children at a university hospital in South Africa: The Pietermaritzburg experience. *South African Med J* 2018; 108(3): 205-9.
12. Passali D, Kim CS. FB injuries: The urgent need for updating the field. *Intern J Pediatr Otorhinolaryngol* 2012; 76(Suppl 1): S2.
13. Yadav S, Yadav S, Agrawal J, Shah G. Pattern of acute poisoning in children in a tertiary care hospital in Eastern Nepal. *Inter J Contempor Pediatr* 2016; 3(3): 1001-5.
14. Cevik M, Gokdemir MT, Boleken ME, et al. The characteristics and outcomes of foreign body ingestion and aspiration in children due to lodged foreign body in the aerodigestive tract. *Pediatr emergency care* 2013; 29(1): 53-7.
15. Patil RT, Prakash A. Foreign bodies in aero-digestive tract in children: spectrum of presentation and management. *Inter Surg J* 2017; 4(6): 1889-95.
16. Gilyoma JM, Chalya PL. Endoscopic procedures for removal of foreign bodies of the aerodigestive tract: The Bugando Medical Centre experience. *BMC Ear, Nose and Throat Disorders* 2011; 11(1): 2.
17. Jotdar A, Dutta M, Kundu S, et al. Surgically repaired esophagus: An anchor pad for foreign bodies. *Egyptian J Ear Nose Throat Allied Sci* 2016; 17(1): 7-10.
18. Friedmacher F, Kroneis B, Huber-Zeyringer A, et al. Postoperative complications and functional outcome after esophageal atresia repair: results from longitudinal single-center follow-up. *J Gastrointestinal Surg* 2017; 21(6): 927-35.
19. Kovesi T. Aspiration risk and respiratory complications in patients with esophageal atresia. *Frontiers in pediatr* 2017; 5: 62.
20. Magsi PB, Sangi HA, Jamro B. Experience of foreign bodies in aero-digestive tract at tertiary care hospital Sukkur, Pakista. *Rawal Med J* 2011; 36(4): 277-80.
21. Selvam DK, Nirmal KJ, Anjan KS, Nagarajan PS. A clinical study on paediatric aero digestive foreign body in emergency department. *Inter J Otorhinolaryngol Head Neck Surg* 2018; 4(3): 4.
22. McKinney OW, Heaton PA, Gamble J, Paul SP. Recognition and management of foreign body ingestion and aspiration. *Nurs Standard* 2017; 31(23): 42.
23. Nakku D, Byaruhanga R, Bajunirwe F, Kyamwanga IT. A case control study of the factors associated

with occurrence of aerodigestive foreign bodies in children in a regional referral hospital in South Western Uganda. *BMC Ear, Nose Throat Disord* 2016; 16(1): 1-8.

24. Truong AQ, Funamura JL, Senders CW. Foreign Body Ingestion and Aspiration in the Pediatric Population: Analysis of 315 Cases. *Otolaryngol Head Neck Surg* 2013; 149(2\_suppl): 246.
25. Verma J, Agarwal P, Singh AJP-IJOR. Changing pattern of foreign body in the aerodigestive tract-a clinical profile of 80 patients. *Paripex-Indian J Research* 2019; 7(12).
26. Digra SK, Kishore K, Digra KK, Slathia SS. Ear and aerodigestive tract foreign body in children in a tertiary care centre in north India. *J Evolution Med Dent Sci* 2017; 6(87): 5997-6000.
27. Watson MC, Errington G. Preventing unintentional injuries in children: successful approaches. *Paediatrics Child Health* 2016; 26(5): 194-9.
28. Singh A, Ghosh D, Samuel C, Bhatti W. Pediatric foreign body aspiration: How much does our community know? *J Indian Association Pediatr Surg* 2010; 15(4): 129.