

REVIEW

Paediatrics: how to manage scabies

Russell Thompson^{1,2}, Sean Westbury³, Dana Slape^{4,5,6}

¹Faculty of Medicine, UNSW, Kensington Campus, Sydney, NSW, Australia; ²Prince of Wales Hospital, Randwick, Sydney, NSW, 2031, Australia; ³St George Hospital, Kogarah, Sydney, NSW, 2217, Australia; ⁴Department of Dermatology, Liverpool and Campbelltown Hospitals, South Western Sydney Local Health District, Sydney, NSW, Australia; ⁵School of Medicine, Western Sydney University, Sydney, NSW, Australia; ⁶Justice Health and Forensic Mental Health Network, Sydney, NSW, Australia

Abstract

This narrative review addresses scabies, a highly contagious, pruritic infestation of the skin caused by the mite *Sarcoptes scabiei var hominis*. Scabies is a common disorder that has a prevalence worldwide estimated to be between 200 and 300 million cases per year. Infestation is of greatest concern in children, the elderly, immunocompromised people and resource-poor endemic populations at risk of chronic complications. A diagnosis of scabies involves a clinical suspicion, a detailed targeted history, clinical examination and contact tracing. Dermoscopy and microscopy, where available, is confirmatory. Due to its infectivity and transmissibility, the management for scabies requires a multimodal approach: topical antiscabietic agents are the first line for most cases of childhood classic scabies and their contacts, which must also be identified and treated to prevent treatment failure and reacquisition. Environmental strategies to control fomite-related reinfestation are also recommended. Oral ivermectin, where available, is reserved for use in high-risk cases in children or in mass drug administration programmes

in endemic communities. The prevention of downstream complications of scabies includes surveillance, early identification and prompt treatment for secondary bacterial infections, often superficial but can be serious and invasive with associated chronic morbidity and mortality. Post-scabetic itch and psychosocial stigma are typical sequelae of the scabies mite infestation. The early identification of patients with scabies and treatment of their contacts reduces community transmission. Although time consuming and labour intensive for caregivers, the implementation of appropriate treatment strategies usually results in prompt cure for the child and their contacts. Here, we provide a summary of treatments and recommendations for the management of paediatric scabies.

Keywords: ivermectin, mites, permethrin, pruritus, scabies.

Citation

Thompson R, Westbury S, Slape D. Paediatrics: how to manage scabies. *Drugs in Context* 2021; 10: 2020-12-3. DOI: [10.7573/dic.2020-12-3](https://doi.org/10.7573/dic.2020-12-3)

Introduction

Scabies is a highly contagious, pruritic, parasitic infestation of the skin caused by the mite *Sarcoptes scabiei var hominis*. Scabies can affect all age groups but is found to be more prevalent in children.¹⁻³ While anyone can become infected, it causes significant morbidity in people who are immunocompromised and within populations where there is overcrowding or poor sanitation.⁴ Scabies requires prompt identification and early treatment to prevent community transmission and reduce complications for the individual child and their contacts. Severe and disabling pruritus can lead to poor feeding in young infants unable to scratch.^{3,5} Secondary bacterial infection is common following traumatic excoriation and more common in resource-poor settings.⁶ *Staphylococcus*

aureus and Group A *Streptococcus pyogenes* (GAS) are the most common secondary pathogens and can lead to acute and superficial bacterial infections but can also lead to invasive bacteraemia, acute post-streptococcal glomerulonephritis (APSGN) and acute rheumatic fever (ARF).^{7,8} Furthermore, poor sleep, poor school engagement, social stigma and school days lost due to infestation are psychosocial implications that may be deprioritized in the context of managing the acute infestation.^{9,10} The cost and accessibility of treatment along with primordial factors, including overcrowding, are issues in some communities.¹¹ Successful treatment for children with scabies requires synchronous environmental and pharmacological management.¹²⁻¹⁴ This narrative review will address the diagnosis, treatment and management of scabies in the paediatric population.

Methods

For this narrative review, we searched the Cochrane Database of Systematic Reviews, MEDLINE, Google Scholar and SCOPUS between July 2020 and January 2021. Keywords in our search included “children”, “child”, “scabies”, “*Sarcoptes scabiei* var. *hominis*”, “treatment”, “intervention”, “management”, “prevention” and “outcomes”. Included studies met the following criteria: (1) studies describing the treatment or prevention of scabies infestations and the related outcomes in children and (2) studies in English. Studies in any other language were excluded.

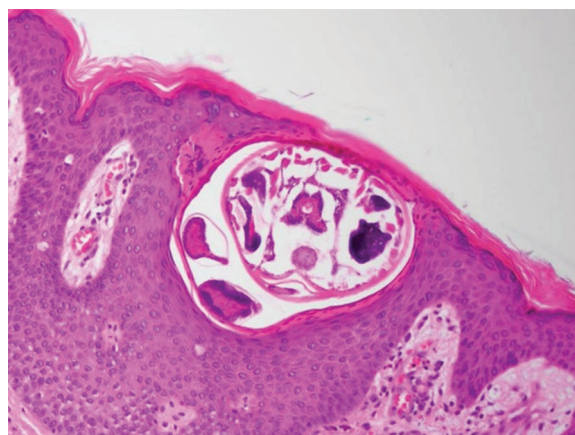
Pathogenesis/transmission

The *Sarcoptes scabiei* mite has a characteristic ovoid, ventrally flattened and dorsally convex body with four legs attached to the ventrocaudal region of the body with suckers allowing for movement¹⁵ (Figure 1). Mite reproduction leads to the demise of the male. The female mites are able to use their legs, which have sharp blades, to penetrate the stratum corneum, where they lay eggs and subsist on keratin. The female mite measures less than 0.5 mm and can produce one to three eggs daily. Larvae emerge beneath the skin 2–3 days after the eggs are laid, with fewer than 1% of the laid eggs developing into adult mites.^{2,16} The adult then exits to the skin surface after approximately 2 weeks, where they may reinfect the skin of the host or that of another human. The antigens on the exoskeleton of the scabies mite, excretions (scybala) and ova elicit a delayed cutaneous hypersensitivity reaction in humans.^{2,8,16} Characteristically, after a first exposure, this presents 2–6 weeks after initial infestation but is brisker in those who are re-exposed.¹⁷ Mites are often difficult to capture on skin biopsy as only 10–15 mites are characteristically present on the body in classic cases.^{2,17} Regardless of the presence or

Figure 1. Warren L. Microscopic section of *Sarcoptes scabiei* mite showing eight legs and the bite apparatus (photo) (2020).

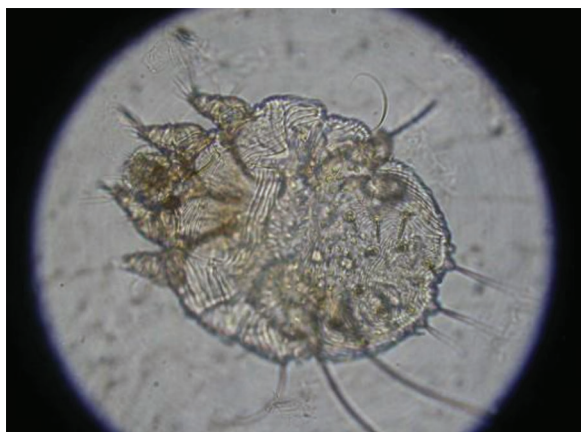

Figure 2. McCrossin I. Histological slide with haematoxylin and eosin staining showing a mite in the epidermis (photo) (2020).



absence of the chitinous exoskeleton of the female mite in the epidermis, histology will typically show surface erosion along with a superficial and deep eosinophil-rich mixed inflammatory infiltrate and dermal oedema¹⁸ (Figure 2). This correlates with the clinical finding of pruritic and excoriated papules.

Transmission occurs from prolonged skin-to-skin contact between infected individuals; however, fomites are implicated. In the paediatric population, prolonged contact between children as well as affected caregivers is a repeated method of infestation. In adolescents, sexual contact is a usual modality of acquisition.¹⁹ It takes approximately 15–20 minutes for the mite to transfer between people.^{12,20,21} When the mite is dislodged from its host, it can survive for 24–36 hours at room temperature and may be transmitted from objects such as shared bedding, towels, clothing or other fomites.^{2,22} Scabies are not readily transmitted by these modalities. When recurrent infestation, reacquisition and treatment failure are of concern, it is prudent to consider exposure to an index case of crusted scabies in a close contact due to the extreme mite burden.¹² This rare hyperkeratotic variant characterized by hyperinfestation of millions of scabies mites is often implicated in community outbreaks of classic/simple scabies. Consideration of the social circumstances and targeted history about at-risk close contacts, such as an elderly or immunocompromised bed-bound relative, may identify an index case that is spreading via their shedding.²³

Epidemiology

Scabies has been known to humankind since ancient times, with Aristotle describing them as ‘lice in the flesh’.² The World Health Organization identified scabies as a global health issue of concern and, in 2017, it was included within their literature regarding neglected tropical diseases.²⁴

The prevalence of scabies worldwide is estimated to be between 200 and 300 million cases per annum, affecting all age groups.²⁵ However, it is most well established in vulnerable groups such as children, immunocompromised and elderly people as well as in people located in resource-poor communities in the developing world, where overcrowding, poor sanitation and socioeconomic disadvantage coexist, causing significant human morbidity and mortality.^{2,8,24,26–28}

Children carry the highest burden of disease with the highest prevalence of scabies being in children under 2 years old.^{8,29} The highest prevalence is seen in tropical regions such as Central America, the Pacific islands and Northern Australia.²⁸ A global systematic review of population-based surveys of scabies found a wide range of prevalence, with the highest prevalence observed in Papua New Guinea (71%), Panama (32%) and Fiji (32%). The prevalence was generally much lower in developed countries, with very few estimates exceeding 2–4%.³⁰ Although Australia is considered a developed country with access to universal healthcare, remote indigenous communities continue to experience a very high burden of scabies, affecting 7 out of 10 children before their first birthday.³¹ This is more than six times the rate seen in the rest of the developed world.^{27,30}

Clinical manifestations

Classic scabies

Scabies infestation causes generalized pruritus, typically worst at night. Often, there is a history of contact with an affected individual. The most common presentation of scabies in children includes burrows, erythematous papules and inflammatory nodules, often with secondary excoriation. Burrows and inflammatory papules have a typical distribution, affecting the flexural limbs, including the anterior axillary folds, elbows, volar wrists and dorsal ankles; acral surfaces especially the interdigital web spaces and feet; anogenital area; and truncal areas, particularly the nipples and periumbilical areas.^{2,3,8,32–34} This is referred to as the circle of Hebra.²

Young children often have widespread erythrosquamous papules and plaques and more poorly defined excoriated eczematous areas, particularly on the trunk (Figures 3–6). This broadly distributed pruritic secondary dermatosis is often more disabling and distressing for the child and caregivers than the primary infestation. Very young babies cannot scratch and may feed poorly or become irritable.³ In children, less common presentations of scabetic lesions may be nodular or bullous.^{35,36}

Crusted scabies

Crusted scabies, exceedingly rare in children, is characterized by a severe infestation of millions of mites resulting in hyperkeratotic plaques or 'crusted skin'.^{25,37,38} When seen in children, crusted scabies has a predilection for immunocompromised and chronically ill children.^{39,40} It is a

Figure 3. Warren L. Severe classical scabies affecting the torso of an infant (photo) (2020).

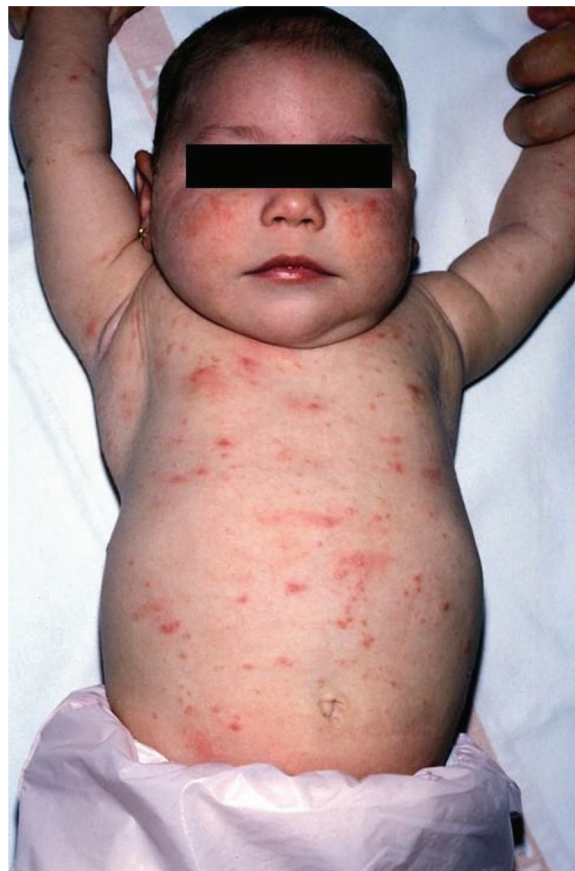

Figure 4. Wong L. Scabies affecting the axilla of a child (photo) (2020).

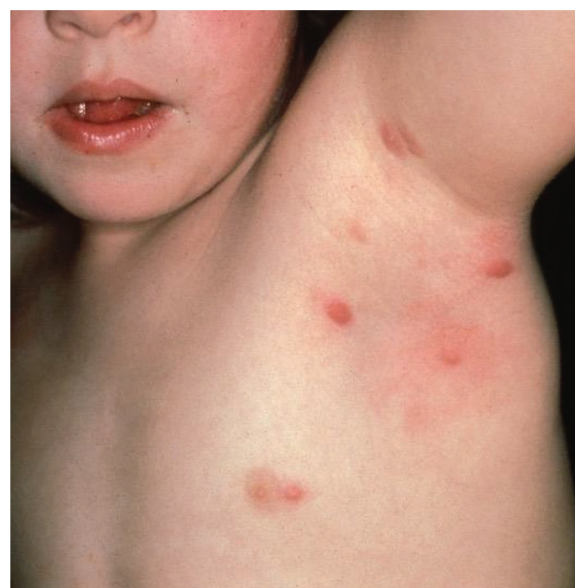

Figure 5. Wong L. Scabies affecting the plantar surface of the foot (photo) (2020).

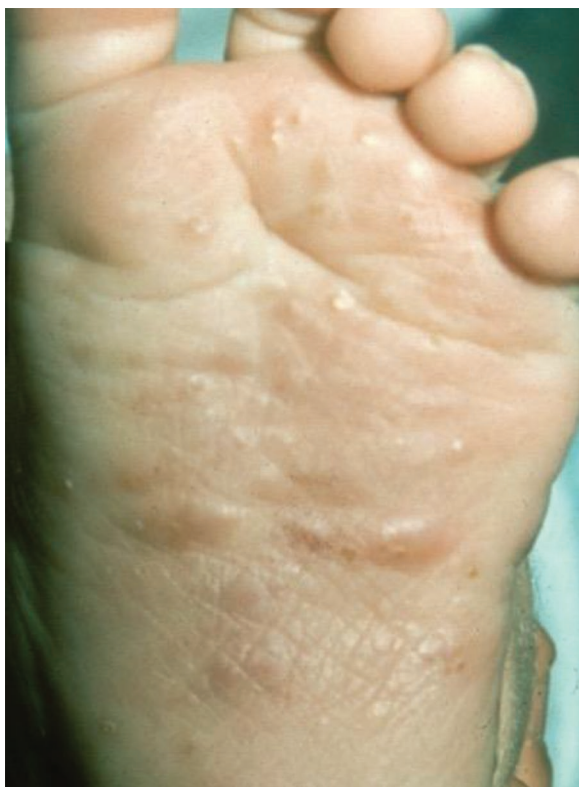
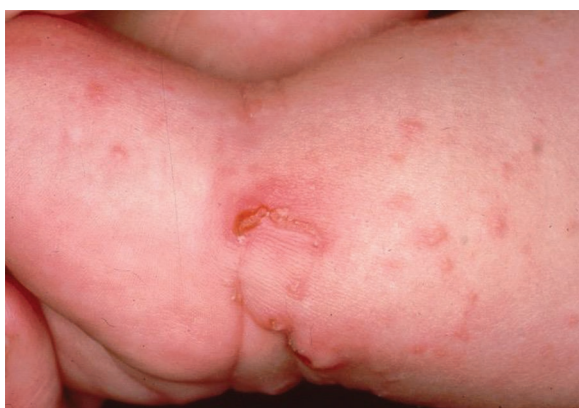
Figure 6. Wong L. Scabies affecting the volar surface of the wrist of a child (photo) (2020).



highly infectious, debilitating and disfiguring condition with a high morbidity and mortality. The high mite burden of crusted scabies leads to high transmissibility in contacts who manifest simple scabies, often in varying degrees of severity. Consideration about contact with an index case of crusted scabies, such as in a bed-bound relative, should be undertaken in children with recurrent simple scabies or treatment refractory scabies.²

Complications of scabies

Scratching, often persistently, is secondary to the cutaneous irritation from the scabies mite causing a delayed hypersensitivity response. Eroded and excoriated primary scabetic papules and secondary eczematous plaques lead to impaired barrier function of the skin and secondary bacterial infection. Superficial impetiginization commonly presents as golden purulent/serous crusting or flaccid pustulation. The most common pathogens are *S. aureus* and GAS.^{41–43}

S. aureus can cause superficial acute impetiginization, abscesses, cellulitis, echthyma, paronychia and furunculosis but can progress to osteomyelitis, endocarditis and life-threatening bacterial sepsis.^{25,28,37,42} Screening for methicillin-resistant *S. aureus* (MRSA) and the selection of targeted antibiotics are important considerations for the treating team.

Secondary bacterial infection from GAS can cause acute local skin and soft tissue infections, including superficial pyoderma, skin abscesses and cellulitis, through to more severe necrotizing fasciitis. Following secondary GAS skin infections, at-risk minority populations can experience complications, including APSGN and ARF, which are associated with chronic renal impairment and chronic rheumatic heart disease, respectively, and are typically seen in disadvantaged tropical populations, including First Nations Peoples of Australia and New Zealand as well as Pacific Islander communities.^{30,44,45} Emerging evidence is suggestive that GAS impetigo plays a role in ARF when previously GAS pharyngitis was presumed to be the only source of upstream infection.^{42,46}

Psychosocial complications of scabies

Scabies causes intense itch, severely affecting sleep and quality of life and the complications of scabies are generally underappreciated. Scabies causes a large burden on families living in poverty due to the cost of treatment, absence from school and missed workdays, thus restricting the ability to provide for the family and educational opportunities for children.^{13,45,47} Furthermore, persistent itching can affect a child's sleep, resulting in daytime tiredness, reduced ability to concentrate and reduced productivity.²⁹

A diagnosis of scabies can be stigmatizing for the child and their caregiving network, as it is strongly associated with poverty and overcrowding and perceived as a disease of disadvantage and inadequate hygiene.^{10,48,49} Conversely, many endemic communities have normalized scabies, which presents a challenge to ongoing management.^{41,45} Breaking down community misperceptions remains an ongoing area of need.

Diagnosis

Suspicion of a parasitic infestation is the prerequisite for diagnosis and, importantly, disease control of the individual and their environment. Missed diagnoses are common and can approach up to half of suspected cases, which can result in

morbidity, community transmission and economic burden.^{50,51} It is important to determine a history of pruritus in other members of the family, other caregivers and casual contacts, i.e. school, playgroups and sexual contacts, which may provide important clues towards a diagnosis.²⁶

A full examination of all cutaneous surfaces of the child should be conducted, looking for papular excoriated lesions, particularly within the circle of Hebra.^{2,5} A classic history of pruritus, worst at night, with classically distributed excoriated papular lesions is enough to warrant empiric treatment, particularly when treating a high-risk patient or in high-risk communities or there are likely affected contacts.

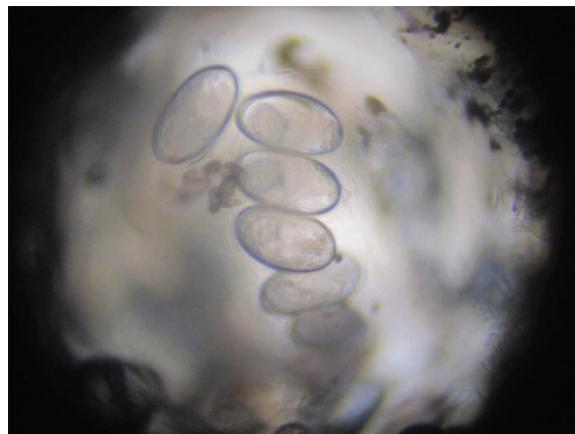
Closer inspection through dermoscopy is helpful in the visualization of scabies and is non-invasive or distressing for the child or caregiver.⁵² The abdomen and eggs of mites are transparent and are poorly visualized through dermoscopy;⁵³ however, when appropriately trained, one can identify the 'delta wing sign'.⁵⁴ This is a small brown triangle at the tip of a poorly defined ovoid translucent structure, which represents the head atop body of the mite, cephalad to a whitish curvilinear structure, which is clinically defined as the burrow containing the eggs and faeces distal to the site of initial burrowing. It is so named due to its dermoscopic features being reminiscent of a delta-wing jet and its contrails^{54,55} (Figure 7).

Where available, the confirmatory test for the diagnosis of scabies is skin scrapings, visualized with microscopy to confirm the presence of mites, eggs and faeces^{2,32} (Figure 8). Scrapings should be taken from the head and body of the suspected lesions³⁴ then suspended in mineral oil or potassium hydroxide 20% to assess for microscopic evidence of mites, eggs and faeces. The presence of the mite or egg casings under microscopy is highly specific,^{5,36} although sensitivity can be variable due to the individual sampling and mounting technique of the operator as well as patients with a low mite

Figure 7. Slape D. Typical scabies lesion, identifying the head, body, and tail (Delta wing sign) (photo) (2020).



Figure 8. McCrossin I. Skin scrapings visualised with microscopy showing ova and scybala (photo) (2018).



count. A negative scraping result does not preclude the diagnosis.^{10,55,56}

Alternative methods that can be used to diagnose scabies include the burrow ink test and adhesive tape stripping. The burrow ink test involves the application of ink to visible burrows on the skin followed by the removal of excess ink with an alcohol preparation, allowing the visualization of a typical curvilinear burrow structure.^{32,34} Adhesive tape stripping involves the application of adhesive tape to suspicious areas being investigated for scabies. This test is most useful in severe cases of scabies.⁵⁷ The adhesive tape is applied to the skin and then pulled to lift the stratum corneum along with mites or their products. The tape is then visualized on a microscope after being transferred to a slide looking for evidence of scabies.⁵²

In resource-poor settings, microscopy or dermoscopy may be unavailable due to logistics and cost, relying on a clinical history and examination for diagnosis⁵⁸; standardized global consensus criteria are available.^{52,50} However, with appropriate training, using dermoscopy and taking skin scrapings in endemic settings increases the sensitivity of diagnosing scabies significantly.⁵⁶

The 2020 International Alliance for the Control of Scabies (IACS) Consensus Criteria acts as a standardized tool to support clinicians in the diagnosis of scabies (Box 1). 'Confirmed scabies', diagnosed with microscopy or dermoscopy is the most specific and certain (level A). 'Clinical scabies' is diagnosed with typical lesions in a classic distribution with a convincing symptom and contact history (level B). 'Suspected scabies' is diagnosed when typical lesions present in a typical distribution with some supportive corroborative history or an atypical distribution/morphology with a convincing symptom and contact history (level C). A diagnosis of clinical (IACS B) or suspected scabies (IACS C) should only be made if other differential diagnoses are considered less likely than scabies.⁵⁹

Box 1. Summary of the 2020 International Alliance for the Control of Scabies Consensus Criteria for the diagnosis of scabies: reproduced with permission from *Br J Dermatol.*, 2020.⁵⁹

A. Confirmed scabies

At least one of:

A1: Mites, eggs or faeces on light microscopy of skin samples

A2: Mites, eggs or faeces visualized on an individual using a high-powered imaging device

A3: Mite visualized on an individual using dermoscopy

B. Clinical scabies

At least one of:

B1: Scabies burrows

B2: Typical lesions affecting male genitalia

B3: Typical lesions in a typical distribution and two history features

C. Suspected scabies

One of:

C1: Typical lesions in a typical distribution and one history feature

C2: Atypical lesions or atypical distribution and two history features

History features

H1: Itch

H2: Positive contact history

Differential diagnoses

Whilst lesions suggestive of scabies usually warrant empirical treatment, it is important to consider the potential differential diagnoses. The differential diagnoses to consider when considering scabies are:^{8,21,60,61}

- Other insect bites (mosquitoes, fleas and bedbugs)
- Papulosquamous disorders such as atopic/irritant/allergic contact dermatitis, lichen planus and lichen nitidus
- Infectious dermatoses including uncomplicated impetigo, molluscum contagiosum, blistering digital dactylitis, dermatophytosis, bacterial folliculitis and, rarely, tungiasis
- Papular urticaria
- Non-infectious inflammatory conditions in paediatric patients, including infantile acropustulosis
- Rare dermatoses in children, including dermatitis herpetiformis, incontinentia pigmenti, Langerhans cell histiocytosis

Active intervention

Primary infestation in children: intervention principles

The management of an index patient affected by scabies includes the eradication of mites with a pharmacological modality, strategies to prevent the spread of scabies to other individuals, and the surveillance and treatment of potentially associated complications of scabies, i.e. associated pruritus

and secondary bacterial infections.²⁹ Infested persons and their close physical contacts should be treated synchronously, regardless of whether symptoms are present due to the incidence of asymptomatic infestation in carriers and the latency of symptom onset. Furthermore, patients should avoid close physical contact until scabicial regimens are complete to prevent reacquisition.^{3,33,62} In endemic settings with concerns about accessibility, adherence and hyperinfestation, treatment via mass drug administration regimens has been successful in decreasing rates of scabies and its complications.^{63–65}

Pharmacological treatment in children

Pharmacological management of paediatric patients with uncomplicated classic scabies is best achieved with topical permethrin 5% lotion.^{7,66,67} Oral ivermectin is considered safe and reserved for complex cases.⁶⁸ Treatment options vary between countries and resource availability.^{12,57,69} In simple classic scabies, pharmacological treatments should be implemented twice, administered 1 week apart.¹⁷ All treatments must be performed from scalp to toes sparing the periorbital and perioral area, on day 0 and repeated on day 7 alongside environmental strategies.

Topical treatments: commonly used

Permethrin 5% cream

Permethrin is a synthetic pyrethroid and potent insecticide. Topical permethrin 5% cream is considered the most effective topical medication for the treatment of scabies.⁶⁶ The mechanism of action is disruption to the function of voltage-

gated sodium channels of arthropods, causing prolonged depolarization of nerve cell membranes and disrupting neurotransmission.⁷⁰ The cream should be applied to the entire body, including the face and the scalp, overnight or for at least 8–12 hours, then washed off and the process repeated 7 days later.^{71,72} Permethrin is efficacious, well tolerated, is safe in children and has minimal side-effects. Less than 2% of the applied amount is cutaneously absorbed in small amounts and metabolized by skin esterases to be excreted back to the skin by sweat and sebum and also excreted in the urine.^{3,8,73}

Sulfur in petroleum

In children less than 2 months of age, sulfur-containing preparations are recommended as an alternative option to permethrin. On the skin, sulfur converts to hydrogen sulfide, polythionic acid and pentathion, which has antibacterial properties shown to also be efficacious in eradicating the scabies mite.⁷⁴ Sulfur preparations are particularly popular in developing countries due to its low cost and have been used for centuries. It comes as an ointment base (2–10% for patients <2 months of age and 10–25% >2 months of age) and is safe for infants and children. However, it is unpleasant to use as it is messy and malodorous and may cause skin irritation. The ointment should be applied to the whole body, then left for 24 hours, and then washed and reapplied for 3 days with skin cleansing between each application (i.e. bath/shower).^{29,33,75}

Crotamiton 10% cream

The mechanism of action for crotamiton is unknown; however, it has been shown to be a safe alternative for infants, but requires multiple treatments. It should be applied to the entire body for 24 hours, washed and reapplied to the whole body for 3–5 days. Some studies suggest treatment efficacy may be improved with daily application for 10–14 days.⁷⁴ Uncommonly, adverse effects may include methemoglobinemia in children and allergic contact dermatitis.^{7,76}

Benzyl benzoate

Benzyl benzoate is an ester of benzoic acid and benzyl alcohol and is neurotoxic to the scabies mite.⁷⁵ It should be applied three times over a 24-hour period to the entire body below the neck and then rinsed off. Reapplication may be repeated for 7–14 days. Benzyl benzoate 25% treatment commonly causes skin irritation and burning after application; therefore, to reduce irritation, benzyl benzoate should be diluted to 12.5% for children and to 6.25% for infants. However, it has been shown that dilution reduces its efficacy.⁷⁵

Other topical treatments: not in common use

Topical ivermectin

Topical ivermectin 1% lotion is reported to be safe and equally as effective as oral ivermectin for simple/classic scabies in

preliminary studies.^{77,78} It is not routinely used due to cost, availability and lack of large-scale evidence of its utility.⁶⁶

Lindane

Lindane is an effective scabicide organochlorine insecticide. Its significant systemic absorption and subsequent central nervous system toxicity has led to its withdrawal from most markets internationally and is largely of historical relevance. Lindane is accessible and affordable in some developing countries; however, it should be avoided in infants, pregnant women and immunocompromised patients due to the risk of seizures, paralysis and death.⁷⁹

Malathion 0.5%

Malathion lotion acts by inhibiting the action of cholinesterase, thus inhibiting the degradation of acetylcholine. There is little evidence that demonstrates the efficacy of malathion in scabies.^{74,75}

Tea tree oil

Tea tree oil 0.002–2% gel has shown both antimicrobial and scabicide activity in vitro.⁸⁰ Current research is investigating the treatment of scabies using a tea tree oil-based gel formulation in Australian Aboriginal children. While real-world application is yet to be established, in culturally diverse and resource-poor endemic populations, the use of traditional medicines may augment more conventional treatment approaches with the goal of improved individual and community control of this disease in areas of need.²⁷

Oral treatment: systemic avermectin antiparasitic agents

Oral ivermectin

Simple and crusted scabies are off-label non-FDA-approved indications⁸¹ for oral ivermectin; however, it is recognized as efficacious and safe and is widely used for this indication, where available. Oral ivermectin is an oral antiparasitic that also has anthelmintic properties.⁸² Ivermectin selectivity binds to the glutamatergic chloride channels in the muscle and nerve cells, resulting in elevated cell membrane permeability and hyperpolarization, causing paralysis and death of the scabies mite.⁷⁴ Oral ivermectin consists of a 200 µg/kg single dose followed by a repeat dose after 1 week for simple scabies, when deemed appropriate based on patient factors. Ivermectin has been shown to be safe in infants and children under 15 kg, with effective scabicide properties and infrequent mild adverse events and no serious complications.⁶⁸ It is pregnancy category B3 and should be avoided in pregnant contacts, where topical therapies should be considered in the first instance.

Emerging: oral moxidectin

There is emerging evidence of an alternate avermectin derivative, moxidectin. Currently, moxidectin is used by

veterinarians as a single-dose antiparasitic agent. The long half-life allows single dosing, killing mites on the skin as well as when hatching from the ova stage. This promising treatment will improve adherence as multidose regimens are a barrier to current treatments. Human trials are currently under way.⁸³

Environmental strategies

The spread of classic scabies without direct person-to-person contact is uncommon; however, it is recommended that, due to the risk of infecting other family members and reinfestation of the index patient, environmental measures be taken.^{7,84} Ideally, clothes, towels and bed linens should be machine washed at 60°C (140°F) and machine dried the day after the first treatment to reduce infestation and subsequent fomite transmission. Clothing or difficult-to-exterminate items such as childrens' toys may also be kept in a sealed plastic bag for at least 48–72 hours.^{7,33} In resource-poor settings, where warm water or conventional washing machines may be unavailable or difficult to access, the abovementioned technique of prolonged sealing in a plastic bag is recommended along with pharmacological management; however, this may be logistically challenging.²¹ Airing items in the sun and avoidance of contact for a similar length of time is often suggested as a practical alternative. Several mass drug administration studies in developing countries achieved control with pharmacological management alone and without environmental decontamination.⁷ While this evidence argues against the proof of benefit of environmental measures, ideally, if able to be done, we recommend that environmental strategies are carried out to reduce the likelihood of fomite transmission.

Management of complications of scabies

Post-scabetic itch

Parents should be advised that the symptoms of scabies take time to resolve and the itch may persist for up to 4–6 weeks post treatment even after all mites have been eradicated. Children should have age-appropriate expectations set about persistence of itch. Simple strategies such as cool compresses, emollients, crotamiton and minimization of traumatic picking can be helpful. Topical corticosteroid preparations are a safe first-line option and can help control the eczematous and inflammatory component. Oral antihistamines are frequently implemented to control the itching with variable success. Sedating antihistamines may assist with sleep.^{3,62}

Management of secondary bacterial pyoderma

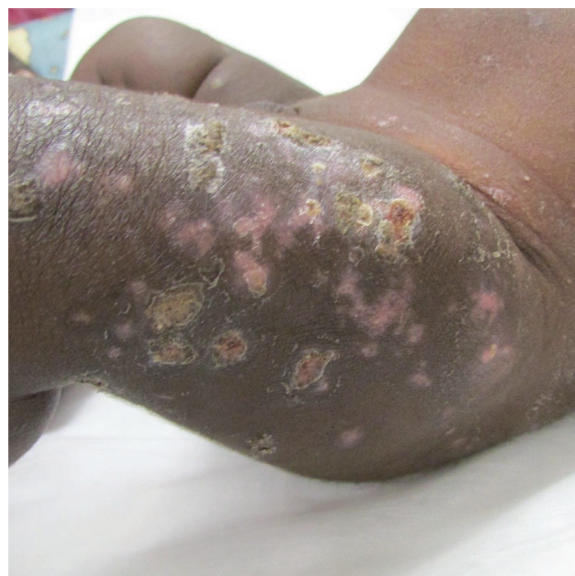Children with secondary bacterial pyodermas should be treated with the standard therapy for scabies discussed previously and,

in addition, will require antibiotic treatment (Figure 9). Empiric treatment is often performed; however, if practical, bacterial swabs for microscopy, culture and sensitivity are recommended prior to beginning treatment, especially if the initial presentation is severe.⁷ Children with a localized skin sore and from environments considered low risk for serious sequelae can be managed with mupirocin 2% ointment or cream topically to crusted areas, 8-hourly for 5 days.⁷

For children with secondary bacterial infection either moderate to severe at initial presentation or refractory to topical agents, empirical antibiotic therapy can be administered, guided by local patterns of sensitivity with particular attention to the prevalence of MRSA. Empiric cover for MRSA is required in communities where this is endemic. Oral antibiotics that are effective against GAS and *S. aureus* are flucloxacillin/dicloxacillin or a first-generation cephalosporin; when MRSA is suspected, adding co-trimoxazole is recommended. Treatment should last 5–10 days with concurrent scabies treatment and follow-up after antibiotics have ceased.^{7,85,86}

For children living in remote areas where scabies is endemic, where serious sequelae such as APSGN and ARF are relatively common, and where treatment access is challenging, benzathine benzylpenicillin intramuscularly can be administered as a single weight-based dose to effectively treat secondary bacterial pyoderma and minimize the potential downstream risks.^{87,88} The monitoring and prompt management of the sequelae of severe infection, such as APSGN and ARF, requires a multidisciplinary paediatric approach in diagnosis and management and is guided by local protocols.^{89,90}

Figure 9. Slape D. Secondarily infected scabies affecting a child's leg (photo) (2020).



Management of the psychosocial effects of scabies

Providing clear targeted educational information to the child and their parents is of importance to ensure adherence to the complex protocols. Where appropriate, patient information sheets are useful to provide instructions for pharmacological and environmental treatment of the child and their contacts in addition to explaining the natural history of the slow resolution of the itch.⁹¹

The psychological impact of children due to stigma of scabies is concerning and healthcare workers should consider psychological strategies as an adjunct to environmental and pharmacological treatment.⁹²

Follow-up

Patients and their families/contacts should be seen during and after treatment where possible: this ensures adherence to the treatment regimen, successful completion of treatment, monitoring for reacquisition/treatment failure, and surveillance for complications.⁵

Prognosis

The prognosis of eradicating scabies in children is good when using a combination of specific targeted pharmacological and non-pharmacological environmental measures. When

individuals and contacts are correctly treated, symptoms are likely to resolve. However, in endemic areas, reinfestation and treatment failure occur more often.

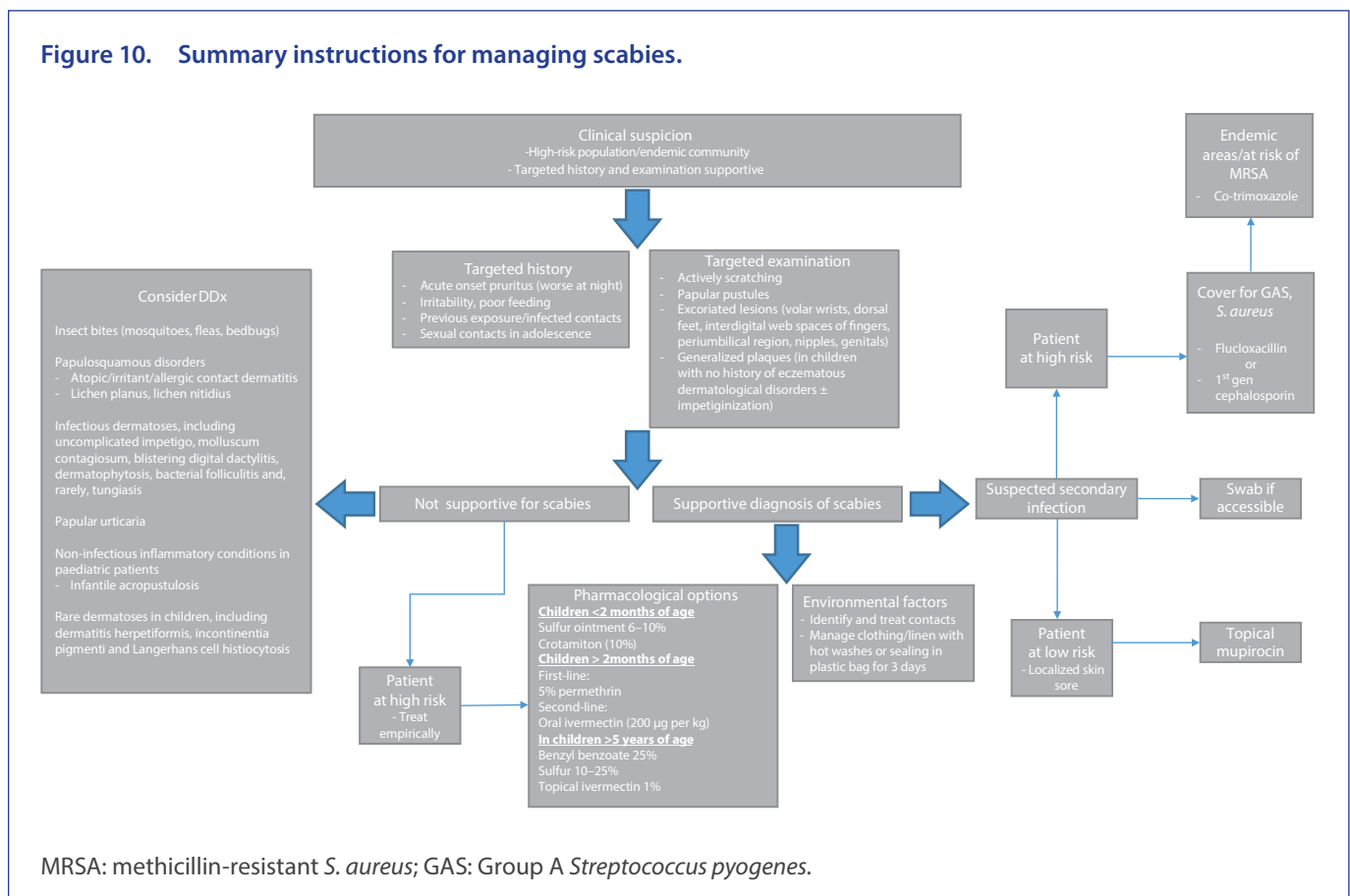
Recommendations for treatment

A flow diagram is provided herein to facilitate the treatment choices for scabies (Figure 10).

Conclusion

Scabies is a contagious parasitic infestation causing a pruritic dermatosis that has effective treatment and management strategies. While it can be debilitating for the child with potential for significant health impacts on the individual, it also has psychosocial challenges for the family and community, regardless of socioeconomic status. Clinical suspicion followed by a targeted history and examination, augmented by diagnostic tools and tests, allows treatment to be implemented. The early diagnosis and treatment of scabies in children along with close contacts is imperative to prevent these complications and to reduce community transmission. As a neglected tropical disease with serious population health risks, often in areas of great health need, improved community control strategies, research into emerging and repurposed topical and systemic treatments, and evidence-based rigorous and practical treatment protocols may see this condition and its sequelae minimized.

Figure 10. Summary instructions for managing scabies.



Key practice points

- Scabies is a common parasitic infestation of the skin, frequently seen in children and adolescents.
- It is characterized by the abrupt onset of severe pruritus, typically worst at night, and widespread excoriated erythematous papules and eczematized plaques with a classic distribution.
- The diagnosis may be aided by tools such as skin scrapings and dermoscopy; however, history and examination findings are usually sufficient to confirm the clinical suspicion and initiate treatment.
- Topical treatment with 5% permethrin is safe and effective and, where available, should be first line. Environmental measures are recommended.
- Prompt consideration of scabies as a cause for a pruritic rash in children allows for the diagnosis and implementation of treatment, which is important for the prevention of complications such as localized and invasive infections.

Contributions: All authors contributed equally to the preparation of this review. All named authors meet the International Committee of Medical Journal Editors (ICMJE) criteria for authorship for this article, take responsibility for the integrity of the work as a whole, and have given their approval for this version to be published.

Disclosure and potential conflicts of interest: The authors declare that they have no conflicts of interest relevant to this manuscript. The International Committee of Medical Journal Editors (ICMJE) Potential Conflicts of Interests form for the authors is available for download at: <https://www.drugsincontext.com/wp-content/uploads/2021/03/dic.2020-12-3-COI.pdf>

Funding declaration: There was no funding associated with the preparation of this article.

Copyright: Copyright © 2021 Thompson R, Westbury S, Slape D. Published by *Drugs in Context* under Creative Commons License Deed CC BY NC ND 4.0 which allows anyone to copy, distribute, and transmit the article provided it is properly attributed in the manner specified below. No commercial use without permission.

Correct attribution: Copyright © 2021 Thompson R, Westbury S, Slape D. <https://doi.org/10.7573/dic.2020-12-3>. Published by *Drugs in Context* under Creative Commons License Deed CC BY NC ND 4.0.

Article URL: <https://www.drugsincontext.com/paediatrics:-how-to-manage-scabies>

Correspondence: Dana Slape, Department of Dermatology, Liverpool and Campbelltown Hospitals, South Western Sydney Local Health District, Sydney, New South Wales, Australia. Email: dana.slape@health.nsw.gov.au

Provenance: Invited; externally peer reviewed.

Submitted: 13 December 2020; **Accepted:** 7 February 2021; **Publication date:** 26 March 2021.

Drugs in Context is published by BioExcel Publishing Ltd. Registered office: Plaza Building, Lee High Road, London, England, SE13 5PT.

BioExcel Publishing Limited is registered in England Number 10038393. VAT GB 252 7720 07.

For all manuscript and submissions enquiries, contact the Editorial office editorial@drugsincontext.com

For all permissions, rights and reprints, contact David Hughes david.hughes@bioexcelpublishing.com

References

1. Hogan, DJ, Schachner, L, Tanglertsampan, C. Diagnosis and treatment of childhood scabies and pediculosis. *Pediatric Clin North Am*. 1991;38(4):941–957. [https://doi.org/10.1016/s0031-3955\(16\)38161-5](https://doi.org/10.1016/s0031-3955(16)38161-5)
2. Walton SF, Currie BJ. Problems in diagnosing scabies, a global disease in human and animal populations. *Clin Microbiol Rev*. 2007;20(2):268–279. <https://doi.org/10.1128/CMR.00042-06>
3. Johnston G, Sladden M. Scabies: diagnosis and treatment. *BMJ*. 2005;331(7517):619–622. <https://doi.org/10.1136/bmj.331.7517.619>
4. Suwandhi P, Dharmarajan TS. Scabies in the nursing home. *Curr Infect Dis Rep*. 2014;17(1):453. <https://doi.org/10.1007/s11908-014-0453-6>
5. Chandler DJ, Fuller LC. A review of scabies: an infestation more than skin deep. *Dermatology*. 2019;235(2):79–90. <https://doi.org/10.1159/000495290>
6. Korte LM, Bowen AC, Draper AD, et al. Scabies and impetigo in Timor-Leste: a school screening study in two districts. *PLoS Negl Trop Dis*. 2018;12(5):e0006400. <https://doi.org/10.1371/journal.pntd.0006400>
7. Chosidow O. Clinical practices. Scabies. *N Engl J Med*. 2006;354(16):1718–1727. <https://doi.org/10.1056/NEJMcp052784>

8. Hill, TA, Cohen B. Scabies in babies. *Pediatr Dermatol*. 2017;34(6):690–694. <https://doi.org/10.1111/pde.13255>
9. Mitchell E, Bell S, Sahukhan A, et al. Community perspectives on scabies, impetigo and mass drug administration in Fiji: a qualitative study. *PLoS Negl Trop Dis*. 2020;14(12):e0008825. <https://doi.org/10.1371/journal.pntd.0008825>
10. Heukelbach J, Feldmeier H. Scabies. *Lancet*. 2006;367(9524):1767–1774. [https://doi.org/10.1016/S0140-6736\(06\)68772-2](https://doi.org/10.1016/S0140-6736(06)68772-2)
11. Banerji A. Scabies. *Paediatr Child Health*. 2015;20(7):395–402. <https://doi.org/10.1093/pch/20.7.395>
12. Goldstein BG. *UpToDate: management of scabies*. <https://www.uptodate.com/contents/scabies-management>. Accessed December 12, 2020.
13. Engelman D, Kiang K, Chosidow O, et al. Toward the global control of human scabies: introducing the International Alliance for the Control of Scabies. *PLoS Negl Trop Dis*. 2013;7(8):e2167. <https://doi.org/10.1371/journal.pntd.0002167>
14. Steer AC, Jenney AWJ, Kado J, et al., High burden of impetigo and scabies in a tropical country. *PLoS Negl Trop Dis*. 2009;3(6):e467. <https://doi.org/10.1371/journal.pntd.0000467>
15. Arlian LG, Morgan MS. A review of *Sarcoptes scabiei*: past, present and future. *Parasit Vectors*. 2017;10(1):297. <https://doi.org/10.1186/s13071-017-2234-1>
16. Mellanby K. The development of symptoms, parasitic infection and immunity in human scabies. *Parasitology*. 1944;35(4):197–206. <https://doi.org/doi:10.1017/S0031182000021612>
17. Bolognia J, Jorizzo JJ, Schaffer JV, et al. *Dermatology*. 3rd ed. London: Elsevier; 2012.
18. Hengge UR, Currie B, Jager G, et al., Scabies: a ubiquitous neglected skin disease. *Lancet Infect Dis*. 2006;6(12):769–779. [https://doi.org/10.1016/S1473-3099\(06\)70654-5](https://doi.org/10.1016/S1473-3099(06)70654-5)
19. Barot J, Solanki A, Patel N, et al., A retrospective study of the pattern of sexually transmitted diseases in teenagers attending sexually transmitted disease clinic during a 7-year period at a tertiary care centre. *Indian J Paed Dermatol*. 2018;19(3):220–223.
20. Kazeminejad A, Hajheydari Z, Ghahari MJ. Scabies treatment in children: a narrative review. *JPR*. 2019;7(2):105–112. <https://doi.org/10.32598/jpr.7.2.105>
21. Thomas C, Coates S, Engleman D, et al. Ectoparasites: scabies. *J Am Acad Dermatol*. 2020;82(3):533–548. <https://doi.org/10.1016/j.jaad.2019.05.109>
22. Manjhi PK, Sinha RI, Kumar M, et al. Comparative study of efficacy of oral ivermectin versus some topical antiscabies drugs in the treatment of scabies. *J Clin Diagn Res*. 2014;8(9):HC01–HC04. <https://doi.org/10.7860/JCDR/2014/9092.4878>
23. FitzGerald D, Grainger RJ, Reid A. Interventions for preventing the spread of infestation in close contacts of people with scabies. *Cochrane Database Syst Rev*. 2014;(2):CD009943. <https://doi.org/10.1002/14651858.CD009943.pub2>
24. World Health Organization. *Scabies in the Western Pacific*. 2020. <https://www.who.int/westernpacific/health-topics/scabies>. Accessed December 12, 2020.
25. Lima F, Cerquiera A, Guimaraes M, et al., Crusted scabies due to indiscriminate use of glucocorticoid therapy in infant. *An Bras Dermatol*. 2017;92(3):383–385. <https://doi.org/10.1590/abd1806-4841.20174433>
26. Karthikeyan K. Scabies in children. *Arch Dis Child Educ Pract Ed*. 2007;92(3):ep65–ep69. <https://doi.org/10.1136/adc.2005.073825>
27. Thomas J, Davey R, Peterson GM, et al. Treatment of scabies using a tea tree oil-based gel formulation in Australian Aboriginal children: protocol for a randomised controlled trial. *BMJ Open*. 2018;8(5):e018507. <https://doi.org/10.1136/bmjopen-2017-018507>
28. Yeoh DK, Bowen AC, Carapetis JR. Impetigo and scabies - disease burden and modern treatment strategies. *J Infect*. 2016;72 Suppl:S61–S67. <https://doi.org/10.1016/j.jinf.2016.04.024>
29. Leung AKC, Lam JM, Leong KF. Scabies: a neglected global disease. *Curr Pediatr Rev*. 2020;16(1):33–42. <https://doi.org/10.2174/1573396315666190717114131>
30. Cox V, Fuller LC, Engelman D, et al. Estimating the global burden of scabies: what else do we need? *Br J Dermatol*. 2020. <https://doi.org/10.1111/bjd.19170>
31. Aung PTZ, Cuningham W, Hwang K, et al. Scabies and risk of skin sores in remote Australian Aboriginal communities: a self-controlled case series study. *PLoS Negl Trop Dis*. 2018;12(7):e0006668. <https://doi.org/10.1371/journal.pntd.0006668>
32. Leung V, Miller M. Detection of scabies: a systematic review of diagnostic methods. *Can J Infect Dis Med Microbiol*. 2011;22(4):143–146. <https://doi.org/10.1155/2011/698494>
33. Chosidow O. Scabies and pediculosis. *Lancet*. 2000;355(9206):819–826. [https://doi.org/10.1016/S0140-6736\(99\)09458-1](https://doi.org/10.1016/S0140-6736(99)09458-1)
34. Chouela E, Albedano A, Pellerano G, et al. Diagnosis and treatment of scabies: a practical guide. *Am J Clin Dermatol*. 2002;3(1):9–18. <https://doi.org/10.2165/00128071-200203010-00002>
35. Luo DQ, Huang MX, Liu JH, et al. Bullous scabies. *Am J Trop Med Hygiene*. 2016;95(3):689–693. <https://doi.org/10.4269/ajtmh.16-0273>
36. Srinivas S, Herakal K, Murthy SK, et al. Dermoscopic study of scabies in children. *Indian J Paediatr Dermatol*. 2019;20(1):46–51. https://doi.org/10.4103/ijpd.IJPD_25_18
37. Engelman D, Steer AC. Control strategies for scabies. *Trop Med Infect Dis*. 2018;3(3):98. <https://doi.org/10.3390/tropicalmed3030098>

38. Lokuge B, Kopczynski A, Woltmann A, et al. Crusted scabies in remote Australia, a new way forward: lessons and outcomes from the East Arnhem Scabies Control Program. *Med J Aust.* 2014;200(11):644–648. <https://doi.org/10.5694/mja14.00172>
39. Fonseca V, Price H, Jeffries M, et al. Crusted scabies misdiagnosed as erythrodermic psoriasis in a 3-year-old girl with down syndrome. *Pediatr Dermatol.* 2014;31(6):753–754. <https://doi.org/10.1111/pde.12225>
40. Prose NS, Mendez H, Menikoff H, et al. Pediatric human immunodeficiency virus infection and its cutaneous manifestations. *Pediatr Dermatol.* 1987;4(2):67–74. <https://doi.org/10.1111/j.1525-1470.1987.tb00755.x>
41. Romani L, Koroivuetta J, Steer A, et al. Scabies and impetigo prevalence and risk factors in Fiji: a national survey. *PLoS Negl Trop Dis.* 2015;9(3):e0003452. <https://doi.org/10.1371/journal.pntd.0003452>
42. Romani L, Steer A, Whitfeld M, et al. Prevalence of scabies and impetigo worldwide: a systematic review. *Lancet Infect Dis.* 2015;15(8):960–967. [https://doi.org/10.1016/S1473-3099\(15\)00132-2](https://doi.org/10.1016/S1473-3099(15)00132-2)
43. Tasani M, Tong S, Andrews RM, et al. The importance of scabies coinfection in the treatment considerations for impetigo. *Pediatr Infect Dis J.* 2016;35(35):374–378. <https://doi.org/10.1097/INF.0000000000001013>
44. Carapetis JR, Steer A, Mulholland EK, et al. The global burden of group A streptococcal diseases. *Lancet Infect Dis.* 2005;5(11):685–694. [https://doi.org/10.1016/S1473-3099\(05\)70267-X](https://doi.org/10.1016/S1473-3099(05)70267-X)
45. Steer AC, Jenney A, Kado J, et al. High burden of impetigo and scabies in a tropical country. *PLoS Negl Trop Dis.* 2009;3(6):e467. <https://doi.org/10.1371/journal.pntd.0000467>
46. Bowen AC, Mahe A, Hay RJ, et al. The Global epidemiology of impetigo: a systematic review of the population prevalence of impetigo and pyoderma. *PLoS One.* 2015;10(8):e0136789. <https://doi.org/10.1371/journal.pone.0136789>
47. Walker SL, Lebas E, De Sario V, et al. The prevalence and association with health-related quality of life of tungiasis and scabies in schoolchildren in southern Ethiopia. *PLoS Negl Trop Dis.* 2017;11(8):e0005808. <https://doi.org/10.1371/journal.pntd.0005808>
48. Jin-gang A, Sheng-xiang X, Sheng-bin X, et al. Quality of life of patients with scabies. *J Eur Acad Dermatol Venereol.* 2010;24(10):1187–1191. <https://doi.org/10.1111/j.1468-3083.2010.03618.x>
49. Mitjà O, Marks M, Bertran L, et al. Integrated control and management of neglected tropical skin diseases. *PLoS Negl Trop Dis.* 2017;11(1):e0005136. <https://doi.org/10.1371/journal.pntd.0005136>
50. Micali G, Lacarrubba F, Verzi AE, et al. Scabies: advances in noninvasive diagnosis. *PLoS Negl Trop Dis.* 2016;10(6):e0004691. <https://doi.org/10.1371/journal.pntd.0004691>
51. Gunning K, Kiraly B, Pippitt K. Lice and scabies: treatment update. *Am Fam Physician.* 2019;99(10):635–642.
52. Abdel-Latif AA, Elshahed A, Salama OA, et al. Comparing the diagnostic properties of skin scraping, adhesive tape, and dermoscopy in diagnosing scabies. *Acta Dermatovenerol Alp Pannonica Adriat.* 2018;27(2):75–78.
53. Park JH, Kim CW, Kim SS, The diagnostic accuracy of dermoscopy for scabies. *Ann Dermatol.* 2012;24(2):194–199. <https://doi.org/10.5021/ad.2012.24.2.194>
54. Scanni G. The mite-gallery unit: a new concept for describing scabies through entodermoscopy. *Trop Med Infect Dis.* 2019;4(1):48. <https://doi.org/10.3390/tropicalmed4010048>
55. Dupuy A, Dehen L, Bourrat E, et al. Accuracy of standard dermoscopy for diagnosing scabies. *J Amer Acad Dermatol.* 2007;56(1):53–62. <https://doi.org/10.1016/j.jaad.2006.07.025>
56. Walter B, Heukelback J, Fengler G, et al. Comparison of dermoscopy, skin scraping, and the adhesive tape test for the diagnosis of scabies in a resource-poor setting. *Arch Dermatol.* 2011;147(4):468–473. <https://doi.org/10.1001/archdermatol.2011.51>
57. BMJ Online. *Scabies.* <https://bestpractice.bmj.com/topics/en-us/124>. Accessed December 12, 2020.
58. Osti MH, Sokana O, Gorae C, et al. The diagnosis of scabies by non-expert examiners: a study of diagnostic accuracy. *PLoS Negl Trop Dis.* 2019;13(8):e0007635. <https://doi.org/10.1371/journal.pntd.0007635>
59. Engelman D, Yoshizumi J, Hay RJ, et al. The 2020 International alliance for the control of scabies consensus criteria for the diagnosis of scabies. *Br J Dermatol.* 2020;183(5):808–820. <https://doi.org/10.1111/bjd.18943>
60. Yang YS, Byun YS, Kim JH, et al. Infantile scabies masquerading as langerhans cell histiocytosis. *Ann Dermatol.* 2015;27(3):349–351. <https://doi.org/10.5021/ad.2015.27.3.349>
61. Lacarrubba F, Verzi AE, Dinotta F, et al. Dermatoscopy in inflammatory and infectious skin disorders. *G Ital Dermatol Venereol.* 2015;150(5):521–531.
62. Whybrew C. Treating scabies infestations in children and adults. *Prescriber.* 2017;28(5):15–20. <https://doi.org/10.1002/psb.1568>
63. Romani L, Marks M, Sokana, O, et al. Feasibility and safety of mass drug coadministration with azithromycin and ivermectin for the control of neglected tropical diseases: a single-arm intervention trial. *Lancet Glob Health.* 2018;6(10):e1132–e1138. [https://doi.org/10.1016/S2214-109X\(18\)30397-8](https://doi.org/10.1016/S2214-109X(18)30397-8)
64. Marks M, Taotao-Wini B, Satorara L, et al. Long term control of scabies fifteen years after an intensive treatment programme. *PLoS Negl Trop Dis.* 2015;9(12):e0004246. <https://doi.org/10.1371/journal.pntd.0004246>
65. Romani L, Whitfeld M, Koroivuetta J, et al. Mass drug administration for scabies control in a population with endemic disease. *N Engl J Med.* 2015;373(24):2305–2313. <https://doi.org/10.1056/NEJMoa1500987>

66. Rosumeck S, Nast A, Dressler C. Ivermectin and permethrin for treating scabies. *Cochrane Database Syst Rev*. 2018;4:CD012994. <https://doi.org/10.1002/14651858.CD012994>
67. Dhana A, Okhovat JP, Cho E, et al. Ivermectin versus permethrin in the treatment of scabies: a systematic review and meta-analysis of randomized controlled trials. *J Am Acad Dermatol*. 2018;78(1):194–198. <https://doi.org/10.1016/j.jaad.2017.09.006>
68. Levy M, Martin L, Bursztejn AC, et al. Ivermectin safety in infants and children under 15 kg treated for scabies: a multicentric observational study. *Br J Dermatol*. 2020;182(4):1003–1006. <https://doi.org/10.1111/bjd.18369>
69. eTG complete. *Insects and mites: bites and infestations: Scabies*. <https://tgldcdp.tg.org.au/searchAction?appendedInputButtons=scabies>. Accessed December 12, 2020.
70. Currie BJ, McCarthy JS. Permethrin and ivermectin for scabies. *N Engl J Med*. 2010;362(8):717–725. <https://doi.org/10.1056/NEJMct0910329>
71. Albakri L, Goldman RD. Permethrin for scabies in children. *Can Fam Physician*. 2010;56(10):1005–1006.
72. Chan OB, O'Brien T, Yazdabadi A, Su JC. The diagnostic challenge of infantile scabies. *Hong Kong J Dermatol Venereol*. 2020;28(2):63–66.
73. Thomas C, Coates S, Engelman D, et al. Ectoparasites: scabies. *J Am Acad Dermatol*. 2020;82(3):533–548. <https://doi.org/10.1016/j.jaad.2019.05.109>
74. Ishii N. Guideline for the diagnosis and treatment of scabies in Japan (2nd edition). *J Dermatol*. 2008;35(6):378–393. <https://doi.org/10.1111/j.1346-8138.2008.00491.x>
75. Hicks MI, Elston DM. Scabies. *Dermatol Ther*. 2009;22(4):279–292. <https://doi.org/10.1111/j.1529-8019.2009.01243.x>
76. Hara H, Masuda T, Yokoyama A, et al. Allergic contact dermatitis due to crotamiton. *Contact Dermatitis*. 2003;49(4):219. <https://doi.org/10.1111/j.0105-1873.2003.0206h.x>
77. Chhaiya SB, Patel VJ, Dave JN, et al. Comparative efficacy and safety of topical permethrin, topical ivermectin, and oral ivermectin in patients of uncomplicated scabies. *Indian J Dermatol Venereol Leprol*. 2012;78(5):605–610. <https://doi.org/10.4103/0378-6323.100571>
78. Ahmad HM, Abdel-Azim ES, Abdel-Aziz RT. Clinical efficacy and safety of topical versus oral ivermectin in treatment of uncomplicated scabies. *Dermatol Ther*. 2016;29(1):58–63. <https://doi.org/10.1111/dth.12310>
79. Nolan K, Kamrath J, Levitt J. Lindane toxicity: a comprehensive review of the medical literature. *Pediatr Dermatol*. 2012;29(2):141–146. <https://doi.org/10.1111/j.1525-1470.2011.01519.x>
80. Thomas J, Carson CF, Peterson GM, et al. Therapeutic potential of tea tree oil for scabies. *Am J Trop Med Hyg*. 2016;94(2):258–266. <https://doi.org/10.4269/ajtmh.14-0515>
81. Centers for Disease Control and Prevention. *Parasites: Scabies*. https://www.cdc.gov/parasites/scabies/health_professionals/meds.html. Accessed December 12, 2020.
82. Goldust M, Rezaee E, Raghifar R. Comparison of oral ivermectin versus crotamiton 10% cream in the treatment of scabies. *Cutaneous Ocular Toxicol*. 2014;33(4):333–336. <https://doi.org/10.3109/15569527.2013.768258>
83. Mounsey KE, Bernigaud C, Chosidow O, et al. Prospects for moxidectin as a new oral treatment for human scabies. *PLoS Negl Trop Dis*. 2016;10(3):e0004389. <https://doi.org/10.1371/journal.pntd.0004389>
84. Arlian LG, Estes SA, Vyszynski-Moher DL. Prevalence of *Sarcoptes scabiei* in the homes and nursing homes of scabietic patients. *J Am Acad Dermatol*. 1988;19(5 Pt 1):806–811. [https://doi.org/10.1016/s0190-9622\(88\)70237-6](https://doi.org/10.1016/s0190-9622(88)70237-6)
85. Stevens DL, Bisno AL, Chambers HF, et al. Practice guidelines for the diagnosis and management of skin and soft tissue infections: 2014 update by the Infectious Diseases Society of America. *Clin Infect Dis*. 2014;59(2):e10–e52. <https://doi.org/10.1093/cid/ciu444>
86. Hartman-Adams H, Banvard C, Juckett G. Impetigo: diagnosis and treatment. *Am Fam Physician*, 2014;90(4):229–235.
87. Remote Primary Health Care Manuals. *CARPA standard treatment manual*. 7th ed. Alice Springs, NT: Centre for Remote Health; 2017.
88. Andrews RM, McCarthy J, Carapetis JR, et al. Skin disorders, including pyoderma, scabies, and tinea infections. *Pediatr Clin*. 2009;56(6):1421–1440. <https://doi.org/10.1016/j.pcl.2009.09.002>
89. Munteanu V, Petaccia A, Contecaru N, et al. Paediatric acute rheumatic fever in developed countries: neglected or negligible disease? Results from an observational study in Lombardy (Italy). *AIMS Public Health*. 2018;5(2):135–143. <https://doi.org/10.3934/publichealth.2018.2.135>
90. Roy R, Laila K. Acute post-streptococcal glomerulonephritis in children – a review. *Bangladesh J Child Health*. 2014;31(1):32–39. <https://doi.org/10.3329/bjch.v38i1.20025>
91. McCarthy JS, Kemp DJ, Walton SF, et al. Scabies: more than just an irritation. *Postgrad Med J*. 2004;80(945):382–387. <https://doi.org/10.1136/pgmj.2003.014563>
92. Liu JM, Hsu RJ, Chang FW, et al. Increase the risk of intellectual disability in children with scabies: a nationwide population-based cohort study. *Medicine*. 2017;96(23):e7108. <https://doi.org/10.1097/MD.00000000000007108>