

Kurtzman et al⁵ reported promising results in 3 patients with recalcitrant cutaneous DM who were treated with TOF. Subsequently, Paik and Christopher-Stine⁴ reported a good response to TOF treatment in an adult DM patient who had failed to respond to multiple therapies. In a review by Cinats et al⁶ of emerging uses of JAK inhibitors in skin diseases, including psoriasis, atopic dermatitis, alopecia areata, vitiligo, DM, and graft versus host disease, adverse effects reported included infections in TOF-treated patients and anemia and thrombocytopenia in those treated with ruxolitinib.⁶

In the last year, clinical cases have been published demonstrating a therapeutic effect of TOF not only in skin manifestations, but also interstitial lung disease and severe refractory calcinosis, with no notable side effects^{1,3,7-9} except for transient hypercalcemia and increased body mass index in 2 patients.¹

The present case is the sixth published description of amyopathic DM treated with TOF. As in the 5 previously published cases,^{3,5,7} the patient improved rapidly and treatment was well tolerated.

Clinical trials are required to reliably confirm the efficacy and safety profile of this treatment. A clinical trial is currently underway to evaluate the efficacy of TOF treatment of treatment-refractory DM.¹⁰

Conflicts of Interest

The authors declare that they have no conflicts of interest.

References

1. Wendel S, Venhoff N, Frye BC, May AM, Agarwal P, Rizzi M, et al. Successful treatment of extensive calcifications and acute pulmonary involvement in dermatomyositis with the Janus-Kinase inhibitor tofacitinib - A report of two cases. *J Autoimmun.* 2019;100:131-6.
2. Concha JSS, Tarazi M, Kushner CJ, Gaffney RG, Werth VP. The diagnosis and classification of amyopathic dermatomyositis: a historical review and assessment of existing criteria. *Br J Dermatol.* 2019;180:1001-8.
3. Moghadam-Kia S, Charlton D, Aggarwal R, Oddis CV. Management of refractory cutaneous dermatomyositis: potential

- role of Janus kinase inhibition with tofacitinib. *Rheumatology (Oxford).* 2019;58:1011-5.
4. Paik JJ, Christopher-Stine L. A case of refractory dermatomyositis responsive to tofacitinib. *Semin Arthritis Rheum.* 2017;46:e19.
 5. Kurtzman DJB, Wright NA, Lin J, Femia AN, Merola JF, Patel M, et al. Tofacitinib citrate for refractory cutaneous dermatomyositis: An alternative treatment. *JAMA Dermatol.* 2016;152:944-5.
 6. Cinats A, Heck E, Robertson L. Janus kinase inhibitors: a review of their emerging applications in dermatology. *Skin Therapy Lett.* 2018;23:5-9.
 7. Kurasawa K, Arai S, Namiki Y, Tanaka A, Takamura Y, Owada T, et al. Tofacitinib for refractory interstitial lung diseases in anti-melanoma differentiation-associated 5 gene antibody-positive dermatomyositis. *Rheumatology (Oxford).* 2018;57:2114-9.
 8. Hornig J, Weinhage T, Schmidt LH, Buerke B, Schneider U, Pavenstädt H, et al. Response of dermatomyositis with lung involvement to Janus kinase inhibitor treatment. *Z Rheumatol.* 2018;77:952-7.
 9. Kato M, Ikeda K, Kageyama T, Kasuya T, Kumagai T, Furuya H, et al. Successful treatment for refractory interstitial lung disease and pneumomediastinum with multidisciplinary therapy including tofacitinib in a patient with anti-MDA5 antibody-positive dermatomyositis. *J Clin Rheumatol.* 2019, <http://dx.doi.org/10.1097/RHU.0000000000000984>. Epub ahead of print.
 10. ClinicalTrials.gov. Study of tofacitinib in refractory dermatomyositis (STIR). Available in: <https://clinicaltrials.gov/ct2/show/NCT03002649?cond=dermatomyositis+tofacitinib&rank=1>. [accessed 23 May 2019].

A. Crespo Cruz^a, J. del Boz^{b,*}, C. Romero Gómez^c

^a Servicio de Dermatología, Hospital Universitario Nuestra Señora de Valme, Sevilla, Spain

^b Servicio de Dermatología, Hospital Costa del Sol, Marbella, Málaga, Spain

^c Servicio de Medicina Interna, Hospital Costa del Sol, Marbella, Málaga, Spain

* Corresponding author.

E-mail address: javierdelboz@yahoo.es (J. del Boz).

<https://doi.org/10.1016/j.adengl.2021.01.034>
1578-2190/ © 2020 AEDV. Published by Elsevier España, S.L.U. This is an open access article under the CC BY-NC-ND license (<http://creativecommons.org/licenses/by-nc-nd/4.0/>).

Adult-Onset Eccrine Angiomatous Hamartoma: A Case Report With Ultrasound Findings[☆]



Hamartoma angiomatoso ecrino en la edad adulta y sus hallazgos ecográficos

To the Editor:

Eccrine angiomatous hamartoma (EAH) is a rare, benign cutaneous tumor composed of vascular and eccrine ele-

ments. It is most commonly diagnosed during the first years of life, although there are reports of cases diagnosed in adults. We report the ultrasound findings of a 46-year-old patient with a left plantar lesion, histopathological diagnosis of which confirmed suspicion of EAH.

Case Description

A 46-year-old woman was seen for mild discomfort in the sole of her left foot when walking. During the anamnesis, she reported a lesion in the midfoot, specifically the plantar support area, that had appeared approximately 10 years earlier. Clinical examination revealed a bluish, rubbery, compressible nodule of approximately 3 cm

[☆] Please cite this article as: Vilas-Sueiro A, López-Armesto A, Mosquera-Martínez MT, Monteagudo B. Hamartoma angiomatoso ecrino en la edad adulta y sus hallazgos ecográficos. *Actas Dermosifiliogr.* 2021;112:376-378.

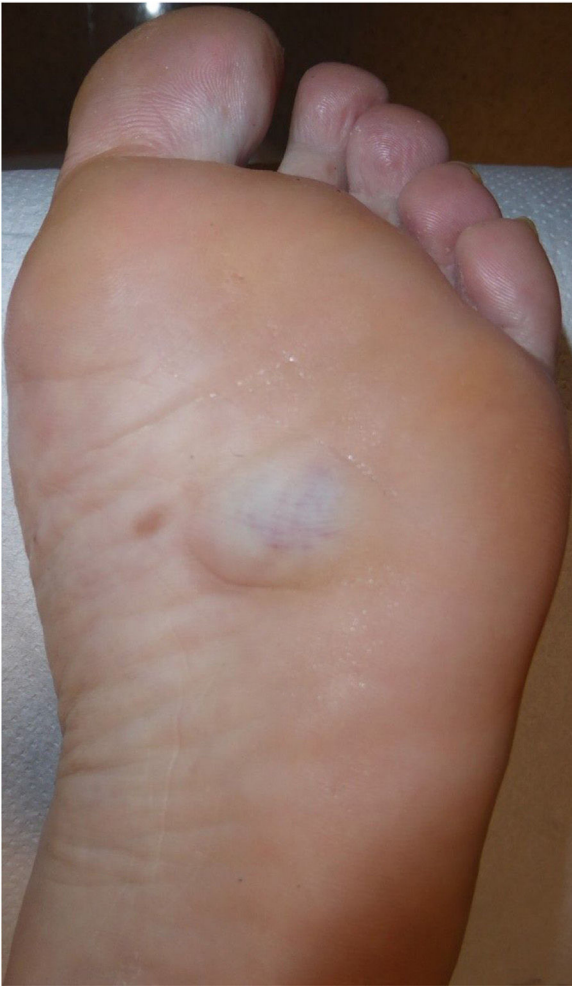

Figure 1 Clinical image showing a bluish nodular lesion of approximately 3 cm in size.

(Fig. 1). Skin ultrasound with a high-frequency (6–19 MHz) linear probe (Esaote MySix®) revealed a poorly defined dermal–hypodermal lesion. Ultrasound in B mode showed tubular hypoechoic foci with mild posterior acoustic reinforcement and isolated hyperechoic structures (Fig. 2A). Color Doppler mode revealed a moderate increase in intralésional uptake that corresponded to high flow and low resistance in spectral mode (Fig. 2B). Histology showed proliferation of dilated vessels with disorganized distribution at the level of the middle and deep dermis, as well as eccrine gland proliferation and foci of adipose tissue (Fig. 3). Due to the size of the lesion and the possible consequences of excisional surgery, it was decided, in agreement with the patient, not to remove the lesion and to adopt a wait-and-see approach.

Discussion

EAH is a sometimes congenital skin tumor that generally presents during the first years of life. However, adult onset, as in the present case, has been described.¹

The etiology and pathogenesis of EAH are poorly understood. It has been proposed that EAH is a consequence of failed interaction between the epithelial and mesenchymal components that leads to abnormal proliferation of vascular and adnexal structures. It has also been postulated that onset in adulthood may be a consequence of repeated microtrauma.² Appearance of EAH in adulthood may also be due to an absence of symptoms during the first few years and a consequent delay in diagnosis.

EAH usually manifests as a single brownish, blue, or reddish lesion. Multiple lesions can develop, usually in the distal areas of the extremities, palms, and soles.³ Most cases are asymptomatic, although some patients may experience hyperhidrosis and local pain caused by neural infiltration of the eccrine component.⁴

In addition to the findings of the clinical examination, some recently described dermoscopic findings may be diagnostically useful.⁵ We decided to perform skin ultrasound because it is a rapid, noninvasive technique that allows visualization of the deep component of lesions, and identification of vascular lesions using color Doppler mode. In our patient, ultrasound revealed a poorly delimited structure at the dermal–hypodermal level with poorly defined hypoechoic areas, which may correspond to intralésional vascular areas. Furthermore, we observed small hyperechoic areas that may correspond to adipose tissue septa interspersed throughout the lesion.

Diagnosis of EAH is clinical, although histopathologic confirmation is necessary. We observed proliferation of eccrine glands, unstructured angiomatous capillaries at the level of the dermis, and variable amounts of adipose tissue.⁶ The differential diagnosis of EAH includes the following: vascular malformations; tufted angioma (develops during the first 5 years of life and can be associated with hypertrichosis or hyperhidrosis); smooth muscle hamartoma (solitary plaques of childhood onset accompanied by hypertrichosis and hyperpigmentation); and rubber bleb nevus (blue, nodular, depressed lesions).⁷ However, eccrine nevus is the entity most difficult to differentiate from EAH. Unlike EAH, which is a mixed variant, eccrine nevus consists exclusively of eccrine tissue. Furthermore, while associated hyperhidrosis occurs in almost all cases of eccrine nevus, this clinical finding is observed in only one third of EAH cases.⁸

Definitive treatment consists of surgical resection, although given the benign nature of the tumor resection is not always necessary, and is usually only considered in cases involving bothersome symptoms such as hyperhidrosis. Other therapeutic alternatives (eg intralesional sclerosing agents, botulinum toxin, or laser) may be useful in certain patients.⁹

The case presented here underscores the value of imaging the differential diagnosis of EAH.

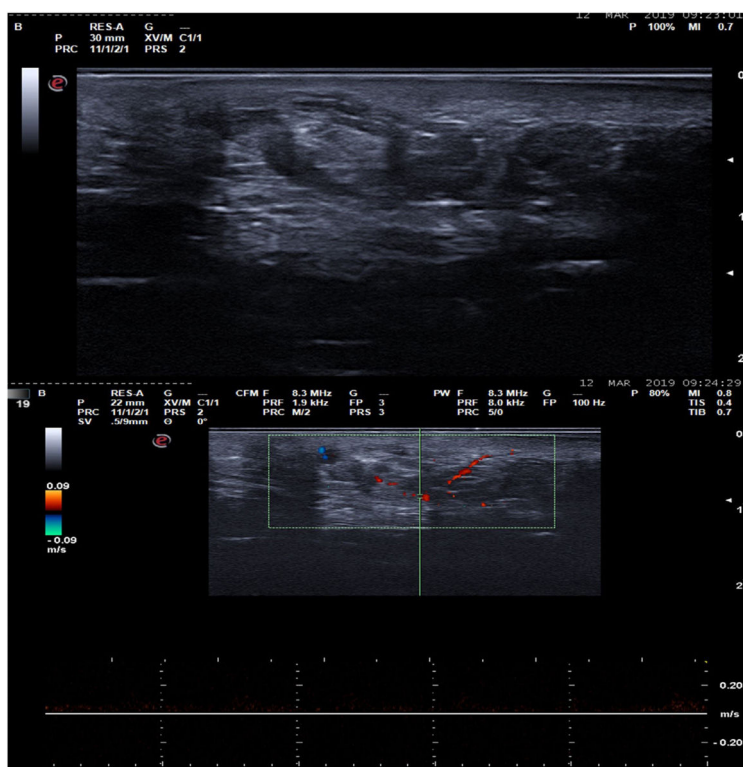


Figure 2 A, B-mode ultrasound image showing a poorly delimited, largely hypoechoic lesion containing tubular hypoechoic structures and scattered hyperechoic areas. B, Spectral Doppler ultrasound image, showing focal intralesional hypervascularization corresponding to high-flow, low-resistance vessels.

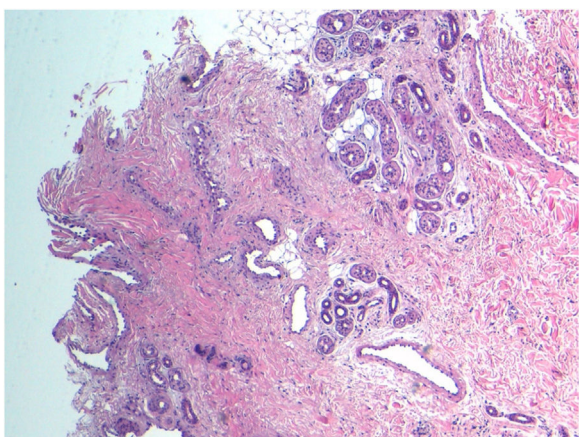


Figure 3 Histopathology image (hematoxylin-eosin, original magnification $\times 10$) showing proliferation of eccrine structures in the deep dermis, dilated capillaries, and foci of adipose tissue.

References

1. Nghiem BT, Kheterpal M, Dandekar M, Chan M, Lowe L, Wang F. Adult-onset eccrine angiomatous hamartoma: report of a rare entity with unusual histological features. *J Eur Acad Dermatol Venereol.* 2014;28:981–3.
2. Zeller DJ, Goldman RL. Eccrine-pilar angiomatous hamartoma. Report of a unique case. *Dermatologica.* 1971;143:100–4.
3. Shin J, Jang YH, Kim SC, Kim YC. Eccrine angiomatous hamartoma: a review of ten cases. *Ann Dermatol.* 2013;25:208–12.
4. Mendiratta V, Malik M, Agrawal M, Jain M, Gupta B. Congenital eccrine angiomatous hamartoma: a rare entity revisited. *Indian Dermatol Online J.* 2018;9:188–90.

5. Kelati A, Chiaverini C, Giaccherio D, Ilie M, Lacour JP, Bahadoran P. Dermoscopy of eccrine angiomatous hamartoma: the spitzoid pattern. *JAAD Case Rep.* 2018;4:835–6.
6. Larralde M, Bazzolo E, Boggio P, Abad ME, Santos Munoz A. Eccrine angiomatous hamartoma: report of five congenital cases. *Pediatr Dermatol.* 2009;26:316–9.
7. Aloï F, Tomasini C, Pippione M. Eccrine angiomatous hamartoma: a multiple variant. *Dermatology.* 1992;184:219–22.
8. Batalla A, Rosón E, Flórez A, Troncoso A, de la Torre C. [Eccrine angiomatous hamartoma: a report of 2 cases]. *Actas Dermosifiliogr.* 2011;102:289–92.
9. Kaliyadan F, Sundeep V, Hiran KR. Late onset eccrine angiomatous hamartoma treated with intralesional sclerosant: a case report. *Ind J Dermatol.* 2007;52:99–101.

A. Vilas-Sueiro^{a,*}, A. López-Armesto^b,
M.T. Mosquera-Martínez^c, B. Monteagudo^a

^a *Servicio de Dermatología, Complejo Hospitalario Universitario de Ferrol, Ferrol, A Coruña, Spain*

^b *Facultad de Enfermería y Podología, Campus de Ferrol, Universidad de A Coruña, Ferrol, A Coruña, Spain*

^c *Servicio de Anatomía Patológica, Complejo Hospitalario Universitario de Ferrol, Ferrol, A Coruña, Spain*

* Corresponding author.

E-mail address: avilassueiro@gmail.com (A. Vilas-Sueiro).

<https://doi.org/10.1016/j.adengl.2021.01.033>
1578-2190/ © 2020 AEDV. Published by Elsevier España, S.L.U. This is an open access article under the CC BY-NC-ND license (<http://creativecommons.org/licenses/by-nc-nd/4.0/>).