



Thomas Jefferson University
Jefferson Digital Commons

Phase 1

Class of 2023

2-2021

Contrast-Enhanced Endoscopic Ultrasound for Identification of Sentinel Lymph Nodes in Esophageal Cancer

Bethanne Venkatesan

Ji-Bin Liu, MD

John R. Eisenbrey, PhD

Sriharsha Gummadi, MD

Thomas Kowalski, MD

See next page for additional authors

Follow this and additional works at: https://jdc.jefferson.edu/si_ctr_2023_phase1

 Part of the [Radiology Commons](#), and the [Translational Medical Research Commons](#)

[Let us know how access to this document benefits you](#)

This Article is brought to you for free and open access by the Jefferson Digital Commons. The Jefferson Digital Commons is a service of Thomas Jefferson University's [Center for Teaching and Learning \(CTL\)](#). The Commons is a showcase for Jefferson books and journals, peer-reviewed scholarly publications, unique historical collections from the University archives, and teaching tools. The Jefferson Digital Commons allows researchers and interested readers anywhere in the world to learn about and keep up to date with Jefferson scholarship. This article has been accepted for inclusion in Phase 1 by an authorized administrator of the Jefferson Digital Commons. For more information, please contact: JeffersonDigitalCommons@jefferson.edu.

Authors

Bethanne Venkatesan; Ji-Bin Liu, MD; John R. Eisenbrey, PhD; Sriharsha Gummadi, MD; Thomas Kowalski, MD; Robert Coben, MD; Flemming Forsberg, PhD; Corinne Wessner; Priscilla Machado, MD; and David Loren, MD



**Sidney Kimmel
Medical College™**
at Thomas Jefferson University

Contrast-Enhanced Endoscopic Ultrasound for Identification of Sentinel Lymph Nodes in Esophageal Cancer

Bethanne Venkatesan, BS, Ji-Bin Liu, MD, John R. Eisenbrey*, PhD, Sriharsha Gummadi, MD, Thomas Kowalski, MD, Robert Coben, MD, Flemming Forsberg, PhD, Corinne Wessner, BS, Priscilla Machado, MD, David Loren, MD



- Esophageal Carcinoma
 - Estimated 18,400 new cases in the US in 2020
 - 5 year survival between 19% – 22%
- Tumor Staging for Esophageal Carcinoma
 - Sentinel Lymph Node identification and staging
 - Endoscopic Ultrasound Guided Biopsy – 38% - 51% accuracy
 - Radionuclide, Blue Dye, and CT – 85% accuracy
 - Prognostic significance

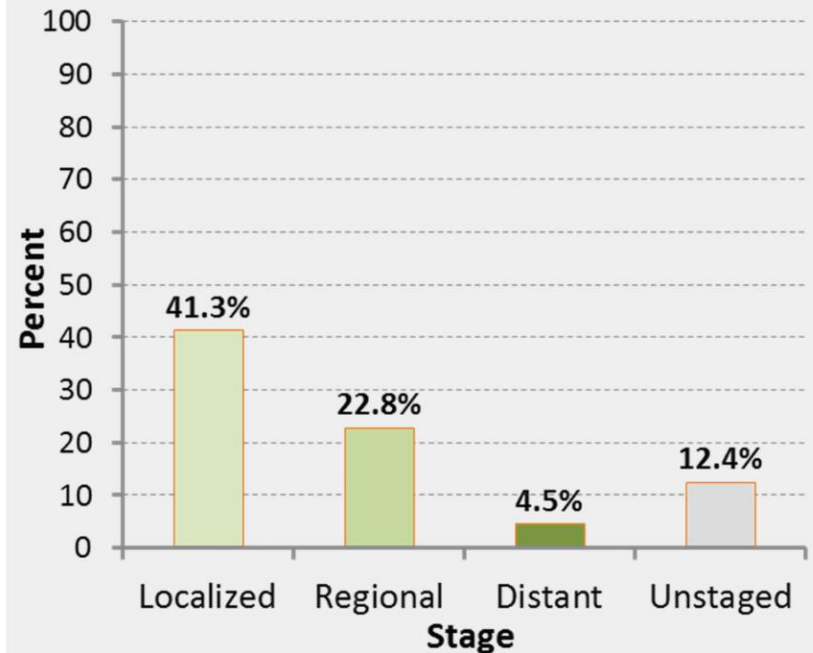
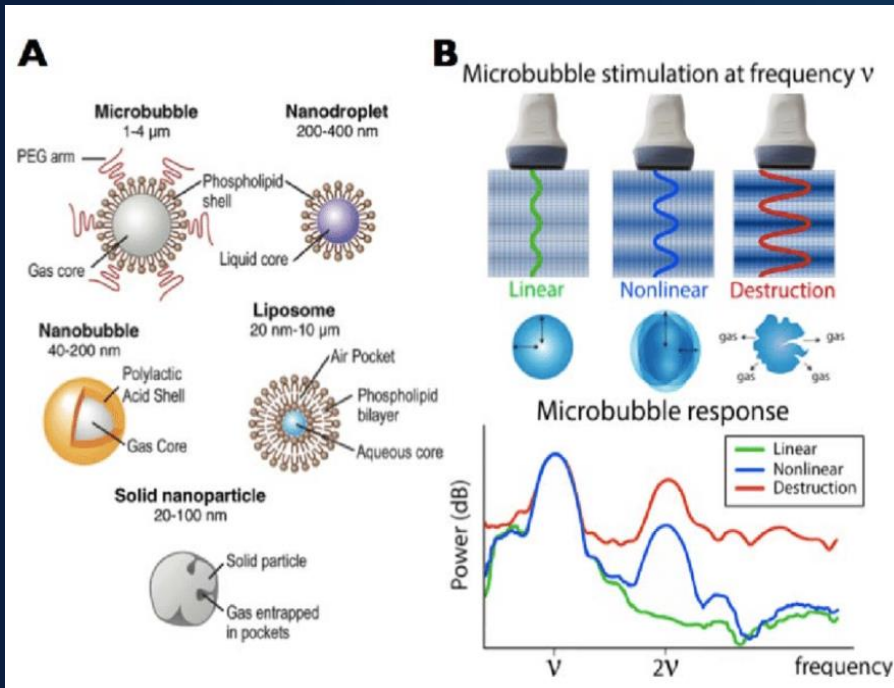


Figure 1. 5 Year survival rates of esophageal cancer by staging [SEER 2010].



- Contrast Enhanced Endoscopic Lymphsonography (CEUS)
 - Enhanced imaging of lymph nodes using Ultrasound Contrast Agents
 - “Contrast-Enhanced Ultrasound Imaging of Sentinel Lymph Nodes After Peritumoral Administration of Sonazoid in a Melanoma Tumor Animal Model”
 - Goldberg et al
 - 82% accuracy in detecting Sentinel Lymph Nodes (SLN)

Objectives & Hypothesis

- Research Question
 - How will Contrast Enhanced Lymphsonography (CEUS) compare to Endoscopic Ultrasound (EUS) in the identification of Sentinel Lymph Nodes and overall tumor staging in adult patients with esophageal carcinoma?
- Hypothesis
 - The use of CEUS in lymph node biopsy will increase the percentage of malignancy positive SLNs biopsied as compared to EUS and provide more accurate tumor staging.

Approach & Results

- Study design
 - Unblinded Pilot Study
- Population / study sample
 - 40 patients at TJUH recently diagnosed with esophageal carcinoma
- Intervention
 - Contrast Enhanced Lymphsonography
- Data source and collection
 - Comparison of patient's contrast enhanced exam with their own unenhanced exam
 - All patients will undergo non-contrast EUS and suspicious nodes will be identified and biopsied (standard of care)
 - Peritumor injection of ultrasound contrast agent, Sonazoid, will be administered and suspicious nodes by CEUS will be biopsied
 - All biopsied specimens will be assessed for presence of cancer spread by qualified pathologist

Approach & Results

- Analysis
 - Calculation of metastasis identification, accuracy of SLN identification, sensitivity, specificity, PPV, and NPV of CEUS and EUS sampled lymph nodes
 - Pathology as reference standard
- Findings

	Nodes Enhanced on CEUS	Nodes Unenhanced on CEUS	
High risk by EUS	Nodes: 6 Path Results: 2 benign 2 indeterminate/unaccessible 2 malignant	Nodes:15 Path Results: 1 benign 12 unaccessible 2 malignant	21
Low risk by EUS	Nodes: 13 Path Results: 3 benign 10 malignant	Nodes: 21 Path Results: 20 untested 1 malignant	34
	19	36	55

- EUS-guided FNA biopsy - metastasis positive rate of 40% (10/20)
- CEUS-guided biopsy - metastasis positive rate of 63% (12/19)
- 4 participants (29%) had nodal status upgrade with the addition of CE-EUS findings
 - altering their clinical management and future course of therapy

CEUS guided FNA

- Accuracy – 61.9%
- Sensitivity – 80%
- Specificity – 16.7%
- PPV – 70.6%
- NPV – 25%

EUS guided FNA

- Accuracy – 33.3%
- Sensitivity – 26.7%
- Specificity – 50%
- PPV – 57.1%
- NPV – 21.4%

CE-EUS identification and FNA of SLN may increase cytologic yield by ruling out nodes not associated with the tumor drainage pattern and identifying SLNs with metastatic deposits not seen by EUS. These findings highlight the current shortcomings of EUS nodal staging in esophageal cancer and the important clinical improvements that can be achieved even by modestly improving SLN identification.

Future Directions

- Larger trial to improve statistical significance
 - Increase length of the study to follow clinical outcomes
- Comparison of different contrast agents
- Effectiveness of Ultrasound Contrast Agent in different cancers

Acknowledgements

Special thanks to:

- Dr. Eisenbrey
- Dr. Liu
- Dr. Forsberg
- Dr. Loren