

# QUIZ

## WHAT IS YOUR DIAGNOSIS?

### Case description

A 73-year-old woman was admitted to the Department of Oral Surgery for treatment of a nodule on her tongue. The clinical diagnosis was pyogenic granuloma. What is your diagnosis?

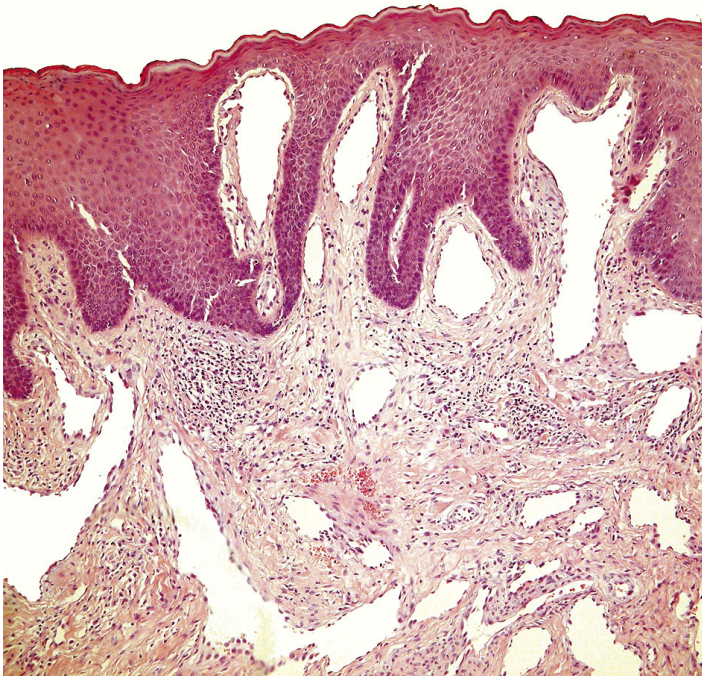


Fig. 1

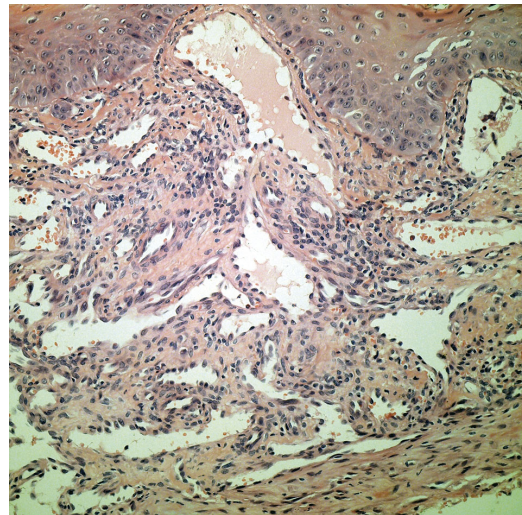


Fig. 2

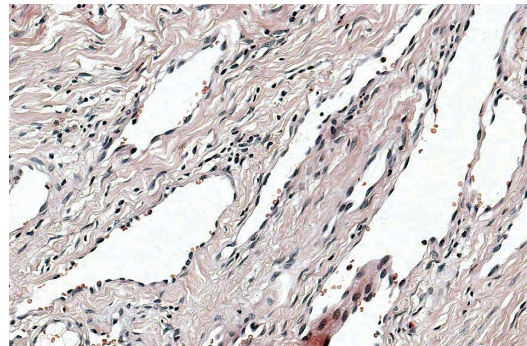


Fig. 3

Maria Hejnold<sup>1</sup>, Grzegorz Dyduch<sup>1</sup>, Izabela Mojsa<sup>2</sup>, Krzysztof Okoń<sup>1</sup>

<sup>1</sup>Department of Pathomorphology, *Collegium Medicum*, Jagiellonian University, Kraków, Poland

<sup>2</sup>Department of Oral Surgery, *Collegium Medicum*, Jagiellonian University, Kraków, Poland

Answers should be sent to the Editorial Office by 20.05.2012. The correct answer will be announced in the next issue of the *Polish Journal of Pathology*. All participants with the highest number of correct answers to the quizzes published in vol. 63 (4 issues) will be entered into the prize draw for a book.