

Sygnatura: Pol J Radiol, 2005; 70(2): 93-95

Otrzymano: 2004.06.21

Zaakceptowano: 2004.12.10

## Ectopic thymus: A rare cause of cervical mass in the neonate

Ektopowa grasicca: rzadki przypadek masy szyjnej u noworodka

Vishwanatha Kini<sup>1</sup>, Adel Ismail<sup>2</sup>, Essam Aref<sup>1</sup>, Wojciech Szmigielski<sup>1</sup>

<sup>1</sup> Departments of Radiology Hamad Medical Corporation, Doha Qatar

<sup>2</sup> Departments of Paediatrics, Hamad Medical Corporation, Doha Qatar

**Adres autora:** Dr. Wojciech Szmigielski, Radiology Department, Hamad General Hospital, P.O. Box 3050, Doha, Qatar, tel: +974 - 4392102, fax: +974 - 4392276, e-mail: wojszmi@qatar.net.qa; W.Szmigielski@gmail.com

### Summary

<b>Background:</b>	A defective migration of the thymus during fetal life leads to the remnant tissue, situated along the path of descent, forming an abnormal mass.
<b>Case Report:</b>	The case of a neonate with an upper lateral neck mass is presented. Ultrasonography, CT, and MRI could only localize this mass as lying deeply and laterally within the parotid-submandibular area. The exact nature of the mass was suggested only after histopathology, which revealed normal thymic tissue.
<b>Conclusion:</b>	Though a rare entity, ectopic thymus should be considered in the differential diagnosis of neck masses in young patients. In view of occasional neoplastic transformation, it is important to localize and recognize ectopic thymic tissue.
<b>Key words:</b>	thymus • ectopic • cervical mass • ultrasonography • CT • MRI
<b>PDF file:</b>	<a href="http://www.polradiol.com/pub/pjr/vol_70/nr_2/5738.pdf">http://www.polradiol.com/pub/pjr/vol_70/nr_2/5738.pdf</a>

### Background

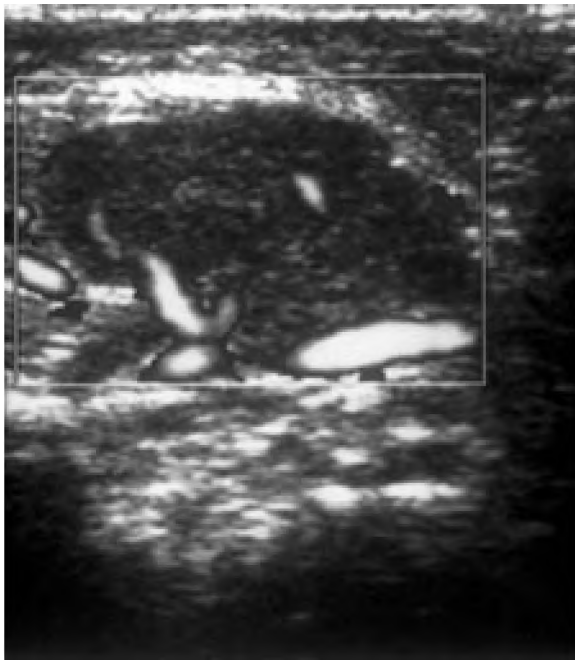
Sporadic cases of the ectopic thymic tissue formed along the path of the embryologic descent from the mandibular region to the mediastinum have been reported [1–8]. The ectopic tissue usually manifests itself as an asymptomatic mass. However, in view of the occasional neoplastic transformation, it is important to localize and recognize the ectopic thymic tissue. A case of a non-malignant ectopic thymus in addition to the normal thymus is presented.

### Case report

A male neonate, born after a full term normal delivery, was brought in with a painless right-side submandibular swelling. A physical examination revealed a non-tender mobile mass, appearing in the form of an enlarged lymph node. The haematological investigations were normal.

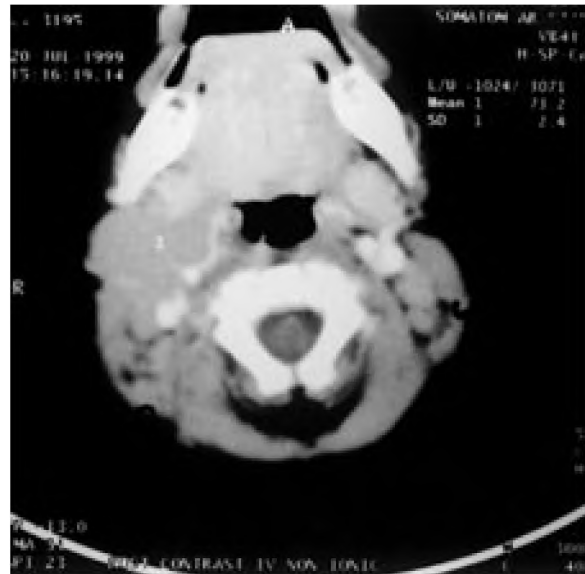Conventional and colour Doppler ultrasonography demonstrated a well-marginated hypo-echoic soft tissue mass measuring approximately 24 x16 x 12 mm, adjacent to the lower pole of the right parotid gland (Fig. 1). No hypervascularity was seen. CT (Fig. 2) and MR examinations demonstrated a homogenous, lobulated mass of soft tissue appearance, located in the right submandibular area extending deeply into the parotid and parapharyngeal regions. The submandibular gland was displaced anteriorly. The imaging features failed to ascertain its histopathological nature. The normal thymus and thyroid glands were demonstrated in their normal anatomical places. No enlarged cervical lymph nodes were noted.

The child underwent excisional biopsy of the lesion. An operatively greyish mass was found bound by the right parotid gland, carotid sheath and the nerves. A histopathological examination revealed normal thymic tissue.



**Figure 1.** Color Doppler ultrasonography of the neck: relatively well-margined hypoechoic area lacking any hypervascularity.

**Rycina 1.** Ultrasonografia z kolorowym Dopplerem szyi: stosunkowo dobrze odgraniczony obszar hipoechogeniczny bez wzmożonego unaczynienia.



**Figure 2.** Contrast-enhanced CT: soft tissue density mass (1 – mean attenuation value 73.2 HU) between the carotid vessels and the parotid gland.

**Rycina 2.** KT ze wzmocnieniem kontrastowym: masa o gęstości tkanki miękkiej (1 – średni współczynnik ostabienia 73.2 H.U.) pomiędzy naczyniami szyjnymi a przyusznicą.

## Discussion

An aberrant cervical thymus is a rare finding, and until 1990 only 79 cases had been presented of a primary neck mass [7]. Most of those lesions manifest themselves between childhood and early adulthood, corresponding with the normal growth of the thymus gland [2]. A diagnosis during infancy is rare [2] and until 1999 only nine cases of an ectopic cervical thymus in infants had been reported in the literature [6].

In terms of embryology, the thymus is derived from the ventral part of the 3<sup>rd</sup> pharyngeal pouch on each side, which grows caudally as solid diverticuli into the mesoderm anterior to the aortic arch [9]. Subsequently, the two diverticuli fuse together. In small proportion, the development occurs from the 4<sup>th</sup> pouch, which is found near the superior parathyroid gland. At birth, the thymic volume is large compared to body weight. Up to the age of two, the absolute weight increases, after which it becomes stable till the age of seven. At this time another spurt in growth is observed. It continues till the age of eleven, following which a decline in size occurs.

Clinically, the remnant thymic tissue remains mostly asymptomatic. Occasionally, it is discovered during a surgery or an autopsy. In some cases, a non-tender neck mass may be seen. In rare cases, it can lead to dyspnoea or dysphagia [3]. Usually, the ectopic thymic tissue forms

a well marginated neck mass. However, occasionally a malignant transformation can occur [1].

The site of the remnant tissue can be observed anywhere along the embryological descent path from the mandibular area down to the mediastinum. It can be adjacent to the thyroid tissue [4, 9], near the carotid bifurcation [7], the superior mediastinum and rarely within the posterior mediastinum [1].

The ectopic thymic tissue can be a solid or a cystic mass. A cystic form of the thymic remnant can occur in a significant number of cases [8]. Ectopic hematomatous thymoma has also been described [5].

In our case, the neonate had an asymptomatic submandibular swelling, which is the commonest presentation in such cases. The imaging modalities demonstrated a well defined soft tissue mass without any obvious signs of malignancy, such as hypervascularity or infiltration of the adjacent structures. Eventually, it was the histopathological examination which provided the final diagnosis.

This case indicates that the presence of the normal thymus in its normal location does not preclude a possibility of an additional ectopic thymus and such a possibility should be considered in cases of cervical masses in the paediatric age group. However, in view of the occasional neoplastic transformation, it is important to localize and recognize the ectopic thymic tissue.

---

**Piśmiennictwo:**

---

1. Anton T, Gregory PH, Hecht A et al: Malignant thymoma in an ectopic thymus: CT appearance. *J Comput Assist Tomogr*, 1991; 15(5): 842-844.
2. Appel T, Berge S, Conrad R et al: Ectopic thymus presenting as a submandibular swelling. *J Oral Maxillofac Surg*, 2001; 59: 950-953.
3. Bistritzer T, Tamir T, Oland J et al: Severe dyspnoea and dysphagia resulting from an aberrant cervical thymus. *European J Ped*, 1985; 144: 86-87.
4. Gimm O, Krause U, Wessel H et al: Ectopic intrathyroidal thymus diagnosed as a solid thyroid lesion: Case report and review of the literature. *J Ped Surg*, 1997; 32 (8): 1241-1243.
5. Hofman B, Battaglione V: Thymoma mimicking a thyroid mass. *Arch Anat Cytol-Pathol*, 1998; 46(1-2): 144-144.
6. Kacker A, April M, Markentel C-B et al: Ectopic thymus presenting as a solid submandibular neck mass in an infant: Case report and review of literature. *Int J Pediatr Otorhinolaryngol*, 1999; 49 (3): 241-245.
7. Spigland N, Bensoussan A L, Blanchard H et al: Aberrant cervical thymus in children: Three case reports and review of the literature. *J Ped Surg*, 1990; 25 (11): 1196-1199.
8. Zarbo R, Areen R, McCathey KD et al: Thymopharyngeal duct cyst: A form of cervical thymus. *Ann Oto-Rhino Laryngology*, 1983; 92: 284-289.
9. Collins P: Embryology and Development. In: *Grays Anatomy*, 38<sup>th</sup> Edition. Churchill Livingstone, 1995, p. 229.