

## CLINICAL VIGNETTE

# His bundle pacing in a patient after heart transplant and complete atrioventricular block

Krzysztof Boczar<sup>1</sup>, Andrzej Ząbek<sup>1</sup>, Mateusz Ulman<sup>1</sup>, Jacek Lelakowski<sup>2,3</sup>, Barbara Małecka<sup>2,3</sup>

<sup>1</sup> Clinical Department of Electrocardiology, John Paul II Hospital, Kraków, Poland

<sup>2</sup> Department of Electrocardiology, Institute of Cardiology, Jagiellonian University Medical College, Kraków, Poland

<sup>3</sup> John Paul II Hospital, Kraków, Poland

In this clinical vignette, we report the case of a 77-year-old man after late heart transplant (HTx) performed 17 years earlier who was referred for dual-chamber pacemaker implantation due to paroxysmal second- and third-degree atrioventricular block (FIGURE 1A and 1B) with preserved left ventricular ejection fraction of 50% to 55%.

Additionally, over a year prior to presentation, the patient sustained infarction in the transplanted heart, treated with percutaneous coronary intervention and stent implantation in the left coronary artery. Electrocardiography performed on admission showed sinus rhythm with preserved atrioventricular conduction and native QRS complexes shorter than 120 ms (FIGURE 1C).

A collective decision was made to implant a dual-chamber cardiac pacemaker enabling His bundle pacing (HBP).<sup>1</sup> The procedure was performed in the electrophysiology laboratory under local anesthesia. Both leads were implanted using cephalic vein cutdown. First, the HBP lead was implanted and the procedure was guided by fluoroscopy and electrophysiological measurements. A 69-cm Lumenless 3830 lead (Medtronic, Minneapolis, Minnesota, United States) was navigated with the Medtronic C315 HIS catheter delivery system into the vicinity of the His bundle. The location of the His bundle was sought with unipolar / bipolar electrophysiological testing and anatomically with fluoroscopy. The presence of a His bundle potential was confirmed by an intracardiac electrogram (FIGURE 1D). The HV interval was estimated at less than 60 ms with the use of the Carelink 2090 Programmer (Medtronic). We achieved a selective His bundle capture. Threshold on the His bundle lead was 0.6 V at 1 ms. The atrial 52-cm

Model 5076 lead (Medtronic) was implanted into the right atrial appendage of the donor heart. During the procedure, an intracardiac electrogram showed atrial fibrillation in the remnants of the recipient's heart.<sup>2</sup> Both leads were connected to the Vitatron G70A2 dual-chamber pacemaker. The procedure was uneventful (total procedural time, 45 min; fluoroscopy time, 432 s; radiation exposure, 122 mGy). Correct lead placement was confirmed by chest X-ray (FIGURE 1E). After the procedure, a DDD pacing mode was implemented. Paced AV duration was programmed to 80 ms for HBP. Subsequent electrocardiography showed a sinus rhythm and synchronized selective atrial HBP. His bundle pacing resulted in QRS intervals of 120 ms, which was similar to intrinsic QRS duration (FIGURE 1E). No adverse events were noted during a short 2-month follow-up. The patient received optimal pharmacological treatment. Pacing parameters remained normal. Device Holter monitoring recorded 96.5% of HBP and 44.5% of atrial pacing.

In the described case, the implementation of HBP in a patient after HTx proved to be an effective and safe pacing method. Although this is a single case report and its results cannot be extrapolated to a large population, it remains in line with the current data on HBP in patients with normal hearts.<sup>3</sup> To the best of our knowledge, this is the first described case of HBP implementation in a transplanted heart.

According to previous studies, both selective and nonselective HBP are similar and have an advantage over right ventricular pacing.<sup>4</sup> Future studies are needed to evaluate the long-term effects of HBP in large samples of patients after HTx.

**Correspondence to:**

Krzysztof Boczar MD, PhD, Clinical Department of Electrocardiology, John Paul II Hospital, ul. Prądnicza 80, 31-202 Kraków, Poland, phone: +48 12 614 23 81, email: krzysiek.boczar@gmail.com  
Received: September 26, 2020.

**Revision accepted:**

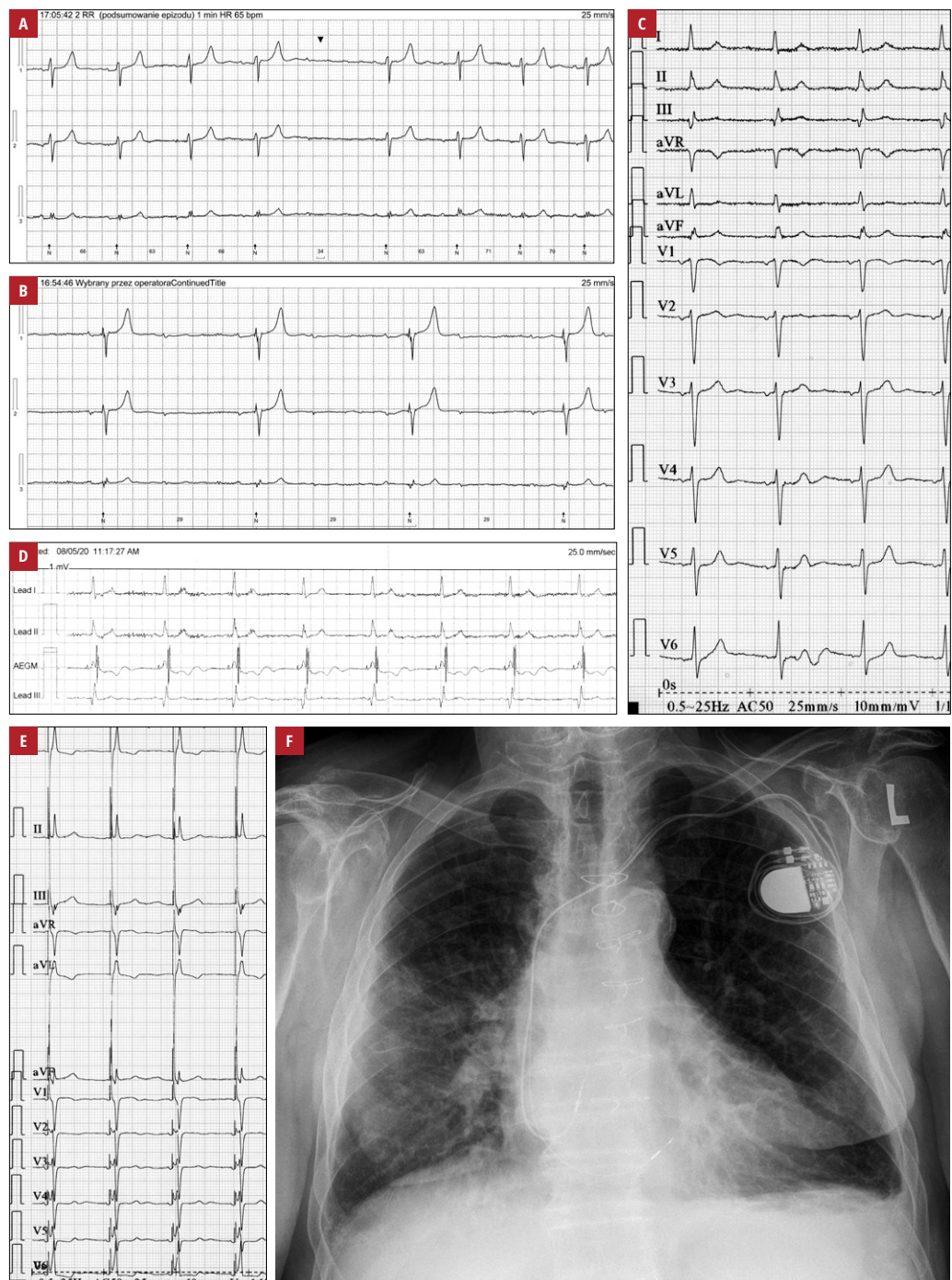
October 30, 2020.

**Published online:**

November 13, 2020.

Kardiol Pol. 2021; 79 (1): 81-82  
doi:10.33963/KP.15681

Copyright by the Author(s), 2021



**FIGURE 1** **A** – Holter electrocardiogram showing second-degree type 1 paroxysmal atrioventricular block; **B** – Holter electrocardiogram depicting third-degree paroxysmal atrioventricular block; **C** – electrocardiogram performed on admission, demonstrating sinus rhythm with preserved atrioventricular conduction and native QRS complexes shorter than 120 ms; **D** – presence of a His bundle potential confirmed by an intracardiac electrogram; **E** – electrocardiogram performed after implantation; **F** – chest X-ray after implantation

## ARTICLE INFORMATION

**CONFLICT OF INTEREST** None declared.

**OPEN ACCESS** This is an Open Access article distributed under the terms of the Creative Commons Attribution-NonCommercial-NoDerivatives 4.0 International License (CC BY-NC-ND 4.0), allowing third parties to download articles and share them with others, provided the original work is properly cited, not changed in any way, distributed under the same license, and used for non-commercial purposes only. For commercial use, please contact the journal office at [kardiologiapolska@ptkardio.pl](mailto:kardiologiapolska@ptkardio.pl).

**HOW TO CITE** Boczar K, Ząbek A, Ulman M, et al. His bundle pacing in a patient after heart transplant and complete atrioventricular block. *Kardiol Pol.* 2021; 79: 81-82. doi:10.33963/KP.15681

## REFERENCES

- 1 Ząbek A, Małecka B, Lelakowski J. One heart, two rhythms [in Polish]. *Kardiol Pol.* 2008; 66: 99-100.
- 2 Kusumoto FM, Schoenfeld MH, Barrett C, et al. 2018 ACC/AHA/HRS Guideline on the evaluation and management of patients with bradycardia and cardiac conduction delay. *Circulation.* 2019; 140: e382-e482.
- 3 Barba-Pichardo R, Moríña-Vázquez P, Venegas-Gamero J, et al. Permanent His-bundle pacing in patients with infra-Hisian atrioventricular block [in Spanish]. *Rev Esp Cardiol.* 2006; 59: 553-558.
- 4 Curilá K, Prochazkova R, Jurak P, et al. Both selective and nonselective His bundle, but not myocardial, pacing preserves ventricular electrical synchrony assessed by ultra-high-frequency ECG. *Heart Rhythm.* 2020; 17: 607-614.