

ORIGINAL ARTICLE

Topography of the oblique vein of the left atrium (vein of Marshall)

Anna Żabówka¹, Marcin Jakiel¹, Filip Bolechała², Rafał Jakiel¹, Katarzyna A. Jasińska¹, Mateusz K. Hołda^{1,3}

¹ HEART – Heart Embryology and Anatomy Research Team, Department of Anatomy, Jagiellonian University Medical College, Kraków, Poland

² Department of Forensic Medicine, Jagiellonian University Medical College, Kraków, Poland

³ Division of Cardiovascular Sciences, The University of Manchester, Manchester, United Kingdom

KEY WORDS

coronary veins, left atrium, oblique vein of the left atrium, pulmonary veins, vein of Marshall

ABSTRACT

BACKGROUND The oblique vein of the left atrium is of interest for electrophysiologists working in the field of both basic science and clinical practice.

AIMS We aimed to examine the topographic anatomy of the oblique vein and to assess the vein's location and relationships with surrounding cardiac structures.

METHODS A total of 200 autopsied adult human hearts were examined.

RESULTS The oblique vein was observed in 71% of the hearts. Its mean (SD) total length was 30.8 (13.6) mm. In hearts with the oblique vein, a larger distance was observed between the left inferior pulmonary vein (LIPV) and great cardiac vein (mean [SD], 18.6 [5.1] mm vs 16.3 [4.8] mm; $P = 0.004$), between the left atrial appendage (LAA) and LIPV (mean [SD], 17.8 [6.8] mm vs 15.1 [5.2] mm; $P = 0.007$), and between the LAA and left superior pulmonary vein (LSPV; mean [SD], 28.5 [7.2] mm vs 21.3 [6.4] mm; $P < 0.001$). Hearts with a classic pattern of left-sided pulmonary veins were categorized into 4 types based on the length of oblique vein extension. In type I, the vein extended below the level of the LIPV (21.9%); in type II, to the level of the LIPV (47.7%); in type III, to the level of the interpulmonary area (17.2%); and in type IV, to the level of the LSPV (13.3%). In each type, the distance between the oblique vein and LIPV was shorter than that between the oblique vein and LAA.

CONCLUSIONS The oblique vein had a variable course and differing lengths of extension. The presence of the oblique vein was connected with a greater distance between the left-sided pulmonary veins and LAA.

INTRODUCTION Initially described in 1850 by John Marshall, the oblique vein of the left atrium (LA) is an embryological remnant of the left common cardinal vein.¹ It drains blood from the posterolateral wall of the LA and joins the cardiac venous system at the point where the great cardiac vein becomes the coronary sinus.²⁻⁴ Although there is lack of agreement on its occurrence, studies report that the vein is present in 30% to 98% of the hearts; in the remaining cases, it is obliterated and forms the ligament of Marshall.⁵⁻⁷ Although the oblique vein is small in diameter and does not play a significant role in cardiac vascularization, it is of particular interest for electrophysiologists working in the field of both basic science and clinical practice.⁸

The oblique vein of the LA is rich in myocardial sleeves that are continuous with the musculature of the coronary sinus.⁹ Moreover, besides being densely innervated by sympathetic nerve fibers, it also has multiple myocardial tract insertions into the LA wall, left-sided pulmonary veins, and coronary sinus.³ Due to these electrophysiological characteristics, the vein or ligament of Marshall can contribute to the formation of a substrate of reentry or it can be a source of ectopic focal electrical activity.¹⁰ Therefore, the oblique vein of the LA has become the target of ablation procedures, which include radiofrequency and chemical ablation.¹¹

Investigators have been studying the morphology of the oblique vein for the past several

Correspondence to:

Mateusz Hołda, MD, PhD,
HEART – Heart Embryology and
Anatomy Research Team,
Department of Anatomy,
Jagiellonian University Medical
College, ul. Kopernika 12,
31-034 Kraków, Poland,
phone: +48 12 422 95 11,
email: mkh@onet.eu

Received: March 18, 2020.

Revision accepted: April 26, 2020.

Published online: April 28, 2020.

Kardiologia Pol. 2020; 78 (7-8): 688-693
doi:10.33963/KP.15318

Copyright by the Author(s), 2020

WHAT'S NEW?

This study examined the topographic anatomy of the oblique vein of the left atrium (vein of Marshall), with a focus on assessing the vein's location and relationships with surrounding cardiac structures. The oblique vein had a variable course and differing lengths of extension, which were classified into 4 distinct types. The presence of an oblique vein was associated with a larger distance between left-sided pulmonary veins and the left atrial appendage. The findings from this study may prove useful for clinicians planning procedures at or near the oblique vein of the left atrium.

decades. Most studies focused on investigating the vein's prevalence, dimensions, histological characteristics, and the location of its ostium.^{3,6,7,12} Despite the vast literature on the subject, some morphometric features of the left oblique vein have not been sufficiently documented. For instance, little is known about the relationship between the oblique vein and the left-sided pulmonary veins or the LA appendage (LAA). Therefore, the aim of this study was to fill that knowledge gap and to evaluate the topographic anatomy of the oblique vein. We focused on assessing the vein's location as well as the interconnections with surrounding cardiac structures.

METHODS This study was conducted at the Department of Anatomy of Jagiellonian University Medical College (Kraków, Poland). It was approved by the Bioethical Committee of Jagiellonian University (No. 1072.6120.120.2018). The study protocol conformed to the ethical guidelines of the 1975 Declaration of Helsinki. The methods were carried out in accordance with the approved guidelines.

Study population The study was performed on 200 adult human hearts collected during routine forensic medical autopsies. Demographic data were available for all studied subjects. Our sample size represented both sexes (female, 22%), and the age of the donors ranged from 18 to 93 years (mean [SD] age, 48.7 [15.6] years). The mean (SD) body mass index of the donors was 26.6 (4.3) kg/m². We excluded subjects who died of heart failure or had any heart trauma, severe cardiac anatomical defects, evident severe macroscopic pathologies of the heart, or heart grafts. We also excluded samples that displayed signs of cadaver decomposition.

Dissection and measurements The hearts and their adjoining great vessels were dissected in a routine manner. All specimens were thoroughly washed to remove excess blood. Subsequently, the hearts were weighed and placed in a 10% paraformaldehyde buffered solution.

First, the coronary sinus was opened longitudinally at the ostium of the coronary sinus all

the way down to the great cardiac vein. This allowed the visualization of the ostium of the left oblique vein. The anterior wall of the LA was also dissected to expose the posterolateral region. After the ostium of the oblique vein was identified, the vein was bluntly dissected from the surrounding tissue by following its epicardial trajectory. The spatial configuration between the oblique vein of the LA and left-sided pulmonary veins and the LAA was assessed. Any variation in the left-sided pulmonary venous drainage was also documented. The following distances were recorded for each specimen: 1) the length of the course of the oblique vein (measured from its ostium until the most prominent extension of the main trunk of the vessel was no longer visible); 2) a distance between the inferior margin of the ostium of the left inferior pulmonary vein (LIPV) and the great cardiac vein (measured from the epicardial side of the LA); 3) the transverse (parallel to the mitral annulus) and superoinferior diameters of the left-sided pulmonary vein ostia; 4) the interpulmonary venous distance (measured from the epicardial side as the distance between the ostium of the left superior pulmonary vein [LSPV] and the LIPV); 5) the transverse diameter of the LAA orifice (parallel to the mitral valve annulus); 6) the shortest distance between the LAA and the LIPV and LSPV (measured from the epicardial side of the LA); and 7) the shortest distance between the oblique vein of the LA and the left margin of the LIPV and LSPV and between the right margin of the LAA (measured at the central level of these structures).

All measurements were collected with the heart held in the attitudinally correct anatomical position. Linear dimensions were recorded with a 0.03-mm precision electronic caliper (YT-7201; YATO, Wrocław, Poland) by 2 different investigators. If a recorded result varied by more than 10%, both investigators were asked to re-measure the specimen and the mean of the 2 new values was reported as the final value.

Statistical analysis All collected data were reported as mean values with the corresponding standard deviations or determined percentages. The Shapiro–Wilk test was used to determine if there was a normal distribution of quantitative data. The Levene test was performed to verify the relative homogeneity of variance. The *t* test and Mann–Whitney test were used for statistical comparisons. Qualitative variables were compared using the χ^2 test of proportions with the Bonferroni correction to account for multiple comparisons. A *P* value lower than 0.05 was considered significant. Statistical analyses were performed using the STATISTICA 13.1 software for Windows (StatSoft Inc., Tulsa, Oklahoma, United States).

TABLE 1 Morphometric characteristics of the heart specimens according to the presence or absence of the oblique vein of the left atrium (n = 200)

Parameter	Oblique vein of the left atrium		P value
	Present (n = 142)	Absent (n = 58)	
LIPV ^a -to-GCV distance, mm	18.6 (5.1)	16.3 (4.8)	0.005
LIPV transverse diameter, mm	14.2 (3.4)	14.5 (3.2)	0.57
LIPV superoinferior diameter, mm	10.4 (2.7)	10.1 (2.9)	0.49
LSPV transverse diameter, mm	14.4 (3)	15.1 (3.2)	0.14
LSPV superoinferior diameter, mm	11.7 (2.6)	11.8 (3)	0.81
Interpulmonary distance ^b , mm	3.9 (2.3)	4.1 (2.2)	0.58
LAA diameter, mm	12.7 (4.4)	12.9 (4.6)	0.77
LIPV ^a -to-LAA distance, mm	17.8 (6.8)	15.1 (5.2)	0.007
LSPV-to-LAA distance, mm	28.5 (7.2)	21.3 (6.4)	<0.001

Data are presented as mean (SD).

a Or the left common pulmonary vein ostium

b Values only for hearts with a classic pattern of the left-sided pulmonary vein drainage

Abbreviations: GCV, great cardiac vein; LAA, left atrial appendage; LIPV, left inferior pulmonary vein; LSPV, left superior pulmonary vein

RESULTS The oblique vein of the LA was observed in 142 of the 200 hearts (71%) and had a mean (SD) total length of 30.8 (13.6) mm. Vein occurrence did not correlate with the sex of the donor ($P = 0.47$). The morphometric characteristics of the studied region according to the presence or absence of the oblique vein are presented in TABLE 1. Hearts with the oblique vein of the LA showed a significantly larger distance between the LIPV and the great cardiac vein,

between the LAA and the LIPV, and between the LAA and the LSPV (TABLE 1).

The classic pattern of the left-sided pulmonary venous drainage (ie, with one superior and one inferior pulmonary vein ostium) was observed in 184 hearts (92%). The remaining 16 specimens (8%) had a single common left pulmonary vein ostium. The prevalence of the oblique vein was similar in hearts with a single left pulmonary vein ostium and those with a classic pattern of the pulmonary venous return (87.5% [14 of the 16 hearts] and 69.6% [128 of the 184 hearts], respectively; $P = 0.13$). The total length of the oblique vein was lower in hearts with a classic pattern of the pulmonary venous drainage (mean [SD], 27.6 [10.4] vs 48.3 [5.6] mm; $P < 0.001$).

The oblique vein was usually found in the area extending below the left inferior (or left common) pulmonary vein or, alternatively, between the left-sided pulmonary veins and the LAA. Its course never followed the right margin of the left-sided pulmonary veins.

Cases with the classic pattern of the left-sided pulmonary venous drainage were further subdivided into 4 distinct categories, which were grouped based on the length of the venous extension: 1) type I, vein extending below the level of the LIPV (FIGURE 1); 2) type II, vein extending to the level of the LIPV; 3) type III, vein extending to the level of the interpulmonary area; and 4) type IV, vein extending to the level of the left superior pulmonary vein (FIGURE 2). The measurements corresponding to each type are presented in TABLE 2. The total length of the vein differed between groups, with the lowest value observed for type I and

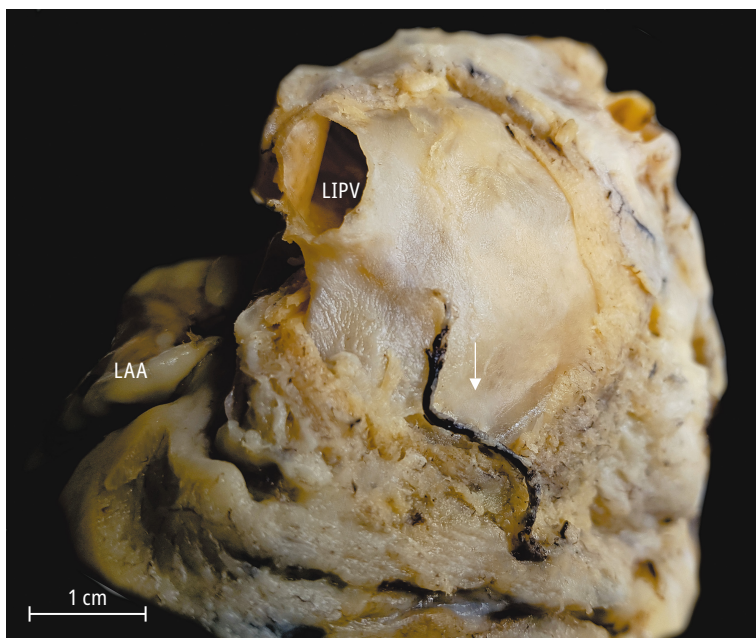


FIGURE 1 Cadaveric heart specimen showing type I of the oblique vein of the left atrium (arrow), extending below the level of the left inferior pulmonary vein

Abbreviations: see TABLE 1

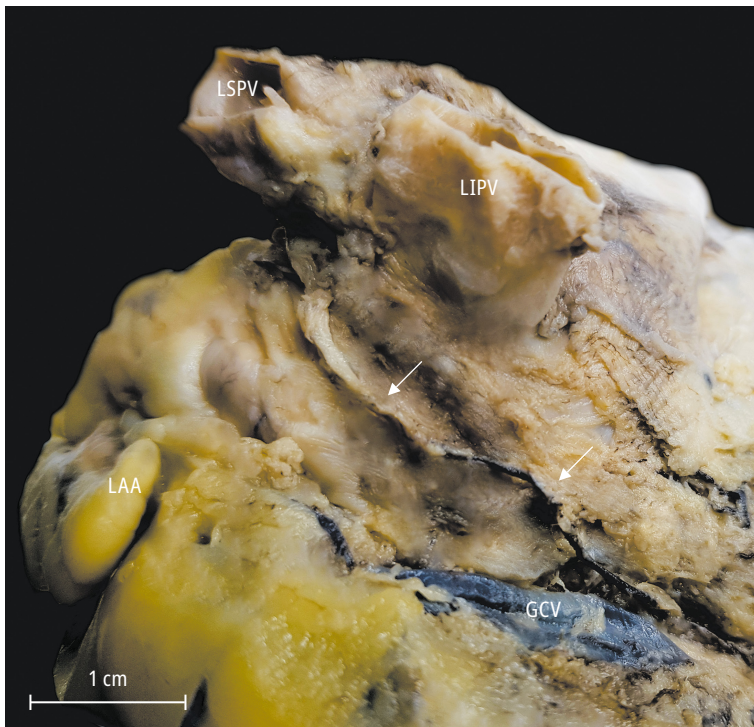


FIGURE 2 Cadaveric heart specimen showing type IV of the oblique vein of the left atrium (arrows), extending to the level of the left superior pulmonary vein (LSPV)
Abbreviations: see TABLE 1

TABLE 2 Prevalence and morphometric characteristics of the oblique vein of the left atrium depending on the type of the vein (n = 128)

Parameter	Type of the vein			
	Type I	Type II	Type III	Type IV
Prevalence, n (%)	28 (21.9)	61 (47.7)	22 (17.2)	17 (13.3)
Total vein length, mm	20.1 (6.2)	34.2 (4.3)	37.9 (2.7)	48.9 (9.8)
Vein-to-LIPV distance, mm	–	8.6 (2.3)	6.5 (3.1)	5.8 (2.7)
Vein-to-LAA distance, mm	–	16.1 (4.2)	17.5 (4.8)	25.8 (4.1)
Vein-to-LSPV distance, mm	–	–	–	3.2 (1.3)

Data are presented as mean (SD) unless otherwise indicated.

Abbreviations: see TABLE 1

the highest, for type IV. The distance between the oblique vein and the left margin of the LIPV was shorter than that between the vein and the right margin of the LAA in all types (TABLE 2; all $P < 0.001$). The sex of the donor had no influence on any of the measured parameters (all $P > 0.05$).

DISCUSSION There are several reasons why the location of the oblique vein of the LA is clinically relevant, the most important being the high potential of the vein for electrical activity and its frequent involvement in the development and maintenance of various arrhythmias.^{10,13,14} As demonstrated in our study, the oblique vein

is always found in the area extending between the left-sided pulmonary veins and the LAA. This region also corresponds to the location of the left common cardinal vein during prenatal development and to the site of a persistent left superior vena cava (if the left-sided cardinal veins are fully patent).¹⁵ The epicardial location of the oblique vein aligns with the LA ridge—the most prominent endocardial fold in the LA structure.¹⁶ The oblique vein is also adjacent to 3 important entities from the perspective of electrophysiology: the pulmonary veins, LAA, and mitral isthmus. These neighboring structures, along with the muscular sleeves within the oblique vein and the surrounding dense neural network, can hinder procedures such as pulmonary vein isolation or mitral isthmus ablation.¹⁷ The presence of the vein has also been linked to the formation of epicardial conductive bridges over lesions that may show proarrhythmic activity.⁹

Although the oblique vein of the LA is located close to the pulmonary vein ostia, the structures are separated by a few millimeters of tissue. As a result, both circumferential radiofrequency ablation of the pulmonary vein ostia and cryoballoon ablation may damage the oblique vein. Circumferential radiofrequency is always performed near but not at the vein ostia. As such, it may also coincide with the territory of the oblique vein.^{18,19} On the other hand, due to the epicardial location of the oblique vein and the abundant adipose tissue that surrounds it, the effect of either technique may be negligible and an epicardial approach may be required.²⁰ Furthermore, because the oblique vein often crosses the region of the mitral isthmus (located between the LIPV and the mitral annulus), it may partly explain poor long-term outcomes in linear mitral isthmus ablation procedures.^{17,21,22} Thus, to interrupt any hidden electrical activity arising from the oblique vein, it has been proposed to use the targeted retrograde intravenous ethanol infusion approach (chemical ablation) to reliably achieve a conduction block.¹¹

Another key aspect in the anatomy of the oblique vein is its ostium, which conventionally marks the border between the great cardiac vein and the coronary sinus. The oblique vein cannulation is not only required for its retrograde ethanol ablation but also to record electrical potentials from the oblique vein, or even the vein may be considered as an alternative site for epicardial LA pacing.^{10,23} Furthermore, in 46.9% of the hearts, the ostium of the oblique vein was accompanied by the Vieussens valve. An overwhelming majority of hearts with this valve and the oblique vein (90%) had their oblique vein's ostium located closer to the coronary sinus ostium than to the Vieussens valve. Moreover, the ostium is often covered by the leaflet of the valve. In such a specific arrangement, the Vieussens

valve could serve as an anatomic landmark for the identification of the oblique vein or as a fulcrum during vein catheterization.²⁴

To achieve the best outcome and to minimize the risk of complications, it is still recommended to try to visualize the coronary venous system prior to invasive interventions.²⁵ Coronary venous system anatomy is relevant not only during cardiac resynchronization therapy implantations but also during electrophysiology studies as well as ablation inside the venous system. Operators must always keep in mind that the oblique vein may be a site for inadvertent cannulation by guidewires, diagnostic electrophysiology catheters, and left ventricular pacing electrodes, posing a risk of coronary venous system perforation and pericardial effusion or tamponade.²⁶ The availability of electrocardiographically gated contrast-enhanced computed tomography angiography and of contrast-enhanced cardiac magnetic resonance angiography allows for noninvasive imaging of the cardiac vasculature.^{27,28} Unfortunately, evidence suggests that with cardiac computed tomography the oblique vein was detected in only 20% of patients, despite using high-resolution equipment and appropriate scanning and reconstruction protocols.²⁹ However, intraprocedural rotational venography, a technique that allows a multi-angle and dynamic imaging of the venous tree, offered a much more promising outcome, with the oblique vein visualized in 84% of patients.²³

The current study has several limitations. First, all measurements were performed on heart specimens that underwent paraformaldehyde fixation. This might have affected the size and shape of the specimens, although a previous study demonstrated that the use of 10% formaldehyde solution for preservation of cardiac tissue samples did not significantly influence atrial tissue dimensions.^{30,31} Second, the measurements were performed on autopsied material; therefore, it may not be a direct representation of the morphology of tissues in vivo. Moreover, the results of the current study do not provide data on the dimensional changes within the cardiac cycle. Nonetheless, in our opinion, these limitations do not significantly affect our morphological analyses, especially those regarding the course and extent of the oblique vein of the LA and the mutual relationships between surrounding structures.

In conclusion, this study presented detailed topographic descriptions of the oblique vein of the LA. The vein was found in 71% of the hearts in the area located below the LIPV or, alternatively, between the left-sided pulmonary veins and the LAA. The oblique vein had varying extension lengths, classified into 4 distinct types. In about 70% of cases, the oblique vein did not exceed the level of the LIPV. The presence of the oblique vein was associated with a greater

distance between the left-sided pulmonary veins and the LAA. Our findings may prove useful for clinicians planning procedures at or near the oblique vein of the LA.

ARTICLE INFORMATION

CONFLICT OF INTEREST None declared.

OPEN ACCESS This is an Open Access article distributed under the terms of the Creative Commons Attribution-Non Commercial-No Derivatives 4.0 International License (CC BY-NC-ND 4.0), allowing third parties to download articles and share them with others, provided the original work is properly cited, not changed in any way, distributed under the same license, and used for non-commercial purposes only. For commercial use, please contact the journal office at kardiologiapolska@ptkardio.pl.

HOW TO CITE Żabówka A, Jakiel M, Bolechała F, et al. Topography of the oblique vein of the left atrium (vein of Marshall). *Kardiol Pol.* 78: 688-693. doi:10.33963/KP.15318

REFERENCES

- 1 Marshall J. On the Development of the Great Anterior Veins in Man and Mammalia; Including an Account of Certain Remnants of Foetal Structure Found in the Adult, a Comparative View of These Great Veins in the Different Mammalia, and an Analysis of Their Occasional Peculiarities in the Human Subject. *Philosophical Transactions of the Royal Society of London.* 1850; 140: 133-170. www.jstor.org/stable/108430.
- 2 Von Lüdinghausen M, Ohmachi N, Besch S, Mettenleiter R. Atrial veins of the human heart. *Clin Anat.* 1995; 8: 169-189.
- 3 Kim DT, Lai AC, Hwang C, et al. The ligament of Marshall: a structural analysis in human hearts with implications for atrial arrhythmias. *J Am Coll Cardiol.* 2000; 36: 1324-1327.
- 4 Mazur M, Żabówka A, Bolechała F, et al. Variations and angulation of the coronary sinus tributaries: Implications for left ventricular pacing. *Pacing Clin Electrophysiol.* 2019; 42: 423-430.
- 5 Chandler N, Aslanidi O, Buckley D, et al. Computer three-dimensional anatomical reconstruction of the human sinus node and a novel paranodal area. *Anat Rec Adv Integr Anat Evol Biol.* 2011; 294: 970-979.
- 6 Cendrowska-Pinkosz M, Urbanowicz Z. Analysis of the course and the ostium of the oblique vein of the left atrium. *Folia Morphol.* 2000; 59: 163-166.
- 7 DeSimone CV, Noheria A, Lachman, N et al. Myocardium of the superior vena cava, coronary sinus, vein of Marshall, and the pulmonary vein ostia: gross anatomic studies in 620 hearts. *J Cardiovasc Electrophysiol.* 2012; 23: 1304-1309.
- 8 Sánchez-Quintana D, López-Mínguez JR, Macías Y, et al. Left atrial anatomy relevant to catheter ablation. *Cardiol Res Pract.* 2014; 2014: 289720.
- 9 Chauvin M, Shah DC, Haïssaguerre M, et al. The anatomic basis of connections between the coronary sinus musculature and the left atrium in humans. *Circulation.* 2000; 101: 647-652.
- 10 Hwang C, Wu TJ, Doshi RN, et al. Vein of Marshall cannulation for the analysis of electrical activity in patients with focal atrial fibrillation. *Circulation.* 2000; 101: 1503-1505.
- 11 Báez-Escudero JL, Morales PF, Dave AS, et al. Ethanol infusion in the vein of Marshall facilitates mitral isthmus ablation. *Hear Rhythm.* 2012; 9: 1207-1215.
- 12 de Oliveira IM, Scanavacca MI, Correia AT, et al. Anatomic relations of the Marshall vein: importance for catheterization of the coronary sinus in ablation procedures. *Europace.* 2007; 9: 915-919.
- 13 Rodríguez-Mañero M, Schurmann P, Valderrábano M. Ligament and vein of Marshall: a therapeutic opportunity in atrial fibrillation. *Hear Rhythm.* 2016; 13: 593-601.
- 14 Lee JH, Nam G-B, Kim M, et al. Radiofrequency catheter ablation targeting the vein of Marshall in difficult mitral isthmus ablation or pulmonary vein isolation. *J Cardiovasc Electrophysiol.* 2017; 28: 386-393.
- 15 Tyrak KW, Hołda J, Hołda MK, et al. Persistent left superior vena cava. *Cardiovasc J Afr.* 2017; 28: e1-e4.
- 16 Piątek-Koziej K, Hołda J, Tyrak K, et al. Anatomy of the left atrial ridge (coumadin ridge) and possible clinical implications for cardiovascular imaging and invasive procedures. *J Cardiovasc Electrophysiol.* 2019; 31: 220-226.
- 17 Hołda MK, Koziej K, Hołda J, et al. Anatomic characteristics of the mitral isthmus region: the left atrial appendage isthmus as a possible ablation target. *Ann Anat.* 2017; 210: 103-111.
- 18 Su W, Kowal R, Kowalski M, et al. Best practice guide for cryoballoon ablation in atrial fibrillation: the compilation experience of more than 3000 procedures. *Hear Rhythm.* 2015; 12: 1658-1666.
- 19 Pappone C, Rosanio S, Oreto G, et al. Circumferential radiofrequency ablation of pulmonary vein ostia: a new anatomic approach for curing atrial fibrillation. *Circulation.* 2000; 102: 2619-2628.
- 20 Hwang C, Fishbein MC, Chen PS. How and when to ablate the ligament of Marshall. *Hear Rhythm.* 2006; 3: 1505-1507.
- 21 Dave AS, Báez-Escudero JL, Sasaridis C, et al. Role of the vein of Marshall in atrial fibrillation recurrences after catheter ablation: Therapeutic effect of ethanol infusion. *J Cardiovasc Electrophysiol.* 2012; 23: 583-591.

- 22 Holda MK, Koziej M, Holda J, et al. Spatial relationship of blood vessels within the mitral isthmus line. *Europace*. 2017; 20: 706-711.
- 23 Blendea D, Shah RV, Auricchio A, et al. Variability of coronary venous anatomy in patients undergoing cardiac resynchronization therapy: a high-speed rotational venography study. *Hear Rhythm*. 2007; 4: 1155-1162.
- 24 Żabówka A, Hołda J, Strona M, et al. Morphology of the Vieussens valve and its imaging in cardiac multislice computed tomography. *J Cardiovasc Electrophysiol*. 2019; 30: 1325-1329.
- 25 Młynarski R, Młynarska A, Gołba KS, Sosnowski M. Three-dimensional visualisation of coronary sinus ostium from the inside right atrium perspective. *Kardiol Pol*. 2018; 76: 536-541.
- 26 Kosztin A, Boros AM, Geller L, Merkely B. Cardiac resynchronisation therapy: current benefits and pitfalls. *Kardiol Pol*. 2018; 76: 1420-1425.
- 27 Chen YA, Nguyen ET, Dennie C, et al. Computed tomography and magnetic resonance imaging of the coronary sinus: anatomic variants and congenital anomalies. *insights imaging*. 2014; 5: 547-557.
- 28 Sun C, Pan Y, Wang H, et al. Assessment of the coronary venous system using 256-slice computed tomography. *PLoS One*. 2014; 9: e104246.
- 29 Młynarski R, Młynarska A, Gołba KS, Sosnowski M. Visualisation of the oblique vein of the left atrium (vein of Marshall) using cardiac computed tomography: Is the game worth the candle? *Kardiol Pol*. 2018; 76: 1344-1349.
- 30 Hołda MK, Klimek-Piotrowska W, Koziej M, et al. Influence of different fixation protocols on the preservation and dimensions of cardiac tissue. *J Anat*. 2016; 229: 334-340.
- 31 Hołda MK, Hołda J, Koziej M, et al. The influence of fixation on the cardiac tissue in a 1-year observation of swine hearts. *Anat Histol Embryol*. 2018; 47: 501-509.