



## Short communication

# Management of cerebral azole-resistant *Aspergillus fumigatus* infection: A role for intraventricular liposomal-amphotericin B

A.F.A.D. Schauwvlieghe<sup>a,\*</sup>, R.G.M. Bredius<sup>b</sup>, R.M. Verdijk<sup>c</sup>, F.J.W. Smiers<sup>b</sup>,  
M.T. van der Beek<sup>d</sup>, B.F. Goemans<sup>e</sup>, C.M. Zwaan<sup>e,f</sup>, R.J. Brüggemann<sup>g,h</sup>, B.J.A. Rijnders<sup>a</sup>

<sup>a</sup> Department of Internal Medicine, Section of Infectious Diseases, Erasmus University Medical Center, Rotterdam, Netherlands

<sup>b</sup> Department of Paediatric Immunology, Section of Infections, Haematology, and Stem Cell Transplantation, Willem-Alexander Children's Hospital, Leiden University Medical Center, Leiden, Netherlands

<sup>c</sup> Department of Pathology, Erasmus Medical Center, Rotterdam, Netherlands

<sup>d</sup> Department of Medical Microbiology, Leiden University Medical Center, Leiden, Netherlands

<sup>e</sup> Department of Haemato-oncology, Princess Máxima Centre for Paediatric Oncology, Utrecht, Netherlands

<sup>f</sup> Department of Paediatric Oncology/Haematology, Erasmus MC-Sophia Children's Hospital, Rotterdam, Netherlands

<sup>g</sup> Department of Pharmacy, Radboud Institute of Health Science, Radboud University Medical Center, Nijmegen, Netherlands

<sup>h</sup> Center of Expertise in Mycology, Radboudumc, Nijmegen, Netherlands



## ARTICLE INFO

## Article history:

Received 16 December 2019

Received in revised form 17 February 2020

Accepted 20 March 2020

Available online 3 April 2020

## Keywords:

Cerebral aspergillosis

Azole resistance

Liposomal-amphotericin B

Intraventricular

*Aspergillus fumigatus*

## ABSTRACT

**Objectives:** In the pre-azole era, central nervous system (CNS) infections with *Aspergillus* had a dismal outcome. Survival improved with voriconazole but CNS infections caused by azole-resistant *Aspergillus fumigatus* preclude its use. Intravenous liposomal-amphotericin B (L-AmB) is the preferred treatment option for azole-resistant CNS infections but has suboptimal brain concentrations.

**Methods:** We describe three patients with biopsy-proven CNS aspergillosis where intraventricular L-AmB was added to systemic therapy. Two patients with azole-resistant aspergillosis and one patient with azole-susceptible CNS aspergillosis were treated with intraventricular L-AmB at a dose of 1 mg weekly. **Results:** We describe three patients successfully treated with a combination of intravenous and intraventricular L-AmB. All three patients survived but one patient developed serious headaches, most likely not related to this treatment.

**Conclusions:** Intraventricular L-AmB may have a role in the treatment of therapy-refractory CNS aspergillosis when added to systemic therapy.

© 2020 The Author(s). Published by Elsevier Ltd on behalf of International Society for Antimicrobial Chemotherapy. This is an open access article under the CC BY-NC-ND license (<http://creativecommons.org/licenses/by-nc-nd/4.0/>).

## 1. Introduction

Few cases of central nervous system (CNS) aspergillosis caused by azole-resistant *Aspergillus fumigatus* (ARAF) have been reported, and almost all of those reported had a fatal outcome [1]. Most patients were treated with combination antifungal therapy. Cerebral infections caused by ARAF almost always have a dismal prognosis. Unfortunately, there are no antifungals available that have activity against ARAF and adequately penetrate the brain.

Therefore, we added intraventricular liposomal-amphotericin B (L-AmB) to systemic therapy in three patients. In this study, we describe these patients and our clinical experience. All patients provided informed consent.

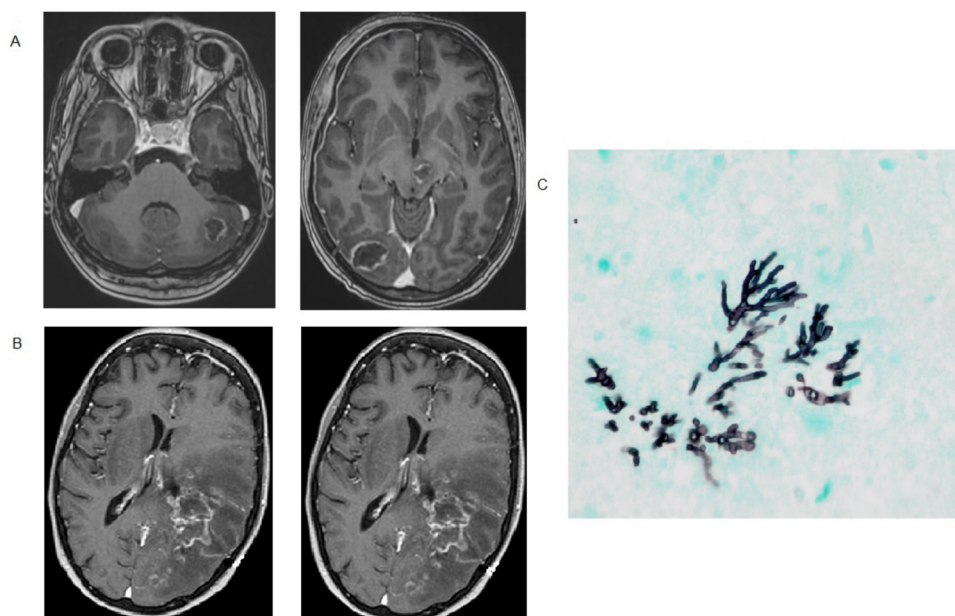
## 2. Case presentation

## 2.1. Case 1

An 18-year-old woman with common acute lymphatic leukaemia (ALL) receiving remission induction chemotherapy was diagnosed with a probable invasive pulmonary aspergillosis (IPA). Combination therapy with intravenous (i.v.) voriconazole and L-AmB (3 mg/kg QD) was started. Serum galactomannan was positive (Optical Density [OD] 2.8) and sputum grew an ARAF with

\* Corresponding author at: Department of Internal Medicine, Section of Infectious Diseases, Erasmus University Medical Center, Room Na-21, P.O. Box 2040, 3000 CA Rotterdam, Netherlands.

E-mail address: [a.schauwvlieghe@erasmusmc.nl](mailto:a.schauwvlieghe@erasmusmc.nl) (A.F.A.D. Schauwvlieghe).



**Fig. 1.** MRI showing multiple nodular lesions. (A) Patient 1. (B) Patient 2. (C) Brain biopsy shows septated hyphae with dichotomous branching at sharp angles using a Gomori methenamine silver stain.

the *CYP51A* TR<sub>34</sub>/L98H mutation. At 8 days on therapy, paresis of the right arm and leg and right facial nerve paralysis were observed. Brain MRI showed multiple lesions (Fig. 1A) and a brain biopsy demonstrated hyphae compatible with *Aspergillus* (Fig. 1C). L-AmB dose was increased to 10 mg/kg and voriconazole (8 mg/kg BID) was replaced by posaconazole and dosed at 300 mg BID to achieve serum trough concentrations >3 mg/L with the hope of achieving therapeutic brain tissue levels. Posaconazole trough concentrations of 5.2 and 6.0 mg/L were documented. Follow-up MRI 15 days after the initiation of therapy showed increased perilesional oedema. During the following 5 months the patient was treated with oral posaconazole 300 mg BID with i.v. L-AmB daily at 5 mg/kg. Six months after diagnosis posaconazole was stopped as cerebral lesions and perilesional oedema had decreased and the arm and leg paresis and facial nerve palsy had improved. Chemotherapy was reinitiated and another 3 months later L-AmB was discontinued. At that time the lesions on brain MRI had decreased in size but had not disappeared completely. Unfortunately, 6 months later the patient was admitted for an epileptic seizure. MRI showed increase in size and oedema around one of the seven lesions. Combination treatment with i.v. L-AmB (5 mg/kg QD) and posaconazole (300 mg BID) was reinitiated and was combined with intraventricular weekly administration of L-AmB (1 mg/week). The patient was discharged with outpatient therapy with i.v. L-AmB, oral posaconazole and once-weekly intraventricular L-AmB using an Ommaya reservoir that was placed for this purpose. The intraventricular L-AmB therapy was well tolerated and continued for 4 months. The MRI remained essentially unchanged in these 4 months. The patient was able to walk and cycle independently but has unilateral hand motor dysfunction as the only sequela.

## 2.2. Case 2

A 13-year-old patient with iron overload as a result of multiple transfusions for beta-thalassaemia was diagnosed with a probable invasive pulmonary and multifocal cerebral aspergillosis 8 months after allogeneic stem cell transplantation (Fig. 1B). An ARAF was cultured from bronchoalveolar lavage (BAL) fluid. Galactomannan in cerebrospinal fluid (CSF) was positive (OD 1.3). Voriconazole

(8 mg/kg BID i.v.) and L-AmB (6 mg/kg) were started. Ten days later an epileptic seizure occurred. MRI showed increased size of the brain lesions and again an ARAF grew from a brain biopsy (Table 1). An Ommaya reservoir was placed for the intraventricular administration of L-AmB as well as caspofungin (for details on dosing see Table 1). Also, i.v. caspofungin (70 mg QD) and flucytosine (25 mg/kg QID) were initiated. With this intervention, the patient improved and lesions decreased in size. Weekly intraventricular administration of L-AmB was continued for 10 weeks and intraventricular caspofungin was continued for 6 months. Systemic therapy with flucytosine, L-AmB and caspofungin was discontinued after 2, 6 and 6 months, respectively. No further improvement of the remaining brain lesions was observed after 6 months.

Several years later the patient developed disabling headache. On imaging the skull and dura mater diameter had thickened significantly. A dura biopsy did not lead to a conclusive diagnosis. At the last follow-up 9 years post-allogeneic transplant the complaints of severe headaches had disappeared but spasticity, occasional epileptic seizures and frontal lobe syndrome had led to severe disability.

## 2.3. Case 3

A 15-year-old girl with common ALL developed aphasia 23 days after chemotherapy initiation. MRI showed one lesion in the left frontal lobe and one lesion in the temporal lobe. A chest computed tomography (CT) showed nodular lesions. BAL sampling was performed. Galactomannan (OD 4.5) was positive and voriconazole-susceptible *A. fumigatus* was cultured (voriconazole MIC 0.5 mg/L). Treatment with voriconazole (4 mg/kg) and L-AmB (5 mg/kg) was initiated and L-AmB stopped on day 16 when voriconazole drug levels were therapeutic. Despite voriconazole serum levels between 3 and 12 mg/L, a follow-up MRI 3 weeks into therapy showed that lesions had increased in size. L-AmB i.v. was reinitiated and weekly intraventricular administration of L-AmB 1 mg was started via a Rickham reservoir while voriconazole was continued also. Follow-up brain MRIs and lung CT at 1 and 2 months into this therapy showed a decrease in the size of the brain lesions and no increase in lung lesions. A lung biopsy confirmed an

**Table 1**  
Clinical and epidemiological characteristics of patients with cerebral azole-resistant invasive aspergillosis.

Factors	Patient 1	Patient 2	Patient 3
Sex, age	F, 18	F, 16	F, 15
Underlying disease	ALL	Thalassaemia, allogeneic SCT	ALL
Classification IPA (EORTC/MSG)	Biopsy proven	Biopsy proven	Biopsy proven (brain and lung)
Culture positive sample	Sputum, brain biopsy	BAL, brain biopsy	BAL
MIC voriconazole	8	16	0.5
MIC posaconazole	2	0.5	0.063
MIC itraconazole	>16	16	0.25
MIC isavuconazole	–	–	0.5
GM value blood	1.3	0.9	0.4
GM value CSF	0.5	1.30	0.5
GM value BAL	2.8	0.36	4.5
Biopsy brain	Positive	Positive	Positive
Treatment regimen (day after diagnosis)	1. Voriconazole + L-AmB i.v. (3 mg/kg) (d0–d5) 2. Posaconazole + L-AmB i.v. (10 mg/kg) (d5–d26) 3. Posaconazole + L-AmB i.v. (3 mg/kg) + IT L-AmB <sup>a</sup> (d26–d191) 4. L-AmB 5 mg/kg 3×/week (d191–d251) 5. Treatment re-initiation L-AmB i.v. + IT <sup>a</sup> (d386–d515)	1. L-AmB i.v. + voriconazole (6 mg/kg) (d0–d10) 2. L-AmB i.v. + caspofungin i.v. (d10–d13) 3. L-AmB i.v. + caspofungin i.v./IT <sup>b</sup> (d13–d24) 4. L-AmB i.v. and IT <sup>a</sup> + caspofungin i.v. and IT <sup>b</sup> (d24–d32) 5. L-AmB i.v. and IT <sup>a</sup> + caspofungin i.v. and IT <sup>b</sup> + flucytosine i.v. (d32–d97) 6. L-AmB i.v. + caspofungin i.v. and IT <sup>b</sup> + flucytosine i.v. (d97–d201)	1. Voriconazole + L-AmB i.v. (d0–d10) 2. Voriconazole (d11–d20) 3. Voriconazole + L-AmB 3 mg/kg i.v./weekly IT (d21–d109) 4. Voriconazole (d110–d149) 5. Voriconazole + L-AmB 3 mg/kg i.v./weekly IT <sup>a</sup> (d149–d176) 6. Isavuconazole + L-AmB 3 mg/kg i.v. and weekly IT (d176–d227) 7. Isavuconazole + L-AmB weekly IT <sup>a</sup> (d228–d348) 8. Isavuconazole (d349–XXX)

<sup>a</sup> Intraventricular/intrathecal L-AmB was given at a dose of 1 mg weekly.

<sup>b</sup> Caspofungin IT 1 mg QD for 2 weeks, 1 mg 3×/week for 1 month and 3×/week 0.5 mg thereafter. ALL, acute lymphatic leukaemia; BAL, bronchoalveolar lavage; CSF, cerebrospinal fluid; EORTC/MSG, European Organization for Research and Treatment of Cancer/Invasive Fungal Infections Cooperative Group and the National Institute of Allergy and Infectious Diseases Mycoses Study Group (EORTC/MSG) host factor; F, female; IPA, invasive pulmonary aspergillosis; IT, intrathecal/intraventricular; i.v., intravenous; L-AmB, liposomal amphotericin B; MIC, minimum inhibitory concentration; GM, galactomannan; SCT, stem cell transplantation.

invasive aspergillosis infection. Eventually, without a change in therapy all infections sites improved, as well as the neurological disabilities of the patient. After 3 months of combination therapy, a step-down to voriconazole monotherapy was made. During the following 6 weeks voriconazole levels were suboptimal (range 0.3–2.6 mg/L) and unfortunately, 6 weeks later dysarthria developed and an MRI showed that the lesions had increased in size. A brain biopsy confirmed the *Aspergillus* infection of the brain and i.v. and intraventricular L-AmB was reinitiated. Administration of i.v. L-AmB was stopped after 2 months but intraventricular continued for 8 months, whereas voriconazole was switched to isavuconazole for liver enzyme elevations. Eventually, follow-up imaging of the lungs and brain showed a good response to therapy. The patient is doing well and has been successfully treated for ALL. During ALL therapy, the patient received isavuconazole as secondary antifungal prophylaxis.

### 3. Discussion

We describe two cases of ARAF and one case with azole-susceptible CNS aspergillosis treated with intraventricular L-AmB. Brain infections with *Aspergillus* have a high mortality and survivors are left with at least some neurological deficit [2]. Although voriconazole improved the chances of survival, ARAF now turns back the clock to the amphotericin-B era.

Over the last 10 years, azole resistance has become an important emerging problem and is associated with very high mortality [3–6]. When voriconazole resistance is documented in a patient infected with a cerebral *Aspergillus* infection, treatment becomes very difficult. Indeed, few other systemic antifungal agents have been shown to penetrate the brain. Furthermore, the therapeutic effect of new drugs is still unknown [7,8]. Pharmacokinetic and pharmacodynamic animal data suggest that compared with other formulations of amphotericin-B, L-AmB results in the highest brain tissue concentrations of amphotericin-B and it was

effective as therapy in a mouse model of candida encephalitis [9]. Therefore, it is regarded as the preferred second-line therapy for cerebral fungal infections but should, at least initially, be dosed at 5–10 mg/kg to achieve therapeutic brain tissue concentrations quickly [1,10]. For azole-resistant CNS infection, L-AmB can be combined with a second drug but itraconazole, posaconazole and echinocandins do not lead to adequate drug concentrations in CSF or brain tissue with standard dosing regimens [1]. Furthermore, it seems that combination therapy does not lead to synergistic treatment effect in vitro against ARAF isolates [11]. To improve CSF and brain penetration, higher systemic exposure may be aimed for to subsequently reach higher CSF and brain concentrations that can exert a pharmacological effect even in the setting where pathogen susceptibility is reduced. Furthermore, a damaged blood–brain barrier, which is present in patients with an angio-invasive *Aspergillus* infection will likely improve the penetration of selected drugs. With this in mind, we combined posaconazole with L-AmB in the first case [12]. Ultimately, we decided to administer L-AmB directly into the CSF space also. The administration was well tolerated with no subjective side effects. Contrary to the first and third case, we observed long-term complications in the second case. We argue that these side effects are probably the result of chronic inflammation and scarring during and after the infection rather than L-AmB or caspofungin-mediated toxicity although we cannot exclude with certainty the possibility that local combination of drug therapy contributed to these side effects.

Current guidelines do not recommend the use of intraventricular administration of antifungals owing to the risk of important adverse events (e.g. chemical meningitis and seizures) [13]. Historically, intrathecal/intraventricular administration of conventional AmB deoxycholate has been and is still being used to treat patients with coccidioidal meningitis. The side effects of intrathecal/intraventricular administration of AmB deoxycholate make it difficult to use and only low doses of typically 0.1 mg are used after which the dose is slowly increased up to 1.0 mg [14]. The reported

side effects of AmB deoxycholate led us to opt for intraventricular L-AmB instead. Based on a theoretical total CSF volume of ca. 100–150 mL in our patients, the administration of 1 mg of L-AmB would result in a peak CSF concentration of L-AmB of 10 µg/mL which is comparable to the peak plasma concentrations after systemic administration by Groll et al. [9]. Distribution kinetics as well as clearance mechanism were unknown so we had no knowledge on possible accumulation, hence we started with a presumed safe dose. In case 1 we tried to measure L-AmB in retrospect on residual CSF fluid but no L-AmB could be detected (limit of detection: 0.5 mg/L). In hindsight we argue that the clearance of L-AmB is much more rapid than initially expected. This is explained by the fact that 500 mL of CSF is produced and reabsorbed each day and helps with clearing L-AmB. Both the dose and frequency of once-weekly intraventricular administration of 1 mg L-AmB might thus be suboptimal and a higher dose as well as a more frequent administration may be preferred for future patients. Intrathecal/intraventricular L-AmB at a higher dose (10 mg per administration) for 7 consecutive days was shown to be well tolerated in 18 patients with cryptococcal meningitis [15]. Although the exact role of intrathecal/intraventricular L-AmB remains to be defined in patients with an *Aspergillus* infection of the CNS, we propose to initiate intrathecal/intraventricular L-AmB as soon as voriconazole resistance is documented at a dose of 5 mg and preferably twice weekly. If available, L-AmB CSF concentration monitoring may guide dosing after the first dose.

Finally, whether local therapy needs to be given in conjunction with systemic therapy is unknown. The benefit of combination therapy may be a more favourable ratio of plasma/brain concentrations and perhaps a longer detainment of adequate CSF/brain concentrations.

Case series like ours have several limitations. In particular, all three patients received systemic treatment also. Therefore, the exact contribution of the intraventricular L-AmB administration cannot be defined. However, it is very unlikely that prospective clinical studies will ever be performed to find the best possible treatment option for very rare infections like CNS aspergillosis. Therefore, treatment should be based on in vitro and animal data and eventually the experience described in case reports and case series can be helpful as well.

In conclusion, three patients with a CNS infection with *A. fumigatus* were treated with combination antifungal therapy that included intraventricular L-AmB. All three survived but one patient was left with severe sequelae.

## Funding

This study was performed as part of our routine work.

## Competing interests

A.F.A.D. Schauwvlieghe has received travel grants from Abvie, Amgen, Roche and Gilead to attend international conferences not related to this manuscript. B.J.A. Rijnders received research grants from Gilead and MSD outside the context of this study. He also received travel grants from MSD, Gilead, BMS, Jansen-Cilag and ViiV and received personal fees from Gilead, ViiV and Great-Lake

pharmaceuticals. He served as an advisor to Gilead, ViiV, BMS, Abbvie, Jansen-Cilag and MSD. R.J.B. Brüggemann has served as a consultant to and has received unrestricted and research grants from Astellas Pharma, Inc., F2G, Gilead Sciences, Merck Sharpe and Dohme Corp., and Pfizer, Inc. All contracts were through Radboudumc and payments were invoiced by Radboudumc. None of this work is related to this manuscript. All other authors have no competing interests to declare.

## Ethical approval

Not required.

## References

- [1] Verweij PE, Ananda-Rajah M, Andes D, Arendrup MC, Brüggemann RJ, Chowdhary A, et al. International expert opinion on the management of infection caused by azole-resistant *Aspergillus fumigatus*. *Drug Resist Updat* 2015;21–22:30–40.
- [2] Marzolf G, Sabou M, Lannes B, Cotton F, Meyronet D, Galanaud D, et al. Magnetic resonance imaging of cerebral aspergillosis: imaging and pathological correlations. *PLoS ONE* 2016;11:e0152475.
- [3] Chong GM, van der Beek MT, von dem Borne PA, Boelens J, Steel E, Kampinga GA, et al. PCR-based detection of *Aspergillus fumigatus* Cyp51A mutations on bronchoalveolar lavage: a multicentre validation of the AsperGenius assay(R) in 201 patients with haematological disease suspected for invasive aspergillosis. *J Antimicrob Chemother* 2016;71:3528–35.
- [4] van der Linden JW, Snelders E, Kampinga GA, Rijnders BJ, Mattsson E, Debets-Ossenkopp YJ, et al. Clinical implications of azole resistance in *Aspergillus fumigatus*, The Netherlands, 2007–2009. *Emerg Infect Dis* 2011;17:1846–54.
- [5] Lestrade PP, Bentvelsen RG, Schauwvlieghe A, Schalekamp S, van der Velden W, Kuiper EJ, et al. Voriconazole resistance and mortality in invasive aspergillosis: a multicenter retrospective cohort study. *Clin Infect Dis* 2019;68:1463–71.
- [6] Zoran T, Sartori B, Sappl L, Aigner M, Sanchez-Reus F, Rezusta A, et al. Azole-resistance in *Aspergillus terreus* and related species: an emerging problem or a rare phenomenon? *Front Microbiol* 2018;9:516.
- [7] Abastabar M, Rahimi N, Meis JF, Aslani N, Khodavaisy S, Nabili M, et al. Potent activities of novel imidazoles lanocnazole and luliconazole against a collection of azole-resistant and -susceptible *Aspergillus fumigatus* strains. *Antimicrob Agents Chemother* 2016;60:6916.
- [8] Buil JB, Rijs A, Meis JF, Birch M, Law D, Melchers VJG, et al. In vitro activity of the novel antifungal compound F901318 against difficult-to-treat *Aspergillus* isolates. *J Antimicrob Chemother* 2017;72:2548–52.
- [9] Groll AH, Giri N, Petraitis V, Petraitiene R, Candelario M, Bacher JS, et al. Comparative efficacy and distribution of lipid formulations of amphotericin B in experimental *Candida albicans* infection of the central nervous system. *J Infect Dis* 2000;182:274–82.
- [10] Groll AH, Rijnders BJA, Walsh TJ, Adler-Moore J, Lewis RE, Brüggemann RJM. Clinical pharmacokinetics, pharmacodynamics, safety and efficacy of liposomal amphotericin B. *Arch Clin Infect Dis* 2019;68:S260–74.
- [11] Fakhim H, Vaezi A, Dannaoui E, Sharma C, Mousavi B, Chowdhary A, et al. In vitro combination of voriconazole with micafungin against azole-resistant clinical isolates of *Aspergillus fumigatus* from different geographical regions. *Diagn Microbiol Infect Dis* 2018;91:266–8.
- [12] Seyedmousavi S, Mouton JW, Melchers VJG, Brüggemann RJM, Verweij PE. The role of azoles in the management of azole-resistant aspergillosis: from the bench to the bedside. *Drug Resist Updat* 2014;17:37–50.
- [13] Patterson TF, Thompson 3rd GR, Denning DW, Fishman JA, Hadley S, Herbrecht R, et al. Practice guidelines for the diagnosis and management of aspergillosis: 2016 update by The Infectious Diseases Society of America. *Arch Clin Infect Dis* 2016;63:e1–e60.
- [14] Ho J, Fowler P, Heidari A, Johnson RH. Intrathecal amphotericin B: a 60-year experience in treating coccidioidal meningitis. *Arch Clin Infect Dis* 2017;64:519–24.
- [15] Alvarez-Uria G, Midde M, Battula J, Pujari HNB. Safety and tolerability of intrathecal liposomal amphotericin B (AmBisome) for cryptococcal meningitis: a retrospective study in HIV-infected patients. *Ther Adv Infect Dis* 2018;5:77–81.