

## Plexiform Neurofibroma Without Neurofibromatosis Type 1

Dear Editor,

Plexiform neurofibroma (PNF) is a particular subtype of benign nerve sheath tumors with a reticular growth pattern not respecting tissue borders and involving several nerve branches or fascicles. It is most commonly reported in patients with neurofibromatosis type-1 (NF-1) and represents in up to 30% of NF-1 patients (1,2). Other possible associations include schwannomatosis, multiple cutaneous schwannomas syndrome, and rarely neurofibromatosis type-2 (NF-2) (3).

PNF develops as a result of tumor proliferation to all parts of the peripheral nervous system. It may

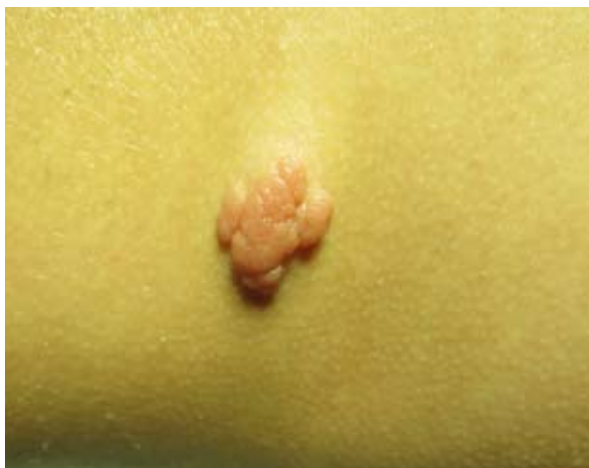cause functional and cosmetic impairment, pain, and a certain risk of malignant transformation in internal organs in some critical cases (4,5). Malignant peripheral nerve sheath tumors occur in about 10% of NF-1 patients (4,5). NF-1 is caused by mutations in the NF-1 tumor-suppressor gene, which encodes a GTPase-Activating Protein (GAP) that negatively regulates p21-RasNF1 (6). These patients have a predisposition to develop both benign and malignant tumors (6).

Isolated or NF-1-associated cutaneous or superficial PNF, however, do not transform into their malignant counterpart (1).

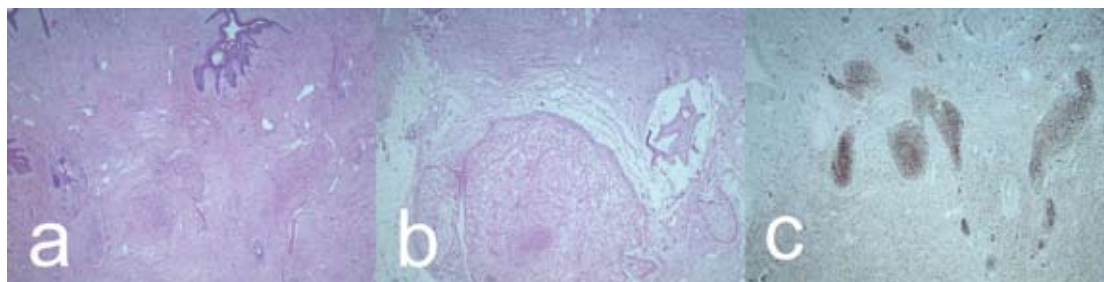
We report an isolated case of a plexiform PNF in a 16-year-old girl without NF-1.

A 16-year-old Caucasian woman presented with a slow-growing exophytic nodule on her right flank. The tumor was asymptomatic, and tumor removal was requested for esthetic reasons. The patient was otherwise healthy. Her family history was negative for hereditary disorders. She was taking no medications at the time.

On examination, a 1.8×1.6 cm large, slow-growing, and asymptomatic exophytic asymptomatic tumor was observed on the right flank (Figure 1). The primary suspicion was a complex nevus tumor type such as nevus sebaceous or nevus lipomatosus. The tumor was surgically removed, and the defect was closed by tissue expansion. Histology revealed a spindle-cell proliferation of S-100 positive cells without cellular



**Figure 1.** Nodular mass of an isolated plexiform neurofibroma on the flank.



**Figure 2.** Histopathology of an isolated plexiform neurofibroma; (a, b) hematoxylin and eosin (×2); (c) S100-staining (×2).

atypia and myxoid stroma (Figure 2). The diagnosis of PNF was thus established. Healing was uneventful. There were no clinical signs of NF-1 or NF-2.

We reported a case of PNF without NF-1 or NF-2. The diagnosis of an isolated PNF is a very rare event (7-10). In a large study from Lima lasting 33 years, only one isolated PNF not associated with NF-1 was observed. In this patient, PNF developed in the oral mucosa (7). An isolated PNF causing an auricular deformity has been previously observed in a 14-year-old boy (8). In India, a 11-year-old girl with an isolated PNF of the tongue was reported (9). Isolated PNFs are not necessarily limited to children and adolescents but may also occur later in life (10).

The gold standard of treatment is surgical intervention. In case of unresectable and painful tumors, interferon alfa is a medical option (11). Other drugs are under evaluation, such as oral selumetinib, a selective inhibitor of MAPK kinase 1 and 2, AZD8055, an ATP-competitive "active-site" mTOR inhibitor, or a BromoDomain-containing protein 4-inhibitor (12,13).

In conclusion, isolated PNF is a very rare observation. In case of impairment, surgery – whenever possible – is the preferred treatment option (8).

### References:

1. Ferner E, Gutmann DH. International consensus statement on malignant peripheral nerve sheath tumors in neurofibromatosis 1. *Cancer Res.* 2002;62:1573-7.
2. Tchernev G, Chokoeva AA, Patterson JW, Bakardzhiev I, Wollina U, Tana C. Plexiform neurofibroma: a case report. *Medicine (Baltimore).* 2016;95:e2663.
3. Val-Bernal JF, Figols J, Vázquez-Barquero A. Cutaneous plexiform schwannoma associated with neurofibromatosis type 2. *Cancer.* 1995;76:1181-6.
4. Azizi AA, Slavic I, Theisen BE, Rausch I, Weber M, Happak W, *et al.* Monitoring of plexiform neurofibroma in children and adolescents with neurofibromatosis type 1 by <sup>18F</sup>FDG-PET imaging. Is it of value in asymptomatic patients? *Pediatr Blood Cancer.* 2018;65:doi: 10.1002/pbc.26733.
5. Tovmassian D, Abdul Razak M, London K. The role of <sup>18F</sup>FDG-PET/CT in predicting malignant transformation of plexiform neurofibromas in neurofibromatosis-1. *Int J Surg Oncol.* 2016;2016:6162182.
6. Abreu Velez AM, Howard MS. Tumor-suppressor genes, cell cycle regulatory checkpoints, and the skin. *N Am J Med Sci.* 2015;7:176-88.
7. Marocchio LS, Oliveira DT, Pereira MC, Soares CT, Fleury RN. Sporadic and multiple neurofibromas in the head and neck region: a retrospective study of 33 years. *Clin Oral Investig.* 2007;11:165-69.
8. Khajavi M, Khoshsirafat S, Ahangarnazari L, Majdinasab N. A brief report of plexiform neurofibroma. *Curr Probl Cancer.* 2018;42:256-60.
9. Sharma A, Sengupta P, Das AK. Isolated plexiform neurofibroma of the tongue. *J Lab Physicians.* 2013;5:127-9.
10. Levy Bencheton A, Mallet S, Rojat Habib MC, Figarella-Branger D, Sigaudy S, Grob JJ, *et al.* Isolated late-onset plexiform neurofibroma in the absence of neurofibromatosis. *Ann Dermatol Venereol.* 2010;137:301-4.
11. Citak EC, Oguz A, Karadeniz C, Okur A, Memis L, Boyunaga O. Management of plexiform neurofibroma with interferon alpha. *Pediatr Hematol Oncol.* 2008;25:673-8.
12. Dombi E, Baldwin A, Marcus LJ, Fisher MJ, Weiss B, Kim A, *et al.* Activity of selumetinib in neurofibromatosis type 1-related plexiform neurofibromas. *N Engl J Med.* 2016;375:2550-60.
13. Varin J, Poulain L, Hivelin M, Nusbaum P, Hubas A, Laurendeau I, *et al.* Dual mTORC1/2 inhibition induces anti-proliferative effect in NF1-associated plexiform neurofibroma and malignant peripheral nerve sheath tumor cells. *Oncotarget.* 2016;7:35753-67.

**Uwe Wollina<sup>1</sup>, Jacqueline Schönlebe<sup>2</sup>**

<sup>1</sup>Department of Dermatology and Allergology, Städtisches Klinikum Dresden, Dresden, Germany

<sup>2</sup>Institute of Pathology "Georg Schmorl", Städtisches Klinikum Dresden, Dresden, Germany

### Corresponding author:

Professor Uwe Wollina, MD  
Department of Dermatology and Allergology  
Städtisches Klinikum Dresden  
Academic Teaching Hospital  
Friedrichstrasse 41  
01067 Dresden  
Germany  
[Uwe.Wollina@klinikum-dresden.de](mailto:Uwe.Wollina@klinikum-dresden.de)

Received: November 10, 2018

Accepted: November 16, 2020