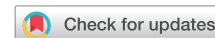

# Successful ablation of ventricular tachycardia in the presence of a novel self-expanding transcatheter mitral valve replacement



Anthony Li, MBBS, MD, Alexander Grimster, BSc, Magdi Saba, MD, FHRS

From the Cardiology Clinical Academic Group, St. George's University Hospitals NHS Trust, London, United Kingdom.

## Introduction

Catheter ablation is widely used for the control of ventricular tachycardia (VT) in structural heart disease. Patients in this group can be highly complex, with multiple comorbidities, and have often had prior cardiac surgery. Increasing numbers of these patients are now being treated with percutaneous options for valve replacement/repair. As such, we are seeing patients referred with these devices to our arrhythmia services who require catheter ablation. We present the first reported case of VT ablation in the presence of the Tendyne mitral valve prosthesis (Abbott, Santa Clara, CA).

## Case report

A 77-year-old man with ischemic cardiomyopathy underwent VT ablation with the Tendyne mitral valve device in situ. The patient had a past history of coronary artery bypass grafting in 2001, followed by an inferior myocardial infarction in 2013, after which a primary prevention cardiac resynchronization therapy defibrillator was implanted. A successful endocardial VT ablation was undertaken in 2014 following recurrent monomorphic VT requiring shock therapy, and he remained free of VT for a total of 5 years. However, worsening heart failure ensued owing to severe mitral regurgitation and, after surgical turn-down, he was referred for the Tendyne mitral valve implant in 2018. Recurrence of VT requiring frequent shocks occurred in late 2019, after which he was placed on amiodarone. The patient then suffered VT storm in early 2020 requiring control with mexiletene but with breakthrough owing to slow VT, and therefore VT ablation was planned.

**KEYWORDS** Ventricular tachycardia; Ablation; Percutaneous mitral valve; Tendyne valve; Intracardiac echocardiography (Heart Rhythm Case Reports 2021;7:131–133)

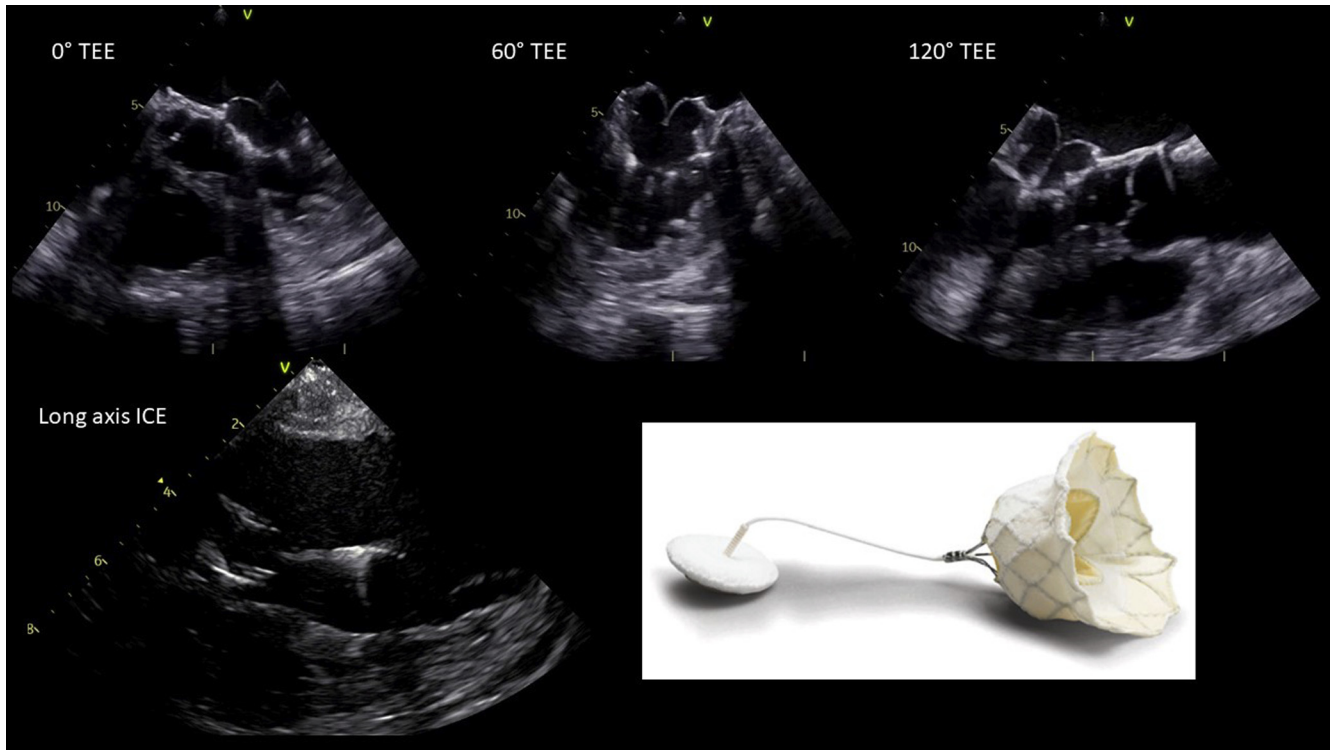
**Conflicts of Interest:** This research did not receive any specific grant from funding agencies in the public, commercial, or not-for-profit sectors. The authors have no conflicts of interests to declare. **Address reprint requests and correspondence:** Dr Anthony Li, Cardiology Clinical Academic Group, St. George's University Hospitals NHS Trust, Blackshaw Road, London SW17 0QT, UK. E-mail address: [ali@sgul.ac.uk](mailto:ali@sgul.ac.uk).

## KEY TEACHING POINTS

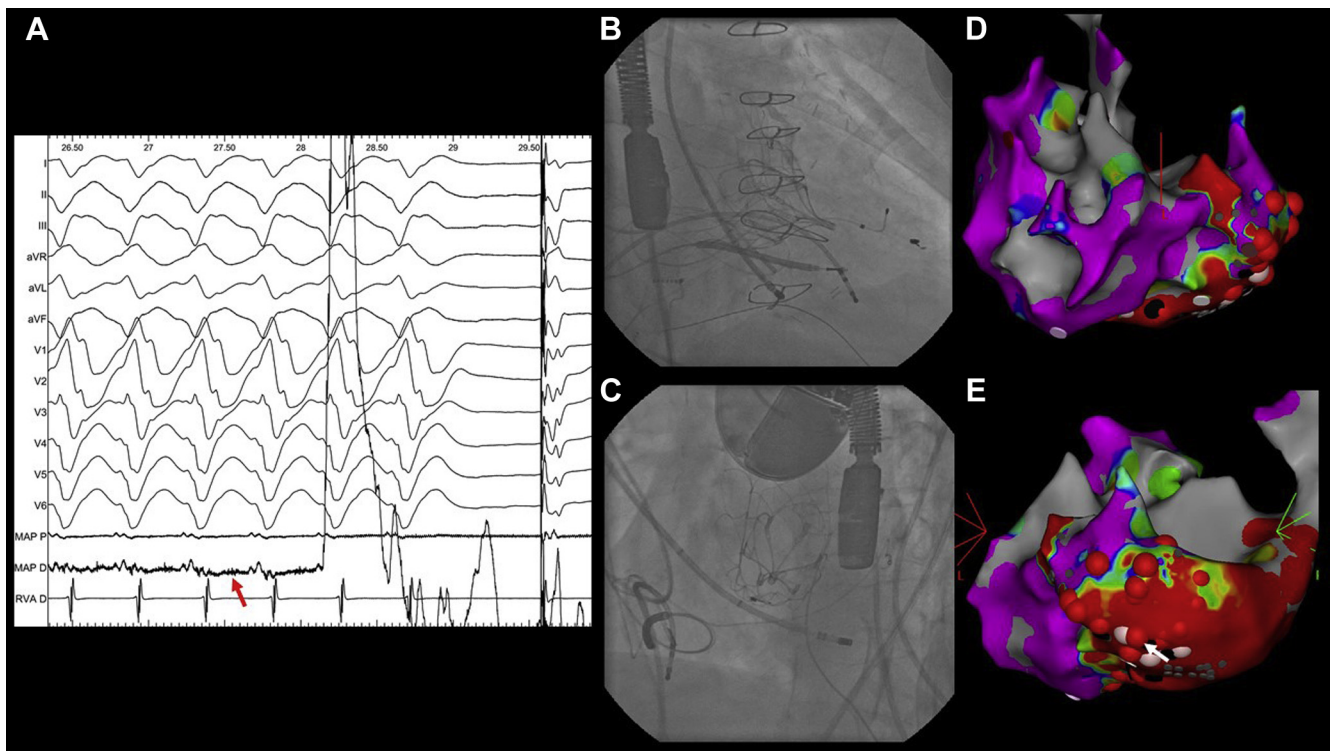
- Catheter ablation in the presence of a Tendyne mitral valve prosthesis (Abbott, Santa Clara, CA) is feasible.
- Exclusive retrograde aortic access is strongly advised.
- Limited access to the basal–mid anterolateral left ventricle should be anticipated.
- Fluoroscopy and intracardiac echocardiography should be used to simultaneously view the valve struts and the valve tether intraprocedurally.

**Figure 1** shows the ultrasound and ex vivo appearances of the Tendyne device. **Figure 2** shows intraprocedural data during VT mapping and ablation.

Ablation was undertaken with general anesthesia. Three-dimensional electroanatomical mapping was undertaken with intracardiac echocardiographic (ICE) guidance under full heparinization. Owing to the presence of a dense network of valve struts, we considered the transmitral route contraindicated, so left ventricular access was exclusively via the retrograde aortic route. Mapping was performed via a single bidirectional ablation catheter, as we were concerned that multi-spline mapping catheters may become entangled. Voltage mapping identified a discrete inferolateral scar. However, it was apparent that access to the basal to mid anterior and anterolateral segments was severely restricted through the aortic route, mainly owing to the presence of the valve struts, the total diameter of which appeared to occupy a significant proportion of the periannular area and extending further apically past the annular plane. The tether could be negotiated readily under ICE guidance. Mapping was carefully undertaken with fluoroscopy, which enabled visualization of the individual valve struts but not the tether, and ICE, which was able to visualize the tether but not the detail of the struts. A



**Figure 1** The top row of images show the Tendyne device (Abbott, Santa Clara, CA) during transesophageal echocardiography (TEE) at 0°, 60°, and 120° probe angulation. The bottom left panel shows a long-axis intracardiac echocardiographic (ICE) image of the device, valve struts, and tethering anchor. The bottom right panel shows an ex vivo image of the Tendyne device.



**Figure 2** **A:** Ventricular tachycardia (VT) termination during ablation with mid-diastolic potential (red arrow) (gained up distal bipole). **B, C:** The intraprocedural appearance of the device from orthogonal fluoroscopic views with the ablation catheter at the site of VT termination. **D, E:** A steep left anterior oblique and posteroanterior view, respectively, of the electroanatomical substrate map with voltage settings 0.5–1.5 mV acquired during the ablation procedure; ablation lesion set shown with termination point (white arrow).

hemodynamically stable VT was induced with programmed stimulation and activation mapped to the mid lateral border of the inferior scar, where entrainment with concealed fusion was obtained, and ablation led to clean termination. Thereafter, the patient remained noninducible, and further substrate modification was undertaken to the remainder of the scar to achieve abolition of late activity. Postprocedure imaging showed no change in mitral valve function. Mexiletene was stopped immediately post ablation and amiodarone was withdrawn at the 3-month clinic follow-up. There was no VT recurrence at 5 months follow-up.

## Discussion

The Tendyne device is a porcine trileaflet pericardial valve sutured to a self-expanding nitinol frame and is anchored with a polyethylene tether through the left ventricular apex and secured epicardially. Implantation occurs off-pump via a left minithoracotomy through a transapical approach and deployed through a 34F sheath, and the tension on the tether is adjusted according to optimal positioning. First-in-human implantation was reported in 2016 and the results of a global CE mark study from the first 100 patients have been published.<sup>1,2</sup>

This case demonstrates the challenges and need for simultaneous multimodality imaging for procedural guidance in

these complex patients. In our opinion, VT ablation should only be done via a retrograde aortic route and extreme difficulty in accessing the mid to basal anterior/anterolateral wall should be anticipated. However, the tether did not represent a major barrier to navigating with the ablation catheter. Owing to the limited access to the basal anterior/anterolateral left ventricular segments encountered during this procedure, catheter ablation may be considered in patients who have experienced VT with a secondary prevention device prior to implantation of a Tendyne device. It may also be advantageous, in this group of patients, to perform epicardial ablation at the same sitting as the implant procedure when epicardial access has been surgically obtained. This is of relevance in those with nonischemic etiologies when future percutaneous epicardial access attempts may be hindered by the formation of adhesions.<sup>3</sup>

## References

1. Quarto C, Davies S, Duncan A, et al. Transcatheter mitral valve implantation 30-day outcome of first-in-man experience with an apically tethered device. *Innovations (Phila)* 2016;11:174–178.
2. Sorajja P, Moat N, Badhwar V, et al. Initial feasibility study of a new transcatheter mitral prosthesis: The first 100 patients. *J Am Coll Cardiol* 2019;73:1250–1260.
3. Li A, Hayase J, Do D, et al. Hybrid surgical vs percutaneous access epicardial ventricular tachycardia ablation. *Heart Rhythm* 2018;15:512–519.