

Case Report

Successful Bronchoscopic Treatment for Postoperative Bronchopleural Fistula Using N-butyl-2-cyanoacrylate (NBCA): Report of a Post-completion Pneumonectomy Case with a History of Induction Chemoradiotherapy Followed by Bilobectomy for Advanced Lung Cancer

Toshio Shiotani^{a,b}, Hiromasa Yamamoto^{b*}, Riko Katsube^b, Yasuaki Tomioka^{a,b},
Ken Suzawa^b, Kentaroh Miyoshi^b, Shinji Otani^b, Mikio Okazaki^b,
Seiichiro Sugimoto^{a,b}, Junichi Soh^{b,c}, Masaomi Yamane^b, and Shinichi Toyooka^b

Departments of ^aOrgan Transplantation Center and ^bThoracic Surgery, Okayama University Hospital, Okayama 700-8558, Japan,
^cDepartment of Surgery, Division of Thoracic Surgery, Kindai University Faculty of Medicine, Osaka-Sayama 589-8511, Japan

Bronchopleural fistula (BPF) is a severe complication following lung resection. We present the case of a patient with a history of advanced lung cancer, who had undergone induction chemoradiotherapy followed by right middle and lower lobectomy, and who developed BPF after completion right pneumonectomy. Although we had covered the bronchial stump with an omental pedicled flap, BPF was found on postoperative day 19. We covered the fistula with n-butyl-2-cyanoacrylate (NBCA) using bronchoscopy. Although we had to repeat the NBCA treatment, we ultimately cured the patient's BPF and no recurrence was observed up to 15.2 months after surgery.

Key words: bronchopleural fistula, pneumonectomy, induction chemoradiotherapy, n-butyl-2-cyanoacrylate (NBCA), omental pedicled flap

Bronchopleural fistula (BPF) is a relatively rare but severe complication after lung resection [1-4] that carries a high rate of morbidity (0.8 to 28%) and mortality (18 to 50%). Thus, BPF is associated with prolonged hospital stay and high utilization of resources [3, 4]. The incidence of postoperative BPF is highest in patients who undergo right pneumonectomy or right lower lobectomy, and is reported to be from 4.5 to 20% after pulmonary resection [2-4]. Successful treatment of chronic BPF requires aggressive control of infection, adequate drainage of the chest cavity, closure of the fistula with vascularized tissue, and reduction of the dead space volume of the chest cavity [4]. Several treatment methods for postoperative BPF, including bron-

choscopic therapy, have been proposed [4-7]. However, guidelines and consensus for the treatment of BPF have yet to be established [4]. We experienced a case with a history of advanced lung cancer, who had undergone induction chemoradiotherapy followed by right middle and lower lobectomy. Our patient developed intractable BPF after completion right pneumonectomy, which we treated by repeatedly covering the fistula with n-butyl-2-cyanoacrylate (NBCA) using bronchoscopy.

Case Report

A 62-year-old male with right middle lobe lung cancer underwent right middle and lower lobectomy with

Received May 30, 2020; accepted September 14, 2020.

*Corresponding author. Phone: +81-86-235-7265; Fax: +81-86-235-7269
E-mail: h.yamamoto@md.okayama-u.ac.jp (H. Yamamoto)

Conflict of Interest Disclosures: No potential conflict of interest relevant to this article was reported.

lymph node dissection after induction chemoradiotherapy, the details of which were reported previously [8]. During this surgery, a bronchial stump was created at the level of the bronchus intermedius, and it was covered by pericardial fat. Two years after the operation, follow-up CT showed a tumorous lesion in the remnant right upper lobe of the lung. Cytological diagnosis using the lavage fluid from the computed tomography (CT)-guided biopsy needle indicated Class V lesions, though histological diagnosis by CT-guided biopsy found no evidence of malignancy. We decided to perform completion right pneumonectomy after discussing the therapeutic strategy with a multidisciplinary team. The bronchial stump formed at the level of the right main bronchus was covered with an omental pedicled flap to separate the stump from the superior vena cava and pulmonary artery. On postoperative day (POD) 19, hemoptysis was observed, and a chest X-ray and CT showed increased air space in the right thoracic cavity (Fig. 1, A and B). Bronchoscopy revealed 2 pinholes at the bronchial stump (Fig. 1C), resulting in a diagnosis of BPF after completion pneumonectomy. Intrathoracic drainage was performed and antibiotics and clotting

factor XIII were administered. On POD 21, we covered the pinholes with NBCA diluted with ethiodized oil to close the fistula. However, the BPF was intractable because NBCA is easily coughed up, and we had to repeat this procedure 5 times, the fifth time under the general anesthesia to inhibit coughing definitively. We brushed the pinholes to remove the ischemic bronchial epithelium and filled the fistula with NBCA (Fig. 2). Immediately following the procedure, follow-up CT showed that the NBCA remained in the bronchial fistula with no air leakage (Fig. 3A). On POD 85, the patient was discharged. No recurrence of BPF was observed at 15.2 months after surgery (Fig. 3B).

Discussion and Conclusion

In the present case, BPF after right completion pneumonectomy developed on POD 19. On POD 21, we started to treat the BPF following an endobronchial procedure using NBCA. Although we needed to perform the procedure five times to close the bronchial fistula, we were ultimately able to cure the BPF using NBCA without any surgical procedures. Several treat-

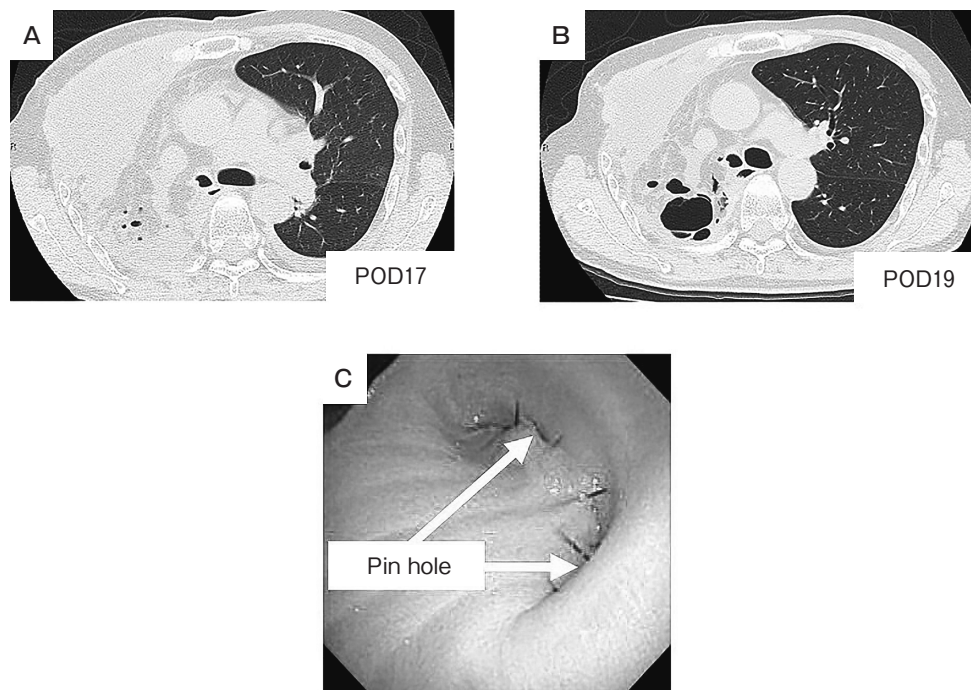


Fig. 1 Postoperative computed tomography (CT) scan of the chest. **(A)** Follow-up CT on postoperative day (POD) 17 showed no air leakage. **(B)** Follow-up CT on POD 19 revealed air leakage around the stump of the right main bronchus. **(C)** Postoperative bronchoscopic findings of the bronchial stump. Pinholes were found at both ends of the stump of the right main bronchus.




Fig. 2 Covering of the bronchopleural fistula with n-butyl-2-cyanoacrylate (NBCA) under bronchoscopy. (A) A pinhole was observed bronchoscopically at the bronchial stump in spite of repeated procedures. (B) We brushed the pinholes to encourage wound healing. (C) After brushing, we covered the bronchopleural fistula with NBCA under bronchoscopy.

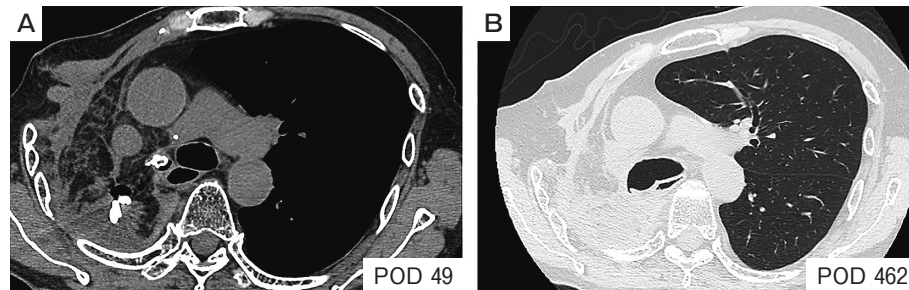


Fig. 3 Follow-up computed tomography (CT) scan of the chest on postoperative days (PODs) 49 and 462. (A) n-butyl-2-cyanoacrylate (NBCA) remained in the fistula at the bronchial stump. (B) CT imaging on POD 462 showed no air leakage or empyema, indicating that the bronchopleural fistula had been completely repaired with the NBCA cover.

ment methods using surgical or endobronchial techniques for postoperative BPF have been proposed, including omental pedicled flap, free pericardial fat pad, muscle flap, endobronchial Watanabe spigot (EWS), Amplatzer septal occluder, fibrin glue, and cyanoacrylate [1-7]. The appropriate treatment option is chosen based on the size of the fistula as well as the presence or absence of thoracic empyema [1, 4, 5, 9]. In Japan, the EWS is frequently used as an endobronchial occlusion material for treating peripheral BPF in cases in which the target bronchi are clearly identifiable [5]. In the present case, thoracic empyema had not developed at the time of the BPF diagnosis. Additionally, we judged that it would be difficult to close the bronchial fistula using an EWS or Amplatzer septal occluder because the fistulas were too small to insert them. Therefore, we chose NBCA to treat the BPF. NBCA is a butyl ester of 2-cyano-2-propenoic acid and it is the main component

of medical cyanoacrylate glue. It changes from monomer to polymer briefly, when it comes into contact with ionic substances like moisture, blood or tissue fluids. Its polymerized form has excellent tensile strength and can close surgical or wound incisions. In Japan, we usually use NBCA diluted with ethiodized oil as an embolization material, especially in the treatment for gastric varix, which is covered by insurance in Japan. There have been several reports describing the use of NBCA in the treatment of BPF under bronchoscopy [4-7], although this procedure is not covered by insurance in Japan. The Ethics Committee of Okayama University Hospital has approved the application of NBCA to BPF (Approval Number: 16).

Our case had 2 major risk factors for developing BPF. First, the patient underwent preoperative chemoradiotherapy, which adversely affects bronchial mucosal blood flow and healing of the bronchial stump due to

injury to the microvasculature [10]. Second, we performed a right completion pneumonectomy for this case. Guggino *et al.* report that BPF occurs in nearly 13% of cases of completion pneumonectomy, especially after right completion pneumonectomy compared with left-sided operations [11]. In the present case, the patient was not elderly and his pulmonary function and performance status after the first surgery were maintained. Thus, we performed the operation and we covered the bronchial stump with an omental pedicled flap to separate the stump from the superior vena cava and pulmonary artery, preventing critical bronchovascular fistula and filling part of the thoracic cavity in order to decrease dead space. We assume that the flap contributed to the success of the NBCA treatment because the NBCA remained at the bronchial fistula near the omental pedicled flap that covered the bronchial stump. NBCA mechanically occludes the fistula and induces a local inflammatory reaction causing proliferation of the bronchial mucosa [1]. This occlusion by NBCA was able to close the fistula permanently, and also to promote the wound healing through the induced local inflammatory reaction. Therefore, we were able to minimize empyema after BPF and complete the conservative therapy of covering the fistula several times with NBCA.

In conclusion, we successfully treated a patient who developed BPF after completion pneumonectomy and who had a history of induction chemoradiotherapy followed by bilobectomy for advanced lung cancer. Conservative treatment of the BPF with NBCA might be an effective treatment option if the fistula is small and empyema can be minimized.

References

1. Cardillo G, Carbone L, Carleo F, Galluccio G, Di Martino M, Giunti R, Lucantoni G, Battistoni P, Batzella S, Dello Iacono R, Petrella L and Dusmet M: The Rationale for Treatment of Postresectional Bronchopleural Fistula: Analysis of 52 Patients. *Ann Thorac Surg* (2015) 100: 251–257.
2. Cerfolio RJ: The incidence, etiology, and prevention of postresectional bronchopleural fistula. *Semin Thorac Cardiovasc Surg* (2001) 13: 3–7.
3. Hu XF, Duan L, Jiang GN, Wang H, Liu HC and Chen C: A clinical risk model for the evaluation of bronchopleural fistula in non-small cell lung cancer after pneumonectomy. *Ann Thorac Surg* (2013) 96: 419–424.
4. Lois M and Noppen M: Bronchopleural fistulas: an overview of the problem with special focus on endoscopic management. *Chest* (2005) 128: 3955–3965.
5. Yamamoto S, Sogabe M, Negishi H, Mitsuda S, Shibano T and Endo S: Successful treatment of post-operative peripheral bronchopleural fistulas using endobronchial Watanabe spigots. *Respirol Case Rep* (2020) 8: e00504.
6. Izumi N, Nagano K, Tei K, Hanada S, Komatsu H and Nishiyama N: Successful Bronchoscopic Closure of Bronchial Stump Fistula Using Cyanoacrylate. *Kikanshigaku (J Jpn Soc Respir Endoscopy)* (2013) 35: 56–59 (in Japanese).
7. Kaminuma Y, Tanahashi M, Suzuki E, Yoshii N and Niwa H: Extensive bronchial occlusion with N-butyl-2-cyanoacrylate for bronchopleural fistula and a destroyed lung. *Respirol Case Rep* (2020) 8: e00500.
8. Toyooka S, Kiura K, Takemoto M, Oto T, Takigawa N, Fujiwara T, Miyoshi S and Date H: Long-term outcome of induction chemoradiotherapy with docetaxel and cisplatin followed by surgery for non-small-cell lung cancer with mediastinal lymph node metastasis. *Interact Cardiovasc Thorac Surg* (2012) 14: 565–569.
9. Narita K, Iwanami H, Hiyoshi H, Tachibana M and Tsuboi M: A Case of Covering and Fixation with an Omental Pedicle for Widely Open Bronchopleural Fistula with Empyema. *Kikanshigaku (J Jpn Soc Respir Endoscopy)* (1998) 20: 523–526 (in Japanese).
10. Yamamoto R, Tada H, Kishi A and Tojo T: Effects of preoperative chemotherapy and radiation therapy on human bronchial blood flow. *J Thorac Cardiovasc Surg* (2000) 119: 939–945.
11. Guggino G, Doddoli C, Barlesi F, Acri P, Chetaille B, Thomas P, Giudicelli R and Fuentes P: Completion pneumonectomy in cancer patients: experience with 55 cases. *Eur J Cardiothorac Surg* (2004) 25: 449–455.