



Retropharyngeal hematoma presenting airway obstruction: A case report

Atsuyoshi Iida^{a,*}, Ayumi Nishida^b, Seiji Yoshitomi^c, Tsuyoshi Nojima^d, Hiromichi Naito^d, Atsunori Nakao^d

^a Department of Emergency Medicine, Okayama Red Cross Hospital, Okayama, Japan

^b Department of Neurosurgery, Okayama Red Cross Hospital, Okayama, Japan

^c Department of Breast and Endocrine Surgery, Okayama Red Cross Hospital, Okayama, Japan

^d Department of Emergency, Critical Care, and Disaster Medicine, Okayama University Graduate School of Medicine, Dentistry and Pharmaceutical Sciences, Japan

ARTICLE INFO

Article history:

Received 15 October 2020

Received in revised form 2 November 2020

Accepted 2 November 2020

Available online 4 November 2020

Keywords:

Airway management
Ascending cervical artery
Emergency tracheostomy
Thyrocervical trunk
Vascular embolization

ABSTRACT

INTRODUCTION: Blunt neck trauma patients can suffer from an airway emergency and are necessary to careful observation.

PRESENTATION OF CASE: A 79-year-old man under anticoagulation therapy presented to our hospital three hours after a fall. Shortly after arrival, he developed dyspnea. Oral intubation was attempted, but with no success; therefore, an emergency tracheotomy was performed. Contrast-enhanced computed tomography (CT) and subsequent angiography revealed active bleeding from a branch of the right ascending cervical artery. Subsequently, the right thyrocervical trunk, which is upstream from the ascending cervical artery, was embolized and hemostasis was achieved. He was discharged 52 days after the emergency admission.

DISCUSSION: This is the first case report of an ascending cervical artery injury due to blunt trauma that resulted in an airway emergency. Contrast-enhanced CT and cervical angiography are useful for confirming the area of injury and size of the hematoma. Half of patients with respiratory distress accompanied by a cervical spine injury require definitive airway management within five hours of the injury and all by 24 h. Neck trauma can lead to fatal airway obstruction and careful monitoring is warranted to detect any signs of impeding respiratory obstruction.

CONCLUSION: All emergency physicians need to keep their airway management skills updated in order to perform reliably and rapidly in difficult and urgent situations.

© 2020 The Authors. Published by Elsevier Ltd on behalf of IJS Publishing Group Ltd. This is an open access article under the CC BY-NC-ND license (<http://creativecommons.org/licenses/by-nc-nd/4.0/>).

1. Introduction

Retropharyngeal hematoma caused by minor trauma resulting in airway obstruction is extremely rare and difficult to identify; however, the condition is potentially life-threatening [1]. Development of a hematoma and onset of symptoms may occur late after an injury. Consequently, initial diagnostic radiographic tests results may be unexceptional. Management of dyspneic patients should include immediate airway stabilization since early symptoms may rapidly escalate to serious upper airway obstruction and death [2].

The case presented in this report is a rare, clinically important case of retropharyngeal hematoma causing severe respiratory distress during anticoagulant therapy leading to emergency invasive

airway management who was successfully treated with emergent transcatheter arterial embolization (TAE) for the bleeding vessels.

This report is a reminder to emergency physicians that a high level of care is required for trauma patients under anticoagulation treatment; potentially lethal complications, including airway compromise and spinal injury, are possible at all times and must be taken into consideration [3].

This work has been reported in line with the SCARE criteria [4].

2. Presentation of case

A 79-year-old man visited an outpatient clinic about 2 h after a fall from a height of 3.5 m with complaints of neck and back pain, but the clinic was incapable of treating trauma and was instructed to visit our hospital without any tests. Symptoms other than pain such as dyspnea had not yet appeared at that time, and he visited our hospital about 3 and a half hours after the injury in a private car driven by his family. The patient was taking warfarin 2.5 mg/day for

* Corresponding author at: Department of Emergency Medicine, Okayama Red Cross Hospital, 2-1-1 Aoe, Kita-ward, Okayama, 700-8607, Japan.

E-mail address: pp7h4al1@okayama-u.ac.jp (A. Iida).

<https://doi.org/10.1016/j.ijscr.2020.11.007>

2210-2612/© 2020 The Authors. Published by Elsevier Ltd on behalf of IJS Publishing Group Ltd. This is an open access article under the CC BY-NC-ND license (<http://creativecommons.org/licenses/by-nc-nd/4.0/>).

chronic atrial fibrillation and had a prothrombin time-international normalized ratio of 1.74 at presentation. The patient had no notable family history or psychosocial history.

At initial presentation immediately visiting our hospital, the patient complained of sustained posterior neck pain, but denied dyspnea, syncope, hoarseness, or breathing issues. Physical examination revealed no other pathological findings. Neurological tests were normal, and his Glasgow Coma Scale score was 15. However, after tens of minutes, namely four hours after the fall, he suddenly presented respiratory insufficiency and lost consciousness in the ED waiting room of the hospital. His vital signs were as follows; blood pressure of 81/47 mmHg, heart rate of 132 beats/min, percutaneous oxygen saturation of 51 % in room air. Arterial blood gas analysis at that time uncovered respiratory acidosis; pH 7.011, PCO_2 123.0 Torr, and PO_2 142.0 Torr.

The patient was admitted to the emergency department and required secure airway management. Following manual ventilation using a bag valve mask, the oxygenation once improved to percutaneous oxygen saturation of 100 %. An anesthesiologist attempted endotracheal intubation after administration of sedatives and muscle relaxants. However, as the posterior pharynx was swollen and the glottis was not visible, oral tracheal intubation was not successful in spite of two attempts even using a glidescope. Finally, an urgent tracheotomy was performed by surgeons in the emergency department. Along with discontinuation of warfarin, vitamin K and fresh frozen plasma were administered to antagonize the anticoagulation effect of warfarin for tracheostomy.

Emergency contrast-enhanced computed tomography (CT) demonstrated a huge retropharyngeal hematoma $53 \times 145 \times 25$ mm in size. Cervical fracture (C3) and spinous process fracture of the cervical spine were noted. This hematoma compressed the hypopharynx and larynx, which may have caused dyspnea (Fig. 1). Contrast agent extravasation was seen in the hematoma at the C7 vertebral body level.

Angiography revealed an extravasation from the right ascending cervical artery, a second branch of thyrocervical trunk. The right thyrocervical trunk, which is the upstream blood vessel from the branch, was embolized with coil (Fig. 2). No pseudoaneurysms or arteriovenous fistulas were detected in the cervical vessels. A neck collar was attached for the C3 cervical fracture. The patient was moved from the intensive care unit to the surgical ward on the seventh day of hospitalization. The retropharyngeal hematoma underwent non-operative management. The patient was properly shared perspective on the treatment he received after intensive care, and was well adhered to and tolerated his treatment. Decanulation was postponed until the patient's giant retropharyngeal hematoma was absorbed and ensured airway safety. The tracheostomy cannula was removed 40 days after admission, and his anatomical airway was fully patent. The patient was discharged home 52 days after admission without any medical complications. The patient still does not show symptoms of airway difficulty after more than 12 months.

3. Discussion

The pathogenesis of retropharyngeal hematoma is a vascular injury with intimal damage resulting from a direct insult or extreme neck movements, either from the actual trauma or from surrounding bony structures. Injuries may include dissection, pseudoaneurysm, or intramural thrombosis [5].

Since these injuries are most frequently associated with closed cervical neck trauma, emergency physicians should keep in mind that in the elderly, a minor head injury with neck hyperextension can trigger acute airway obstruction. This patient was associated with a minor C3 fracture. A previous study reported that patients

with cervical vertebral fractures higher than C6 tend to develop retropharyngeal hematomas [6,7].

Like in the patient, oral anticoagulation, which is frequently used for patients with atrial fibrillation to prevent embolic complications, may enhance the risk of retropharyngeal hematoma, even after minor trauma. Warfarin-associated hemorrhagic complications account for 10.5 % of all adverse drug reactions that result in hospital admissions [8]. Bleeding is more likely when INR is greater than 4.5 [9]. Retropharyngeal hematomas have also been connected to coughing, whiplash injury, cannulation of the internal jugular vein, bleeding diathesis, arteriography, foreign body ingestion, insertion of a gastric tube, carotid artery aneurysm, retropharyngeal infection, carotid sinus massage, and carcinoma, and can even spontaneously occur [10–12].

Most retropharyngeal hematoma patients are conservatively managed [13]. There is little evidence supporting the use of prophylactic antibiotics or steroids in these patients [11]. Reversal of coagulopathy in those taking anticoagulants should be promptly performed if indicated. For this patient, a combination of fresh frozen plasma and vitamin K was administered in the emergency department to antagonize the effect of warfarin and prevent the spread of the hematoma. Occasionally, if the hematoma is extremely large or impedes mechanical ventilation, surgical drainage is required. Interventional radiology (TAE) should immediately be considered as an alternative recourse before other surgical interventions. TAE's advantages include not necessarily needing general anesthesia, rapid access, short procedure time, ability to control multiple local bleeding points, and ability to use angiography to localize superior hemorrhage origin and perform super selective therapeutic vessel occlusion by cannulating the smaller vessel branches not amenable to open surgical repair.

If airway compromise occurs, the airway must be immediately secured. Endotracheal intubation can be challenging due to hematoma localization and dangerous when there is damage to the cervical spine. A rough oropharyngeal intubation attempt can end in hematoma rupture with bleeding and escalating edema, further compromising the airway. Fiberoptic endoscopy may be helpful in performing non-traumatic intubation. Emergent tracheostomy can be considered as an alternative yet infrequently utilized option, like in the patient [14].

To the best of our knowledge, this is the first case report describing an ascending cervical artery injury due to blunt trauma leading to an airway emergency. Previous reports show that half of cervical spine injury cases with airway narrowing require a definitive airway within five hours after the injury and all patients 24 h later [2]. Therefore, careful observation should be continued, even for patients who do not initially exhibit an airway disorder like this patient, because asphyxia may develop suddenly and lead to fatal outcomes [2,13,15]. Also, as this case shows, even with prompt and appropriate management at admission, retropharyngeal hematomas in the elderly receiving anticoagulant therapies require long-term observation and hospitalization.

4. Conclusion

Airway compromise due to a retropharyngeal hematoma caused by blunt neck trauma can rapidly exacerbate even hours after the injury; therefore, emergency physicians should pay close attention to patients, especially those receiving anticoagulant therapy. When a patient with a non-displaced cervical spine injury has an obstructed airway, vigorous hemorrhage in the retropharyngeal space should be considered the agent, and clinicians should perform emergency contrast-enhanced CT of the neck after the airway is promptly secured.

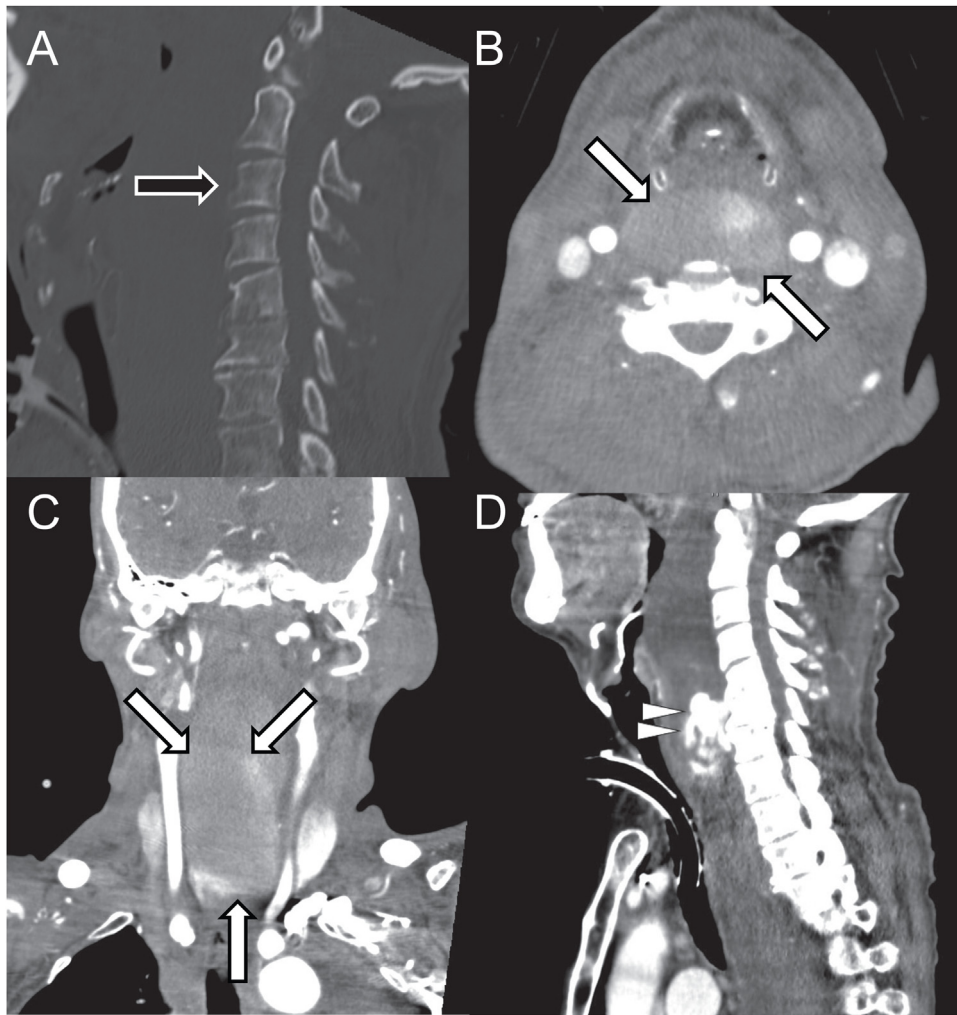


Fig. 1. Contrast-enhanced computed tomography images of the neck. A widespread hematoma and anterior airway displacement were observed in the retropharynx with leakage of the contrast medium in coronal (A), sagittal (B), and transverse (D) plane. The arrows indicate the leakage of the contrast medium. Cervical fracture was also noted (C).

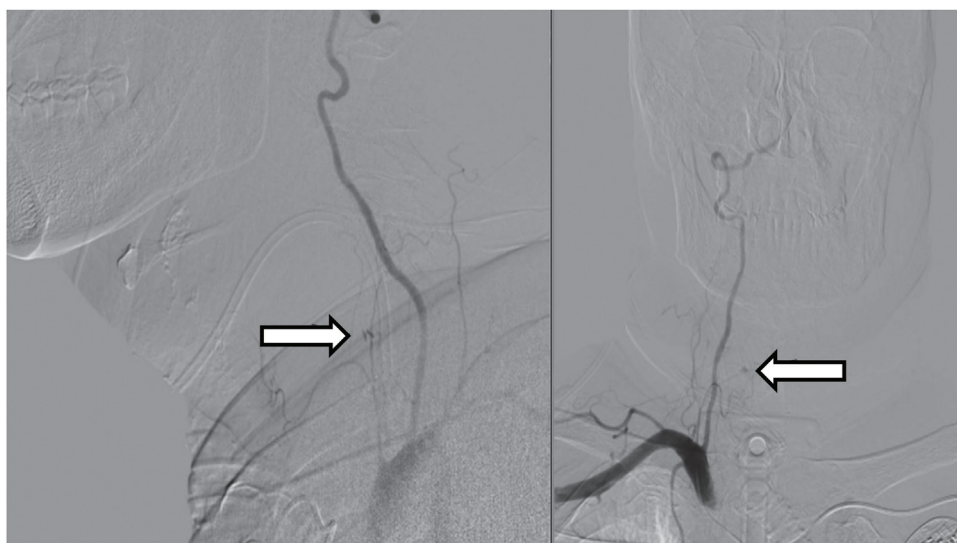


Fig. 2. Angiographic images of the neck in side and front view. Each arrow points to the extravasation of the contrast medium from the ascending cervical artery.

Declaration of Competing Interest

The authors report no declarations of interest.

Funding

No funding support was given for this study.

Ethical approval

Ethical approval was waived for this study.

Consent

Written informed consent was obtained from the patient for publication of this case report and accompanying images. A copy of the written consent is available for review by the Editor-in-Chief of this journal on request.

Authors contribution

Atsuyoshi Iida, Ayumi Nishida, Shunsuke Nakamura, Seiji Yoshitomi, Tsuyoshi Nojima, and Hiromichi Naito contributed to the study design, data collections, data analysis, writing and review. Ayumi Nishida performed the transarterial embolization. Atsunori Nakao contributed to the data collections and review. All authors have read and approved the final manuscript.

Registration of research studies

Not applicable.

Guarantor

Atsuyoshi Iida.

Provenance and peer review

Not commissioned, externally peer-reviewed.

Acknowledgements

We thank Christine Burr for English-language editing.

References

- [1] L. Penning, Prevertebral hematoma in cervical spine injury, *AJR Am. J. Roentgenol.* 136 (1981) 553–561.
- [2] J.E. Kuhn, G.P. Graziano, Airway compromise as a result of retropharyngeal hematoma following cervical spine injury, *J. Spinal Disord.* 4 (1991) 264–269.
- [3] R.C. Schneider, K.E. Livingston, A.J.E. Cave, G. Hamilton, “Hangman’s fracture” of the cervical spine, *J. Neurosurg.* 22 (1965) 141–154.
- [4] R.A. Agha, M.R. Borrelli, R. Farwana, K. Koshy, A. Fowler, D.P. Orgill, For the SCARE Group, The SCARE 2018 statement: updating consensus surgical CAse REport (SCARE) guidelines, *Int. J. Surg.* 60 (2018) 132–136.
- [5] J.J. O'Donnell, R. Birkinshaw, B. Harte, Mechanical airway obstruction secondary to retropharyngeal haematoma, *Eur. J. Emerg. Med.* 4 (1997) 166–168.
- [6] T. Suzuki, H. Imai, M. Uchino, R. Wakita, M. Endo, T. Kitahara, et al., Fatal retropharyngeal haematoma secondary to blunt trauma, *Injury* 35 (2004) 1059–1063.
- [7] P.L. Tenofsky, S.W. Porter, J.W. Shaw, Fatal airway compromise due to retropharyngeal hematoma after airbag deployment, *Am. Surg.* 66 (2000) 692–694.
- [8] J.A. Coleman Jr., J.T. Johnson, Retropharyngeal hematoma: complication of cervical fracture, *Otolaryngol. Head. Neck Surg.* 94 (1986) 387–390.
- [9] K.A. Collins, K. Sellars, Vertebral artery laceration mimicking elder abuse, *Am. J. Forensic Med. Pathol.* 26 (2005) 150–154.
- [10] G. Jakanani, R. Kenningham, A. Bolia, Active retropharyngeal hemorrhage from an acute thyrocervical artery injury: a rare complication of hyperextension cervical spine injury, *J. Emerg. Med.* 43 (2012) e39–41.
- [11] C.A. McLauchlan, R. Pidsley, P.J. Vandenberk, Minor trauma-major problem. Neck injuries, retropharyngeal haematoma and emergency airway management, *Arch. Emerg. Med.* 8 (1991) 135–139.
- [12] F. Kette, P. Mergoni, M. Girardis, D. Sabbadini, M. Zauli, L. Sussi, et al., Delayed upper airway obstruction following a retropharyngeal haematoma after minor head trauma, *Eur. J. Emerg. Med.* 7 (2000) 301–303.
- [13] L.W. Lazott, J.A. Ponzio, R.B. Puana, K.S. Artz, D.P. Ciceri, W.C. Culp Jr., Severe upper airway obstruction due to delayed retropharyngeal hematoma formation following blunt cervical trauma, *BMC Anesthesiol.* 7 (2007) 2.
- [14] Jeffrey L. Apfelbaum, Carin A. Hagberg, Robert A. Caplan, Casey D. Blitt, Richard T. Connis, David G. Nickinovich, et al., Practice guidelines for management of the difficult airway: an updated report by the American Society of Anesthesiologists Task Force on Management of the Difficult Airway, *Anesthesiology* 118 (2013) 251–270.
- [15] S. Senthuran, S. Lim, K.E. Gunning, Life threatening airway obstruction caused by retropharyngeal haematoma, *Anaesthesia* 54 (1999) 674–678.

Open Access

This article is published Open Access at [sciencedirect.com](https://www.sciencedirect.com). It is distributed under the [IJSCR Supplemental terms and conditions](#), which permits unrestricted non commercial use, distribution, and reproduction in any medium, provided the original authors and source are credited.