



Brief Report

Postural Axial Tremor in a Patient with Cerebellar Atrophy

A. Albanese, A. Daniele, M. Lo Monaco, V. Di Lazzaro, D. Restuccia, M. Milone, and P. Tonali

Istituto di Neurologia, Università Cattolica del Sacro Cuore, Roma, Italy

Summary: A patient affected by low-frequency postural tremor of the trunk and limbs is reported. Apart from mild dysarthria and gait ataxia, no other neurological abnormalities were present. Cerebellar atrophy was demonstrated by means of magnetic resonance imaging. The tremor was associated with alternating activity in antagonistic muscles; it was triggered whenever a contraction of lumbar back extensor muscles occurred. Electrical stimulation of the cerebellum did not produce the normal suppression phases of motor responses evoked by a magnetic stimulation of the cerebral cortex. **Key Words:** Cerebellum—Brain stimulation—Degenerative diseases—GABA—Tremor.

Tremors that appear while standing constitute an uncommon clinical sign, which may be observed in a restricted number of neurological disorders. We observed the case of a man who developed a low-frequency trembling of the trunk, which only appeared when standing or during postures against gravity.

CASE REPORT

A 70-year-old man first experienced unsteadiness and swaying while walking and occasional falls. About a year later, he noticed a quivering of the trunk and neck and sometimes of the arms, that appeared when he sat, stood, or walked. Upon prescription of a neurologist, he was treated with low doses of levodopa plus benserazide for ~1 year with no relief. This movement disorder slowly progressed throughout the following years.

At the age of 75, the patient was first reported to us as affected by orthostatic tremor. He complained of a disabling tremulous condition that constantly appeared when standing. Family history revealed that his maternal grandfather, who lived until the age of 90, suffered from a shaking of the trunk and of the arms while standing, which disappeared when seated. Medical history was re-

markable only for a chronic bronchitis and a diabetes mellitus controlled by oral therapy.

Neurological examination was remarkable for normal mentation, dexterity, mild cerebellar signs, and a postural tremor of the trunk. No sensory abnormalities were found; muscle strength and tone were normal; deep tendon reflexes were reduced in the four limbs; plantar responses were flexor. There were neither intention tremor or dysmetria or adiadochokinesia, but a mild dysarthria was associated with a slightly wide-based gait. No tremor was present when lying down or when seated leaning against the back of a chair, but, immediately after seating with no back support or standing up, fore-aft rhythmic oscillatory movements began in his trunk that progressed to the limbs. The tremor did not resolve upon walking, but rather increased in amplitude; it disappeared when the patient was lifted vertically off the floor, when he actively bent his trunk against resistance or when the extensor muscles of the trunk were relaxed (e.g., by leaning against the back of a chair). In the limbs, tremulous movements were proximal and increased with sustained postures (e.g., when the arms were outstretched).

No tremor was present when the patient lay either supine or prone. In the prone position, tremor could be evoked by asking the patient to contract the paraspinal extensor muscles to raise his trunk against gravity. By contrast, when prone, no tremor occurred when the head alone was raised by a voluntary contraction of the neck extensor muscles against gravity. On the whole, the

A videotape segment accompanies this article.

Address correspondence and reprint requests to Dr. A. Albanese at Istituto di Neurologia, Università Cattolica, Largo A. Gemelli, 8, I-00168 Roma, Italy.

tremor occurred whenever the trunk was actively maintained in such antigravitary postures that required a contraction of paraspinal extensor muscles (e.g., when seated with no back support), whereas it disappeared in all postures associated with a relaxation of the same muscles (e.g., when seated with back support). Most motor activities were affected by the occurrence of tremor. As an example, when the patient sat at a table leaning against the back of a chair, his handwriting was much better than that produced when he sat with his back unsupported (Fig. 1).

All routine investigations (except for blood sugar) were normal; serum ceruloplasmin and copper levels, and urinary copper excretion were all normal. MR showed a marked cerebellar atrophy involving the vermis and the medial hemispheres, particularly in the anterior lobe (Fig. 2); a mild cortical and subcortical cerebral atrophy, consistent with the age of the subject, was also reported.

The patient was first treated with clonazepam (0.25 mg t.i.d.), which was effective in relieving the tremor. The treatment was discontinued due to the onset of side effects (namely, drowsiness and muscle weakness). A treatment with baclofen (10 mg t.i.d.) was then started. After a few weeks of treatment, an initial significant relief of tremor occurred. The therapeutic benefit lasted for some months, then it gradually disappeared. Propranolol (40 mg b.i.d.) had no effect on tremor.

ELECTROPHYSIOLOGICAL DATA


Electroencephalograms recorded while standing or laying were normal. Motor and sensory nerve conduction studies along several nerves of upper and lower limbs showed normal findings. Somatosensory potentials evoked by stimulation of the median nerve and of the ulnar nerve were of normal latency and size. Central motor conduction to upper and lower limb myotomes evaluated by means of magnetic stimulation of the motor cortex and of the spine was normal.

Electromyography

Electromyographic recordings from posterior muscles of the neck and of the back showed a rhythmic activity consisting of bursts occurring at 3 Hz with an average burst duration of approximately 150 ms. Similar bursts were also recorded in the limbs, where they were less evident distally. An alternating pattern was shown both in limb and neck antagonistic muscles (Fig. 3). EMG recordings performed in different muscles during postural oscillations in the orthostatic position showed that rhythmic EMG activity could be selectively abolished in the upper limb muscles but not in the paraspinal extensor muscles. It was observed that EMG activity could be abolished in the biceps brachii, in the triceps brachii, or in both when the relevant muscle was relaxed (Fig. 4). The rhythmic

A

questa mattina mi sono
 abitato alle ore quattro mi sono
 fatta la barba, poi sono
 tornato al letto



B

questa mattina mi sono
 abitato alle ore quattro mi sono
 fatta la barba, poi sono
 tornato al letto

FIG. 1. When the patient sits with no back support (A), his handwriting is significantly worse than when he actively pushes the trunk against the table while sitting (B). In the first position, tremor occurs in the trunk and in the proximal upper limbs, handwriting is large and irregular; in the latter position, tremor is not detectable, handwriting is fluent. Calibration bar = 2 cm.

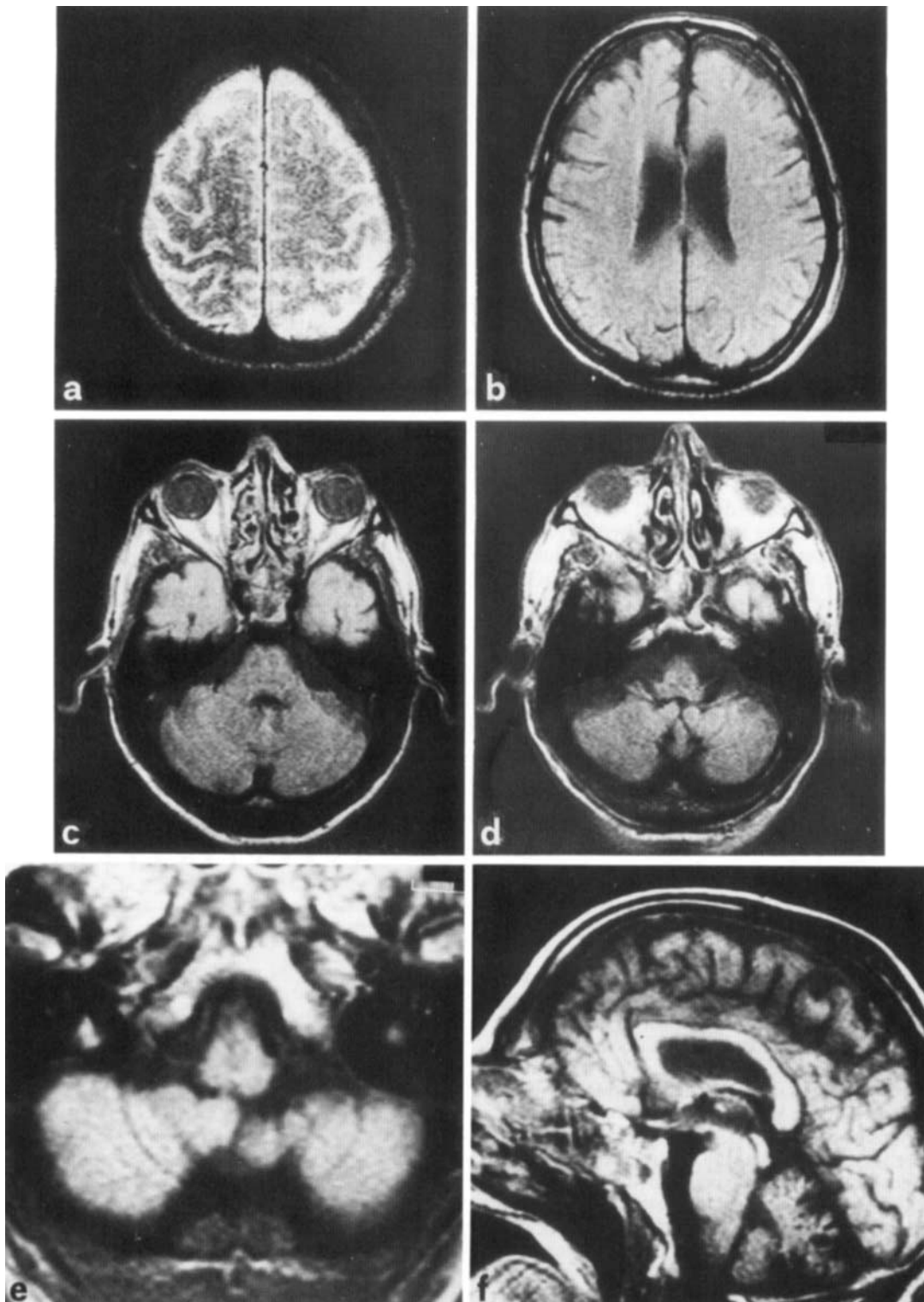


FIG. 2. a-f: Magnetic resonance scan reveals the presence of a mild cortical and subcortical atrophy and of a severe cerebellar atrophy affecting particularly the hemispheres and the anterior lobe (d,e).

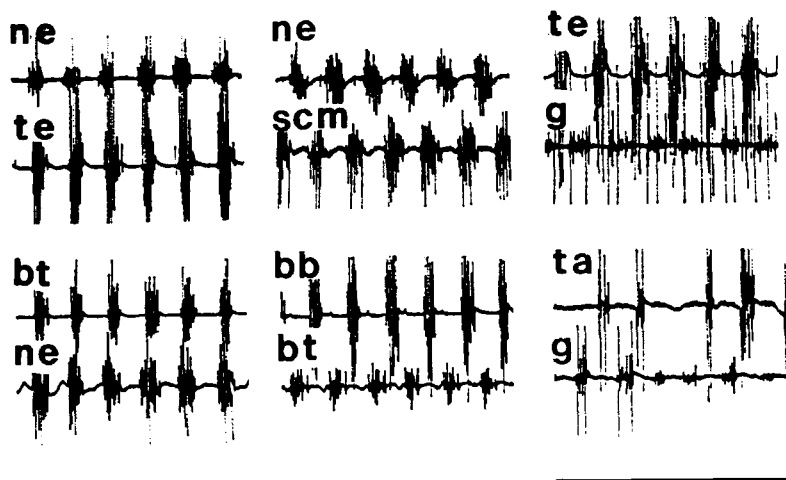


FIG. 3. Rhythmic spontaneous EMG activity recorded in agonistic (left column) and in antagonistic muscles (middle and right columns) while standing. The extensor muscles of the neck (ne) and of the trunk (te) discharge synchronously with the triceps brachii (bt) and with the tibialis anterior (ta). By contrast, an alternating pattern is recorded in antagonistic muscles of the neck (ne and scm), of the limbs (bb and bt, ta and g). EMG bursts recorded in the trunk extensors (te) were not in phase with those of the gastrocnemius (g). bb, biceps brachii; bt, triceps brachii; g, gastrocnemius; ne, neck extensors; scm, sternocleidomastoid; ta, tibialis anterior; te, trunk extensors. Time bar = 2 sec.

EMG activity of the trunk disappeared in postures not associated with the activation of lumbar paraspinal muscles. When the patient laid in the supine position, the extension of the head produced a normal recruitment in the neck extensors; when the trunk was raised by extending the lumbar muscles, the recruitment in the lumbar extensors showed an alternating pattern. The voluntary contraction of lumbar paraspinal extensor muscles also turned the normal recruitment pattern of neck extensors into a 3-Hz rhythmic activity (Fig. 5).

When EMG recordings of the paraspinal extensor muscles were performed simultaneously at several rostrocaudal levels it was observed that the activity of muscles located at cervical levels always preceded that of dorsal and lumbar muscles. Since the time of onset of the first tremor burst increased rostrocaudally, the rhythmic EMG activity appeared to proceed along the spinal cord (Fig. 6).

Cerebellar Stimulation

The excitability of motor cortex was examined at different times after an electrical stimulus over the cerebellum (1,2). For cerebellar stimulation, electrical stimuli (300 V and 50 μ s in duration) were delivered through two electrodes placed 5 cm lateral to the inion on a line joining the inion and the external auditory meatus, with the anode on cerebellar hemisphere contralateral to the stimulated motor cortex. Transcutaneous magnetic stimulation of the motor cortex was achieved using a Magstim 200 (Novametrics, UK). The magnetic pulses were delivered through a 90-mm circular coil. The maximal magnetic field generated was \sim 2 tesla at the centre of the coil. The stimulus intensity was set to be just above motor threshold. The coil was centered over the vertex. To obtain a preferential activation of each hemisphere, a clockwise inducing current flow, as viewed from above, was used for the right motor cortex and a counter-clockwise flow for the left motor cortex (3). All experiments were performed at rest. Compound motor action potentials (CMAPs) were recorded from the abductor digiti minimi muscle by surface electrodes and amplified with filter settings of 2 Hz and 5 KHz. After recording CMAPs evoked

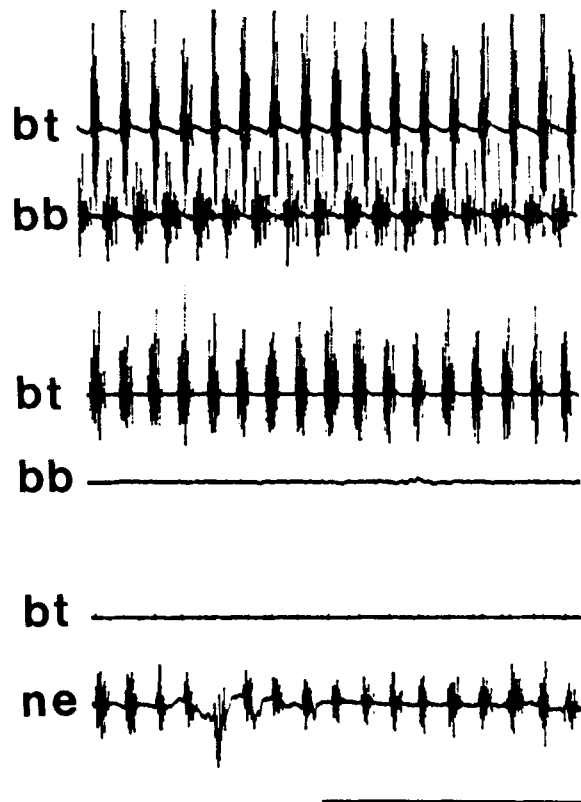
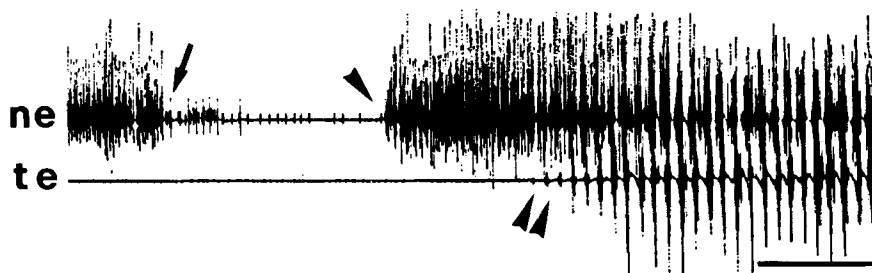


FIG. 4. An alternating activation pattern of the triceps (bt) and of the biceps brachii (bb) is observed in the upper limb when the patient is standing with outstretched arms (upper traces). The antigravitary job exerted by either muscle can be selectively abolished by relaxing the arm. Under these circumstances rhythmic activity selectively disappears in the relaxed muscle: either in the biceps brachii (middle traces) or in the triceps brachii (lower traces), whereas neck muscles are unaffected (lower traces). bb, biceps brachii; bt, triceps brachii; ne, neck muscles. Time bar = 3 sec.

FIG. 5. When the patient raises his head EMG activity can only be recorded in the neck (ne); when he is lying prone (arrow), no spontaneous activity occurs either in the neck (ne) or in the lumbar trunk extensor (te) muscles. When the head is lifted again (single arrowhead), a normal recruitment of motor units is recorded in the neck extensor muscles. When the trunk is also lifted (double arrowhead), a rhythmic 3-Hz activation of the trunk extensor muscles appears and the activity pattern of the neck extensor muscles becomes rhythmic too. Time bar = 3 sec.



by cortical magnetic stimulation to obtain a control response, we coupled magnetic stimulation of the motor cortex with electrical stimulation of the cerebellum. The interval between cerebellar and cortical stimulation was varied from 2 to 12 ms. Four responses at each time interval were recorded. They were measured as percentage of the amplitude of control responses obtained after cortical stimulation alone. The mean percent values measured in this patient were compared with those obtained from seven normal subjects. Statistical validation was performed by means of Student's *t* test.

In all normal subjects, shocks over the cerebellum reduced the peak-to-peak amplitude of the CMAPs recorded from the abductor digiti minimi after magnetic

stimulation of the motor cortex. The suppression consisted of two phases; the first phase reached a maximum when the stimulus over the cerebellum preceded the cortical stimulus by 5 ms, and the responses were 50% (SD = 18.3; $p < 0.001$) of the control size; the second phase reached its maximum when the cerebellar stimulus preceded the cortical stimulus by 10 ms and the responses were 49.2% (SD = 9.9; $p < 0.001$) of the control size. In the patient no evident reduction of CMAP amplitude was observed at each time interval studied. When the stimulus over the cerebellum preceded the cortical stimulus by 5 ms the CMAP was 75% of the control size on the right hand side ($p < 0.05$ vs. control values), and it was 91.7% on the left ($p < 0.05$). When the stimulus over the cerebellum preceded the cortical stimulus by 10 msec, the CMAP amplitude was 120% of the control size on the right hand side ($p < 0.001$), and 95% on the left ($p < 0.001$) (Fig. 7).

Neither cortical stimulation nor cerebellar stimulation affected the frequency of the tremor.

DISCUSSION

This case meets most of the criteria which have been so far utilised for the diagnosis of late onset cortical cerebellar atrophy, a syndrome associated with the selective degeneration of Purkinje cells. The first case was reported by Murri (4), who observed that "the anatomical evidence of a cerebellar involvement is the disappearance of Purkinje cells. . . . Pathological abnormalities have been found in the spinal cord and in the brain, but in no other region than the cerebellum a degeneration of nerve cells has been observed." Few years later, Rossi (5) described the clinicopathological correlates of three patients with late onset cerebellar atrophy, who presented ataxia and "oscillations," particularly when starting to walk. Familial cases were first described by Holmes (6). Similar cases were studied pathologically by Hänel and Bielschowsky (7), who observed a diffuse atrophy of the cerebellar hemispheres and reported that "in the Purkinje cells layer there is a marked depletion of neurons . . . [to the extent that] it is necessary to look at several consecutive sections in order to find a single Purkinje cell." More recent descriptions of this syndrome showed that sporadic cases often occur in alcoholic subjects, and confirmed that the clinical picture consists of tremor and of few other cerebellar signs (Table 1), whereas pathologi-

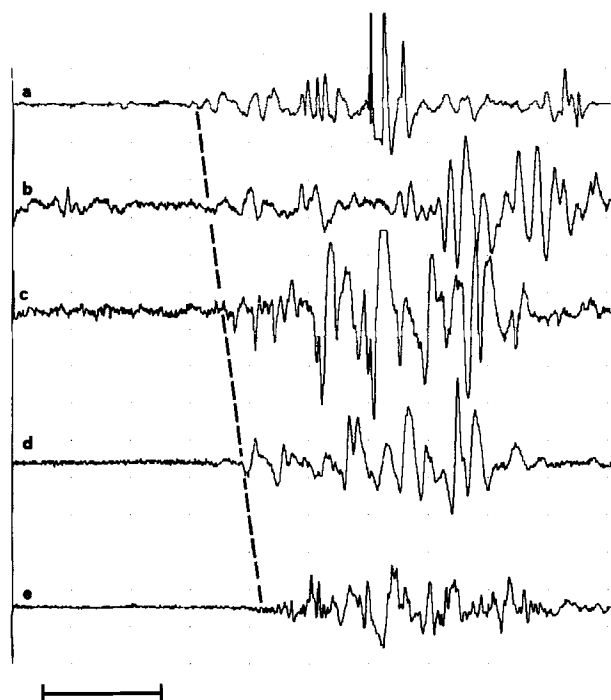


FIG. 6. Simultaneous recordings from extensor paraspinal muscles at different rostrocaudal levels: cervical (a); upper (b), middle (c), and lower (d) thoracic; and lumbar (e). The distance between each recording site is ~12 cm. It can be observed that the time of onset of the first tremor burst increases rostrocaudally (dashed line). Time bar = 40 ms.

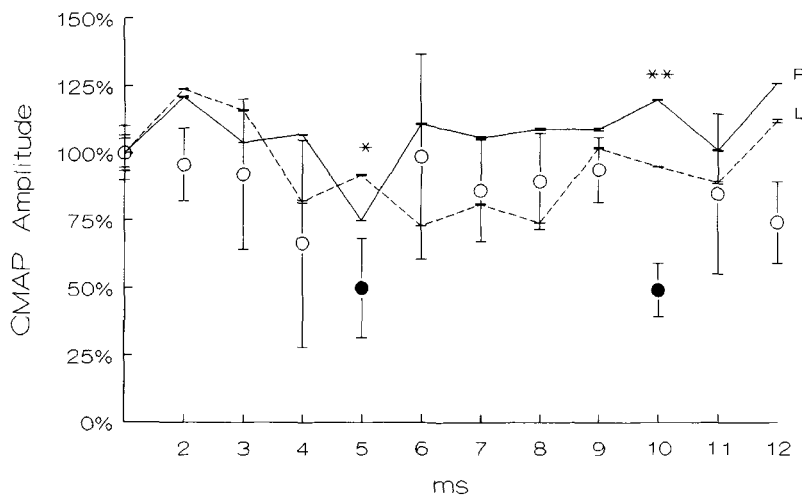


FIG. 7. Changes in amplitude of CMAPs recorded when cortical magnetic stimulation was preceded by electrical stimulation of the cerebellum. CMAP amplitude is represented as percentage of CMAPs evoked by cortical stimulation alone; interstimulus intervals range from 2 to 12 ms. Circles represent the average amplitude (\pm SD) recorded in normal subjects; filled circles indicate intervals at which CMAP was statistically different from CMAP recorded after cortical stimulation alone ($p < 0.001$). Solid and dashed lines are recordings from the right (R) and left (L) hand side of the patient, respectively; standard deviations are also shown for each time interval. In normal controls, CMAP amplitude is markedly suppressed at interstimulus intervals of 5 and 10 ms. In the patient, instead, the normal reduction is not observed; the values observed at 5 and 10 ms are significantly different from controls (* $p < 0.05$; ** $p < 0.001$).

cally a degeneration of the cerebellar cortex is observed (8–10).

Even though pathological confirmation is not available in our case, there are three main lines of evidence suggesting such a nosologic classification (Table 1). First, the overall clinical picture is very typical of late cortical cerebellar atrophy (8); this is supported by the predominance of gait disturbances with wide-based walking in absence of either limb ataxia or hypotonia. Moreover, the occurrence of mild dysarthria and dysgraphia are thought to be consistent with this clinical entity, while the absence of a past history of alcohol misuse does not disprove the di-

agnosis (8). Second, low-frequency tremor (< 4 Hz) is thought to be pathognomonic of cerebellar dysfunction; indeed, a 3-Hz postural tremor of the limbs was also described in patients affected by multiple sclerosis with cerebellar signs (11). This latter tremor has a wide amplitude and is also characterized by alternating activity in antagonistic muscles with EMG bursts of ~ 200 ms. Third, in this patient MR scan revealed a marked cerebellar atrophy, mainly involving the vermis and the medial part of the cerebellar hemispheres in the anterior lobe.

In this case, tremor occurred in the trunk and in the lower limbs on standing and disappeared when the patient

TABLE 1. Clinical features of orthostatic tremor and of late cortical cerebellar atrophy

	Orthostatic tremor	Late-onset cortical cerebellar atrophy (8)	This case
Age (years)	> 50	38–62 (mean, 51)	70
M:F ratio	1:1	3:1	Male
Family history for tremor	Usually no history	No history	Grandfather with tremor
Features of tremor			
Frequency (Hz)	Usually > 15	3	3
Latent period	Several seconds	< 1 s	< 1 s
Crescendo	Yes	Not reported	No
Activating factors	Isometric activity of lower limbs	Isotonic activity of lower limbs Electrical stimulation of posterior tibialis nerve	Isometric or isotonic contraction of lumbar paraspinal muscles
Pattern of activity	Synchronous or alternating	Alternating	Alternating
On standing	Present	Present	Present
On walking	Absent	Not reported	Present
At rest	Absent	Not reported	Absent
When lifted off	Absent	Not reported	Absent
Drugs			
Helpful	Clonazepam Primidone	Not reported	Baclofen Clonazepam Propranolol
Not effective			
Associated cerebellar features			
Dysarthria	Absent	Slight in 46% of cases	Slight
Limb ataxia	Absent	Slight in 8% of cases	Absent
Dysdiadochokinesia	Absent	Present in 15% of cases	Absent
Wide based gait	Absent	Present in all cases	Present

was lifted vertically off the floor or when he laid down. These features are typically seen also in patients with orthostatic tremor (12–14), but several lines of evidence differentiate this case from those of orthostatic tremor (Table 1). First, in this patient tremor was not reduced when he sat or walked; on the contrary it increased in amplitude on walking. Second, although a wide range of frequencies has been reported to be associated with orthostatic tremor, they are never <6–7 Hz (13–16). According to Rothwell (17), the frequency of orthostatic tremor is typically 16 Hz. Third, as confirmed by EMG findings, in this patient the tremor was more evident and incoercible in the trunk rather than in the limbs.

The occurrence of rhythmic EMG activity in the neck and back muscles has not been described in previous reports on late cortical cerebellar atrophy. Our physiological data on this patient demonstrate that a prolonged contraction of lumbar back muscles generates a low frequency rhythmic activation, which also triggers the onset of a rhythmic activity in other muscles of the trunk and limbs, which would otherwise contract continuously (Fig. 5). Thus, even though tremor occurred during orthostatism (as well as in other body postures), it was not triggered by orthostatism and occurred in any posture of the body associated with a contraction of lumbar back muscles. Idiopathic orthostatic tremor is also postural in nature, since it is triggered by postural isometric contractions of lower limb muscles (15,16). This may lead to criticize the epithet "orthostatic," since idiopathic orthostatic tremor can also be observed in patients laying prone or supine and it disappears when they are lifted vertically off the floor.

The active contraction of lumbar paraspinal muscles appeared to be a specific triggering factor in this patient, because a voluntary contraction of lumbar paraspinal muscles not only produced a tremulous contraction in the same muscles but also turned a normal interference activity of neck extensor muscles into a rhythmic one (Fig. 5). Such a triggering manoeuvre has not been previously reported in patients affected by tremors or by other movement disorders. The triggering role played by a contraction of lumbar paraspinal extensor muscles on the tremor is also consistent with the observation that the patient spontaneously developed tricks to decrease the contraction of lumbar extensor muscles. As shown in the videotape, in order to reduce the tremor, when standing he bent his trunk forward; in addition, he could stop completely the tremor by actively bending his trunk forward against resistance. The observation of a clear increase of tremor during walking was also explained by an increase in the activity of the same muscles, which normally are subject to repetitive contractions during walking.

As reported above, in patients affected by late onset cortical cerebellar atrophy a degeneration of the cerebellar cortex, particularly of Purkinje cells, has been clearly observed by several authors. Purkinje cells are known to be GABAergic and to represent the source of corticonuclear projections in the cerebellum (18). Thus, it may be hypothesised that late cortical cerebellar atrophy is a degenerative disease predominantly affecting a morphological and chemical class of nerve cells. Whether this is

the case in our patient is unknown. We believe that this or some other mechanism is able to switch on the activity of a central rhythmic discharge. The observation that a stimulation of the cerebellum did not produce the normal suppression phases on compound motor action potentials evoked by a magnetic stimulation of the cerebral cortex is consistent with this view. Interestingly, the physiological defect in cerebellar function was demonstrated in the abductor digiti minimi muscle even in the absence of a clinical evidence of cerebellar dysfunction in the distal upper limbs. This indicates that the combination of cerebellar stimulation and of magnetic cortical stimulation can be used to detect a deficit in cerebellar inhibition of the motor cortex also in the absence of clinical signs of cerebellar disease in the body part under study.

A putative suprasegmental oscillator may be located in the inferior olives, but the existence of a spinal oscillator cannot be ruled out. The latter mechanism could probably explain more easily the peculiar occurrence of a trigger region located in the paraspinal extensor muscles. Still, our physiological data, showing that the activation of axial muscles proceeds in a rostrocaudal sequence, strongly support the existence of a suprasegmental origin.

LEGEND TO VIDEOTAPE

A patient affected by rhythmic (3 Hz) oscillatory forearm movements of the trunk is shown. The tremor occurs when the patient sits with no back support; it disappears when the trunk is supported by the arms or by the back of a chair. In the upright position the tremor is increased by walking. The walking stick is of no additional use when walking; it is used, instead, to reduce the tremor by supporting the body upon standing and, by this way, releasing the lumbar extensor muscles. Walking is wide-based and ataxic; stamping on the floor produces a rhythmic noise. Handwriting also significantly worsens when the tremor occurs; therefore, when writing at a table, the patient actively pushes the trunk against the table.

REFERENCES

1. Day BL, Ugawa Y, Rothwell JC, Thompson PD, Marsden CD. Suppression of the motor cortex by an electrical stimulus over the cerebellum in intact man. *Mov Disord* 1990;5(suppl 1):5.
2. Ugawa Y, Day BL, Rothwell JC, Thompson PD, Merton PA, Marsden CD. Modulation of motor cortical excitability by electrical stimulation over the cerebellum in man. *J Physiol* 1991;441:57–72.
3. Day BL, Hess CW, Maertens de Noordhout A, et al. Direction of current in magnetic stimulating coils used for percutaneous activation of brain, spinal cord, and peripheral nerve. *J Physiol* 1990;430:617.
4. Murri A. Degenerazione cerebellare da intossicazione enterogena. *Rivista Critica di Clinica Medica (Firenze)* 1900; 1:593–8,609–16.
5. Rossi I. Atrophie primitive parenchymateuse du cervelet à localisation corticale. *Nouvelle Iconographie de la Salpêtrière (Paris)* 1907;20:66–83.
6. Holmes G. A form of familial degeneration of the cerebellum. *Brain* 1907;30:466–89.

7. Hänel H, Bielschowsky M. Olivocerebellare Atrophie unter dem Bilde des familiären Paramyoklonus. Nebst Beiträgen zur Kenntnis der normalen und pathologischen Anatomie des Kleinhirns. *Journal für Psychologie und Neurologie (Leipzig)* 1915;21:385-416.
8. Mauritz KH, Dichgans J, Hufschmidt A. Quantitative analysis of stance in late cortical cerebellar atrophy of the anterior lobe and other forms of cerebellar ataxia. *Brain* 1979; 102:461-82.
9. Thomas A. Atrophie lamellaire des cellules de Purkinje. *Rev Neurol (Paris)* 1905;13:917-24.
10. Victor M, Adams RD, Mancall EL. A restricted form of cerebellar cortical degeneration occurring in alcoholic patients. *Arch Neurol* 1959;1:579-688.
11. Sabra AF, Hallett M, Sudarsky L, Mullally W. Treatment of action tremor in multiple sclerosis with isoniazid. *Neurology* 1982;32:912-3.
12. Heilman KM. Orthostatic tremor. *Arch Neurol* 1984;41:880-91.
13. Papa SM, Gershanik OS. Orthostatic tremor: an essential tremor variant? *Mov Disord* 1988;3:97-108.
14. Thompson PD, Rothwell JC, Day BL, et al. The physiology of orthostatic tremor. *Arch Neurol* 1986;43:584-7.
15. Uncini A, Onofrij M, Basciani M, et al. Orthostatic tremor: report of two cases and an electrophysiological study. *Acta Neurol Scand* 1989;79:119-22.
16. Wee AS, Subramony SH, Currier RD. "Orthostatic tremor" in familial-essential tremor. *Neurology* 1986;36:1241-5.
17. Rothwell JC. Orthostatic tremor. In: Quinn N, Jenner P, eds. *Disorders of movement: clinical, pharmacological and physiological aspects*. New York: Academic Press, 1989:521-8.
18. Schulman JA. Chemical neuroanatomy of the cerebellar cortex. In: Emson PC, ed. *Chemical neuroanatomy*. New York: Raven Press, 1983:209-28.